

# Predictive factors of ectopic eruption of the maxillary permanent second molar: A retrospective study

Original  
Article

*Dina Osman ElAbbasy*

*Ass. Prof. of Orthodontics, Orthodontic Department, Faculty of Dentistry, Cairo University.*

---

## ABSTRACT

**Aim of the study:** The aim of this study was to investigate the diagnostic methods and possible predictive factors associated with maxillary second molars ectopic eruption.

**Materials and Methods:** This retrospective study assessed the diagnostic records of 40 adult female subjects (study models, panoramic radiographs, and lateral cephalometric radiographs) equally divided into two groups: normal maxillary second molar eruption (20 subjects, mean age 25.625.19±) and bilateral ectopic maxillary second molar eruption (20 subjects, mean age 27.784.65±). The variables were statistically analyzed by independent t-tests and Mann-Whitney U test.

**Results:** The mesiodistal diameter of the maxillary second premolars, first permanent molars and second permanent molars bilaterally were significantly larger in the ectopic eruption group compared to the normal group. Greater arch lengths were also recorded for the ectopic group. Regarding cephalometric measurements angles SNA, OP-17, and linear measurements PTV-16 and PTV-17 were significantly smaller in the ectopic eruption group. Angles HRL/16d-17d & Angle 1617- were significantly larger in the ectopic eruption group. Panoramic radiograph in the ectopic eruption group showed increased inclination of the maxillary molars in a distal direction compared to the normal eruption group whereby angles OP/17, OP/27 were significantly smaller in the ectopic group. Intermolar angles 1617/ and 2627/ were significantly larger in the ectopic eruption group.

**Conclusion:** Multiple factors are associated with the ectopic eruption of maxillary second molars. This could be used as a diagnostic aid for the prediction of this eruption disturbance.

**Key Words:** Ectopic eruption, Eruption disturbance, Malalignment, Prediction, Second permanent molar

**Received:** 7 June 2023, **Accepted:** 15 June 2023.

**Corresponding Author:** Dina Osman ElAbbasy, Ass. Prof. of Orthodontics, Orthodontic Department, Faculty of Dentistry, Cairo University., **Mobile:** 01009711115, **E-mail:** dinaosman@hotmail.com

**ISSN:** 2090-097X, January 2023, Vol. 14, No. 1

## INTRODUCTION:

Tooth eruption is defined as the occlusal movement of a tooth from its developmental position inside the jaw towards its functional position at the occlusal plane.<sup>[1]</sup>

Tooth eruption also occurs as a compensatory mechanism for the occlusal wear and growth of the jaws that take place throughout life. During facial growth and development, compensatory changes in the path of tooth eruption also occur. Occasionally, if these compensatory changes are inadequate, positional anomalies and malocclusion might happen.<sup>[2,3]</sup>

Ectopic eruption is defined as any abnormal eruptive position taken by a tooth.<sup>[4]</sup> The maxillary second molar normally erupts in a mesio palatal direction.<sup>[5]</sup>

In some cases, it erupts in a distobuccal direction and never reaches an upright position mainly due to posterior arch length inadequacy. This is due to deficient growth at the maxillary tuberosity.<sup>[6]</sup>

Disturbances in tooth eruption occur due to multiple

etiologic factors which include genetic, systemic, or local factors. Genetic and systemic factors are manifested in some developmental syndromes due to disturbance in the cellular mechanism of tooth eruption<sup>[7]</sup> and involve multiple teeth<sup>[8,9]</sup>.

According to earlier studies, the incidence of ectopic eruption of maxillary first molars is higher than maxillary second molars with a range from 2% to 6%.<sup>[10,13,14,15,16]</sup> The incidence of maxillary second molars ectopic eruption is less common and ranges from 0%-2.3%.<sup>[3,17]</sup> Similar to maxillary canines, they erupt later and therefore are subject to lack of space which result in poor eruption angulation. Other factors due to orthodontic treatment mechanics such as full arch distalization or headgear can negatively impact the space available for the maxillary second molars.<sup>[18]</sup>

Over the years, orthodontists have debated the standard engagement of second molars due to the technical difficulty of bonding or banding the teeth.<sup>[19,20,21]</sup> However, it is essential to consider their position at the initial examination and aim for their adequate alignment within the dental

arch. This is important as second molars provide the distal ends of the dental arch, which maintains occlusal support for appropriate mastication. Furthermore, they assist in the coordination of facial growth.<sup>[22,23,24,25]</sup> Early diagnosis of eruption disturbances is crucial in order to initiate treatment at the ideal time and to minimize complications.<sup>[14]</sup>

First and second molars are of great importance for the normal development of the dentition and coordination of the facial growth.<sup>[24]</sup> Haruki et al<sup>[26]</sup> found a strong association between second molar eruption and calcification rate and normal dentofacial growth (indicated by ANB angle and anteroposterior maxillary length) and occlusal relationship (Class II or Class III malocclusion). Normally, the eruption of mandibular second molars happens before the maxillary second molar.<sup>[24]</sup> Lo and Moyers<sup>[27]</sup> determined that the eruption of the maxillary second molar before the mandibular molar is indicative of Class II malocclusion.

The ectopic eruption of the maxillary second molars has not been thoroughly investigated in the literature. Only a few case reports have been published regarding this topic <sup>[28,29]</sup> as well as a limited number of publications. <sup>[3,6,19,30]</sup> Therefore, the aim of this retrospective study was to examine the possible factors contributing to the ectopic eruption of permanent maxillary second molars and possibly utilize them as predictive factors.

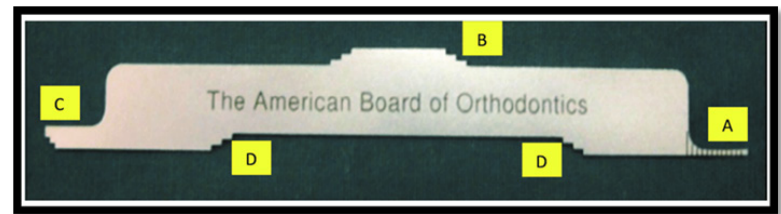
#### MATERIALS AND METHODS:

This study included the records of 40 Egyptian female patients from the patient database of a private orthodontic practice in Cairo, Egypt. Twenty patients had bilateral ectopic eruption of maxillary second molars (mean age  $27.78 \pm 4.65$ ) and 20 patients (mean age  $25.62 \pm 5.19$ ) with normal maxillary second molar eruption were allocated as the normal eruption group or control group.


An ABO gauge (American board of orthodontics) (Figure 1) was used to quantify the maxillary second molar displacement.

The inclusion criteria for the normal eruption group were: a- well aligned maxillary second molars in the buccolingual direction or within 0.5 mm of malalignment, b- marginal ridge discrepancy between the maxillary first and second molars within 0.5mm, and c- the buccal cusps of the maxillary second molars within 1 mm of buccal displacement from the horizontal line joining the contralateral palatal cusps (Figure 2).

The inclusion criteria for the ectopic eruption group were: a- more than 2 mm of buccolingual displacement of maxillary second molars, b- more than 2 mm of marginal ridge discrepancy between the maxillary first and second molars, and c- the buccal cusps of the maxillary second molars buccally displaced by a value exceeding 2 mm from the horizontal line joining the contralateral palatal cusps (Figure 3).



**Figure (1):** ABO gauge: A) 1mm in width and measures discrepancies in alignment, overjet, interproximal contact, occlusal contact, occlusal relationships. B) Steps 1mm in heights and measures discrepancies in mandibular posterior teeth buccolingual inclination. C) Steps 1 mm in height and measures marginal ridge discrepancies. D) Steps 1mm in height and measures discrepancies in maxillary posterior teeth buccolingual inclination.



**Figure (2):** ABO gauge measuring molar discrepancy in the study model of normal eruption group



**Figure (3):** ABO gauge measuring molar discrepancy in the study model of ectopic eruption group

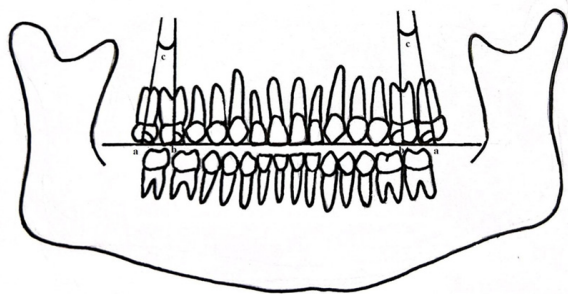
Only cases with mild to moderate irregularity of the maxillary anterior teeth were included in the study.

Exclusion criteria were: a- syndromic patients, b- systemic diseases, c- congenitally missing or impacted one or more permanent teeth in the maxillary arch or previous extractions, d- incomplete eruption of the maxillary second molars, e- abnormal crown morphology or prosthetic treatment of the second molars, f- previous orthodontic treatment, g- severe crowding, h- presence of interproximal tooth wear, i- gross caries involving the mesial and distal surfaces, j- supernumerary teeth or tooth anomalies, k- proclined maxillary incisors and l- incomplete or faulty records. Little irregularity index <sup>[31]</sup> was used to quantify the amount of maxillary crowding by viewing the

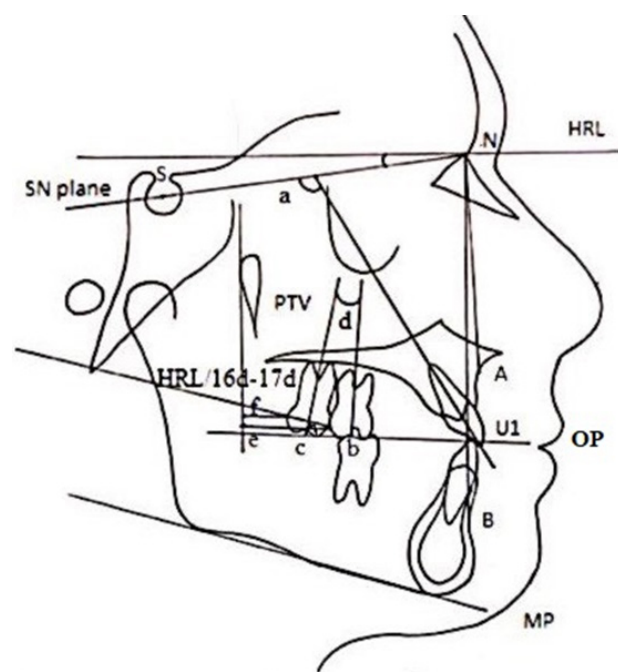
dental cast from above and holding an electronic digital caliper (Stainless hardened Sakara) parallel to the occlusal plane during obtaining each measurement. [31] Measurement of the mesiodistal diameter of the maxillary teeth was made directly on the study models by using a manual Boley gauge with fine tips (Dentaurum, Pforzheim, Germany) with accuracy to the nearest 0.1 mm. The tip was held perpendicular to the long axis of the tooth and the mesiodistal dimension was obtained by measuring the largest distance between the contact points of all maxillary teeth from the second molars to the central incisors. Maxillary arch length was documented by measuring the distance from the labial surface of the central incisors at the midline to the tangent of the mesial surface of the first permanent molar on the right and left side of the arch. The average value was then calculated. Maxillary intercanine and intermolar widths were also recorded.

Regarding panoramic radiograph, 6 measurements were recorded for every patient [30]. First the occlusal plane (OP) was drawn from the maxillary first molar on the right side to the first molar on the left side passing through the incisal edges of the maxillary central incisors. The angles formed by the long axes of the first and second molars to the OP bilaterally as well as the angle formed between the two molars on both the right and left sides were recorded (Figure 4). The long axis of the molars was formed by the line connecting the furcation and the midpoint of the crown.

Regarding the lateral cephalometric measurements, there were 10 angular and 2 linear measurements (Figure 5). The measuring points and reference lines were those defined by Steiner. [18,32] The horizontal reference line (HRL) was first identified as a line that is rotated from the Sella-Nasion line (SN) by 7 degrees in a clockwise direction at point N (Nasion). Sagittal jaw relationships were evaluated using angles SNA, SNB and ANB. Vertical jaw relationships were evaluated by measuring angles SN-Mandibular plane (SN-MP). Maxillary incisor inclination was evaluated by measuring the angle between SN plane and maxillary incisor (SN-Mx1).



**Figure (4):** Panoramic radiograph revealing the angulation of the long axis of the maxillary permanent first molar (b), permanent second molar (a) and intermolar angle (c)



**Figure (5):** Cephalometric landmarks, planes and measurements. Horizontal reference line (HRL); sella-nasion plane (SN plane); occlusal plane (OP); mandibular plane (MP); pterygoid vertical plane (PTV); line connecting distal contact points of maxillary first and second permanent molars (16d-17d); position of the maxilla relative to the anterior cranial base (SNA); position of the mandible relative to the anterior cranial base (SNB); position of the maxilla and mandible relative to one another (ANB); mandibular plane inclination to SN plane (MP/SN); maxillary incisor long axis inclination with the SN plane (SN-Mx1 or angle [a]); degree of distal inclination of maxillary second molar with horizontal reference line (HRL/16d-17d); angulation between long axis of first molar and occlusal plane (OP-16 or angle [b]); angulation between long axis of second molar and occlusal plane (OP-17 or angle [c]); angle between long axes of the first and second molars (Angle 16-17 or angle [d]); shortest distance between the line perpendicular to HRL at PTV and 16d (linear distance e) and 17d (linear distance f).

To evaluate maxillary molar inclination (16 and 17), the measurements used by Hwang et al [30] were applied. The angle between HRL and the line joining the most distal convex points (d) of the maxillary first molar (16) and second molar (17) was measured (HRL/16d-17d). The angles between the OP and the long axes of the molars (OP-16, OP-17) and the angle formed between the long axes of the molars (Angle 16-17) were recorded. The two linear measurements were the shortest horizontal distance from the line perpendicular to HRL at the pterygoid point to the most distal convex points of the maxillary molars, 16d and 17d (HRL/16d-17d).

All the lateral cephalograms from the patients' database were originally taken by the same machine with standardized criteria using Instrumentarium



Imaging Orthoceph OC100 type cephalostat with an anode-to-midsubject distance of 152.5 cm and a midsubject-to-film distance of 14.6 cm with a standard magnification of 8%. The lateral cephalograms were imported to (CephX imaging software, ORCA Dental AI, USA), whereby the anatomical landmarks and reference lines/planes were digitally specified and tracing was carried out utilizing this software. In a random sample of 20 patients, the measurements were recorded then repeated again after a two week interval to assess measurement reproducibility.

**Statistical analysis:**

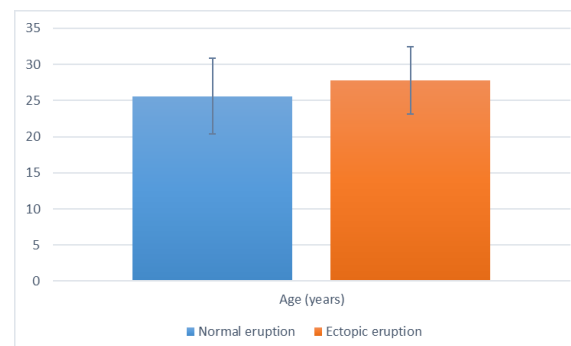
Numerical data was represented as mean and standard deviation (SD) values. Shapiro-Wilk's test was used to test for normality. Homogeneity of variances was tested using Levene's test. ANB data were non-parametric and were analyzed using Mann-Whitney U test. Other data were normally distributed, had homogenous variances across groups and were analyzed using independent t-test. The significance level was set at  $p < 0.05$  within all tests. Statistical analysis was performed with R statistical analysis software version 4.3.0 for Windows (R Core Team (2023), Foundation for Statistical Computing, Vienna, Austria.)

**RESULTS:**

The study was conducted on 40 cases (i.e. 20 cases per group), all were females. The mean age of the cases in the normal eruption group was  $(25.62 \pm 5.19)$  years and in the ectopic eruption group it was  $(27.78 \pm 4.65)$  and there was no significant difference between both groups ( $t=1.39$ ,  $p=0.174$ ). Mean and standard deviation values for age data are presented in Figure (6).

Results of intergroup comparisons and summary statistics for study model linear measurements are presented in Table (1) and in Figures (7) and (8). For teeth measurements, results showed widths of the right and left second premolars, first and second molars were significantly higher in the ectopic eruption group in comparison to normal eruption group ( $p < 0.05$ ). In addition, the maxillary arch length in the ectopic eruption group was also significantly higher ( $p < 0.001$ ). While for intermolar and intercanine widths, and other teeth measurements, the differences were not statistically significant ( $p > 0.05$ ). Results of intergroup comparisons and summary statistics for panoramic radiograph angular measurements are presented in Table (2) and in Figure (9). For OP/17 and OP/27, the normal eruption group had significantly higher values than the ectopic eruption group ( $p < 0.001$ ). While for intermolar Angle 16/17 and angle 26/27, the values measured in the ectopic eruption group were significantly higher ( $p < 0.001$ ). For other angles, the differences were not statistically significant ( $p > 0.05$ ). Results of intergroup comparisons and summary statistics for lateral cephalometric measurements are presented in Table (3) and in Figures (10) and (11). For SNA, PTV-16d, PTV-17d, OP-17, Angle 16-17 measurements; the

normal eruption group had significantly higher values the ectopic eruption group ( $p < 0.05$ ). However, for HRL/16d-17d angle, the ectopic eruption group had significantly higher value ( $p < 0.001$ ). For all other measurements, the differences were not statistically significant ( $p > 0.05$ ).



**Figure (6):** Bar chart showing mean and standard deviation (error bars) values for age (years)

**Table (1):** Intergroup comparisons of study model linear measurements

Measurement	(Mean±SD) (mm)		Test statistic	p-value
	Normal eruption	Ectopic eruption		
11	8.20±0.30	8.31±0.48	-0.90	0.374
12	7.14±0.38	7.34±0.46	-1.41	0.167
13	7.61±0.28	7.76±0.38	-1.38	0.175
14	7.10±0.26	7.26±0.42	-1.46	0.154
15	6.53±0.29	6.85±0.36	-3.10	0.004*
16	10.16±0.51	10.89±0.46	-4.68	<0.001*
17	9.97±0.39	10.31±0.39	-2.81	0.008*
21	8.24±0.29	8.35±0.46	-0.86	0.394
22	7.05±0.34	7.25±0.48	-1.52	0.137
23	7.64±0.29	7.77±0.41	-1.12	0.270
24	7.18±0.23	7.33±0.42	-1.40	0.169
25	6.61±0.27	6.85±0.40	-2.21	0.033*
26	10.46±0.41	10.91±0.46	-3.29	0.002*
27	9.96±0.31	10.26±0.41	-2.65	0.012*
Maxillary arch length	28.09±2.15	30.70±1.81	-4.17	<0.001*
Maxillary intermolar width	44.29±4.31	44.72±5.30	-0.28	0.782
Maxillary intercanine width	36.16±1.43	36.97±1.60	-1.69	0.100

\*significant ( $p < 0.05$ )

**Table (2):** Intergroup comparisons of panoramic radiograph angular measurements

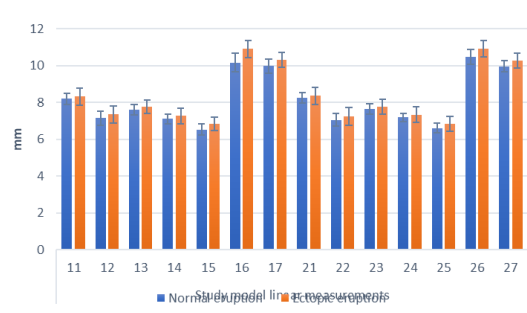
Angles	(Mean±SD) (°)		Test statistic	p-value
	Normal eruption	Ectopic eruption		
OP/16	89.73±2.33	90.82±1.97	-1.59	0.119
OP/17	82.00±2.75	74.44±4.78	6.13	<0.001*
OP/26	85.66±1.50	86.38±2.82	-1.01	0.317
OP/27	79.02±3.86	69.34±4.58	7.22	<0.001*
Angle 16/17	7.97±1.47	12.57±4.45	-4.39	<0.001*
Angle 26/27	6.47±1.50	14.05±4.35	-7.37	<0.001*

\*significant (p<0.05)

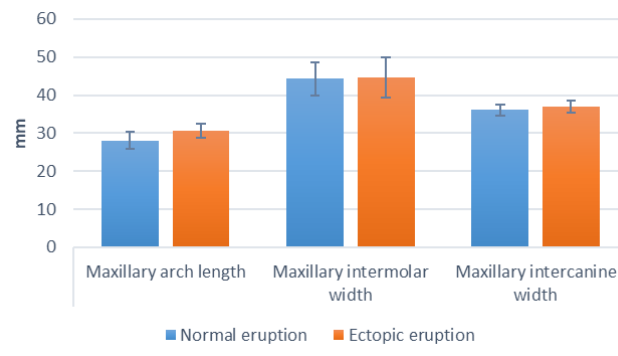
**Table (3):** Intergroup comparisons of lateral cephalometric measurements

Angles	(Mean±SD) (°)		Test statistic	p-value
	Normal eruption	Ectopic eruption		
SNA (°)	82.22±1.93	80.31±2.94	2.44	0.020*
SNB (°)	79.98±1.85	79.16±1.36	1.61	0.116
ANB (°)	2.24±2.33	1.15±2.90	236.50	0.330
SN-OP (°)	17.64±2.89	16.52±2.57	1.28	0.207
SN-MdP (°)	37.26±2.55	36.68±3.17	0.64	0.524
SN-Mx1 (°)	106.89±1.98	107.58±2.49	-0.97	0.338
HRL/16d-17d (°)	17.61±2.03	21.50±3.07	-4.71	<0.001*
PTV-16d (mm)	17.07±2.67	12.98±1.57	5.90	<0.001*
PTV-17d (mm)	8.21±1.61	5.52±1.50	5.48	<0.001*
OP-16 (°)	88.19±1.66	85.95±3.98	2.32	0.214
OP-17 (°)	84.07±2.07	78.75±4.05	5.22	<0.001*
Angle 16-17 (°)	6.34±1.32	7.47±2.75	-1.66	<0.001*

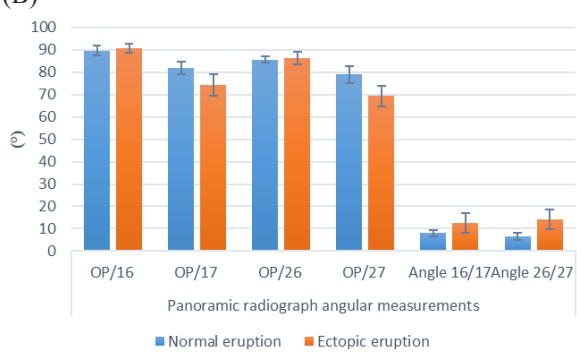
\*significant (p<0.05)



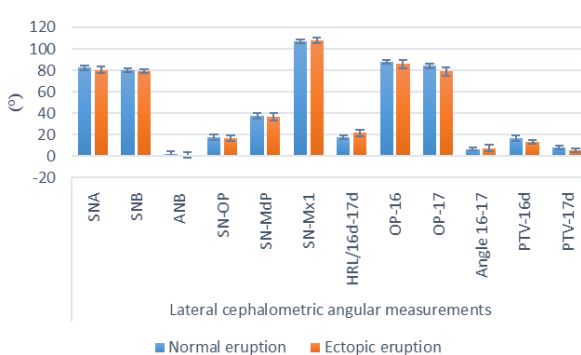
**Figure (7):** Bar chart showing mean and standard deviation (error bars) values for study model linear measurements (A)



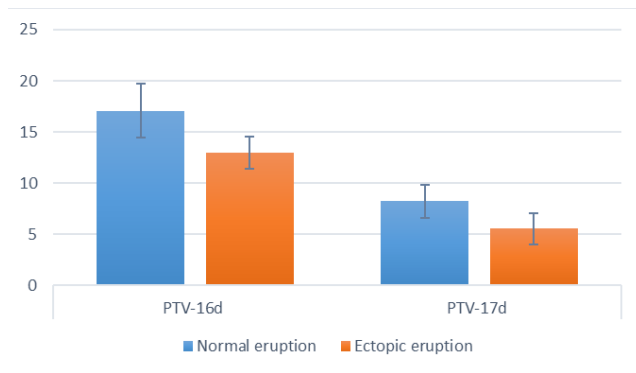
**Figure (8):** Bar chart showing mean and standard deviation (error bars) values for study model linear measurements (B)



**Figure (9):** Bar chart showing mean and standard deviation (error bars) values for panoramic radiograph angular measurements



**Figure (10):** Bar chart showing mean and standard deviation (error bars) values for lateral cephalometric angular measurements



**Figure (11):** Bar chart showing mean and standard deviation (error bars) values for lateral cephalometric linear measurements

## DISCUSSION:

The timing of second molar eruption is a clinically important factor possibly associated with different types of craniofacial skeletal morphology and malocclusion development. This event can be considered as a developmental landmark, in some cases important for the start of orthodontic treatment. It might also have bearing on the possible influence of extraoral force traction on the eruption of the maxillary second molars in the treatment of Class II patients.<sup>[33]</sup>

Ectopic eruption of permanent molars does not lead to marked aesthetic impairment similar to incisors or canines, however functional disorders may develop quite rapidly depending on the number of teeth affected.<sup>[7]</sup> Grover and Lorton<sup>[10]</sup> stated that the second molars (0.08% of the population for upper second molars and 0.06% for lower second molars) are the most frequently non erupted permanent molars excluding third molars. The posterior position of the maxillary permanent second molar makes it difficult for the patients to notice its ectopic eruption. However, the maxillary second molars play a very important role in mastication and their malposition can lead to balancing, working and protrusive occlusal interferences.

<sup>[34]</sup> The most frequent position for ectopic eruption is in the distobuccal direction that makes maintaining good oral hygiene strenuous. Cureton<sup>[35]</sup> evaluated the prevalence of malaligned second molars in subjects who have not been orthodontically treated. He observed that maxillary second molars erupted in a more buccal position than

did mandibular second molars. These malpositioned maxillary second molars were inclined with their roots to the mesial and their crowns to the distal. Hence, the etiology of ectopic eruption of maxillary permanent second molar should be taken into consideration during the diagnostic stage.<sup>[30]</sup>

In this study, the study model analysis revealed a statistically significant difference in the arch length measurement between the normal and the ectopic eruption group (28.09 mm  $\pm$ 2.15; 30.70 mm $\pm$ 1.81). This was due to wider mesiodistal dimension of the second premolars, first and second permanent molars in the ectopic eruption group. The mesiodistal dimensions of the maxillary incisors, canines and first premolars were also larger in the ectopic group though not statistically significant. This was in alignment with earlier studies that concluded that crowding of teeth takes place in patients with an enlarged mesiodistal teeth dimensions.<sup>[13,36,37]</sup> Similar results were also reported by Hwang et al<sup>30</sup> however they found no statistically significant difference between maxillary second molars mesiodistal dimensions in both groups. Furthermore the canines and first premolars were significantly larger in the ectopic eruption than in the normal eruption group. Although statistically insignificant, the central incisors and first molars were larger in width in the ectopic eruption group.

Growth of the maxilla posteriorly at the tuberosity region occurs by bone apposition at the rate of 1mm/year starting at the age of 10 until 18 years old. This results in an increase in the distance between PTV to maxillary first molar and provides adequate space for the eruption of the maxillary second and third molars.<sup>6</sup> Forward movement of the maxillary first molar also occurs by alveolar bone growth.<sup>[38]</sup> Downward and forward growth of the maxilla also creates room for the erupting molars. It has been postulated that increased periosteal bone apposition at the posterior edge of the maxillary tuberosity occurs in subjects with marked forward growth of the maxilla.<sup>[39,40]</sup> Lack of adequate bone growth at the maxillary tuberosity area is directly associated with ectopic eruption and buccal displacement of maxillary second and/or third molars.<sup>[6,16,41]</sup> In the study by Hwang et al<sup>30</sup>, there was an association between angle ANB and distances PTV-16d and PTV-17d whereby a small ANB angle was linked with a short linear distance from PTV to maxillary first and second molars. This is aligned with the results of the present study whereby the linear cephalometric measurements PTV-16d and PTV-17d were significantly smaller in the ectopic eruption group compared to the normal eruption group.

Angle SNA was significantly smaller in the ectopic eruption group compared to the normal eruption group. This indicates that the maxilla is relatively more posteriorly located in the ectopic eruption group. This is in agreement with previous studies that reported a retro-positioned maxilla relative to the cranial base in cases with ectopic maxillary second molar eruption.<sup>[13,30]</sup> Angle ANB was smaller in the ectopic eruption group but was not statistically significant.

It has been previously documented that first and second molars are crucial for normal dental development as well as coordination of the facial growth.<sup>[24]</sup>

In a study by Haruki et al [26] a strong relationship was found between second molar eruption and calcification rate as well as normal dentofacial growth (expressed by angle ANB and anteroposterior length of the maxilla) and occlusal relationship (Class II or Class III malocclusion).

Other researchers suggested that second molar development or eruption might be related to a specific pattern of jaw size or position. Suda et al [42] examined the relationship between the formation or eruption of the maxillary teeth and the skeletal pattern of the maxilla in a maxillary retrusion and a control group. They concluded no significant difference in the rate of formation of the maxillary and mandibular teeth between the two groups. However, the eruption of the maxillary second molars was delayed in the maxillary retrusion group. Another study [43] examined subjects with skeletal Class II prognathic maxilla and found a more forward position of the maxillary first molar. Moreover, Lo and Moyers [27] emphasized that the eruption of the maxillary second molar precedes that of mandibular molar in Class II malocclusion with forward positioned maxilla. In contrast to this, Demirjian et al [44] found that the association between the degree of skeletal maturity and dental development is low.

The mechanism of eruption of maxillary second molars starts with the roots directed in a palatal direction and the occlusal surface in a distobuccal direction. Normally, upon eruption, the maxillary second molars are brought to their final upright occlusal position with the opposing teeth through the cone-funnel mechanism.[45] In ectopic eruption, the maxillary second molar maintains a distobuccal inclination upon emergence and does not redirect its path in a mesiolingual direction during the final stages of eruption. This is confirmed by the increased inclination of the second molars relative to HRL (HRL/16d-17d) by about 4 degrees compared to the normal eruption group. Angles OP-17 and OP-27 were significantly smaller in the ectopic eruption group compared to the normal group. The intermolar angle (Angle 16-17) is statistically increased in the ectopic eruption group. This has also been confirmed in the panoramic radiograph whereby angles OP/17 and OP/27 were statistically smaller than the normal eruption group. The intermolar angles 16/17 and 26/27 were significantly larger in the ectopic eruption group. This result validates the increased distobuccal inclination of the maxillary second molar relative to the occlusal plane in the ectopic eruption group. This also goes in accordance with previous studies that suggested the maxillary molar inclination to the occlusal plane as an important etiologic factor in diagnosing ectopic eruption.[13,16,30]

#### CONCLUSIONS:

- Larger mesiodistal widths of maxillary second premolars, first and second permanent molars were detected in the ectopic eruption group.

dimensions of the teeth from central incisors to first premolars were also larger in the ectopic eruption group though not statistically significant.

- Larger arch length was present in the ectopic eruption group.
- The maxilla was in a retrusive position and the area of the maxillary tuberosity was shorter in the ectopic eruption group compared with the normal group.
- Ectopically erupted maxillary second molars displayed a more significant distal inclination compared to the normally erupted second molars.
- These factors could be used to predict ectopic eruption of maxillary permanent second molars.

#### CONFLICT OF INTEREST

This clinical study was self-funded by the authors, with no conflict of interest.

#### REFERENCES

- 1- Ten Cate AR. Oral Histology, Development, Structure, and Function. 3rd ed. St Louis, MO: CV Mosby; 1989:275 – 298.
- 2- Björk A, Skieller V. Facial development and tooth eruption. Am J Orthod. 1972;62:339–383.
- 3- Bondemark L, Tsiopa J. Prevalence of ectopic eruption, impaction, retention and agenesis of the permanent second molar. Angle Orthod. 2007;77:773–778.
- 4- Chattopadhyay A, Srinivas K. Transposition of teeth and genetic etiology. Angle Orthod. 1996;66:147–152.
- 5- Gatzalas P, Droschl H, Muchitsch AP, Fluch O, Bantleon HP. 3-dimensional location of the upper 2nd molars after the termination of orthodontic treatment. Z Stomatol. 1987;84:241–250.
- 6- Yoon YJ, Jang SH, Hwang GW, Kim KW. Stress distribution produced by correction of the maxillary second molar in buccal crossbite. Angle Orthod. 2002 Oct;72(5):397-401.
- 7- Proff P, Bayerlein T, Fanghanel J, Allegrini S Jr, Ge drange T. Morphological and clinical considerations of first and second permanent molar eruption disorders. Ann Anat. 2006;188:353–361.
- 8- Gorlin RJ, Pindborg JJ, Cohen MM. Syndromes of head and neck. 2nd ed. New York, NY: McGraw-Hill; 1976:180–184.
- 9- Jensen BL, Kreiborg S. Development of the dentition in cleidocranial dysplasia. J Oral Pathol Med. 1990;19:89–93

- 10- Grover PS, Lorton L. The incidence of unerupted permanent teeth and related clinical cases. *Oral Surg Oral Med Oral Pathol.* 1985;59:420–425.
- 11- Raghoebar GM, Boering G, Vissink A, Stegenga B. Eruption disturbances of permanent molars: a review. *J Oral Pathol Med.* 1991;20:159–166.
- 12- Vedtofte H, Andreasen JO, Kjaer I. Arrested eruption of the permanent lower second molar. *Eur J Orthod.* 1999;21:31–40.
- 13- Pulver F. The etiology and prevalence of ectopic eruption of the maxillary first permanent molar. *ASDC J Dent Child.* 1968;35:138–146.
- 14- Varpio M, Wellfelt B. Disturbed eruption of the lower second molar: clinical appearance, prevalence, and etiology. *ASDC J Dent Child.* 1988;55:114–118.
- 15- Bjerklin K, Kurol J. Ectopic eruption of the maxillary first permanent molar: etiologic factors. *Am J Orthod.* 1983;84:147–155.
- 16- Cheyne VD, Wessels KE. Impaction of permanent first molar with resorption and space loss in region of deciduous second molar. *J Am Dent Assoc.* 1947;35:774–787.
- 17- Magnusson C, Kjellberg H. Impaction and retention of second molars: diagnosis, treatment and outcome. A retrospective follow-up study. *Angle Orthod.* 2009;79:422–427.
- 18- Proffit WR. *Contemporary Orthodontics.* 3rd Edition 1999. C.V. Mosby, 012000. 6.4.2.2.2.
- 19- Levine TP, Matthews GJ, Salama LA, Yee A. Antero-posterior skeletofacial classification and its relationship to maxillary second molar buccopalatal angulation. *Angle Orthod.* 2020 Nov 1;90(6):851–856.
- 20- Smith R. The effects of extracting upper second permanent molars on lower second permanent molar position. *Br J Orthod.* 1996; 23 (2): 109–114.
- 21- Keim RG. Don't forget the second molars. *J Clin Orthod.* 2007; 41 (5): 243–244.
- 22- Proffit WR, Fields HWJ. *Contemporary Orthodontics.* St Louis, MO: Mosby; 1999.
- 23- Sultana MH, Yamada K, Hanada K. Changes in occlusal force and occlusal contact area after active orthodontic treatment: a pilot study using pressure-sensitive sheets. *J Oral Rehabil.* 2002;29:484–491.
- 24- Proffit WR. Equilibrium theory revisited: factors influencing position of the teeth. *Angle Orthod.* 1978;48:175–186.
- 25- Alexander RG. The vari-simplex discipline. Part 1. Concept and appliance design. *J Clin Orthod.* 1983;17:380–392.
- 26- Haruki T, Kanomi R, Shimono T. The differences in the chronology and calcification of second molars between Angle Class III and Class II occlusions in Japanese children. *J Dent Child.* 1997; 64: 400404-.
- 27- Lo RT, Moyers RE. Studies in the etiology and prevention of malocclusion. I. The sequence of eruption of the permanent dentition. *Am J Orthod* 1953;39:4607-.
- 28- Duncan WK, Ashrafi MH. Ectopic eruption of the mandibular first permanent molar. *J Am Dent Assoc.* 1981;102:651–654.
- 29- Groper JN. Ectopic eruption of a mandibular first permanent molar: report of an unusual case. *ASDC J Dent Child.* 1992;59:228–230.
- 30- Hwang S, Choi YJ, Lee JY, Chung C, Kim KH. Ectopic eruption of the maxillary second molar: Predictive factors. *Angle Orthod.* 2017 Jul;87(4):583589-.
- 31- Little RM. The irregularity index: a quantitative score of mandibular anterior alignment. *Am J Orthod.* 1975;68:554–563.
- 32- McNamara JA. A method of cephalometric evaluation. *Am J Orthod Dentofacial Orthop.* 1984;86(6): 449469-.
- 33- Brin I, Camasuvi S, Dali N, Aizenbud D. Comparison of second molar eruption patterns in patients with skeletal Class II and skeletal Class I malocclusions. *Am J Orthod Dentofacial Orthop.* 2006 Dec;130(6):74651-.
- 34- Broadbent JM. Chewing and occlusal function. *Funct Orthod.* 2000;17:34–39.
- 35- Cureton, S.L. Second molar biomechanics. *J Clin Orthod* 1995. 29:500508-.
- 36- Herman E. The malposed first permanent molar. *N Y State Dent J.* 1969;35:343–350.
- 37- Doris JM, Bernard BW, Kuftinec MM, Stom D. A biometric study of tooth size and dental crowding. *Am J Orthod.* 1981;79:326–336.
- 38- Jedlickova O. [Diagnostic method for assessment of possible distalization of the first upper molars]. *Prakt Zubn Lek.* 1990;38:245–249.
-



39- Bjork A. Sutural growth of the upper face studied by the implant method. *Acta Odontol. Scand.* 1966;24:109–127. 24.

40- Bjork A, Skieller V. Growth of the maxilla in three dimensions as revealed radiographically by the implant method. *Br J Orthod.* 1977;4:53–64.

41- Barberia-Leache E, Suarez-Clua MC, Saavedra-Ontiveros D. Ectopic eruption of the maxillary first permanent molar: characteristics and occurrence in growing children. *Angle Orthod.* 2005;75:610–615.

42- Suda N, Hiyama S, Kuroda T. Relationship between formation/eruption of maxillary teeth and skeletal pattern of maxilla. *Am J Orthod Dentofacial Orthop.* 2002;121: 46-52.

43- Andria LM, Reagin KB, Leiter LP, King LB. Statistical evaluation of possible factors affecting the sagittal position of the first permanent molar in the maxilla. *Angle Orthod* 2004;74:220-5.

44- Demirjian A, Buschang PH, Tanguay R, Patterson DK. Interrelationships among measures of somatic, skeletal, dental, and sexual maturity. *Am J Orthod* 1985;88:433-8.

45- Van der Linden FP. Changes in the position of posterior teeth in relation to ruga points. *Am J Orthod.* 1978;74:142–161.