

Pentacam topographic changes after Epithelium-off collagen cross-linking versus Epithelium-on collagen cross-linking in patients with keratoconus

Asmaa Elasmay, Prof.Dr.GamalAbdellatif, Prof.Dr.MohamedElagouz ,and Prof.Dr.Hatem Ammar.

Ophthalmology Department , Faculty of Medicine , Sohag University

Introduction:

Keratoconus is a bilateral non-inflammatory disease .One of its characteristics is reduction of biomechanical strength of cornea and stromal thinning , which gradually decreases corneal thickness and induces irregular astigmatism , myopia , corneal scarring, and reduction of visual acuity.⁽¹⁾For early stages of keratoconus , one would use spectacles and contact lenses though the progression of the disease can lead to irregular astigmatism or corneal scarring, leaving no other option but corneal transplantation in about 20% of patients.⁽²⁾Corneal transplantation is an expensive procedure with many complications such as high astigmatism and graft rejection; hence, seeking for a way to halt this progressive disease seems to be of crucial importance.⁽³⁾

For more than a decade, corneal cross-linking (CXL) has been considered as the only method for improving corneal biomechanical power.⁽⁴⁾Corneal collagen cross-linking (CXL) is a low-invasive treatment aimed to improve biomechanical stability in eyes with keratectasia.⁽⁵⁾

The “standard CXL protocol” described by Wollensak and colleagues includes removal of the corneal epithelium in a diameter of 9 mm , followed by saturation of the corneal stroma using 0.1% isotonic riboflavin solution in 20% dextran.⁽⁶⁾This procedure is proved to be

effective in increasing corneal stiffness , stabilization of keratoconus , and in some cases in improving the refractive and topographic features.Even so, the epithelial removal may lead to serious complications that include infection⁽⁷⁾,stromal haze ⁽⁸⁾, and corneal melting ⁽⁹⁾in addition to severe pain and decrease in vision occurring during the first days after the treatment.To avoid such complications, Boxer Wachler et al. suggested a modification of the technique by keeping the epithelium intact (epithelium-on or transepithelial CXL) ⁽¹⁰⁾.In this study, we sought to compare keratoconus indices before and after crosslinking either epi-off or epi-on CXL by Pentacam criteria.

Features of Pentacam

The Pentacam shares many of the capabilities of the Orbscan and measures basic corneal features such as elevation, thickness and curvature. The Pentacam also displays them in the same color-coded fashion; green, yellow, and light blue for near normal values, and red and purple for caution, and the most common display is a 4-map display .⁽¹¹⁾[Figure 1] presents the Refractive 4-map display, where clockwise from the top left, the sagittal power, anterior (front) elevation, posterior (back) elevation, and pachymetry maps are included. The top left data box contains patient and exam data. Boxes underneath display quantitative data regarding the anterior

and posterior corneal surfaces: Simulated keratometry readings (k1, k2) and radii of curvature (Rh, Rv), mean keratometry (Rm) and radius of curvature in the 3.0 mm zone (Km), the quality specification of the examination (QS), the axis of the flat meridian and amount of astigmatism (Astig), the mean eccentricity value in 30 degrees (ecc), the mean radius of curvature of the 7.0-9.0 mm ring area (Rper), and the minimum radius of curvature (Rmin).⁽¹¹⁾

Pachymetry data of the pupil center, apex, thinnest point, and their locations are followed by maximum curvature amount and location. Bottom boxes display the values of the corneal volume, keratometric power difference (KPD), chamber volume, the smaller angle size in the horizontal meridian, anterior chamber depth, and pupil diameter. The intraocular pressure (IOP) box is provided to compute the corrected IOP. Lens thickness (final box) contains a

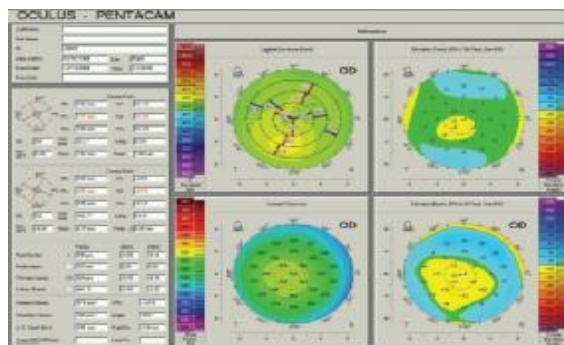


Figure (1): A Pentacam refractive 4-map of normal right eye. The four maps, clockwise, from the top left include the sagittal power, anterior (front) elevation, posterior (back) elevation, and pachymetry .⁽¹¹⁾

Patients and methods:

This study was performed in Sohag ophthalmology department in Sohag university hospital in collaboration with Sohag Future Femto-Laser center.

Type of the Study: This is a non-randomized comparative retrospective clinical study done in the period from June 2015 to December 2016.

Patients: Fifty eyes were divided into two groups:

The first group was the epithelium-off CXL group that included 28 eyes, whereas

The second group was the epithelium-on CXL group (TE-CXL group) that included 22 eyes

Inclusion criteria:

- Age range from 12 to 45 years ,
- Confirmed keratoconus, Central corneal thickness at least 400 μm, Clear cornea.

Exclusion criteria: Eyes with the following conditions were excluded from the study

- Corneal opacity, Any previous surgery on eyes as rings,
- Previous ophthalmic herpes infection, Past history of uveitis,
- Diabetes mellitus, Pregnancy,
- Collagen vascular diseases, Severe dry eye.

Methods of the study : The procedure was first explained to subjects eligible for inclusion and the consent form was signed. Preoperatively, all patients were subjected to:

- 1- A detailed ocular and medical history.
- 2- Complete ophthalmic examination including:-
 - a. Uncorrected visual acuity (UCVA).
 - b. Manifest refraction.
 - c. Best spectacle-corrected visual acuity (BSCVA).
 - d. Slit lamp examination to exclude corneal opacity or inflammation.
 - e. Fundus examination to report any posterior segment abnormalities.
 - f. Simulated keratometry, corneal topography, and pachymetry (Sirius, CSO, Firenze, Italy).

Operative procedures:

Epithelium-off collagen cross-linking procedure:

Topical anesthesia was given as benoxinate hydrochloride (one drop every 5 min half an hour before surgery). Skin disinfection was performed by povidone iodine 10%.

The device used was AVEDRO (KXL system , UnitedStates). The epithelium was removed with a blunt-tipped spatula. Sodium hyaluronate (Provisc; Alcon, Fort Worth, Texas, USA) was applied on the limbus all around to keep riboflavin on the cornea. The room lights were turned off in order not to affect the composition and efficacy of riboflavin. The riboflavin was instilled every 3 min for 30 min . Corneal irradiation with UVA was performed for 30 min while dropping of the riboflavin every 3 min. Irrigation of the eye by saline was performed. A bandage soft contact lens was applied onto the cornea. At the end of surgery, eye drops were applied including topical antibiotic, topical steroid , and cyclopentolate followed by eye patching. Postoperative treatment usually lasted for 2–4 weeks and included the following: Antibiotic eye drop, Steroid eye drops, Tears substitutes , Systemic vitamin A and

vitamin C twice daily and Systemic analgesic and anti-inflammatory. The patient was followed up daily in the first week until re-epithelization of the cornea took place. Thereafter, the patient was followed up at 1, 3, 6, and 12 months postoperatively. The patient was instructed to wear sunglasses for 2 weeks.

Epithelium-on collagen cross-linking procedure:

The preoperative preparation was the same as in conventional CXL. The same device used in conventional CXL was used in TE-CXL, The first step in this procedure was application of the silicon ring onto the cornea . Transepithelial riboflavin phosphate 0.127 g (Ricola TE; Sooft) was instilled every 2 min for 30 min until the anterior corneal stroma was saturated by riboflavin. Corneal irradiation was performed with the use of UVA source for 30 min while riboflavin was still instilled every 2 min. Irrigation of the eye was performed to wash the remnants of riboflavin. At the end of surgery, eye drops were applied including topical antibiotic, topical steroid, and cyclopentolate. The patient was instructed to wear sunglasses for 2 weeks. Postoperative treatment usually lasted from 1 to 2 weeks and included topical antibiotic, topical steroid, systemic vitamin A and C, tears substitutes and systemic analgesic and anti-inflammatory. The patient was followed up daily in the first week. During this follow-up, the patient was examined by the slit lamp to detect corneal haziness. Thereafter, the patient was followed up at 1, 3, 6, and 12 months postoperatively. All eyes were subjected to the preoperative and postoperative measures including UCVA and BCVA, pachymetry, simulated keratometry, and corneal topography .

The preoperative and postoperative data and 12 months in all eyes.
were analyzed at baseline and at 3, 6,

Results

This study included 50 eyes in two groups , Group 1= 28 eyes for epi-off and Group 2 =22 eyes for epi-on , from both sexes who were asked to be followed up for one year.

Age: Group 1: Patients have age Mean±SD:21.82± 3.221 and Group 2: Patients have age Mean±SD:21.86± 3.182.

Sex: Group 1: Number of male patients were 17 eyes(60.7%) while female patients represented 11 eyes(39.3%) and Group 2: Number of male patients were 10 eyes(45.5%) while female patients represented 12 eyes(54.5%).

Visual outcome

1-Uncorrected visual acuity (UCVA) :

In Group 1(epi-off) : Mean preoperative UCVA 0.180 ± 0.038 ,at 1year the mean changed to 0.225 ± 0.048 .

In Group 2 (epi-on) : Mean preoperative UCVA 0.186 ± 0.035 ,at 1year the mean changed to 0.161 ± 0.030 .

2- Best corrected visual acuity (BCVA) :

In Group 1(epi-off):Mean preoperative BCVA 0.643 ± 0.107 ,at 1year the mean changed to 0.732 ± 0.101 .

In Group 2 (epi-on) : Mean preoperative BCVA 0.348 ± 0.213 ,at 1year the mean changed to 0.542 ± 0.193 .

Corneal Topographic Indices

1-K1 :

In Group 1(epi-off): Mean preoperative K1 47.199 ± 1.663 , at 1year the mean changed to 45.224 ± 1.125 .

In Group 2 (epi-on): Mean preoperative K1 47.054 ± 1.068 , at 1year the mean changed to 46.171 ± 1.099 .

2-K2 :

In Group 1(epi-off) : Mean preoperative K2 50.275 ± 2.025 ,at 1year the mean changed to 48.153 ± 1.422 .

In Group 2 (epi-on) : Mean preoperative K2 49.846 ± 1.493 ,at 1year the mean changed to 49.390 ± 1.406 .

3-Average (Sim)K :

In Group 1(epi-off) : Mean preoperative Avg.K 48.737 ± 1.768 ,at 1year the mean changed to 46.688 ± 1.193 .

In Group 2 (epi-on) : Mean preoperative Avg.K 48.450 ± 0.617 ,at 1year the mean changed to 47.780 ± 0.595 .

4-Average Astigmatism :

In Group 1(epi-off) : Mean preoperative Avg. Astig. 3.013 ± 1.364 , at 1year the mean changed to 2.137 ± 1.070 .

In Group 2 (epi-on) : Mean preoperative Avg. Astig. 2.939 ± 1.140 , at 1year the mean changed to 2.779 ± 1.145 .

5-Central Corneal Thickness (CCT) :

In Group 1(epi-off) : Mean preoperative CCT 466.714 ± 43.392 ,at 1year the mean changed to 430.000 ± 47.755 .

In Group 2 (epi-on) : Mean preoperative CCT 438.500 ± 31.444 ,at 1year the mean changed to 428.773 ± 33.527 .

Conclusion

This study has proved that epithelium-on CXL is superior to epithelium-off CXL regarding pain, complications, and early patient convalescence. However, epithelium-off CXL is superior to epithelium-on CXL regarding the efficacy in visual stabilization and improvement. In short, this study concluded that conventional epithelium-off CXL is better than epithelium-on CXL.

References

- 1- Rabinowitz YS. Keratoconus. Surv Ophthalmol 1998;42: 297-319.
- 2- Krachmer JH, Feder RS, Belin MW. Keratoconus and related non inflammatory corneal thinning disorders. Surv Ophthalmol 1984; 28:293- 322.
- 3- Kennedy RH, Bourne WM, Dyer JA. A 48-year clinical and epidemiologic study of keratoconus. Am J Ophthalmol 1986; 101:267-73 .
- 4- Keratoconus: Overview and update on treatment. Middle East African J Ophthalmol 2010; 17(1): 15-20.
- 5- Edwards M, McGhee CN, Dean S: The genetics of keratoconus . Clin Exp Ophthalmol 2001; 29:345-51.
- 6- Wachtmeister L, Ingemansson SO, Moller E. Atopy and HLA antigens in patients with keratoconus. Acta Ophthalmol (Copenh) 1982; 60:113-22.
- 7- Adachi W, Mitsuishi Y, Terai K, et al. The association of HLA with young-onset keratoconus in Japan. Am J Ophthalmol 2002; 133:557- 9 .
- 8- Wang Y, Rabinowitz YS, Rotter JI, Yang H; Genetic epidemiological study of keratoconus: evidence for major gene determination. Am J Med Genet 2000;93:403-9.
- 9- Ihalainen A. Clinical and epidemiological features of keratoconus. Genetic and external factors in the pathogenesis of the disease. Acta Ophthalmol (Copenh) 1986; 64(Suppl.): 178.
- 10- Rahi A, Davies P, Ruben M, et al. Keratoconus and coexisting atopic disease. Br J Ophthalmol 1977;61:761-4.
- 11- Hashemi H, Mehravaran S . Day to day clinically relevant corneal elevation, thickness, and curvature parameters using the orbscan II scanning slit topographer and the pentacam scheimpflug imaging device. Middle East Aff J Ophthalmol. 2010; 17:44-55.
- 12- Barkana Y, Gerber Y, Elbaz U, et al. Central corneal thickness measurement with the pentacam Scheimpflug system, optical low-coherence reflectometry pachymeter and ultrasound. J Cataract Refract Surg. 2005; 31(9): 1729-35.
- 13- Belin M., Ambrósio R., Khachikian S., Salomão M. Keratoconus / Ectasia Detection with the Oculus Pentacam: Belin / Ambrosio Enhanced Ectasia Display. J Highlights of Ophthalmology, 2009; 35 : 5-12.
- 14- Holladay JT, Hill WE, Steinmueller A. Corneal power measurements using scheimpflug imaging in eyes with prior corneal refractive surgery. J Refract Surg. 2009; 25:862-8.
- 15- Dumitrica DM and Colin J. Indices for the detection of keratoconus. Ophthalmologia. 2010; 54(2): 19-29.
- 16- Holladay J., Belin M., Dick B., Ambrosio R.. Why Cataract And Refractive Surgeons Need The Pentacam, J Cataract & Refract Surg. 2006; p 1-12.
- 17- Ambrósio R., Simonato R., Jardim D., Fontes B., Fontes P. Corneal Biomechanics, Pachymetric Progression, and Corneal Volume: Novel Indices for Detecting Ectasia and Screening Refractive Patients. SAN FRANCISCO, ASCRS, 2006; p 1-29.

