

Fallopian Tube Recanalization for the Management of Infertility: Review article

Mohammed Mouselhy Farrag, Khaled Ahmed Atwa, Waleed Fouad Gharib,

Mohammed El-prince Adel, Mohammed Ahmed Sayed Abd El-Sattar*

Obstetrics and Gynecology, Faculty of Medicine, Suez Canal University

Corresponding author: Mohammed Ahmed Sayed Abd El-Sattar, Email: ptrservices2022@gmail.com, Mobile: +201013736393

ABSTRACT

Infertility is an issue that affects people all over the world. It is defined as the inability to conceive a child following a period of a year of consistent, unprotected sexual activity. Infertility can have a variety of causes, some of which are linked to male issues while others are related to female factors. One of the most prevalent causes of infertility in women is a blockage of the fallopian tubes. Infertility was initially treated with fluoroscopic fallopian tube recanalization in 1985. Over a hundred studies have been published since then detailing different techniques for recanalizing blocked fallopian tubes. Methods of fallopian tube recanalization for the treatment of infertility were the focus of this research. In conclusion, recanalization of the fallopian tubes is an outpatient operation characterized by a low risk of complications and a short recovery time. For women with a blocked fallopian tube at its proximal end, this treatment option should be their first choice.

Keywords: Selective salpingography, Fallopian tube occlusion, Recanalization, Infertility

INTRODUCTION

Inability to become pregnant in women can have several reasons, but the most common is a problem with the ovaries and fallopian tubes, which accounts for 25 to 35 percent of all cases of ovulatory infertility in women around the world. Approximately 10 to 20 percent of all cases of tubal factor infertility are attributable to proximal tubal blockage ⁽¹⁾.

Previous pelvic inflammatory disease, pelvic surgery, or endometriosis, can lead to proximal obstruction or injury of the fallopian tubes, both of which are considered forms of fallopian tube disease. Surgical tubal repair, watchful waiting and in vitro fertilization-embryo transfer (IVF-ET) are all viable treatment options. However, it is vital to determine the origin of the tubal illness because in vitro fertilization-embryo transfer may not be required in all cases of infertility ⁽²⁾.

Tubal reconstructive operation is an option for couples hoping to lessen their reliance on IVF-ET since it allows women with normal tubal mucosa to conceive without the assistance of artificial reproductive technologies ⁽³⁾.

A meta-analysis determined that hysterosalpingography (HSG), a test used to determine whether or not the fallopian tubes are patent, has a specificity of eighty-three percent but a sensitivity of just sixty-five percent, hence laparoscopy is now the preferred method for diagnosing tubal blockage ⁽⁴⁾.

Catheters, flexible atraumatic guide wires, or balloon systems may be employed to re-open blocked fallopian tubes using endoscopic (fallopscopy/hysteroscopy/laparoscopy), fluoroscopic, sonographic, or tactile guiding. The ability to objectively define the source of proximal tubal obstruction and provide a correct visual assessment of endotubal illness is made possible through fallopscopy. Accurate diagnosis of tubal blockage, peritubal adhesion, and endometriosis requires laparoscopy. Hysteroscopic tubal catheterization (HTC)

is used for recanalization if laparoscopic chromopertubation reveals tubal blockage ⁽⁵⁾.

The purpose of this research was to assess the efficacy of fallopian tube recanalization procedures for treating infertility.

Structure and Function

The fallopian tubes are two tubes in a woman's pelvis that connect her ovaries to her uterus on both sides. They play a key role in the transfer of oocytes as well as the subsequent fertilization process. As a result of their importance, the fallopian tubes are frequently the target of surgical sterilization procedures and are also a prevalent cause of infertility. They may also serve as origins for tumors or ascending infections. The fallopian tubes are hollow seromuscular organs that originate at the uterine horns, extend laterally within the superior edge of the mesosalpinx of the wide ligament, and terminate near the ipsilateral ovary. Other names for fallopian tubes are oviducts along with uterine tubes. They range in length from eleven to twelve centimeters and have a lumen diameter of fewer than one millimeter ⁽⁶⁾.

Fallopian Tube Obstruction: Diagnosis and Treatment:

The fallopian tubes are an essential part of the process by which sperm and eggs become attached to one another, yet it is impossible to conceive naturally without them functioning normally. One of the most significant factors contributing to a woman's inability to conceive a child is a condition known as obstruction of the fallopian tubes. Patients in this situation have a strong desire to have their clogged fallopian tubes unblocked and their reproductive capabilities fully restored ⁽⁷⁾. Inflammation is the leading cause of fallopian tube obstruction. Fallopian tube obstruction is a growing problem, as are cases of reproductive system infection and the "items" that spread them. Hydrosalpinx along with blocked fallopian tubes are

responsible for thirty to forty percent of all cases of infertility in ladies⁽⁸⁾. Infections can be caused by anything from common bacteria to more exotic pathogens like Chlamydia trachomatis, Ureaplasma urealyticum, Mycoplasma hominis, or a protozoon. Therefore, it is essential for the treatment of infertility to involve correct diagnosis and the best possible therapy. Hysterosalpingo-contrast sonography, hysterosalpingography, and the gynecological endoscope have all become standard methods of diagnosis in recent years⁽⁹⁾.

Among the several treatment options, laparoscope hysteroscope, and interventional therapy are the most common. Traditional Chinese medicine and psychological intervention therapy provide 2 other treatment options⁽¹⁰⁾.

This report summarized the methods used to identify and treat infertility arising from blocked fallopian tubes, highlighting the benefits and drawbacks of each method along with its clinical utility.

Hysterosalpingography (HSG):

In HSG, iodinated oil, a high specific gravity substance, is injected into the uterine cavity via the cervix to create artificial contrast across the lumen as well as the surrounding tissues on X-ray, allowing the doctor to assess the health of the uterus as well as fallopian tube (Figure 1). As demonstrated in the following picture, it can also disclose the shape of the uterus in addition to providing information regarding the presence and the position of a blockage in the fallopian tubes. Evaluating the uterus and fallopian tubes in this manner is common because it is painless along with requiring no anesthetic to determine if they are smooth⁽¹¹⁾.

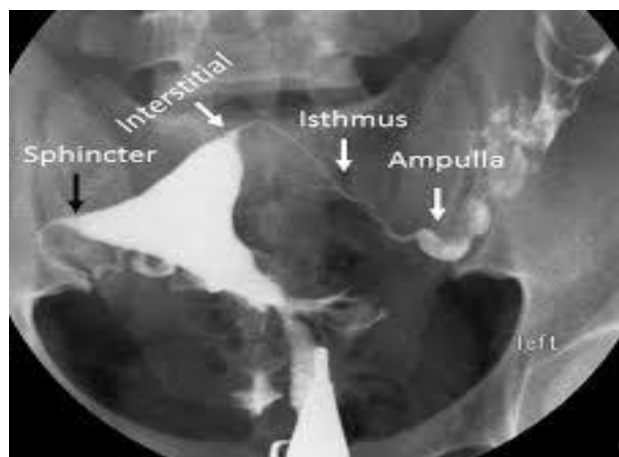


Figure (1): HSG X-ray film showing uterus and both tubes⁽¹³⁾

Hysterosalpingography has been compared to diagnostic laparoscopy in a few trials for its efficacy in making a diagnosis. HSG was found to be helpful due to its low cost, low complication rate and little invasiveness in the initial investigation of a possible fallopian tube obstruction. On the other hand, it has limited diagnostic utility in addition to cannot reliably

detect problems such pelvic inflammation as well endometriosis⁽¹²⁾.

Hysterosalpingo-contrast sonography (HyCoSy)

To create ultrasonic pictures of the dilated uterine chamber and fallopian tubes, Hysterosalpingo-contrast sonography injects a contrast material into the lumen. Its primary applications are in the diagnosis of uterine cavity disorders and the assessment of fallopian tube smoothness⁽¹³⁾.

When first attempting to employ the HyCoSy for the diagnosis of gynecological disorders, researchers both at home as well as abroad mostly focused on two-dimensional ultrasonic scanning. Ultrasonography has advanced from traditional B-type grayscale imaging to color Doppler blood flow imaging, energy diagrams along with additional techniques for imaging. Additionally, the contrast agent has progressed from saline to hydrogen peroxide and 1st- and 2nd-generation ultrasonic contrast agents⁽¹⁴⁾.

Two-dimensional ultrasound contrast has several drawbacks, including its inability to show the entire curved fallopian tube in various planes, its inability to recognize the contrast agent from the echo of the intestinal canal, its inability to obtain a coronal section of the uterus, as well as the insufficient data it provides about uterine disorders⁽¹⁴⁾.

It's important to remember that 3D images are constructed from 2D ones, thus the quality of the latter might have a direct bearing on the efficacy of the former. The limited field of view of a 3D transvaginal ultrasound makes it inappropriate for women who are just eight to ten weeks along in their pregnancies. In addition, if the adnexal mass is particularly sizable or structurally complex, it may obscure the results of tubal reconstruction from view. In particular, disorders of the tubal mucosa as well as pelvic adhesion are difficult for 3D HyCoSy to show⁽¹⁵⁾.

Gynecological endoscopy

Laparoscopy is the gold standard for diagnosing tubal infertility because of its high level of specificity and sensitivity as well as its ability to evaluate the abdominal cavity in addition to other pelvic structures⁽¹⁶⁾.

Under laparoscopy, **Liu et al.**⁽¹⁷⁾ performed hydrotubation and HSG on 120 cases of tubal infertility. The outcomes demonstrated that the sensitivity and specificity of HSG in diagnosing tubal obstruction were 84.62 as well as 69 percent, respectively, while those of laparoscopy were 94.8 as well as 82 percent, respectively. It suggested that laparoscopy was superior for diagnosing this obstruction. However, laparoscopy was an invasive, expensive procedure for individuals.

Hysteroscopy:

Hysteroscopy's principal benefit is that it allows doctors to see into the uterus, where they may make a

more informed diagnosis of any underlying disorders along with frequently find the organic causes of infertility or repeated abortions ⁽¹⁸⁾.

Hysteroscopy, according to **Molinas and Campo** ⁽¹⁹⁾, can become the major method for diagnosing infertility due to blocked fallopian tubes since it provides a direct view of the uterine cavity. Hysteroscopy and laparoscopy are two separate diagnostic procedures, although some research has shown that they can be performed together for a more precise diagnosis ⁽²⁰⁾.

Chlamydia testing using serology:

Tubal mucositis and peri-salpingitis are the most common causes of tubal infertility and other physiological functioning problems of the fallopian

tubes after the onset of any type of pelvic infection. Recent research has linked the sexually transmitted infection Chlamydia trachomatis (CT) to tubal infertility ⁽²¹⁾.

Therapies

Transcervical tubal cannulation and selective salpingography (Figure 2): Under fluoroscopic ⁽¹⁷⁾, falloposcopic ⁽³⁾, sonographic ⁽²²⁾ or hysteroscopic guidance, transcervical tubal cannulation for the reversal of proximal tubal occlusion can be carried out. This procedure is performed in order to reverse proximal tubal occlusion. The inspissated material can be directly mechanically disrupted by threading an atraumatic guidewire through the catheter (also known as tubal cannulation) ⁽²³⁾.

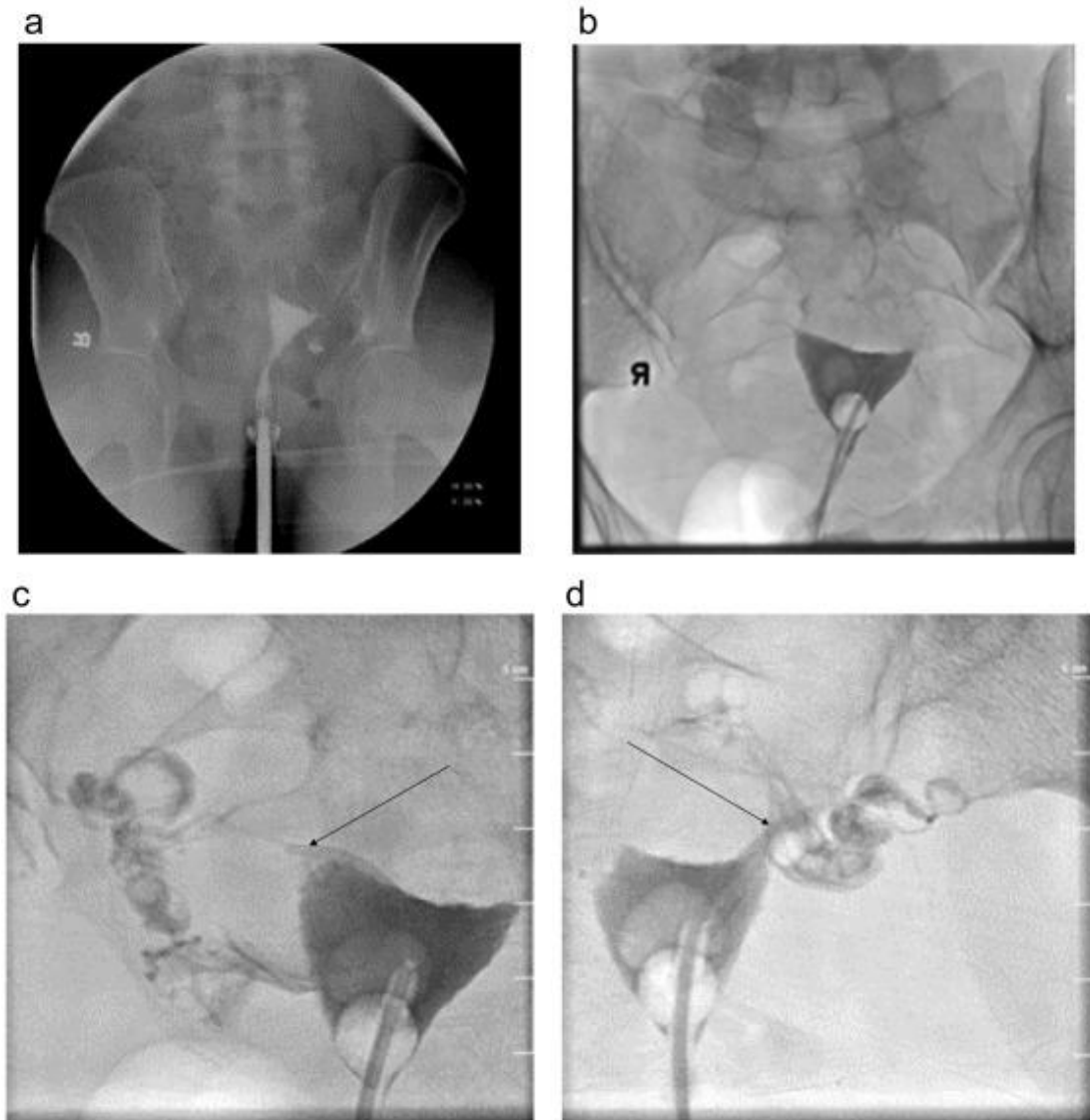

Figure (2): Cannulation of the tubal cervix transcervically in addition to selective salpingography⁽¹⁷⁾.

Tubo-cornual anastomosis

Macro-surgical tubal re-anastomosis for proximal tubal occlusion entails removing the tubal isthmus, axially incising the remnant tube along its anti-mesenteric boundary, and re-implanting it into a new uterotomy located posterior to the cornu ⁽²⁴⁾.

Hysteroscopic transcervical tubal cannulation stands out from the crowd, with an average continuing pregnancy rate of forty-nine percent hysteroscopic transcervical tubal cannulation with selective salpingography may be as efficient as microsurgical tubal ligation in some individuals, notably those without concomitant tubal disease, but less invasive as well as less expensive ⁽²⁵⁾.

Tubal recanalization under assistance of endoscopy

Tubal obstruction therapy under assistance of hysteroscopy-laparoscopy:

Hysteroscopy-laparoscopy provides a direct visual of the uterus and fallopian tubes to diagnose disease along with plan subsequent treatment. Pelvic adhesiolysis, oophorectomy, hysterectomy, polycystic ovary drilling, reductive surgery for intrapelvic abnormalities, tubal fimbrioplasty, and neostomy are all examples of gynecological procedures ⁽⁴¹⁾.

For intermediate also proximal obstruction, hysteroscopy allows for proximal intubation, pressurization, as well as hydrotubation; for intrauterine adhesion, a needle electrode separation; along with for uterine malformation, a loop electro-surgical excisional technique, bipolar vaporization, or scissor cutting ⁽²⁵⁾.

Tube recanalization under assistance of hysteroscopy (Figure 3):

One hour before undergoing an operation, the person is orally administered misoprostol. The uterus is dilated, hysteroscopy is introduced into the uterus and fallopian tube to reach the interstitial area and the ostium is adjusted after standard sterilization along with anesthesia. The catheter is infused with a solution of normal saline, gentamicin, dexamethasone, plus methylene blue.

The recanalization liquid return is a major focus ⁽²⁶⁾.

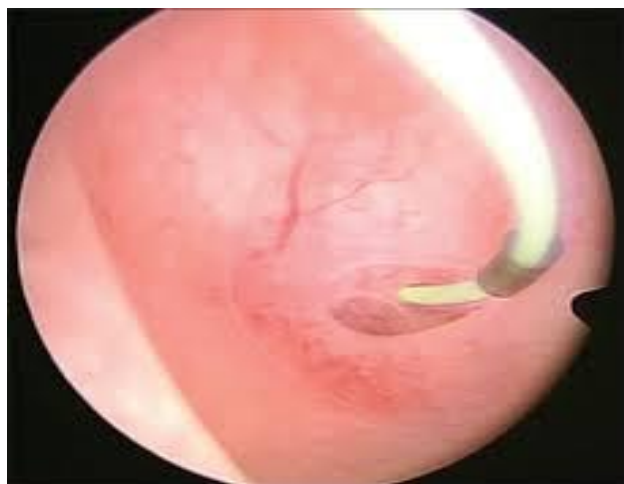

Figure (3): Tubal cannulation guided by hysteroscopy ⁽²⁶⁾.

Tube recanalization under assistance of laparoscopy

(Figure 4): Before surgery, most people are fine with a standard vulvar cleaning. An intratracheal inhalation technique should be used for the anesthetic, after an aseptic cloth has been spread. The individual is placed in the lithotomy position, then a cut is made just below the belly button to provide access for the laparoscope. In addition, a 5-millimeter incision is made in front of the crista iliaca ⁽⁴¹⁾.

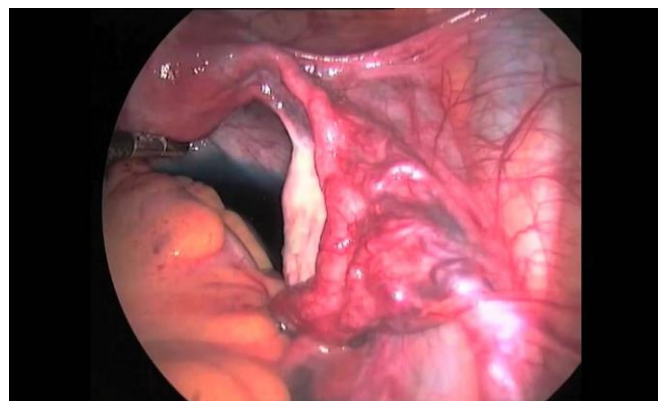


Figure (4): Laparoscopic guided tubal cannulation ^(27, 28).

Sixty-three individuals had laparoscopic recanalization of their blocked fallopian tubes as part of a research. The softness rate of the participants was increased to 49.2 percent after treatment, with no adverse effects or complications. The outlook seemed encouraging. As laparoscopic treatment for tubal infertility has been demonstrated to have a positive clinical outcome with minimal intraoperative difficulties, it may be useful in clinical practice ⁽²⁷⁾.

The tube recanalization under combined hysteroscopy with laparoscopy:

Eighty individuals with tubal infertility were randomly assigned to one of 2 trial groups. About fifty percent of patients in both groups had secondary causes of infertility. Hysteroscopy only and hysteroscopy combined with laparoscopy were both approved for use in recanalizing fallopian tubes in two separate groups. The data displayed that the recanalization rate of success in the hysteroscopy group was 55%, which was significantly reduced than the recanalization effectiveness rate in the hysteroscopy-laparoscopy group, which was 85%. The recanalization rate was 85.71% amongst 21 persons with secondary infertility who received hysteroscopy in conjunction with laparoscopy, compared to 27.78% among 19 people with initial infertility who performed hysteroscopy alone ⁽²⁸⁾.

Wire-guided tube recanalization under combination of hysteroscopy with laparoscopy:

Under general anesthesia, the patient is placed in a lithotomy position, as well as tracheal tube is inserted. To check for adhesion or deformation of the fallopian tubes and to determine the size and location of the pelvic cavity,

uterus, along with ovaries, laparoscopy requires drilling into the body. Appropriate surgical treatments are carried out, such as the separation of the pelvic adhesion (if present) as well as the restoration of the normal forms of the organs inside the pelvic cavity⁽¹¹⁾.

Hysteroscopy is used to check the uterine cavity's size, shape, along with the endometrium's color and thickness. Under hysteroscopy, an oviduct catheter is inserted through the ostium of the fallopian tubes, as well as an indicator solution of methylene blue additionally with normal saline is introduced through the catheter to provide details about the obstruction of the fallopian tubes in addition its precise location while laparoscopy monitors the procedure. There is tubal obstruction if there is significant resistance or an expanded portion of the fallopian tube⁽²⁹⁾.

The data show that tubal intubation can dramatically increase the pregnancy rate, along with that individuals with unilateral tubal blockage are most likely to conceive if the procedure has been carried out successfully⁽²⁹⁾. This suggests that hysteroscopy intubation under laparoscopic guidance is an option for female with proximal tubal blockage instead of assisted reproductive technologies⁽¹¹⁾.

Interventional treatment

By integrating radiological and imaging technology to perform intervention, minimally invasive interventional treatment can be used to treat fallopian tube occlusion. Selective salpingography is used for diagnosis, while tube recanalization along with drug perfusion inside the fallopian tube lumen are used for treatment⁽³⁰⁾.

While conventional per-X ray salpingography can identify areas of adhesion and blockage, it cannot alleviate the symptoms caused by them. When compared to recanalization, which uses the dilation of the guide wire to remove the adhesion within the fallopian tubes in addition to restores unrestricted fallopian tubes through the pushing static force of the liquid, selective salpingography improves the static pressure of liquid throughout the fallopian tubes as well as overcomes pain resulting from excessive expansion of the uterine cavity in addition pseudo-positive factors of sphincter spasm⁽³⁰⁾.

Assisted treatment with traditional Chinese medicine (TCM):

While improving uterine pregnancy rates, hysteroscopic laparoscopic treatment of tubal obstruction is prone to recurrence of adhesion and obstruction following the procedure⁽¹¹⁾.

Some trials indicate that using traditional Chinese medicine before, during, or after a tube recanalization procedure can increase the success rate of the procedure, decrease the re-obstruction rate, enhance the intrapelvic environment, consolidate the operating effect, as well as boost the pregnant rate. According to TCM, the main causes of infertility due to tubal

obstruction include damp toxin accumulation, Qi-stagnation, blood stasis and blocked veins⁽²⁷⁾.

According to traditional Chinese medicine, the goal of treating tubal blockage is to stimulate blood flow, disperse stagnation and dredge collaterals⁽¹¹⁾.

The intrauterine pregnancy rate can be increased with the use of traditional Chinese medicine after a hysteroscopic laparoscopic combination procedure as well as that assisted TCM therapy following tube recanalization has a particular reference value for treatment⁽²⁷⁾.

CONCLUSIONS

Proximal tubal occlusion, the leading cause of infertility in the Western world, has been successfully treated in recent years. An efficient and minimally invasive method of treating proximal occlusions is fluoroscopic guiding for selective salpingography and recanalization. It dispenses with invasive techniques like laparoscopic guiding or hysteroscopic guidance that need dilatation of the cervical canal and general anesthesia. The patient only needs to go through one operation instead of two because the diagnostic HSG can also perform selective salpingography and recanalization. The therapeutic procedure of selective salpingography combined with tubal recanalization also has diagnostic applications. Fallopian tube recanalization (FTR) may not always be successful, but it can still provide important diagnostic information that can guide subsequent infertility treatment.

DECLARATIONS

- **Consent for publication:** I attest that all authors have agreed to submit the work.
- **Availability of data and material:** Available
- **Funding:** No fund
- **Conflicts of interest:** No conflicts of interest.

REFERENCES

1. **Zafarani F, Ghaffari F, Ahmadi F et al. (2021):** Hysterosalpingography in the Assessment of Proximal Tubal Pathology: A Review of Congenital and Acquired Abnormalities. *The British Journal of Radiology*, **94**(1122): 20201386.
2. **Chua S, Akande V, Mol B (2017):** Surgery for Tubal Infertility. *Cochrane Database of Systematic Reviews*, 2017(1): CD006415.
3. **Kong G, Li T (2015):** Surgical Management of Tubal Disease and Infertility. *Obstetrics, Gynaecology and Reproductive Medicine*, **25**(1): 6-11.
4. **Gharekhanloo F, Rastegar F (2017):** Comparison of Hysterosalpingography and Laparoscopy in Evaluation of Female Infertility. *European society of medicine*, **5**:6.
5. **Antaratani R, Harsha B (2017):** Hysterolaparoscopy in the Evaluation and Management of Female Infertility. *International Journal of Reproduction, Contraception, Obstetrics and Gynecology*, **6**(10): 4454-4457.
6. **Howard C, Rice P, Keenan M et al. (2022):** Study of Fallopian Tube Anatomy and Mechanical Properties to

- Determine Pressure Limits for Endoscopic Exploration. *Journal of Histotechnology*, **45**(1): 10-20.
7. **Revzin M, Moshiri M, Katz D et al. (2020):** Imaging Evaluation of Fallopian Tubes and Related Disease: A Primer for Radiologists. *Radiographics*, **40**(5): 1473-1501.
 8. **Ambildhuke K, Pajai S, Chimegave A et al. (2022):** A Review of Tubal Factors Affecting Fertility and Its Management. *Cureus*, **14**(11): e30990.
 9. **Giakoumelou S, Wheelhouse N, Cuschieri K et al. (2016):** The Role of Infection in Miscarriage. *Human Reproduction Update*, **22**(1): 116-133.
 10. **De Silva P, Chu J, Gallos I et al. (2017):** Fallopian Tube Catheterization in the Treatment of Proximal Tubal Obstruction: A Systematic Review and Meta-Analysis. *Human Reproduction*, **32**(4): 836-852.
 11. **Liu X, Cui H, Chen W et al. (2017):** Diagnosis and Treatment of Fallopian Tube Obstruction: A Literature Review. *International Journal of Clinical Experimental Medicine*, **10**(12): 15950-15959.
 12. **Ngowa J, Kasia J, Georges N et al. (2015):** Comparison of Hysterosalpingograms with Laparoscopy in the Diagnostic of Tubal Factor of Female Infertility at the Yaoundé General Hospital, Cameroon. *Pan African Medical Journal*, **22**(1): 264-271.
 13. **Lo Monte G, Capobianco G, Piva I et al. (2015):** Hysterosalpingo Contrast Sonography (HyCoSy): Let's Make the Point! *Archives of Gynecology and Obstetrics*, **291**(1): 19-30.
 14. **Alcázar J, Martínez A, Duarte M et al. (2022):** Two-Dimensional Hysterosalpingo-Contrast-Sonography Compared to Three/Four-Dimensional Hysterosalpingo-Contrast-Sonography for the Assessment of Tubal Occlusion in Women with Infertility/Subfertility: A Systematic Review with Meta-Analysis. *Human Fertility*, **25**(1): 43-55.
 15. **Volondat M, Fontas E, Delotte J et al. (2019):** Magnetic Resonance Hysterosalpingography in Diagnostic Work-up of Female Infertility Comparison with Conventional Hysterosalpingography: A Randomised Study. *European Radiology*, **29**(2): 501-508.
 16. **Shanmugham D, Vidhyalakshmi R, Varghese J (2018):** Evaluation of Tubal Patency in Infertile Patients with Saline Infusion Sonosalpingogram. *International Journal of Reproduction, Contraception, Obstetrics and Gynecology*, **7**(7): 2590-2595.
 17. **Liu X, Akhavan S, Stadtmuer L (2022):** Proximal Tubal Obstruction. Reproductive Surgery: Current Techniques to Optimize Fertility. Lindheim and Petrozza. Cham, Springer International Publishing, 83-89.
 18. **Xia E, Yu D (2022):** Diagnostic Hysteroscopy. Practical Manual of Hysteroscopy. Xia. Singapore, Springer Nature Singapore, 73-181.
 19. **Molinas C, Campo R (2006):** Office Hysteroscopy and Adenomyosis. *Best practice and research Clinical obstetrics and gynaecology*, **20**(4): 557-567.
 20. **Shen J, Kang Q, Mao Y et al. (2020):** Urinary Bisphenol a Concentration Is Correlated with Poorer Oocyte Retrieval and Embryo Implantation Outcomes in Patients with Tubal Factor Infertility Undergoing in Vitro Fertilisation. *Ecotoxicology and environmental safety*, **187**: Article ID 109816(8).
 21. **Surana A, Rastogi V, Nirwan P (2012):** Association of the Serum Anti-Chlamydial Antibodies with Tubal Infertility. *Journal of Clinical and Diagnostic Research*, **6**(10): 1692-1694.
 22. **Gebeh A, Metwally M (2019):** Surgical Management of Tubal Disease and Infertility. *Obstetrics, Gynaecology and Reproductive Medicine*, **29**(5): 123-128.
 23. **Ikechebelu J, Eleje G (2022):** Laparoscopy-Guided Hysteroscopic Proximal Tubal Cannulation (Endoscopic Tubal Cannulation). Gynaecological Endoscopic Surgery: Basic Concepts. Okohue, Ikechebelu, Ola, Kalu and Ibeanu. Cham, Springer International Publishing, 185-189.
 24. **Adewole A, Asaolu O, Akintobi A (2022):** Laparoscopic Tubal Surgery and Laparoscopic Management of Ectopic Pregnancy. Gynaecological Endoscopic Surgery: Basic Concepts. Okohue, Ikechebelu, Ola, Kalu and Ibeanu. Cham, Springer International Publishing, 159-184.
 25. **Siddiqui M, Ghafoor N, Abdullah R et al. (2021):** Laparoscopy Guided Hysteroscopic Tubal Cannulation: A Study on Fertility Outcome. *Bangladesh Journal of Fertility and Sterility*, **1**(1): 18-22.
 26. **Lin J, Xu H, Chen B et al. (2020):** Expanding the Genetic and Phenotypic Spectrum of Female Infertility Caused by Tle6 Mutations. *Journal of assisted reproduction and genetics*, **37**(2): 437-442.
 27. **Wen H, Fu J, Tang H et al. (2015):** Hydrotubation Combined with Chinese Herbal Medicine for Salpingitic Infecundity: A Systematic Review and Meta-Analysis. *Cell biochemistry and biophysics*, **71**(2): 519-527.
 28. **Bing P, Wang Q (2015):** Study on the Clinical Efficacy of Hysteroscopy Combined with Laparoscopy in Treating Fallopian Tubal Obstruction. *Chinese Journal of Primary Medicine and Pharmacy*, (15): 2321-2323.
 29. **Tanaka A, Tanaka I, Yamaguchi T et al. (2017):** Development of a New Tubal Recanalization Method Using the Combination of Hysteroscope and Laparoscope in the Treatment of Obstructed Fallopian Tubes. *Gynecology and Minimally Invasive Therapy*, **6**(4): 226-227.
 30. **Sun N, Wei L, Chen D et al. (2017):** Clinical Observation of Fallopian Tube Obstruction Recanalization by Ozone. *Pakistan Journal of Medical Sciences*, **33**(2): 290-294.