

Atrophic Acne Scar Fractional CO₂ Laser Treatment; Comparative Whole versus Focal Area Study

Mahmoud Abdelrahim AbdAllah, Salwa Gamal Hussain Gomah, Christine Kamal Thabet Gobrial*

Department of Dermatology and Venereology, Faculty of Medicine, Ain Shams University, Egypt

*Corresponding author: Christine Kamal Thabet Gobrial, Mobile: (+20) 01226312561, E-mail: christinekamal81@yahoo.com

ABSTRACT

Background: Acne patients are always concerned with scars and may suffer from depression and suicidal thoughts and even attempts. The commonest type is atrophic scars that could be ice pick and rolling or boxcar scars. Many therapeutic modalities are used for amelioration of the post acne scars.

Objectives: This study aimed to compare between whole facial-area versus Focal Acne Scar Treatment (FAST) treatment techniques of atrophic post-acne scars using fractional carbon dioxide light amplification by stimulated emission of radiation (CO₂ LASER)

Patients and Methods: This split face comparative study was held in Dermatology and Venereology Department, Ain Shams University. It included twenty atrophic, post-acne vulgaris adult scar patients. Each patient received one fractional CO₂ LASER resurfacing session; the right side of the face was treated by the whole area, while the left by the FAST technique. Before and after results evaluation was done by 16 mega pixel Samsung UK S6 edge and Antera 3D digital cameras' photographs, patients' satisfaction and physician blinded scoring.

Results: Antera texture (roughness) mode showed statistically highly significant improvement in acne scars using both whole and focal fractional CO₂ laser treatment, but no statistically significant difference could be detected between both modalities. Patients' and researchers' assessments of post-treatment results showed statistically non-significant differences in both modalities.

Conclusion: Treatment of post-acne atrophic scars with fractional CO₂ laser showed statistically highly significant improvement by both techniques and both were equally preferable.

Keywords: Focal acne scar treatment, Atrophic post-acne scars, Fractional CO₂ laser.

INTRODUCTION

Scarring is a major concern of acne patient. It may exacerbate depression and even leads to suicidal thoughts. Facial appearance interferes with human relationships and employment ⁽¹⁾. Acne scars are classed as atrophic, hypertrophic, or keloidal. Atrophic acne is the commonest type (ice pick and rolling or boxcar scars ^(2,3).

There are several treatment options for scars, such as chemical peeling and dermabrasion, which are facial resurfacing techniques of damaged layers to accelerate the normal exfoliation and re-epithelialization process ^(4, 5), punch techniques, transforming larger, deeper scars into smaller, linear closure ⁽⁶⁾, fat transplantation and tissue augmentation technique using soft tissue fillers in order to treat atrophic acne scars ^(5,7).

For the treatment of acne scars, laser therapy is a reliable and simple option ⁽⁸⁾. It may be ablative or non-ablative as well as fractionated or non-fractionated. Non fractionated lasers act on the whole treated skin surface area, whereas fractionated lasers produce microscopic thermal skin wounds, split by non-involved tissue islands from which tissue healing begins ⁽⁹⁾.

A randomized blinded, split face comparison of non-ablative fractionated laser (NAFL) (1550 nm erbium) to ablative fractionated laser (AFL) (10600 nm carbon dioxide demonstrated equal or greater improvement in scarring, with AFL than NAFL ⁽¹⁰⁾. Due to their effectiveness, safety, and short recovery periods, AFL carbon dioxide (CO₂) lasers have

replaced other methods of treating acne scars as the gold standard. Resurfacing often involves treating the entire face, including both skin with and without scars ⁽¹¹⁾. FAST is a useful technique for enhancing the look of atrophic acne scars. Less negative effects and quicker recovery might be achieved even with higher energy and density levels ⁽¹¹⁾.

We aimed at comparing the results of atrophic acne scar treatment, using, whole facial (scarred and non-scarred areas) versus FAST by fractional CO₂ laser in a split face study.

PATIENTS AND METHODS

This study was issued in the Department of Dermatology and Venereology, Al-Demerdash Hospital, Ain Shams University, from January 2018 till December 2019. We included atrophic scarring acne vulgaris patients; rolling, boxcar and ice pick scars, if not dominant, according to scar morphological classification ⁽³⁾, with various severities: mild, moderate and severe according to qualitative global scarring grading system ⁽¹²⁾. Males and females in the age group from 18 to 44 years, Fitzpatrick skin types III and IV.

Excluded criteria:

Patients with active acne, dominant ice pick scars, having a history of using isotretinoin, deep chemical peel, filler injection or any invasive ablative procedures in the previous 6 months and those suffering from active herpes simplex (HSV), herpes zoster or any other infection in the treated area or

bleeding tendencies and those taking anticoagulant therapy. We also avoided the patients who had been tanned one month before the study, or having a history of photosensitivity disorder as well as patients with systemic diseases that affect acne severity like polycystic ovary disease (PCOD) or taking any hormones or systemic steroids. Other types of acne rather than acne vulgaris are excluded as well.

Inquiries concerning the start, course, and length of acne, previous treatments for acne scars, and side effects of such treatments like hyperpigmentation or keloid development were all part of our thorough past and present histories. General and local dermatologic examination was done for each patient.

Twenty atrophic acne scar patients shared in this study, 11 males and 9 females. They were managed by two techniques; the right side of the face was treated by the whole area technique including the scared and non-scared areas. While, the left side of the face was treated by the FAST technique focally on the acne scars leaving the normal skin untreated. We used BISON Firexel, CO₂ laser, wave length 10600 nm (South Korea) single treatment session on each side of the face⁽¹³⁾.

The parameters set were scanner mode, pulse width 986 ms, repeat delay single, density 0.8 mm, energy 66.3 mj/cm², and microbeam size 300 um. Local anesthetic cream was applied before laser session to the whole face and covered with cellophane tape for approximately 45-60 minutes. In our pilot study, the aim was to determine the maximum effective pulse overlaps, which will cause no post-inflammatory hyperpigmentation (PIH). PIH was noticed at lower pulse overlaps of fractional CO₂ laser in the right side (whole area technique) in comparison with left side (FAST), which means, higher treatment levels can be used over focally treated area when healthy skin is left intact. According to that, we used 3 pulse overlaps for the right, wholly treated side and 6 overlaps for the left, focally treated, side.

We used patient's photographs before and three months after CO₂ LASER session, 16 mega pixel Samsung UK S6 edge digital camera. For objective assessment of the acne scars, Antera 3D digital camera, Miravex Limited Ireland 2014⁽¹⁴⁾ and texture (roughness) mode was used. Patients' visual analogue scale (VAS) was used to evaluate their satisfaction as well as quartile grading scale (QGS) that was used by the researcher and 3 dermatologists blindly to assess post treatment changes⁽¹⁵⁾.

Ethical approval:

This study was approved by Ethics Committee, Faculty of Medicine, Ain Shams University. All research participants were fully informed about the treatment technique, potential adverse effects, and picture recording. They all supplied written consent. The Helsinki Declaration was followed throughout the study's conduct.

Statistical Analysis

Using IBM SPSS Version 20, the obtained data was updated, coded, tabulated, and presented to a computer. Data were given, and the type of data gathered for each parameter was appropriately analysed. For parametric numerical data, the mean±standard deviation, and range, the frequency and percentage to determine the statistical significance of the difference between the means of two parametric study groups, use the Student T test. To determine the statistical significance of the variation of a non-parametric variable between two research groups, use the Mann-Whitney Test (U test). Correlation coefficient, represented symbolically by "r," measures the strength and direction of the linear relationship between two variables to determine the degree of linkage between two quantitative variables. The statistical significance of the difference between two means evaluated twice for the same research group using a paired t-test. The statistical significance of the difference between an ordinal variable (score) assessed twice for the same research group was evaluated using the Wilcoxon signed rank test. P value<0.05 was regarded as significant.

RESULTS

Twenty atrophic post acne scar patients shared in this study, 11 males and 9 females. Their ages ranged from 18 to 44 years old, with the mean age of 24.8 ± 6.44 years, fourteen (70.0%) were non-smokers while 6 patients (30%) were smokers, 5 patients were Fitzpatrick skin type III (25%) and 15 (75%) were type IV. Patients' past history of acne duration ranged from 1 to 30 years, with 7 patients had no previous acne treatment, 10 patients were treated with systemic antibiotic and topical medications and only 3 patients were treated with Isotretinoin. Their scars' past history duration ranged from 1 to 25 years, 18 patients had no previous scars treatment and only 2 patients tried to treat their scars. Morphological scar ratio among patients was macular 25.0%, ice pick 90.0%, rolling 90.0%, boxcar 85.0%. Scar severity among cases using qualitative scarring global grading system were 35.0 % mild, 50.0% moderate and 15.0% severe.

Antera camera photo-analysis showed statistically highly significant improvement of acne scars in both sides (left & right) after fractional CO₂ laser treatment (P-value 0.000) (Table 1 and Figures 1-8). Antera assessment of scar texture, before treatment, showed non-statistically significant difference between both facial sides, making them comparatively matching (P-value >0.05). Non-statistically significant difference was found, between right and left sides, as regards, acne scars texture improvement after fractional CO₂ treatment measured by the Antera camera (P-value 0.109) (Table 2).

Table (1): Comparative assessment of scars improvement in both face sides using the texture (roughness) mode of Antera camera before and after treatment.

Antera		Before treatment	After treatment	Test value•	P-value	Sig.
		No. = 20	No. = 20			
Right (whole area technique)	Mean±SD	28.542 ± 10.678	25.367 ± 10.012	6.257	0.000	HS
	Range	13.261 – 54.729	9.496 – 44.629			
Left (FAST)	Mean±SD	29.175 ± 9.182	24.649 ± 8.736	7.013	0.000	HS
	Range	14.184 – 42.409	P.687 – 37.848			

•: Paired t- test P-value 0.05: Non-significant; P-value <0.05: Significant (S); P-value< 0.01: highly significant (HS)

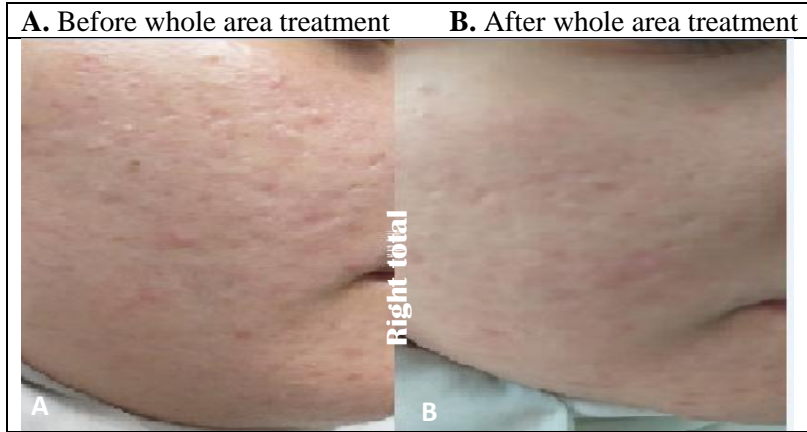
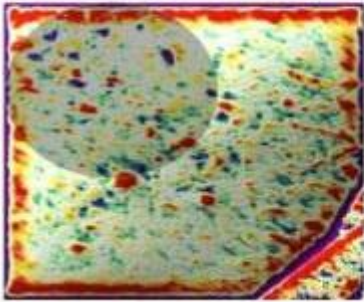


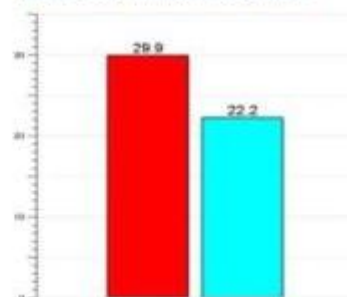
Figure (1): Right side of 18 years old female, patient (1), with mixed types of atrophic pot-scars of moderate severity before and after whole area fractional CO₂ laser treatment, using 16 mega pixel Samsung UK S6 edge digital camera.

Antera 3D Report

Texture: Medium (0.1 - 2 mm)



Roughness under 2.0 mm of lateral size



Right Antera before whole area treatment

Right Antera after whole area treatment

Figure (2): Right Antera texture before and after whole area fractional CO₂ treatment for patient in figure (1). Right texture measures before whole area treatment was 29.9 and after treatment was 22.2.

A. Before focal area treatment

B. After focal area treatment

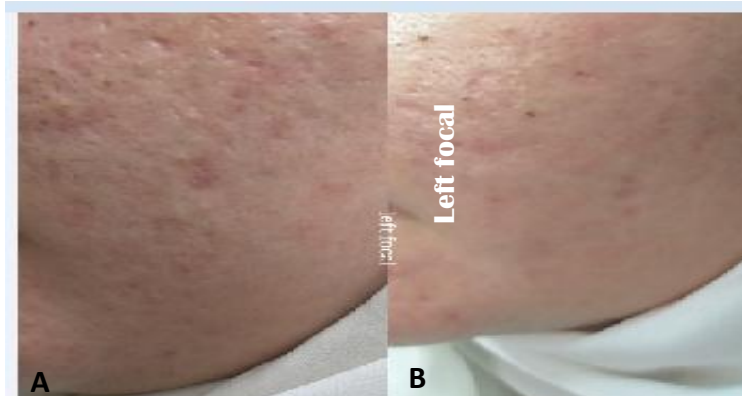



Figure (3): Left side of the same patient (1) before and after focal area fractional CO₂ laser treatment (FAST), using 16 mega pixel Samsung UK S6 edge digital camera.

Antera 3D Report

Texture: Medium (0.1 - 2 mm)



Left Antera before FAST



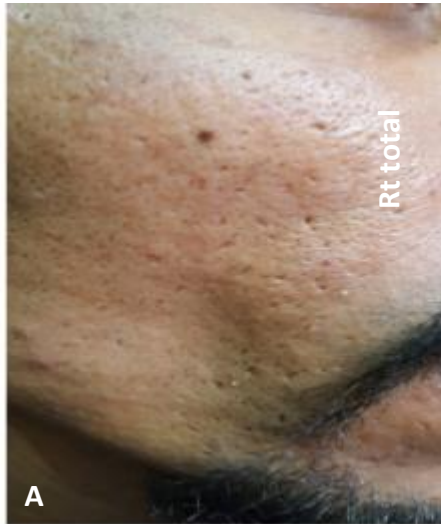Left Antera after FAST

Roughness under 2.0 mm of lateral size




Figure (4): Left Antera texture before and after focal area fractional CO₂ treatment for patient (1) at figure (3). Left (focal area technique) texture measures before treatment was 22.9 and after treatment was 21.66.

A. Before whole area treatment




B. After whole area treatment

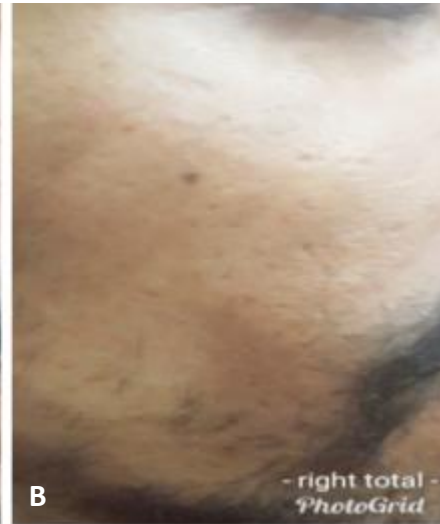


Figure (5): Right side of 35 years old male patient (Patient 2), with mixed types of atrophic post-acne scar of mild severity before and after whole area fractional CO₂ treatment, using 16 mega pixel Samsung UK S6 edge digital camera.

Antera 3D Report



Right Antera before focal area treatment



Right Antera after focal area treatment




Figure (6): Right Antera texture before and after whole area fractional CO₂ treatment for patient (2) at figure (5). Right (whole area technique) texture measures before treatment was 22.6 and after treatment was 20.8.

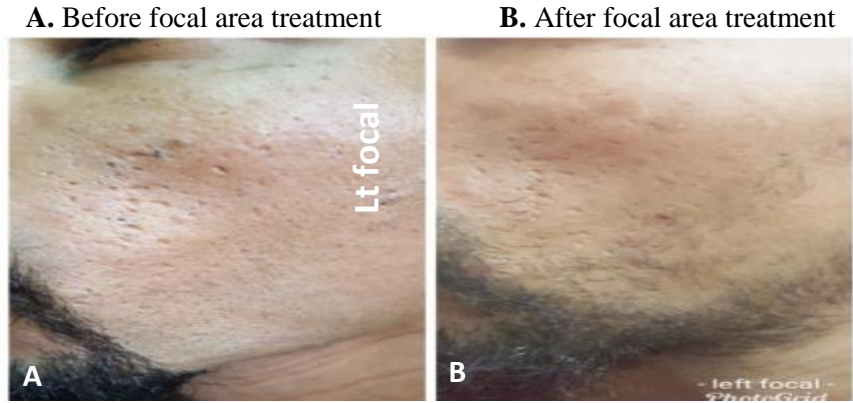


Figure (7): Left side of the same patient (2) before and after focal area fractional CO₂ treatment, using 16 mega pixel Samsung UK S6 edge digital camera.

Antera 3D Report

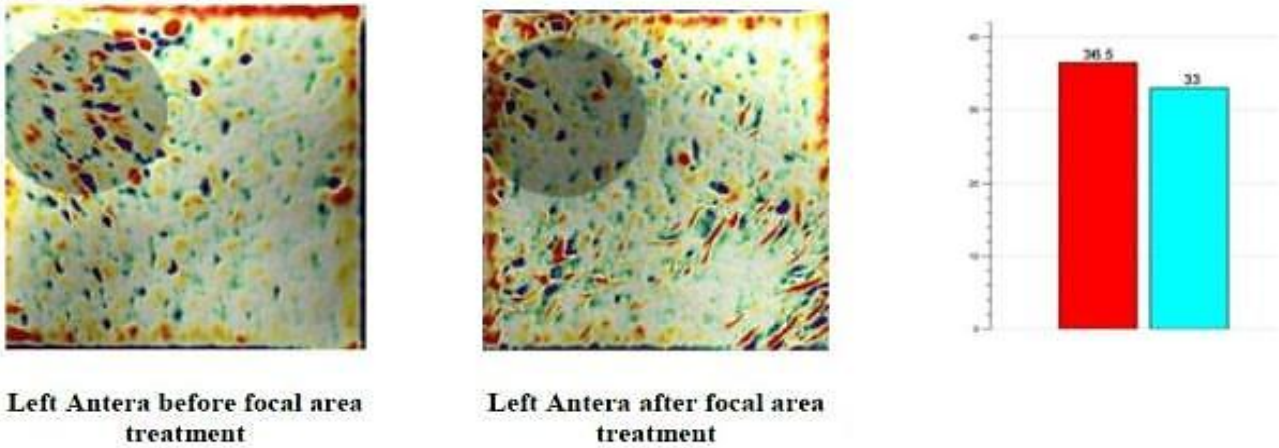


Figure (8): Left Antera texture before and after focal area fractional CO₂ treatment for patient (2) at figure (7). Left (focal area technique) texture measures before treatment was 36.5 and after treatment was 33.

Table (2) showed that there was non-significant statistical difference in the mean value of acne scars texture measured by Antera camera, before fractional CO₂ treatment in both right and left sides, making both sides comparatively matching and non-statistically significant difference in acne scars texture improvement after fractional CO₂ treatment as well.

Table (2): The difference in scars improvement in both face sides using texture (roughness) mode of Antera before and after treatment.

		Right (whole area technique)	Left (focal area technique)	Test value*	P-value	Sig.
		No. = 20	No. = 20			
Antera before	Mean ± SD	28.542 ± 10.678	29.175 ± 9.182	-0.446	0.661	NS
	Range	13.261 – 54.729	14.184 – 42.409			
Antera after	Mean ± SD	25.367 ± 10.012	24.649 ± 8.736	0.526	0.605	NS
	Range	9.496 – 44.629	8.687 – 37.848			
Difference	Mean ± SD	3.18 ± 2.27	4.53 ± 2.89	1.643	0.109	NS

*: Independent t-test.

Patients' scar improvement satisfaction was rated on each side of the face, 3 months after the fractional CO₂ laser session using VAS, in a scale of 0-10 where 10 is the best. Patients' VAS showed non-statistically significant difference between right and left facial sides using any of both techniques (P-value 0.711) (Table 3).

Table (3): Comparative assessment of clinical improvement according to patient's satisfaction using visual analog scale (VAS)

VAS (patient visual analog scale)	Right (whole area treatment)	Left (FAST)	Test value*	P-value	Sig.
	No. = 20	No. = 20			
Mean ± SD	6.50 ± 2.40	6.70 ± 1.63	-0.377	0.711	NS
Range	2 – 9	2 – 9			

*: Independent t-test

QGS was used by the researcher and 3 dermatologists blindly to assess the scar improvement three months post-treatment. QGS showed that both resurfacing techniques improved the appearance of the acne scars, but, no statistically significant difference could be detected between both facial sides using whole area versus FAST technique (researcher P-value 0.798 and the blinded 3 specialists' P-value 0.565) (Table 4).

Table 4: Right (whole area treatment) and left (FAST) comparative clinical assessment of scars improvement using quartile grading scale (QGS)

		Right (whole area treatment)		Left (focal area treatment)		Test value*	P-value	Sig.
		No.	%	No.	%			
Researcher QGS	Poor	1	5.0%	1	5.0%	0.452	0.798	NS
	Fair	8	40.0%	6	30.0%			
	Good	11	55.0%	13	65.0%			
	Excellent	0	0.0%	0	0.0%			
Average of 3 blind assessment by QGS	Poor	3.6	18.0%	1.3	6.5 %	0.586	0.565	NS
	Fair	5.6	28.0%	11	55.0%			
	Good	9.3	46.5 %	7	35.0%			
	Excellent	1.3	6.5 %	0.6	3.0%			

*: Chi-square test

There was a statistically significant correlation between right Antera texture measures' difference before and after whole area treatment and previous acne treatment, patients treated with isotretinoion showed higher roughness results (P-value0.034). Also, there was a statistically significant correlation between right Antera texture measures' difference before and after treatment and the scars severity, severer scars were rougher than others (P-value0.007). However, statistically non-significant correlations were detected, between right Antera texture measures' difference before and after treatment, on one side, and gender, special habit, Fitzpatrick skin type, previous scar treatment and morphological types of acne scars.

Regarding post-laser: pain, peeling, erythema, edema, post-inflammatory hypopigmentation/ hyperpigmentation, scarring and HSV activation at both sides, there was a statistically significant difference, as regards peeling, in right wholly and left focally treated side, it was faster in the right versus left side (P-value=0.010). There was statistically non-significant difference between both treatment techniques in post-fractional pain and PIH.. There was a statistically significant difference between peeling in right side treated by whole area technique in comparison with left focally treated side. Peeling was faster at the right (whole area technique) versus FAST. Statistically non-significant difference was detected between both treatment techniques in post fractional pain and PIH. There were no further complications such as secondary infection, scarring keloid, or persistent erythema (Table 5).

Table (5): Comparison of post fractional treatment side effects and complications at both treatment sides

	Right (whole area treatment)	Left (FAST)	Test value•	P-value	Sig.
	No. = 20	No. = 20			
Post fractional pain	7 (35.0%)	6(30.0%)	0.114	0.736	NS
Post fractional peeling	12 (60.0%)	4 (20.0%)	6.667	0.010	S
Post fractional erythema	5 (25.0%)	5 (25.0%)	0.000	1.000	NS
Post fractional edema	4 (20.0%)	3(15.0%)	0.173	0.677	NS
Post inflammatory hypopigmentation	0 (0.0%)	0 (0.0%)	NA	NA	NA
Post fractional scarring	0 (0.0%)	0 (0.0%)	NA	NA	NA
HSV activation	0 (0.0%)	0 (0.0%)	NA	NA	NA
PIH	1 (5.0%)	2(10.0%)	0.360	0.549	NS

*:Chi-square test

DISCUSSION

In addition to comedones, inflammatory papules, pustules, and occasionally nodules and cysts, acne is a multifactorial chronic inflammatory illness of the pilosebaceous unit. Treating acne scars has proven to be one of the most difficult cosmetic operations due to the fact that acne scarring is a typical side effect of the condition that causes significant psychological stress⁽¹⁶⁾. Ablative laser resurfacing, chemical peeling, dermabrasion, punch methods, subcuticular incision (subcision), injection of dermal fillers, and fractional photothermolysis are only a few of the treatment modalities designed to reduce the appearance of acne scars⁽¹⁷⁾.

The majority of treatment options either include a lifting operation to bring the base of the scar closer to the surrounding skin, or involve resurfacing, which damages the epidermis and superficial dermis and causes neocollagenesis and epidermal healing⁽¹⁸⁾.

Previous studies of acne scars resurfacing by fractional CO₂ laser were done by either whole area or focal treatment technique. This study was conducted to compare the results of whole facial area treatment versus FAST by fractional ablative CO₂ laser in a split face study. This study included 20 patients, with different types of atrophic post-acne scars (11 males and 9 females). Each patient was treated by two techniques; the right side of the face was managed by the whole area ablative fractional CO₂ laser technique including the scarred and non-scarred areas and the left side was treated by the focal acne scar ablative fractional CO₂ laser technique (FAST), focally on the acne scars leaving the normal skin un-treated.

Improvement in skin texture and reduction in scar severity after the treatment session were noticed after both treatment techniques in all patients. Assessment by the texture (roughness) mode of the Antera camera showed highly significant improvement in both right (Whole area technique) and left side (focal area technique) after fractional CO₂ laser treatment (P value 0.000). The mean value of acne scars texture improvement, measured by the Antera camera, at the right side, before treatment was 28.542 ± 10.678 and after treatment, was 25.367 ± 10.012 and the left side, before the treatment was 29.175 ± 9.182 and after treatment, was 24.649 ± 8.736 .

Comparing the right and left sides as regards acne scars texture, measured by the Antera camera, showed no statistically significant difference, before treatment, making both sides comparatively matching, as well as, no statistically significant difference in the improvement after fractional CO₂ treatment (P-value 0.109).

In this study, three months after the fractional CO₂ laser session, participants were asked to rate their scars' improvement satisfaction on each side of the face, using VAS, and statistically non-significant difference was found between both techniques (P-value= 0.711). QGS was used by the researcher and 3

specialist dermatologists blindly to assess the scar improvement, three months post treatment. QGS showed that both resurfacing techniques improved the appearance of the acne scars, but, no statistically significant difference could be detected between both face sides using whole area versus FAST technique (researcher P-value 0.798 and the blinded 3 specialists' P-value 0.565).

Patients were asked to rate their discomfort, peeling, and consequences after CO₂ fractional therapy on the right and left sides. In terms of pain, both sides showed a statistically non-significant difference. It was greater on the right side in 35% of instances, greater on the left side in 30% of cases, and equal in the remaining cases (P-value 0.736). While, there was a statistically significant difference in peeling, it was quicker on the right side in 60% of instances, 20% on the left side in 20% of cases, and equal in the remaining cases (P-value 0.010), which could be explained by the greater number of passes, in the left focally treated side, which increased the depth of microthermal zones (MTZs). Therefore, left sided FAST technique with 6 pulse overlaps led to thicker and adherent scales and crusts formation and slower peeling process than right wholly treated side, with only 3 overlaps. A statistically non-significant difference in post-inflammatory hyperpigmentation was seen on both sides; 4 patients exhibited PIH (1 on the right side, 2 on the left side, and 1 on both sides), (P-value 0.549). There were no further complications such as secondary infection, scarring keloid, or persistent erythema.

Positive statistically significant correlations were found between post-treatment, Antera camera texture mode measures, in right and left sides, and patients' age, acne duration and scars longevity. The scars were rougher with older patients and those with longer history of acne and scars.

Our findings supported those of **Hedelund et al.**⁽¹⁹⁾, who treated 13 patients with atrophic acne scars with fractional CO₂ laser resurfacing in a randomised controlled experiment. Two face regions of comparable size and look were drawn out, labelled A and B, and then randomised to either treatment or no therapy. Three laser treatments were given to patients, spaced four to five weeks apart. With a laser spot diameter of 0.5 mm, a pulse width of 4 milliseconds, and a power of 12–14 W, the laser treatment was completed in a single pass. Patients themselves and three physicians who were blinded to the treatment response and side effects rated them on a scale from 0 to 10. When compared to untreated control locations, **Hedelund et al.**⁽¹⁹⁾ found that the scar texture had improved and the degree of atrophy had decreased. The majority of patients only experienced moderate erythema and superficial sores 2-3 days after the intervention, therefore adverse effects were minimal.

Our results also agree with the study of **Eric and Sundick** ⁽¹¹⁾ which was conducted to evaluate the safety and efficacy of a focal approach of fractional CO₂ laser (FAST) in managing acne scars, treating only the acne scars and leaving normal skin untreated. Six patients were included in this study and showed significant improvement, ranging from 40% to 70% in four weeks post-treatment as estimated by the treating dermatologist and patients. Two individuals experienced transient post-inflammatory hyperpigmentation. **Eric and Sundick** ⁽¹¹⁾ study showed that the FAST technique was found to be a successful means of enhancing the look of atrophic acne scars. Healing is better and faster than treating the whole scarred and non-scarred areas, with no increase in the adverse effects.

CONCLUSION

We evaluated the results of full facial area therapy on the right side of the face to Focal Acne Scar Treatment (FAST) on the left side using a fractional CO₂ laser in this study. We discovered a statistically significant link between acne scar improvement and fractional CO₂ laser treatment using either approach, which is equally desirable in terms of results and side effects. However, FAST technique, allowed usage of higher density levels without increased incidence of permanent side effects. Also we found a statistically significant correlation between post-treatment measures of the texture mode of the Antera camera and patients' age, acne duration, scars longevity and severity. More studies are needed for further evaluation of this technique.

- **Sponsoring financially:** Nil.
- **Competing interests:** Nil.

REFERENCES

1. **Thiboutot D, Del Rosso J (2013):** Acne vulgaris and the epidermal barrier: is acne vulgaris associated with inherent epidermal abnormalities that cause impairment of barrier functions? Do any topical Acne Therapies Alter the Structural and / or Functional Integrity of the Epidermal Barrier? *J Clin Aesthet Dermatol.*, 6 (2): 18-24.
2. **Gozali M, Zhou B, Luo D (2015):** Effective treatments of Atrophic acne scars. *J Clin Aesthet Dermatol.*, 8 (5): 33-40.
3. **Kaung S, Lozada V, Bettoli V et al. (2016):** New Atrophic Acne Scar Classification: Reliability of Assessments Based on size, shape and number. *J Drugs Dermatol.*, 15 (6): 693-702.
4. **Roberts W (2004):** Chemical peeling in ethnic/-dark skin. *Dermatol Ther.*, 17 (2): 196-205.
5. **Fabbrocini G, Annunziata M, Darco V et al. (2010):** Acne Scars: Pathogenesis, Classification and treatment. *Dermatol Res Pract.*, 29 (4): 3-11.
6. **Rivera A (2008):** Acne scarring: a review and current treatment modalities. *J Am Acad Dermatol.*, 59: 659- 76.
7. **Goodman G (2003):** Post acne scarring a review. *J Cosmet Laser Ther.*, 5: 77-95.
8. **Hsiao P, Lin Y, Huang C et al. (2013):** Efficacy and safety of a single treatment using a 10,600 nm carbon dioxide fractional laser for mild to moderate atrophic acne scars in Asian skin. *Dermatologi Sinica*, 31: 59-63.
9. **Petrov A (2016):** Efficiency of Carbon Dioxide Fractional Laser in skin Resurfacing. *Open Access Maced J Med Sci.*, 4 (2): 271-6.
10. **Cho S, Lee S, Kang J et al. (2009):** The Efficacy and Safety of 10600 nm Carbon Dioxide Fractional laser for Acne Scars in Asian Patients. *Dermatol Surg.*, 35 (12): 1955-61.
11. **Eric S, Sundick L (2013):** Focal Acne Scar Treatment (FAST), a New Approach to Atrophic Acne Scars: A Case Series. *J Drugs Dermatol.*, 12 (10): 1163-67.
12. **Goodman G, Baron J (2006):** Post acne scarring: qualitative global scarring grading system. *Dermatol Surg.*, 32 (12): 1458-66.
13. **Christiansen K, Bjerring P (2008):** Low density, non-ablative fractional CO₂ laser rejuvenation. *Laser Surg Med.*, 40 (7): 454-60.
14. **Linming F, Wei H, Anqi L et al. (2018):** Comparison of two skin imaging analysis instruments: The VISIA from Canfield vs the ANTERA 3D CS from Miravex. *Skin Res Technol.*, 24: 3-8.
15. **Faghihi G, Poostiyan N, Asilian A et al. (2017):** Efficacy of fractionated microneedle radiofrequency with and without adding subcision for the treatment of atrophic facial acne scars: A randomized split-face clinical study. *J Cosmet Dermatol.*, 16: 223-9.
16. **Larsen Z, Lisa A, Sabrina G (2016):** Acne Scar Treatment: A multimodality approach tailored to scar type. *Dermatologic Surg J.*, 42: 139-49.
17. **Kucuktas M, Engin B, Kutlubay Z (2013):** Subcision treatment of acne scars. *J Turk Acad Dermatol.*, 7:1373. DOI: 10.6003/jtad.1373r1
18. **Fife D (2016):** Evaluation of Acne Scars: How to assess them and how to tell the patient. *Dermatol Clin.*, 34: 207-13.
19. **Hedelund L, Haak C, Togsverd-Bo K et al. (2012):** Fractional CO₂ laser resurfacing for atrophic acne scars: a randomized controlled trial with blinded response evaluation. *Lasers in Surgery and Medicine*, 44 (6): 447-52.