



## Eugenol Mitigates $\gamma$ -Rays-induced Acute Renal Destructive Impacts in Rats

Ahmed A. Elkady<sup>(1)#</sup>, Rehab M. Ebrahim<sup>(1)</sup>, Wael A. El khouly<sup>(2)</sup>

<sup>(1)</sup>Health Radiation Research Department, National Center for Radiation Research and Technology (NCRRT), Egyptian Atomic Energy Authority, Cairo, Egypt; <sup>(2)</sup>Radiation Protection Department, Nuclear and Radiation Safety Research Center (NRSRC), Egyptian Atomic Energy Authority, Cairo, Egypt.



**A**CUTE renal injury is a common and hazardous distress of  $\gamma$ -rays' exposure. The aim of the current study is to explore the role of eugenol on  $\gamma$ -rays-induced acute kidney lesions in rats. The rats were separated into four groups (n=6). The control group received saline for two weeks. The eugenol group received i.p. 20 mg/kg Eugenol for two weeks. The  $\gamma$ -rays group was pretreated with saline for a week, then whole-body exposed to 8 Gy  $\gamma$ -rays and saline treatment continued for another week. The rats in  $\gamma$ -rays+ eugenol group received Eugenol for a week pre-irradiation, then were exposed to  $\gamma$ -rays and eugenol treatment continued for another week. The blood and kidney samples were collected for histopathological and biochemical investigations. It was observed that exposure to  $\gamma$ -rays induced atrophy of glomeruli with increasing capsular space, expanded renal tubules and congested inter tubular blood vessels. Histological changes were accompanied by significant decreases in the level of antioxidants: reduced glutathione content (GSH), and superoxide dismutase (SOD), and catalase (CAT) activities with a significant increase of malondialdehyde (MDA; end-product of lipid peroxidation), indicating oxidative stress. Significant increases in the levels of inflammatory markers, tumor necrosis factor-alpha (TNF- $\alpha$ ) and interleukin-1 Beta (IL-1 $\beta$ ) levels were recorded also. Kidney damage was substantiated by significant increases in urea, creatinine, lactate dehydrogenase (LDH),  $\gamma$ -glutamyltransferase ( $\gamma$ GT), and disturbance of electrolytes balance; elevated sodium (Na<sup>+</sup>), and decreased potassium (K<sup>+</sup>). Eugenol treatment has significantly improved histological damage oxidative stress and inflammatory-biomarkers, which was accompanied by significant amelioration of kidney functions. It could be concluded that eugenol may alleviate acute kidney injury resulting from  $\gamma$ -rays exposure through its antioxidant and anti-inflammatory properties.

**Keywords:** Eugenol extract, Oxidative damage, Rats, Renal injury,  $\gamma$ -rays.

### Introduction

Acute renal injury is related to hazardous distress of  $\gamma$ -rays and radiotherapy disclosure (Kawamoto et al., 2020; El Bakary et al., 2022). Eugenol is used as an essential mediator in foodstuff and constitutes in the soybeans, clove oil, camphorated oil, basil, nutmeg, cinnamon, and bay leaf (Hossain et al., 2023). It has a prospective role in improving and avoidance of chronic illnesses such as malignancy, inflammatory diseases, and other disorders (Begum

et al., 2022). Besides, it has attracted attention due to its anti-bacterial, anti-inflammatory, and antioxidant activities (Wang et al., 2022). The anticancer activity of Eugenol has become overriding in the researches at the latest years (Begum et al., 2022; Padhy et al., 2022). Moreover, it has defending roles against cerebral ischemic reperfusion injury, aluminum-induced neurotoxicity, and biliopancreatic duct's ligation-induced acute pancreatitis and acute renal injury related to the oxidative damage in rats (Markakis et al., 2016; Mesole et al., 2020; Sun et

#Corresponding author e-mail: elkadyah13@gmail.com

Received 25/05/2023; Accepted 15/08/2023

DOI: 10.21608/EJRSA.2023.213316.1155

©2023 National Information and Documentation Center (NIDOC)

al., 2020), and also in acute myocardial ischemia-reperfusion injury in humans (Xue et al., 2023).

Ionizing radiation has evoked an allowance of consideration due to its benefits in medical and industrial fields, as well as its achievable destructive effects on the human population. The damaging properties of ionizing radiation have been contributed to the generation of reactive oxygen species (ROS) and reduction of the activity of antioxidant enzymes. Gamma-rays provokes destructive effects in the rats' kidney (Jit et al., 2022; Ismail et al., 2023). Moreover, the kidney is usually exposed to high doses of radiation in the treatment of some cancers in abdominal region radiotherapy (Azmoonfar et al., 2023).

Eugenol effect on  $\gamma$ -rays-induced acute renal nephrotoxicity has not been studied until now. The present study was conducted to determine the protective role of eugenol on  $\gamma$ -rays-induced acute renal destructive impacts.

## **Materials and Methods**

### **Experimental animals**

Male, 24 Sprague-Dawley rats weighting (220–250 g) were saved in clean boxes with 12 hours' light/dark phase at room temperature ( $22\pm 2^\circ\text{C}$ ) with free contact to foodstuff and water. The animals were accustomed to the settings and experimentations before starting the investigation. The rats were gone through procedure, maintained and used in accordance with the guide for the care and use of laboratory animals published before, National Institutes of Health, No. 85–23, revised 1996.

### **Irradiation of rats**

The rats were irradiated in a well-ventilated Canadian gamma-chamber ( $^{137}\text{Cs}$  source, gamma cell-40 Exactor, Best Theratronics, Ottawa, Canada) belonging to the National Center for Radiation Research and Technology (NCRRT), Nasr City, Egypt. The dose rate was 0.4 Gy/ minute. The animals were irradiated with a whole-body single dose of 8 Gy  $\gamma$ -rays.

### **Chemicals**

Eugenol (ReagentPlus®, 99% liquid) obtained from Sigma-Aldrich; Merck, Germany. All other chemicals and solvents used were of the researches' highest purity grade available. The eugenol dose was daily 20 mg/kg body weight via intra-peritoneal (i.p.) route for 15 days according to Feng et al. (2018).

### **Animal grouping and investigational scheme**

The rats were divided randomly into four sets, each of six rats. The control group received i.p. 0.5 ml of physiological saline/day for two weeks. The rats in the eugenol group received i.p. 0.5 ml of saline contains eugenol dosages/for two weeks. The rats in  $\gamma$ -rays group were pretreated with i.p. 0.5 ml of the physiological saline/day for a week and exposed to 8 Gy  $\gamma$ -rays after 1 h flowing the last dose then continued receiving the saline for another week. The rats in  $\gamma$ -rays+ eugenol group received i.p. eugenol dosages/for a week and exposed to 8 Gy  $\gamma$ -rays after 1 h flowing the last dose then continued receiving the eugenol dosages for another week. All rats were sacrificed by cervical dislocations 1 day after i.p. injection, under general anesthesia (87 mg ketamine/kg and 13mg xylazine/kg of body weight) and kidney samples, were collected for assessment.

Blood samples were taken through the heart puncture and the serum was harvested after centrifugation (300 xg) for 10 min. Also the kidneys were instantly trimmed for histological examination and biochemical investigations. kidneys were processed in a cooled 0.15 M Tris KCl buffer (pH 7.4) to produce a 10% (w/v) homogenate utilizing, Homogenizer-MNW-302, Poland. The homogenate was centrifuged at 800xg for 5 min,  $4^\circ\text{C}$  to separate the tissue fragments. The supernatant of the homogenates was preserved at  $70^\circ\text{C}$  for the biochemical analysis.

### **Evaluation of renal damage markers**

Colorimetric assessment of serum renal function biomarkers; urea, creatinine and sodium ( $\text{Na}^+$ ) using Biodiagnostic kits (UR 21 10, CR 12 50 and SO 19 10, respectively), Egypt. Potassium ( $\text{K}^+$ ) concentration was measured using turbidimetric method (PT 18 20) belonging to Biodiagnostic, Egypt.

### **Evaluation of renal oxidative stress markers**

Colorimetric assessment of renal oxidative stress markers: reduced glutathione (GSH), malondialdehyde (MDA), superoxide dismutase (SOD), and catalase (CAT) were performed as described by Cigala et al. (2012), Ohkawa et al. (1979), Kakkar et al. (1984) and Titov & Osipov (2017), respectively.

### **Evaluation of renal damage markers**

Renal tissue damage markers; lactate dehydrogenase (LDH) were determined according to Bergmeyer & Bernt (1974) method and  $\gamma$ -glutamyltransferase ( $\gamma\text{GT}$ ) was employed using

Biodiagnostic kit (MAK089), Egypt according to Rosalki (1975) method.

#### Evaluation of renal inflammatory biomarkers

Assessment of renal inflammatory biomarkers; Tumor necrosis factor-alpha (TNF- $\alpha$ ) and interleukin-1 Beta (IL-1 $\beta$ ) levels were measured using the enzyme-linked immunosorbent assay (ELISA) Technology Biotech Company Kits (Catalogue No. CSB-E11987r and Catalogue No. CSB-E08055r, respectively), China. The homogenate's total protein content was evaluated using Lowry et al. (1951) technique (TP 20 21) belonging to Biodiagnostic, Egypt.

#### Histological examination

The Kidneys were separated and cut crosswise and put in Bouin's fixative for 4 hours then washed and placed in isopropanol (70%) for 12 hours at 20°C. The samples were dehydrated, cleared with xylene, and embedded in paraffin. Tissue samples were cut into 5 $\mu$ m thick sections followed by hematoxylin and eosin (H&E) staining according to Suvama et al. (2013) and examined through light microscope.

#### Statistical analysis

The Data were analyzed using SPSS version 20, one-way Analysis of Variances (ANOVA), and the "Tukey test" were calculated. In between groups, data and statistical significance were presented as mean  $\pm$  standard deviation (S. D.), and P value  $\leq$  0.05 was considered as statistically significant.

### Results

The administration of eugenol to the eugenol rat group did not indicate modifications compared with the control group in expressions of all studied serum and renal markers ( $P < 0.05$ ), which confirmed that the eugenol used does not utilize a toxic result

(Tables 1-4). However, it must be used according to the therapeutic welfare evidenced in toxicity (Barboza et al., 2018).

In the  $\gamma$ -rays rat group, an irradiation (8 Gy  $\gamma$ -rays) produced significant increases in urea, creatinine, and Na<sup>+</sup> levels but K<sup>+</sup> decreased significantly, with respect to the control rats group. Administration of eugenol regime to the irradiated rats ( $\gamma$ -rays+eugenol group) did not cause any significant change in the estimated serum urea, creatinine, Na<sup>+</sup>, and K<sup>+</sup> concentrations, with respect to normal controls, (Table 1).

The  $\gamma$ -rays' exposure initiated a significant rise in the renal MDA (30%) level, beside the exhaustion of the antioxidant system in renal tissues as denoted by the significant drop in GSH, SOD, and CAT levels (49%, 38%, and 40%), respectively. The i.p. intake of eugenol to  $\gamma$ -irradiated rats was competent to regularize renal MDA and GSH concentrations, as well as SOD and CAT activities, (Table 2).

The  $\gamma$ -rays provided rise to a significant increase in renal LDH and  $\gamma$ GT activities (48% and 50%, respectively), compared with the control rats group. However, i.p. protracted administration of the eugenol with  $\gamma$ -rays normalized the renal LDH and  $\gamma$ GT activities, compared with the control rats group (Table 3).

The whole body  $\gamma$ -rays-exposure dramatically augmented the renal TNF- $\alpha$  (450%) and IL-1 $\beta$  (277%) levels, compared to the control rats group.

The i.p. pre- and post-injections of  $\gamma$ -irradiated rats with eugenol exhibited an intense reduction in both renal TNF- $\alpha$  and IL-1 $\beta$  levels compared to the  $\gamma$ -rays rat group, but their levels still significantly higher compared to the control rats group (Table 4).

**TABLE 1. Statistical significance of the serum urea, creatinine, sodium and potassium concentrations in rats treated with Eugenol and/or  $\gamma$ -rays**

Groups	Control	Eugenol	$\gamma$ -rays	$\gamma$ -rays+Eugenol
Urea (mg/dL)	31.31 $\pm$ 1.343	33.51 $\pm$ 4.162 <sup>c</sup>	74.72 $\pm$ 6.173 <sup>a,b,d</sup>	42.52 $\pm$ 4.214 <sup>c</sup>
% change		+7%	+239%	+36%
Creatinine (mg/dL)	0.84 $\pm$ 0.036	0.91 $\pm$ 0.054 <sup>c</sup>	1.72 $\pm$ 0.161 <sup>a,b,d</sup>	1.01 $\pm$ 0.071 <sup>c</sup>
% change		+11.5%	+105.5%	+20%
Na <sup>+</sup> (mEq/L)	120.52 $\pm$ 8.933	118.22 $\pm$ 9.064 <sup>c</sup>	156.73 $\pm$ 12.283 <sup>a,b,d</sup>	126.32 $\pm$ 10.121 <sup>c</sup>
% change		-2%	+30%	+5%
K <sup>+</sup> (mEq/L)	4.55 $\pm$ 0.325	4.61 $\pm$ 0.352 <sup>c</sup>	3.01 $\pm$ 0.242 <sup>a,b,d</sup>	4.20 $\pm$ 4.010 <sup>c</sup>
% change		+1%	-34%	-8%

Values are presented as the mean $\pm$  S. D., and (n = 6).

<sup>a,b,c,d</sup>P < 0.05 versus control, Eugenol,  $\gamma$ -rays or  $\gamma$ -rays+ Eugenol group.

**TABLE 2. Statistical significance of the renal MDA, GSH, SOD, and CAT levels in rats treated with Eugenol and/or  $\gamma$ -rays**

Groups	Control	Eugenol	$\gamma$ -rays	$\gamma$ -rays+Eugenol
MDA (nmol/g tissue)	56.21± 4.771	53.21± 4.292 <sup>c</sup>	73.22± 6.131 <sup>a,b,d</sup>	58.52± 5.022 <sup>c</sup>
% change		-7%	+30%	+4%
GSH ( $\mu$ mol/g tissue)	0.43± 0.032	0.41± 0.031 <sup>c</sup>	0.22± 0.021 <sup>a,b,d</sup>	0.38± 0.039 <sup>c</sup>
% change		-5%	-49%	-12%
SOD (U/mg protein)	4.71± 0.321	4.92± 0.362 <sup>c</sup>	2.91± 0.276 <sup>a,b,d</sup>	4.41± 0.321 <sup>c</sup>
% change		+4%	-38%	-6%
CAT (U/mg protein)	0.87± 0.076	0.88± 0.055 <sup>c</sup>	0.52± 0.044 <sup>a,b,d</sup>	0.83± 0.061 <sup>c</sup>
% change		+1%	-40%	-5%

Values are presented as the mean± S. D., and (n = 6).

<sup>a,b,c,d</sup>P < 0.05 versus control, Eugenol,  $\gamma$ -rays or  $\gamma$ -rays+ Eugenol group.

**TABLE 3. Statistical significance of the renal LDH and  $\gamma$ GT levels in rats treated with Eugenol and/or  $\gamma$ -rays**

Groups	Control	Eugenol	$\gamma$ -rays	$\gamma$ -rays+Eugenol
LDH (U/mg protein)	1.12± 0.073	1.10± 0.063 <sup>c</sup>	1.66± 0.086 <sup>a,b,d</sup>	1.21± 0.075 <sup>c</sup>
% change		-2%	+48%	+8%
$\gamma$ GT (U/mg protein)	0.62± 0.052	0.64± 0.042 <sup>c</sup>	1.24± 0.132 <sup>a,b,d</sup>	0.70± 0.042 <sup>c</sup>
% change		+3%	+50%	+13%

Values are presented as the mean± S. D., and (n = 6).

<sup>a,b,c,d</sup>P < 0.05 versus control, Eugenol,  $\gamma$ -rays or  $\gamma$ -rays+ Eugenol group.

**TABLE 4. Statistical significance of the renal TNF- $\alpha$  and IL-1 $\beta$  levels in rats treated with Eugenol and/or  $\gamma$ -rays**

Groups	Control	Eugenol	$\gamma$ -rays	$\gamma$ -rays+Eugenol
TNF- $\alpha$ (pg/ mg protein)	4.92± 0.363	4.81± 0.354 <sup>c,d</sup>	22.13± 2.106 <sup>a,b,d</sup>	7.01± 0.662 <sup>a,b,c</sup>
% change		-2%	+450%	+142%
IL-1 $\beta$ (pg/ mg protein)	2.33± 0.192	2.24± 0.172 <sup>c,d</sup>	6.45± 0.622 <sup>a,b,d</sup>	2.68± 0.181 <sup>a,b,c</sup>
% change		-4%	+277%	+15%

Values are presented as the mean± S. D., and (n = 6).

<sup>a,b,c,d</sup>P < 0.05 versus control, Eugenol,  $\gamma$ -rays or  $\gamma$ -rays+ Eugenol group.

### Histopathological finding

Renal tissues of both control and eugenol rats showed normal structure (Figs. 1 & 2). In  $\gamma$ -rays group, the proximal and distal renal tubules were expanded and contain hyaline casts, hemorrhage and/or congested inter tubular blood vessels. In other cases, the renal tissues were infiltrated by substantial leukocytes with exudates in the renal cortex. Moreover, the lesions showed progressively atrophied glomeruli with increasing capsular space (Fig. 3 A & B). In addition, in some cases apoptosis were showed among the epithelium of renal tubules (Fig. 3 C). However, in eugenol-treated and irradiated group, the histological structure of kidney showed relatively well conserved architecture without degenerative changes with expanded tubules and/or congested inter-tubular blood vessels (Fig. 4 A & B).

### Discussion

The results of extensive studies revealed that eugenol protects male albino rats against potassium dichromate-induced acute kidney damage (Barhoma, 2018). Furthermore, eugenol ameliorates silver nanoparticles-induced nephrotoxicity (Aboelwafa et al., 2022) and hepatotoxicity in male rats, with parallel improvement of the histopathological alterations (Yousef et al., 2022). Moreover, it attenuates the neuro-inflammation outcomes in various neurological diseases (Zhu et al., 2023). The current results verified the mitigating roles of eugenol as an antioxidant phenolic agent, on  $\gamma$ -rays-induced acute renal destructive impacts, in line with the consideration that ROS are significant mediators of  $\gamma$ -rays-induced acute renal nephrotoxicity (El Bakary et al., 2022).

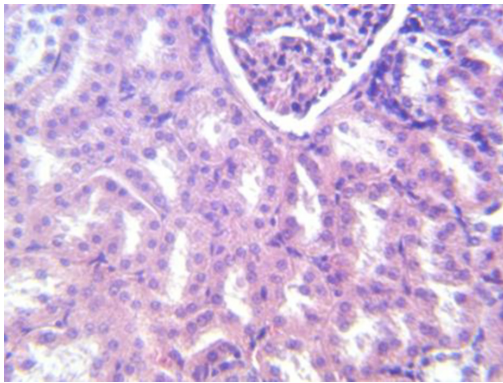


Fig. 1. kidney of control rat shows normal structure (H&E 400x)

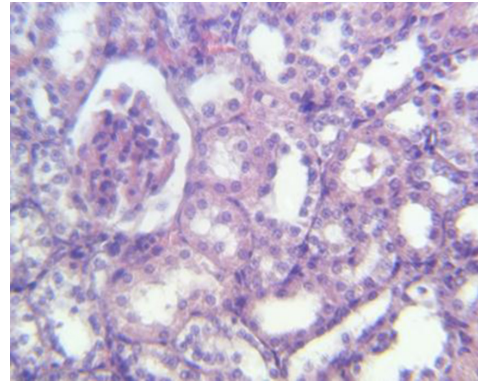


Fig. 2. kidney of eugenol rat shows normal structure (H&E 400x)

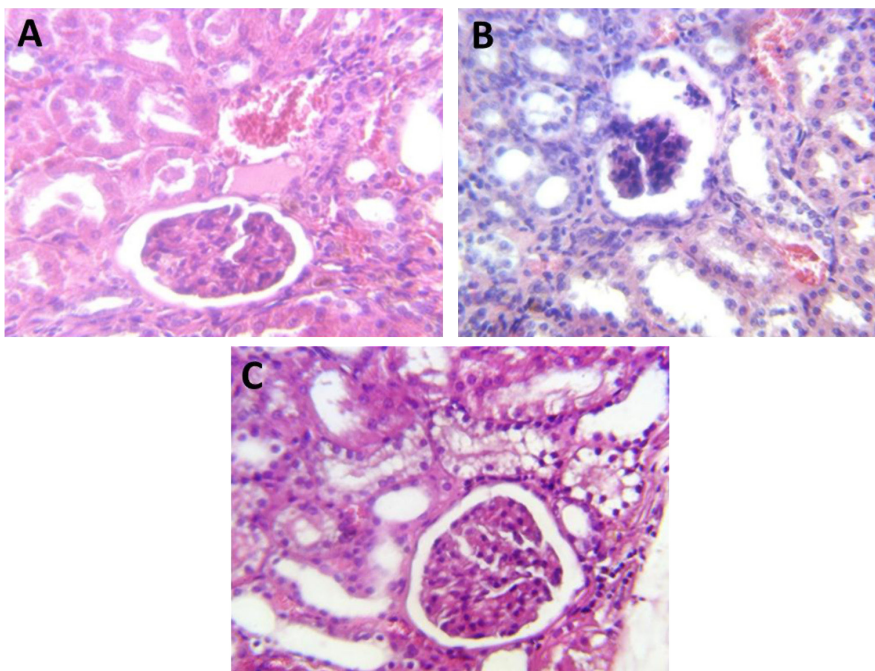


Fig. 3A. kidney of irradiated group shows dilated inter tubular blood vessels, hemorrhage inside tubule and hyaline cast with increasing leukocytes among the tubules. B: kidney of irradiated group shows atrophy of glomeruli with expanded tubules cover with massive leukocytes tubules tubule. C: kidney of irradiated group shows apoptosis of tubular epitheliums with loss its brush border (H&E 400x)

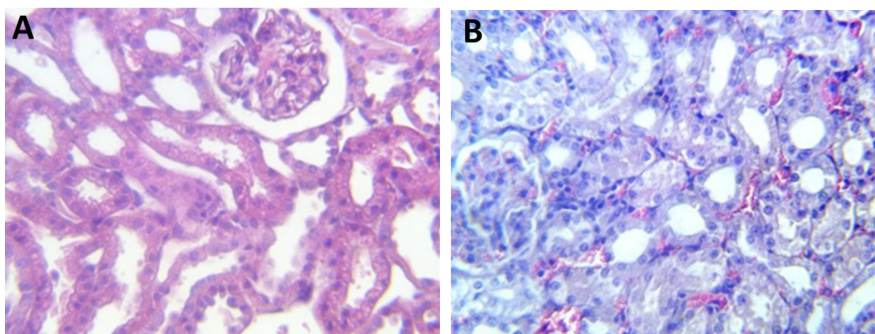


Fig. 4A. kidney of treated-irradiated group shows normal structure with expanded tubules. B: kidney of treated-irradiated group shows normal structure with dilated inter-tubular blood vessels (H&E 400x)

Acute kidney injury is associated with the sudden loss of kidney function (Basile et al., 2012), verified by elevated levels of serum urea and creatinine and electrolyte disorders (Chen et al., 2021). In the current study,  $\gamma$ -rays-exposure initiated obvious renal-dysfunction verified by the significant rise in serum urea, and creatinine, which goes in line with the previous findings of Asker et al. (2021). A significant rise of serum urea content is directly relative to the severity of renal injury (Arase et al., 2020). The results showed also a significant increase of  $\text{Na}^+$  and a significant decrease of  $\text{K}^+$ . Eugenol treatment has significantly improved the renal function verifying the reno-protective utilization of eugenol (Fathy et al., 2022).

In the present study, the GSH, SOD, and CAT levels in renal homogenate were significantly declined in  $\gamma$ -irradiated rats whereas MDA level was augmented significantly. The  $\gamma$ -rays-induced nephrotoxicity was previously designated by a significant increase in the level of MDA in the rats (Abdel-Magied et al., 2019). The increase of MDA is possibly the result of the interaction of the hydroxyl radical ( $\cdot\text{OH}$ ) generated upon irradiation, with polyunsaturated fatty acids. Also, it has been described that radiation-induced exhaustion in the levels of antioxidant markers such as GSH contents, and SOD, and CAT activities in the kidney of albino rats (Abdel-Magied et al., 2020; Mahgoub et al., 2020). The modulator effect of eugenol against oxidative stress may be attributed to its role in neutralizing lipid oxidation and enhancing antioxidant markers (Sharma et al., 2019).

The significant variations in LDH and  $\gamma\text{GT}$  in  $\gamma$ -rays rat group are in agreement with previous findings that oxidative stress in the kidney of rats caused renal damages (Djaber et al., 2020; Gargouri et al., 2020), and appeared to be degenerative changes of the kidney tubules (Abdel-Magied et al., 2020). However, the significant decline in LDH and  $\gamma\text{GT}$  activities in  $\gamma$ -rays+ eugenol rats group may be attributed to tubular repair by eugenol. The results are in agreement with the findings of Mnafigui et al. (2016) that eugenol exerted a protective activity against isoproterenol-induced destructive intoxication in liver, kidney, and heart of Wistar rats and significantly restored the  $\gamma\text{GT}$ , creatinine, and urea levels to near normal rates, in alloxan-induced diabetic biochemical alterations (Mnafigui et al., 2013).

It is well documented that inflammation represents an important component of acute kidney injury (Basile et al., 2012). In the current study,  $\gamma$ -rays-exposure of rats induced significant elevation in the level of the inflammatory markers;  $\text{TNF-}\alpha$  and  $\text{IL-1}\beta$ , associated to increase of serum urea and creatinine, and reduction of the renal antioxidants; GSH, SOD and CAT. The results are in agreement with those of El-Gazzar et al. (2016) who observed that  $\gamma$ -rays exposure induced inflammation, renal disfunction and oxidative stress. Moreover, Elkady & Ibrahim (2016) recorded that a dose of 5 Gy  $\gamma$ -rays exhibited elevations of  $\text{TNF-}\alpha$  and  $\text{IL-1}\beta$  levels, and reductions of GSH and CAT activities in the kidney of male albino rats. The elevation of  $\text{TNF}\alpha$  and  $\text{IL-1}\beta$  might be attributed to the correlation between oxidative stress and inflammation, one of which can be easily induced by another (Sandoval et al., 2018).

Ultimately, the biochemical findings were confirmed by histopathological examination of renal tissues of irradiated rats which showed expanded proximal and distal renal tubules contained hyaline casts beside hemorrhage and/or congested inter tubular blood vessels. Furthermore, renal tissues were infiltrated by significant leukocytes with exudates in the renal cortex, and atrophy of glomeruli with increasing capsular space shown. This is in agreement with previous findings that gamma rays induced nephropathy noticed by the occurrence of damage to glomeruli, blood vessels, tubular epithelium, and interstitial tissues (Cohen & Robbins, 2003; Elkady & Ibrahim, 2016). In eugenol-treated and irradiated group, the histological structure of kidney showed relatively well conserved architecture without degenerative changes with expanded tubules and/or congested inter-tubular blood vessels. The results could be attributed to the role of eugenol in the modulation of oxidative stress and inflammation.

In this context, Said (2011) reported that eugenol improves garamycin-induced nephrotoxicity and oxidative injury by scavenging oxygen free radicals, decreasing lipid peroxidation, improving intracellular antioxidant defense, lower severe tubular necrosis at the cortex and decreased cellular inflammatory processes. Additionally, Hussein et al. (2020) described that the administration of eugenol effectively protected from the histopathological and functional kidney damage induced by cadmium exposure via antioxidant and anti-apoptotic effects.

## Conclusions

Eugenol mitigates  $\gamma$ -rays-induced acute renal damage in rats. It enhances the renal function-, renal oxidative stress-, renal tissue damage-, and renal inflammatory-markers through both anti-oxidative and/or anti-inflammatory properties, avoiding damage to the renal structure.

**Recommendations:** Further studies are required to approve the efficiency of eugenol in the defense of renal diseases and to detect the most suitable dose regime.

**Acknowledgements:** The authors are thankful to their colleagues in Health Radiation Research Department for providing laboratory services, and technicians of the NCRRT, Egyptian Atomic Energy Authority, for providing the fundamental irradiation facilities.

## References

- Abdel-Magied, N., Elkady, A.A. (2019) Possible curative role of curcumin and silymarin against nephrotoxicity induced by gamma-rays in rats. *Experimental and Molecular Pathology*, **111**, 104299. doi: 10.1016/j.yexmp.2019.104299.
- Abdel-Magied, N., Elkady, A.A., Abdel Fattah, S.M. (2020) Effect of low-level Laser on some metals related to redox state and histological alterations in the liver and kidney of irradiated rats. *Biological Trace Element Research*, **194**(2), 410-422. doi: 10.1007/s12011-019-01779-3.
- Aboelwafa, H.R., Ramadan, R.A., Ibraheim, S.S., Yousef, H.N. (2022) Modulation effects of eugenol on nephrotoxicity triggered by Silver nanoparticles in adult rats. *Biology (Basel)*, **11**(12), 1719. doi: 10.3390/biology11121719.
- Arase, H., Yamada, S., Hiyamuta, H., Taniguchi, M., Tokumoto, M., Tsuruya, K., et al. (2020) Modified creatinine index and risk for long-term infection-related mortality in hemodialysis patients: ten-year outcomes of the Q-Cohort Study. *Scientific Reports*, **10**(1), 1241. doi: 10.1038/s41598-020-58181-6.
- Asker, M.E., Ali, S.I., Mohamed, S.H., Abdalaleem, R.M.A., Younis, N.N. (2021) The efficacy of bone marrow-derived mesenchymal stem cells and/or erythropoietin in ameliorating kidney damage in gamma irradiated rats: Role of non-hematopoietic erythropoietin anti-apoptotic signaling. *Life Sciences*, **275**, 119388. doi: 10.1016/j.lfs.2021.119388.
- Azmoonfar, R., Khosravi, H., Rafieemehr, H., Mirzaei, F., Dastan, D., Ghiasvand, M.R., Khorshidi, L., Pashaki, A.S. (2023) Radioprotective effect of *Malva sylvestris* L. against radiation-induced liver, kidney and intestine damages in rat: A histopathological study. *Biochemistry and Biophysics Reports*, **34**, 101455. doi: 10.1016/j.bbrep.2023.101455.
- Barboza, J.N., da Silva Maia Bezerra Filho, C., Silva, R.O., Medeiros, J.V.R., de Sousa, D.P. (2018) An overview on the anti-inflammatory potential and antioxidant profile of eugenol. *Oxidative Medicine and Cellular Longevity*, **2018**, 3957262. doi: 10.1155/2018/3957262.
- Barhoma, R.A.E. (2018) The role of eugenol in the prevention of chromium-induced acute kidney injury in male albino rats. *Alexandria Journal of Medicine*, **54**(4), 711-715. doi: 10.1016/j.ajme.2018.05.006.
- Basile, D.P., Anderson, M.D., Sutton, T.A. (2012) Pathophysiology of acute kidney injury. *Comprehensive Physiology*, **2**(2), 1303-1353. doi: 10.1002/cphy.c110041.
- Begum, S.N., Ray, A.S., Rahaman, C.H. (2022) A comprehensive and systematic review on potential anticancer activities of eugenol: From pre-clinical evidence to molecular mechanisms of action. *Phytomedicine*. **107**, 154456. doi: 10.1016/j.phymed.2022.154456.
- Bergmeyer, H.U., Bernt, E. (1974) UV-assay with pyruvate and NADH. In: "*Methods of Enzymatic Analysis*", Bergmeyer, H.U. (Ed.), pp. 574-579. Academic Press, New York.
- Chen, X., Xu, J., Li, Y., Xu, X., Shen, B., Zou, Z., Ding, X., et al. (2021) Risk scoring systems including electrolyte disorders for predicting the incidence of acute kidney injury in hospitalized patients. *Clinical Epidemiology*, **13**, 383-396. doi: 10.2147/CLEP.S311364.
- Cigala, R.M., Crea, F., De Stefano, C., Lando, G., Milea, D., Sammartano S. (2012) Modeling the acid-base properties of glutathione in different ionic media, with particular reference to natural waters and biological fluids. *Amino Acids*, **43**, 629-648. doi: 10.1007/s00726-011-1110-0.

- Cohen, E.P., Robbins, M.E. (2003) Radiation nephropathy. *Seminars in Nephrology*, **23**, 486–499.
- Djaber, N., Ounaceur, L.S., Moubine, B.N., Khaldi, T., Rouag, M., Berrouague, S., et al. (2020) Roundup-induced biochemical and histopathological changes in the liver and kidney of rats: the ameliorative effects of *Linum usitatissimum* oil. *Acta Biochimica Polonica*, **67**(1), 53-64. doi: 10.18388/abp.2020\_2898.
- El Bakary, N.M., Abdel-Rafei, M.K., Maarouf, R.E., Mansour, S.Z., Thabet, N.M. (2022) Trans-resveratrol alleviates hepatic and renal injury in  $\gamma$ -irradiated rats. *Human & Experimental Toxicology*, **41**, 9603271221142817. doi: 10.1177/09603271221142817.
- El-Gazzar, M.G., Zaher, N.H., El-Hossary, E.M., Ismail, A.F.M. (2016) Radio-protective effect of some new curcumin analogues. *Journal of Photochemistry and Photobiology B*, **162**, 694-702. doi: 10.1016/j.jphotobiol.2016.08.002.
- Elkady, A.A., Ibrahim, I.M. (2016) Protective effects of erdosteine against nephrotoxicity caused by gamma radiation in male albino rats. *Human & Experimental Toxicology*, **35**(1), 21-28. doi: 10.1177/0960327115574919.
- Fathy, M., Abdel-Latif, R., Abdelgwad, Y.M., Othman, O.A., Abdel-Razik, A.H., Dandekar, T., Othman, E.M. (2022) Nephroprotective potential of eugenol in a rat experimental model of chronic kidney injury; targeting NOX, TGF- $\beta$ , and Akt signaling. *Life Sciences*, **308**, 120957. doi: 10.1016/j.lfs.2022.120957.
- Feng, W., Jin, L., Xie, Q., Huang, L., Jiang, Z., Ji, Y., Li, C., Yang, L., Wang, D. (2018) Eugenol protects the transplanted heart against ischemia/reperfusion injury in rats by inhibiting the inflammatory response and apoptosis. *Experimental and Therapeutic Medicine*, **16**(4), 3464-3470. doi: 10.3892/etm.2018.6598.
- Gargouri, M., Akrouti, A., Magné, C., ElFeki, A., Soussi, A. (2020) Protective effects of spirulina against hemato-biochemical alterations, nephrotoxicity, and DNA damage upon lead exposition. *Human & Experimental Toxicology*, **39**(6), 855-869. doi: 10.1177/0960327120903490.
- Hossain, M.B., Ahmed, L., Martin-Diana, A.B., Brunton, N.P., Barry-Ryan, C. (2023) Individual and combined antioxidant activity of spices and spice phenolics. *Antioxidants (Basel)*, **12**(2), 308. doi: 10.3390/antiox12020308.
- Hussein, R., Khalaf, M., Mohamed, W. (2020) Hesperidin and eugenol attenuate cadmium-induced nephrotoxicity via regulation of oxidative stress, Bax/Bcl2 and cleaved caspase 3 expression. *Turkish Journal of Biochemistry*, **45**(6), 767–775. <https://doi.org/10.1515/tjb-2020-0161>
- Ismail, A.F.M., Salem, A.A., Eassawy, M.M.T. (2023) Rutin protects against gamma-irradiation and malathion-induced oxidative stress and inflammation through regulation of mir-129-3p, mir-200C-3p, and mir-210 gene expressions in rats' kidney. *Environmental Science and Pollution Research*, **30**, 72930-72948. doi: 10.1007/s11356-023-27166-z.
- Jit, B.P., Pattnaik, S., Arya, R., Dash, R., Sahoo, S.S., Pradhan, B., et al. (2022) Phytochemicals: A potential next generation agent for radioprotection. *Phytomedicine*, **106**, 154188. doi: 10.1016/j.phymed.2022.154188.
- Kakkar, P., Das, B., Viswanathan, P.N. (1984) A modified spectrophotometric assay of superoxide dismutase. *Indian Journal of Biochemistry and Biophysics*, **21**, 130–132.
- Kawamoto, T., Shikama, N., Mine, S., Tsurumaru, M., Sasai, K. (2020) Clinical impact of baseline renal function on the safety of radiotherapy with concurrent docetaxel for esophageal cancer in elderly patients. *Esophagus*, **17**(4), 425-432. doi: 10.1007/s10388-020-00731-y.
- Lowry, O.H., Rosebrough, N.J., Farr, A.L., Randall, R.J. (1951) Protein measurement with the Folin phenol reagent. *Journal of Biological Chemistry*, **193**, 265-675.
- Mahgoub, S., Sallam, A.O., Sarhan, H.K.A., Ammar, A.A.A., Soror, S.H. (2020) Role of Diosmin in protection against the oxidative stress induced damage by gamma-radiation in Wistar albino rats. *Regulatory Toxicology and Pharmacology*, **113**, 104622. doi: 10.1016/j.yrtph.2020.104622.
- Markakis, C., Tsaroucha, A., Papalois, A.E., Lambropoulou, M., Spartalis, E., Tsigalou, C., et al. (2016) The role of eugenol in the prevention



- of acute pancreatitis-induced acute kidney injury: Experimental study. *HPB Surgery*, **2016**, 3203147. doi: 10.1155/2016/3203147.
- Mesole, S.B., Alfred, O.O., Yusuf, U.A., Lukubi, L., Ndhlovu, D. (2020) Apoptotic inducement of neuronal cells by Aluminium chloride and the neuroprotective effect of eugenol in Wistar rats. *Oxidative Medicine and Cellular Longevity*, **2020**, 8425643. doi: 10.1155/2020/8425643.
- Mnafgui, K., Kaanich, F., Derbali, A., Hamden, K., Derbali, F., Slama, S., et al. (2013) Inhibition of key enzymes related to diabetes and hypertension by Eugenol in vitro and in alloxan-induced diabetic rats. *Archives of Physiology and Biochemistry*, **119**(5), 225-33. doi: 10.3109/13813455.2013.822521.
- Mnafgui, K., Hajji, R., Derbali, F., Gammoudi, A., Khabbabi, G., Ellefi, H., et al. (2016) Anti-inflammatory, antithrombotic and cardiac remodeling preventive effects of eugenol in isoproterenol-induced myocardial infarction in Wistar rat. *Cardiovascular Toxicology*, **16**(4), 336-44. doi: 10.1007/s12012-015-9343-x.
- Ohkawa, H., Ohishi, N., Yagi, K. (1979) Assay for lipid peroxides in animal tissues by thiobarbituric acid reaction. *Analytical Biochemistry*, **95**(2), 351-358.
- Padhy, I., Paul, P., Sharma, T., Banerjee, S., Mondal, A. (2022) Molecular mechanisms of action of eugenol in cancer: Recent trends and advancement. *Life (Basel)*, **12**(11), 1795. doi: 10.3390/life12111795.
- Rosalki, S.B. (1975) Gamma-glutamyl transpeptidase. *Advances in Clinical Chemistry*, **17**, 53-107. doi: 10.1016/s0065-2423(08)60248-6.
- Said M.M., (2011) The protective effect of eugenol against gentamicin-induced nephrotoxicity and oxidative damage in rat kidney. *Fundamental & Clinical Pharmacology*, **25**(6), 708-716. doi: 10.1111/j.1472-8206.2010.00900.x.
- Sandoval, R., Lazcano, P., Ferrari, F., Pinto-Pardo, N., González-Billault, C., Utreras, E. (2018) TNF- $\alpha$  increases production of reactive oxygen species through Cdk5 activation in nociceptive neurons. *Frontiers in Physiology*, **9**, 65. doi: 10.3389/fphys.2018.00065.
- Sharma, U.K., Kumar, R., Gupta, A., Ganguly, R., Singh, A.K., Ojha, A.K., Pandey, A.K. (2019) Ameliorating efficacy of eugenol against metanil yellow induced toxicity in albino Wistar rats. *Food and Chemical Toxicology*, **126**, 34-40. doi: 10.1016/j.fct.2019.01.032.
- Sun, X., Wang, D., Zhang, T., Lu, X., Duan, F., Ju, L., Zhuang, X., Jiang, X. (2020) Eugenol attenuates cerebral ischemia-reperfusion injury by enhancing autophagy via AMPK-mTOR-P70S6K pathway. *Frontiers in Pharmacology*, **11**, 84. doi: 10.3389/fphar.2020.00084.
- Suvarna, K.S., Layton, C., Bancroft, J.D. (2013) "Bancroft's Theory and Practice of Histological Techniques", 7<sup>th</sup> ed., Churchill Livingstone, USA, 766p.
- Titov, V.Y., Osipov, A.N. (2017) Nitrite and nitroso compounds can serve as specific catalase inhibitors. *Redox Report*, **22**(2), 91-97. doi: 10.1080/13510002.2016.1168589.
- Wang, M., Dai, T., Li, S., Wang, W. (2022) Eugenol suppresses the proliferation and invasion of TNF- $\alpha$ -induced fibroblast-like synoviocytes via regulating NF- $\kappa$ B and COX-2. *Biochemical and Biophysical Research Communications*, **612**, 63-69. doi: 10.1016/j.bbrc.2022.04.074.
- Xue, T., Xue, Y., Fang, Y., Lu, C., Fu, Y., Lai, Z., Qin, X., et al. (2023) Exploring Myocardial Ischemia-Reperfusion Injury Mechanism of Cinnamon by Network pharmacology, molecular docking, and experiment validation. *Computational and Mathematical Methods in Medicine*, **2023**, 1066057. doi: 10.1155/2023/1066057.
- Yousef, H.N., Ibraheim, S.S., Ramadan, R.A., Aboelwafa, H.R. (2022) The ameliorative role of eugenol against silver nanoparticles-induced hepatotoxicity in male Wistar rats. *Oxidative Medicine and Cellular Longevity*, **2022**, 3820848. doi: 10.1155/2022/3820848.
- Zhu, J., Park, S., Kim, C.H., Jeong, K.H., Kim, W.J. (2023) Eugenol alleviates neuronal damage via inhibiting inflammatory process against pilocarpine-induced status epilepticus. *Experimental Biology and Medicine (Maywood)*, 15353702231151976. Under press. doi: 10.1177/15353702231151976.