



Biochemical and histopathological effect of probiotics on experimentally-induced liver fibrosis in rat

Mahfouz MK¹; Omnia. M. Abd El-Hamid¹; Emam MA², Menna. A. Bakr¹

¹ *Biochemistry and Clinical Biochemistry Department, Faculty of Veterinary Medicine, Benha University.*

² *Histology and Cytology Department, Faculty of Veterinary Medicine, Benha University, 13736 Egypt.*

ABSTRACT

The objective of the present study was to evaluate the biochemical effect of probiotics treatment on Thioacetamide (TAA) induced liver fibrosis in rats. Thirty white male Sprague Dewily rats of 8-10 weeks old and Weighing 150 to 200 g were used in the experiment. Rats were randomly divided in to 2 main groups, 1st group acts as normal control, 2nd group was injected with TAA intraperitoneally (200mg/kg b.wt) twice a week for 6 weeks for the induction of liver fibrosis, after that the 2nd group was subdivided into 2 subgroups 1st subgroup received no drugs and served as positive control, 2nd subgroup was treated with a daily dose of probiotics (0.0128×10⁹ bacteria per gram of rat body weight) which is equivalent to (135mg/kgb.wt) orally for 6 weeks. Blood samples were collected twice after 3 and 6 weeks of probiotics treatment for biochemical examination, then rats were decapitated and liver specimens were collected for histopathological examination. Intraperitoneal supplementation of TAA caused increase in serum level of AST, ALT, Tbil, Dbil and pro-inflammatory cytokines as TNF α and IL6, decrease in serum level of Albumin and total protein. Furthermore, histopathological examination revealed extensive degeneration, inflammatory infiltration and nodulation of the liver. Probiotics treatment revealed decrease in serum level of ALT, AST, Tbil, Dbil and pro-inflammatory cytokines as TNF α and IL6, decrease in serum level of Albumin and Total protein. Moreover, histopathological examination revealed mild inflammation and less nodulation of the hepatic parenchyma.

Keywords: TAA, Probiotics, TNF α , IL6, Liver fibrosis

(<http://www.bvmj.bu.edu.eg>)

(BVMJ-31(2): 248 -253, 2016)

1. INTRODUCTION

Hepatic fibrosis is the wound response to chronic hepatic injury, including viral infection, alcohol abuse and cholestasis. It's characterized by excessive production and deposition of extracellular matrix (ECM) molecules (Bataller and Brenner, 2005). It is thought to be a passive and irreversible process and this is due to the collapse of the hepatic parenchyma and its substitution with a collagen-rich tissue (Popper and Uenfriend, 1970). Oral and intraperitoneal administrations of TAA are both established methods in the generation of fibrosis and cirrhosis models in rats (Zhao et al., 2002). It is commonly used for the induction of fulminant hepatic failure (Bruck et al., 1999) and liver cirrhosis in animal models (Li et al., 2002). TAA causes oxidative damage associated liver injury. Therefore, there has been a considerable interest in the role of complementary and alternative medicines in the treatment of liver diseases. The elucidation of the cellular and molecular mechanisms responsible for the development and progression of the Hepatic

fibrosis (Pinzani, 1999) has provided a sound basis for development of pharmacologic strategies able to modulate the course of the disease (Fujimoto, 2000). Thioacetamide (TAA) is an organic compound which has the formula of CH₃CSNH₂. TAA is a thiono-sulphur containing compound, which prepared by treating acetamide with phosphorus pentasulphide. TAA a potent hepatotoxin, was first used to control the decay of citrus fruits especially orange and therefore, as a fungicide (Lee et al., 2003). Acute toxic effect of TAA is a dose dependent as single dose leads to liver injury specially centrilobular region with subsequent regenerative response (Chen et al., 2008). In addition, long term administration of thioacetamide is also an established technique for generating rat models of liver fibrosis and cirrhosis (Low et al., 2004). Probiotics are live microorganisms which when administered in adequate amount are benefit to health (Sanders et al., 2013). Presently, probiotics have a vital role in improving health for humans and are also used as

therapeutic, prophylactic and growth supplements in animal production (Anukam et al., 2005). Takei (2013) determined that, intake of probiotic reduce the incidence of liver enzyme abnormality. On the other side, treatment with probiotic exhibit a significant reduction in the serum level of TNF- α and IL-6 which act as marker of liver inflammation (Loguercio et al., 2005).

The goal of the present study was to evaluate the beneficial effect of probiotics on treating TAA induced hepatic fibrosis in rats by evaluating liver function test, pro inflammatory cytokines and histopathological examination.

2. MATERIAL AND METHOD

2.1. Rats and experimental design

Thirty white male Sprague Dewily rats of 8-10 weeks old and Weighing 150 to 200 gm were commercially obtained. They were housed in separate metal cages; fresh and clean drinking water was supplied. All animals were left for acclimatization before the beginning of the experiment. Rats were randomly divided in to 2 main groups, 1st group acted as normal control group, 2nd group was injected with TAA intraperitoneally (200 mg/kg bwt) (Chang-Chi et al., 2008), twice a week for 6 weeks for the induction of liver fibrosis. After that the 2nd group was subdivided into 2 subgroups. 1st subgroup received no drugs and served as positive control, 2nd subgroup was treated with a daily dose of probiotics (0.0128×10^9 bacteria per gram of rat body weight) (Gupta et al., 2013) which is equivalent to (135mg/kgb.wt) orally in drinking water (Velayudham et al., 2009).

Probiotics composition: The used probiotics obtained from Multipharm Company, it composed of a mixture of microorganisms namely Lactobacillus acidophilus, Lactobacillus plantarum, Lactobacillus casei, Lactobacillus bulgaricus, Bifidobacterium bifidum, Streptococcus thermophilus, Streptococcus faecium, Saccharomyces boulardii, Aspergillus oryzae, Torulopsis spp, Amylase and Xylanase enzymes, Lactose.

2.2. Blood samples:

Blood samples were collected after overnight fasting from all animal groups (control and experimental groups) twice after (3 and 6 weeks) from the onset of the treatment, samples were collected from retro-orbital plexus of eye, and then rats were decapitated for liver specimen removal. Blood samples allowed to clot by leaving it undisturbed in room temperature for 15-30

minutes. Serum samples are separated after centrifuging at 1800 rpm for 10 minutes then divided into small aliquots and stored at -20°C until examined.

2.3. Blood parameters:

Liver function tests (AST and ALT) was performed according to Murray (1984). Serum Total and Direct bilirubin according to Malloy and Evelyn (1937). Total protein concentration according to Josephson and Gyllensward (1957). Serum albumin concentration according to Young (1995). Serum IL6 according to Chan and Perlstein (1987), the mouse IL6 ELISA uses anti-mouse IL6 antibodies for solid phase (microtiter wells) immobilization and biotinylated anti- mouse IL6 antibodies. Serum Tumor necrosis factor- alpha (TNF α) according to Beyaert and Fires (1998), the BD OptEIAM test is a solid phase sandwich ELISA, it utilizes a monoclonal antibody specific for rat TNF coated on 96- well plate.

2.4. Tissue specimens:

After blood sampling, rats of each group were sacrificed by decapitation and the liver was rapidly excised clean by rinsing with isotonic saline, cleared blood and small pieces from the liver were immersed in 10% neutral buffered formalin for 48 h for histopathological examination; the fixed tissue were processed routinely, embedded in paraffin, sectioned, deparaffinized and rehydrated using the standard techniques according to Bancroft and Gamble (2002). The extent of degree of liver fibrosis was evaluated by assessing the morphological changes in the liver sections stained with hematoxylin and eosin (H&E) and Masson's trichrome stain.

2.5. Statistical analysis:

All the obtained data were analyzed and graphically represented using the statistical package for social science (IBM SPSS, 20.0 software, Duncan) for obtaining mean and standard deviation and error. The data were analyzed using one-way ANOVA to determine the statistical significance of differences among groups. Duncan's test was used for making a multiple comparison among the groups for testing the inter-grouping homogeneity.

3. RESULTS

3.1. Biochemical findings

The obtained data in table (1) showed that Rats injected with TAA- induced fibrosis caused a significant increase in the Serum levels of AST, ALT, T&D bilirubin, IL6 and TNF- α and decrease

in the serum levels of Alb and Total protein after 6 weeks from TAA injection as compared to normal control group. Treatment with probiotic revealed significant decrease in the serum levels of AST,

ALT, T&D bilirubin, IL6 and TNF- α and increase in the serum levels of Alb and Total protein observed at 3rd and 6th week compared with positive control.

Table (1). Effect of probiotics treatment on some blood parameters & some pro-inflammatory cytokines on liver fibrosis induced experimentally in rats.

Blood Parameter & Pro-inflammatory Cytokines	Control	TAA	TAA + PROB 3 Weeks	TAA + PROB 6 Weeks
AST (U/L)	21.75 \pm 1.93 ^d	74.33 \pm 9.90 ^a	40.67 \pm 2.40 ^b	30.75 \pm 1.49 ^{b,c,d}
ALT (U/L)	12.25 \pm 1.11 ^f	62.33 \pm 5.04 ^a	44.67 \pm 2.91 ^b	34.50 \pm 1.89 ^c
T.P (g/dl)	7.81 \pm 0.12 ^{a,b}	6.61 \pm 0.10 ^e	7.15 \pm 0.03 ^d	7.40 \pm 0.02 ^c
ALB (g/dl)	4.20 \pm 0.08 ^{a,b}	3.42 \pm 0.04 ^c	3.75 \pm 0.03 ^{a,b,c}	4.05 \pm 0.02 ^{a,b,c}
TBIL (mg/dl)	1.05 \pm 0.06 ^d	1.71 \pm 0.09 ^a	1.40 \pm 0.02 ^b	1.30 \pm 0.01 ^{b,c}
DBIL (mg/dl)	0.27 \pm 0.02 ^{d,e}	0.59 \pm 0.06 ^a	0.44 \pm 0.03 ^b	0.34 \pm 0.02 ^{c,d}
TNF α (Pg/ml)	25.03 \pm 1.57 ^d	74.67 \pm 3.74 ^a	49.80 \pm 2.43 ^b	46.10 \pm 6.80 ^{b,c}
IL6 (Pg/ml)	53.07 \pm 4.20 ^e	106.37 \pm 4.19 ^a	84.07 \pm 0.62 ^{b,c}	85.39 \pm 8.33 ^b

Data are represented as (Mean \pm S.E). S.E = Standard error. Mean values with different superscript letters in the same columns are significantly different at ($p < 0.05$).

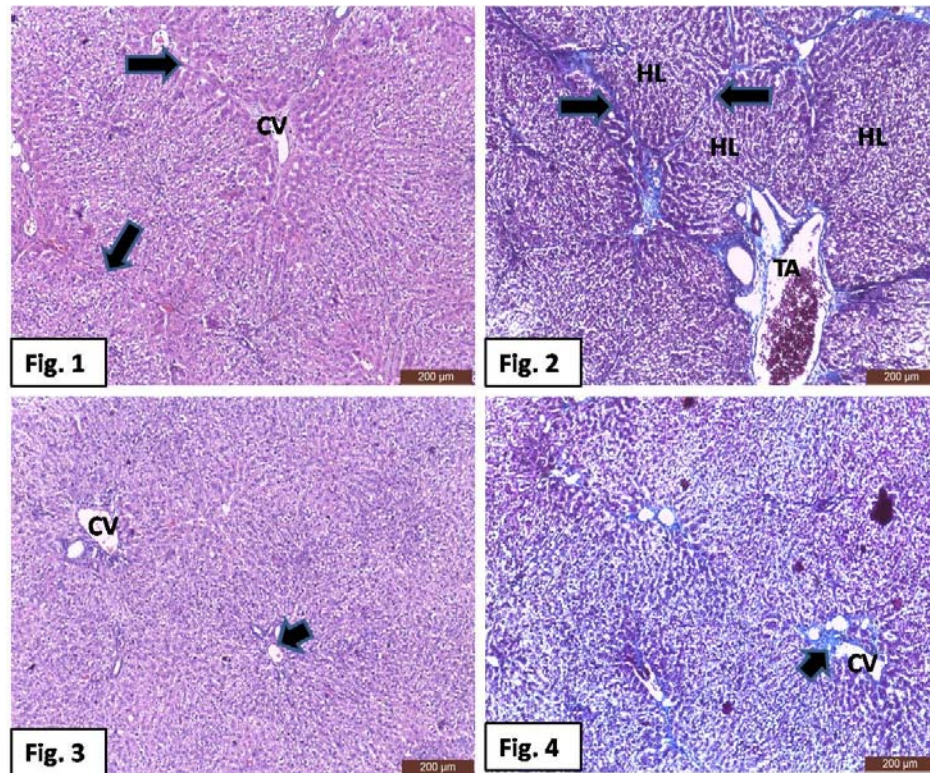


Fig. 1: Photomicrograph of liver from rats treated with TAA showing: thick interlobular connective septa (arrow) and around the central veins (CV). H&E stain, Scale bar = 200 μ m. Fig. 2: Photomicrograph of liver from rats treated with TAA showing: nodulation of hepatic parenchyma (arrows) into hepatic lobules (HL) and deposition of fibrous tissue in triad area (TA). Masson's trichrome stain. Scale bar = 200 μ m. Fig. 3: Photomicrograph of liver from rats treated with TAA and probiotics showing: fewer amount of fibrous tissue (arrow) around the central vein (CV) compared to Fig. 1. H&E stain. Scale bar = 200 μ m. Fig. 4: Photomicrograph of liver from rats treated with TAA and probiotics showing: fewer amount of fibrous tissue (arrow) around the central vein (CV) compared to Fig. 2. Masson's trichrome stain. Scale bar = 200 μ m.

3.2. Histopathological findings:

3.2.1. Rats treated with TAA (positive control group).

Liver section taken from this group revealed an abnormal architecture. It characterized by thick interlobular connective tissue septa and around the central veins (Fig. 1). The sections stained with Masson's trichrome demonstrated nodular parenchyma that surrounded by fibrous septa (Fig. 2). Moreover, disarrangement, vacuolar degeneration, and inflammatory cell collections can be seen (Fig. 1).

3.2.2. Rats treated with TAA + probiotic.

Liver sections obtained from this group revealed a slight reduction of fibrous tissue compared with TAA group. Liver showed shorter and fewer number of interlobular septa and fibrous tissue around the central vein (Figs. 3&4)

4. DISCUSSION:

The obtained data demonstrated in table 1 revealed that, a significant increase in ALT, AST, T&D bilirubin, pro-inflammatory cytokines (TNF α & IL6) and decrease in serum levels of Albumin and Total protein were observed in rats injected with TAA for 6 weeks when compared with normal control group. These results come in accordance with Kumar et al. (2007) who reported that rats treated with TAA showed atypical signs of liver dysfunction as evident from the increased serum ALT, AST. Moreover, Galisteo et al. (2006) found that, the injection of rats with TAA produce a significant decrease of plasma T.P and albumin in relation to control normal group. In addition, the significant elevation of serum level of TNF α & IL6 in TAA injected rats in comparison with normal control group come in accordance with Baeuerle and Baichwal (1997) who stated that, TAA induce a significant increase in hepatic NF-kBp65 and COX-2 expression together with significant elevation in tissue levels of the TNF- α and IL-1B. The hepatotoxic effect of TAA is due to the bioactivation of TAA by the mixed function oxidase system in the body (Baskaran et al., 2010) attributed the bioactivation of TAA cyt. p450 and/or flavin-containing monooxygenase (FMO) to the reactive metabolite. During the biotransformation of TAA, both of FMOs and cyt. p450 reduce dioxygen to superoxide anion, which is catalyzed to form hydrogen peroxide (Low et al., 2004), an increase in MDA (So et al., 2002) and disappearance of tetraploid hepatocytes in liver cells (Low et al., 2004).

Probiotics was found to be beneficial in liberating tropic factors, enzymes and proteins during their intestinal transit so contribute to improve the host immune, defense, digestion and absorption of nutrients (Buts and De Keyser, 2006). Moreover, a significant improvement in Liver function test is observed in probiotics - treated rats where there is a marked decrease in serum level of AST and ALT and these results come in accordance with Tilg and Hotamisligil (2006) who revealed that a significant decrease in serum ALT and AST by treatment with probiotics due to protective effect on liver. In addition, Zang et al. (2006) found that, a significant decrease in serum ALT and AST activities by treatment with probiotics strains of some lactobacilli help prevent low grade inflammation and liver disease.

Also, there is a reduction in serum Total and Direct bilirubin, increase in T.P and Albumin was observed. In addition, Probiotics treatment in the current study improved liver damage and normalized the activation of the main pathways involved in inflammation after damage produced by TAA to liver tissue, as observed by a decreased TNF- α and IL6 levels. These data are consistent with previous studies which demonstrated that, chronic treatment with probiotics reduce the progression of fibrosis in a model of steatohepatitis in rats (Velayudham et al., 2009). Bacterial translocation and a pro-inflammatory state are relevant in promoting liver damage in liver diseases, including cirrhosis (Wiest et al., 2014).

Histopathological finding of the present study showed that the liver of rat treated with TAA revealed an abnormal architecture in comparison to normal liver. The hepatic damage after TAA administration varies depending on the dose. It may range from the parenchymal cell necrosis and liver cell proliferation to the production of pseudo lobules and nodular cirrhosis (Sadasivan et al., 2006).

In the present study, liver of rat treated with TAA is characterized by nodular parenchyma that surrounded by fibrous septa. Such finding was in consistence with Alshawsh et al. (2011) and Al-Attar (2012), in mice treated with TAA. Also, the liver sections showed disarrangement, degeneration of normal hepatic cells, vacuolar degeneration, necrosis, and inflammatory cell infiltration with intense centrilobular necrosis and congestion and destruction of central vein that was similar to finding of Salama et al. (2012) and Rao et al. (2014).

Liver sections obtained from the group injected with TAA and treated with probiotic revealed a slight reduction of fibrous tissue compared with TAA group. In the probiotic group, the liver

damage caused by TAA was improved and collagen deposits were slightly reduced. However, Giuseppe et al. (2013) mentioned that, liver specimen which obtained from the group injected with ccl4 and treated with FB (*L. paracasei* B21060, L- glutamine, Arabinogalactan and Xilo-oligosaccharides) revealed a marked reduction of fibrous tissue compared with ccl4 group.

5. CONCLUSION

Based on the results in the current research, treatment with TAA induce chronic liver damage in rats, as was to be expected. Probiotics has antifibrotic effect as it's administration protect liver from damage by reducing serum level of AST, ALT, T&D bilirubin, TNF α & IL6, increasing serum level of Albumin and T.P. In addition, probiotics ameliorate the fibrotic effect of TAA, as it shows a decrease in the fibrous tissue compared with TAA treated group.

6. REFERENCES

- Al-Attar, A.M., 2012. Attenuating effect of Ginkgo biloba leaves extract on liver fibrosis induced by thioacetamide in mice. *J Biomed Biotechnol* 2012, 761450.
- Alshawsh, M.A., Abdullah, M.A., Ismail, S., Amin, Z., 2011. Hepatoprotective Effects of *Orthosiphonstamineus* Extract on Thioacetamide-Induced Liver Cirrhosis in Rats. *Evid Based Complement Alternat Med* 1-6.
- Anukam, K.C., Osazuwa, E.O., Greigor, R., 2005. Knowledge of probiotics by Nigerian clinicians. *Int. J. Nat Appl. Sci*, 1, 65 – 69.
- Baeuerle, P.A., Baichwal, V.R., 1997. NF-kappa B as a frequent target for immunosuppressive and anti-inflammatory molecules. *Advances in Immunology*, Vol 65 65, 111-137.
- Bancroft, J.D., Gamble, M., 2002. *Theory and Practice of Histological Techniques*, 5th ed. Churchill Livingstone, London, New York and Philadelphia.
- Baskaran, Y., Periyasamy, V., Venkatraman, A.C., 2010. Investigation of antioxidant, anti-inflammatory and DNA-protective properties of eugenol in thioacetamide-induced liver injury in rats. *Toxicology* 268, 204-212.
- Bataller, R., Brenner, D.A., 2005. Liver fibrosis. *J. ClinInves* 115, 209–218.
- Beyaert, R., Fires, W., 1998. Tumor Necrosis Factor and Lymphotoxin. In *Cytokines*, A.R.M.-S. a.R. Thorpe. Academic Press, San Diego.
- Bruck, R.H., Aeed, H., Shirin, Z., 1999. The hydroxyl radical scavengers dimethylsulfoxide and dimethylthiourea protect rats against thioacetamide induced hepatic failure. *J. Hepatol.* 31, 27-38.
- Buts, J.P., De Keyser, N., 2006. Effects of *Saccharomyces boulardii* on intestinal mucosa. *Dig Dis Sci* 51, 1485-1492.
- Chan, D.W., Perlstein, N.T., 1987. *Immunoassay: A Practical Guide*. Academic Press, New York.
- Chang-Chi, H., Hsun-Lang, F., Wen-Chuan, L., 2008. Inhibitory effect of *Solanum nigrum* on thioacetamide-induced liver fibrosis in mice. *Journal of Ethnopharmacology* 119, 117-121.
- Chen, T.M., Subeq, Y.M., Lee, R.P., Chiou, T.W., Hsu, B.G., 2008. Single dose intravenous thioacetamide administration as a model of acute liver damage in rats. *International Journal of Experimental Pathology* 89, 223-231.
- Fujimoto, J., 2000. Gene therapy for liver fibrosis. *J Gastro Hepatol* 15, D33-D36.
- Galisteo, M., Suarez, A., Montilla, M.P., Torres, M.I., Gil, A., Navarro, M.C., 2006. Protective Effect of *Rosmarinustomentosus* ethanol extract on thioacetamide-induced liver cirrhosis in rats. *Phytomedicine* 13, 101-108.
- Giuseppe, D.A., Rita, C., Concetta, T., Giovanna, M., Alessandro, F., Annalisa, L.D.M., Enzo, G., Maria, L.C., Marilena, C., Nicola, C., Marco, R., Lorenzo, M., Carmela, L., 2013. Symbiotic formulation in experimentally induced liver fibrosis in rats: intestinal microbiota as a key point to treat liver damage. *Liver Int* 33, 687-697.
- Gupta, N., Kumar, A., Sharma, P., 2013. Effects of the adjunctive probiotic VSL#3 on portal haemodynamics in patients with cirrhosis and large varices: a randomized trial. *Liver Int* 33, 1148–1157.
- Josephson, B., Gyllensward, C., 1957. Enhanced cardiac enzyme profile. *Cli. lab. med* Dec. 9, 689-716.
- kumar, S.A., Tasduq, D.K., Gupta, S., Bhardwaj, Johri, R.K., 2007. 'Reversal of hepatotoxin-induced prefibrogenic events by *EmbllicaOfficinalis*-a histological study". *Indian Journal of Experimental Biology* 45, 626-629.
- Lee, J.W., Shin, K.D., Lee, M., Kim, E.J., Han, S.S., Han, M.Y., Ha, H., Jeong, T.C., Koh,

- W.S., 2003. Role of metabolism by flavin-containing monooxygenase in thioacetamide-induced immunosuppression. *Toxicol Lett* 136, 163-172.
- Li, X.N., Benjamin, I.S., Alexander, B., 2002. Reproducible production of thioacetamide-induced macronodular cirrhosis in the rat with no mortality. *Journal of Hepatology* 36, 488-493.
- Loguercio, C., Federico, A., Tuccillo, C., Terracciano, F., D'Auria, M.V., De Simone, C., Del Vecchio Blanco, C., 2005. Beneficial effects of a probiotic VSL#3 on parameters of liver dysfunction in chronic liver diseases. *J Clin Gastroenterol* 39, 540-543.
- Low, T.Y., Leow, C.K., Salto-Tellez, M., Chung, M.C., 2004. A proteomic analysis of thioacetamide-induced hepatotoxicity and cirrhosis in rat livers. *Proteomics* 4, 3960-3974.
- Malloy, H.M., Evelyn, K., 1937. *J. boil. Chem.* 119, 481.
- Pinzani, M., 1999. Liver fibrosis. *Springer Semin Immunopathol* 21, 475-490.
- Popper, H., Uenfriend, S., 1970. Hepatic fibrosis. Correlation of biochemical and morphologic investigations. *Am. J. Med.* 49, 707-721.
- Rao, S.V., Einstein, J.W., Das, K., 2014. Hepatoprotective and antioxidant activity of *Lannea coromandelica* Linn. on thioacetamide induced hepatotoxicity in rats. *International Letters of Natural Sciences* 3, 30-43.
- Sadasivan, S., Latha, P.G., Sasikumar, J.M., Rajashekar, S., Shyamal, S., Shine, V.J., 2006. Hepatoprotective studies on *Hedyotis corymbosa* (L.) Lam. *J Ethnopharmacol* 106, 245-249.
- Salama, S.M., Bilgen, M., Al Rashdi, A.S., Abdulla, M.A., 2012. Efficacy of *Boesenbergia rotunda* Treatment against Thioacetamide-Induced Liver Cirrhosis in a Rat Model. *Evid Based Complement Alternat Med* 2012, 137083.
- Sanders, M.E., Guarner, F., Guerrant, R., Holt, P.R., Quigley, E.M.M., Sartor, R.B., Sherman, P.M., Mayer, E.A., 2013. An update on the use and investigation of probiotics in health and disease. *Gut* 62, 787-796.
- So, E.C., Wong, K.L., Huang, T.C., Tasi, S.C., Liu, C.F., 2002. Tetramethyl pyrazine protects mice against thioacetamide-induced acute hepatotoxicity. *J. Biomed. Sci.* 9, 410-414.
- Takei, Y., 2013. Treatment of non-alcoholic fatty liver disease. *J Gastroenterol Hepatol* 28, 79-80.
- Tilg, H., Hotamisligil, G.S., 2006. Nonalcoholic fatty liver disease: Cytokine-adipokine interplay and regulation of insulin resistance. *Gastroenterology* 131, 934-945.
- Velayudham, A., Dolganiuc, A., Ellis, M., Petrasek, J., Kodys, K., Mandrekar, P., Szabo, G., 2009. VSL#3 probiotic treatment attenuates fibrosis without changes in steatohepatitis in a diet-induced nonalcoholic steatohepatitis model in mice. *Hepatology* 49, 989-997.
- Wiest, R., Lawson, M., Geuking, M., 2014. Pathological bacterial translocation in liver cirrhosis. *J Hepatol* 60, 197-209.
- Young, D.S., 1995. *Effects of Drugs on Clinical Laboratory Tests*, 4th ed. AACC Press, Washington, D.C.
- Zang, M., Xu, S., Maitland-Toolan, K.A., Zuccollo, A., Hou, X., Jiang, B., Wierzbicki, M., Verbeuren, T.J., Cohen, R.A., 2006. Polyphenols stimulate AMP-activated protein kinase, lower lipids, and inhibit accelerated atherosclerosis in diabetic LDL receptor-deficient mice. *Diabetes* 55, 2180-2191.
- Zhao, G., Nakano, K., Chijiwa, K., 2002. Inhibited activities in CCAAT/enhancer-binding protein, activating protein-1 and cyclins after hepatectomy in rats with thioacetamide-induced liver cirrhosis. *Biochem Biophys. Res. Commun* 292, 474-481.