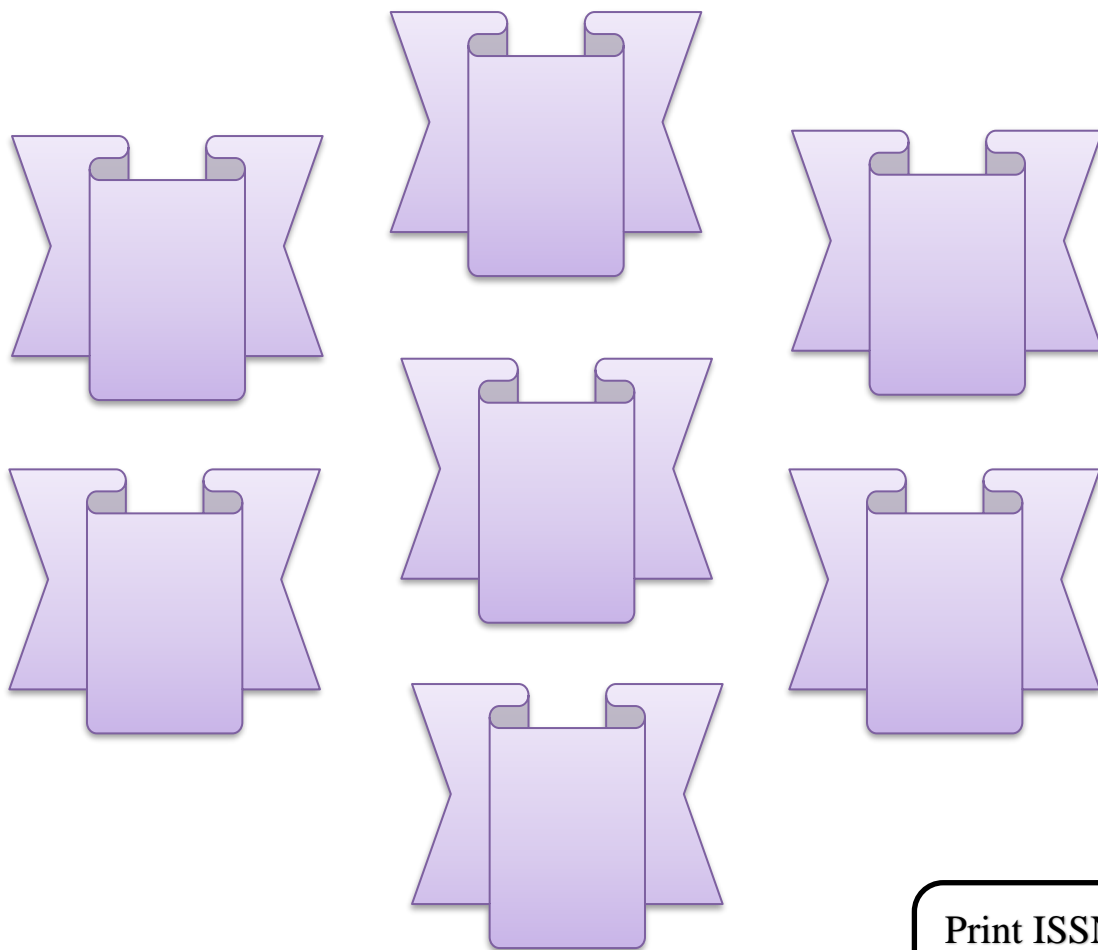


INTERNATIONAL JOURNAL OF MEDICAL ARTS



Volume 5, Issue 7, July 2023

<https://ijma.journals.ekb.eg/>



Print ISSN: 2636-4174

Online ISSN: 2682-3780



Available online at Journal Website
<https://ijma.journals.ekb.eg/>
 Main Subject [Cardiology]



Original Article

Computed Tomographic Predictors of Conduction Disturbances Following Transcatheter Aortic Valve Implantation

Mahmoud Abdelshafy ^{*1}, Mansour Mohammad Mustafa ¹, Islam Shawky ¹, Abdelhamid Ismail Abdelhamid ¹, Sameh Mosaad Abdul-Wahab ²

¹ Department of Cardiology, Faculty of Medicine, Al-Azhar University, Cairo, Egypt

² Department of Cardiology, Faculty of Medicine, Modern University of Technology and Information (MTI), Cairo, Egypt

ABSTRACT

Article information

Received: 13-06-2023

Accepted: 15-08-2023

DOI: 10.21608/IJMA.2023.217334.1702.

*Corresponding author

Email: mahmoudabdala7@gmail.com

Citation: Abdelshafy M, Mustafa MM, Shawky I, Abdelhamid AI, Abdul-Wahab SM. Computed Tomographic Predictors of Conduction Disturbances Following Transcatheter Aortic Valve Implantation. IJMA 2023 July; 5 [7]: 3465-3469. doi: 10.21608/IJMA.2023.217334.1702.

Background: It is not uncommon for patients who undergo TAVI to experience conduction abnormalities that require the placement of a new permanent pacemaker [PPM]. However, using a comprehensive multi-slice computed tomography [MSCT] analysis can aid in predicting and planning the procedure for optimal results.

Aim of the work: Our objective was to examine the MSCT predictors of conduction disturbances that necessitate PPM after TAVI.

Patients and Methods: We enrolled patients who had undergone TAVI with the Evolut platform. A comprehensive MSCT analysis was conducted, which included measuring the length of the membranous septum [MS], semi-quantitative analysis of the aortic leaflets, and assessment of mitral annulus calcification.

Results: Among 100 patients [age, 81.8±5.1 years; 32% female, median EuroSCORE II 2.8[1.8, 4.4]], 10[10%] required PPM at discharge. Compared with patients who did not require a new PPM, those who did have shorter membranous septum [MS] length and more frequent ≥moderate mitral annular calcification.

Conclusion: The length of the membranous septum and the severity of mitral annular calcification have been determined to be important factors in predicting the need for a permanent pacemaker implantation following transcatheter aortic valve implantation.

Keywords: TAVI; Conduction disturbance; Pacemaker implantation; Computed tomography.



This is an open-access article registered under the Creative Commons, ShareAlike 4.0 International license [CC BY-SA 4.0] [<https://creativecommons.org/licenses/by-sa/4.0/legalcode>].

INTRODUCTION

Transcatheter aortic valve implantation [TAVI] is a therapy that has been proven to be reliable for elderly individuals with symptomatic severe aortic stenosis. This applies to all patients, regardless of their surgery risk level ^[1,2]. Survival after TAVI can be impacted by five major complications. These complications include moderate or greater paravalvular leakage, major vascular complications, stroke, acute renal injury, and conduction abnormalities that require permanent pacemaker implantation [PPM] ^[3]. It is important to prevent these five complications during the procedure as they can significantly impact mortality post-TAVI ^[4].

The development of new conduction abnormalities, especially left bundle branch block [LBBB], and the implantation of a new PPM have been linked to higher mortality rates and increased hospitalizations due to heart failure within one year ^[5]. Inserting a new TAVI device can compress the conduction system, leading to local ischemia, oedema, and haemorrhage. These problems have the potential to damage the calcific conductive system ^[6].

When comparing the first-generation self-expanding CoreValve system to the balloon-expandable counterparts, the frequency of new PPM was five times higher ^[7,8].

By incorporating multislice computed tomography [MSCT] in the standard preoperative imaging and planning process before TAVI, there is now greater precision in valve sizing and predicting potential complications. Additionally, the evaluation of vascular access, such as the femoral artery and the entire aorta, allows for the consideration of alternative access routes if required ^[9].

Previously identified predictors of new PPM post-TAVI are older age, right bundle branch block [RBBB] on baseline electrocardiogram [ECG], higher mean aortic valve gradient, calcification including left ventricular outflow tract [LVOT] or mitral annulus, membranous septum [MS] length and implantation depth [ID] ^[10, 11].

The aim of this study was to investigate the MSCT factors that cause conduction disturbance resulting in the need for a new PPM after TAVI upon discharge.

PATIENTS AND METHODS

The study involved 100 patients who had severe aortic stenosis and were deemed suitable for TAVI using the Medtronic Evolut R/PRO/PRO+ systems, as determined by the heart team. The study was conducted at University Hospital Galway in Ireland between October 2019 and August 2022. Patients with a prior PPM and those undergoing valve-in-valve implantation were excluded. The study received approval from the Ethical Research Board [ERB] at the Faculty of Medicine, Al-Azhar University in Cairo, Egypt and was adhered to the guidelines of the Declaration of Helsinki.

Pre-TAVI Workup: Pre-procedure workup included baseline ECG, echocardiography [TTE], and multislice computed tomography [MSCT]. The heart team determined eligibility for TAVI in all cases. After undergoing TAVI, patients received routine in-hospital care that involved daily ECG monitoring until their discharge. Additionally, all patients underwent echocardiography as part of their post-TAVI care.

The MSCT prior to TAVI was obtained and evaluated in accordance with the SCCT guidelines ^[12]. The reconstruction and analysis were performed using 3mensio software [Pie Medical Imaging, the Netherlands]. The degree of calcification at the aortic cusps and left ventricular outflow tract was assessed visually and scored on a scale of 0 to 3, with 0 indicating no calcification, 1 indicating mild calcification, 2 indicating moderate calcification, and 3 indicating severe calcification. Mitral annular calcification [MAC] is classified into four grades: grade 0 indicates the absence of MAC, grade 1 indicates mild MAC affecting up to 25% of the annulus, grade 2 indicates moderate MAC affecting 25% to 50% of the annulus, and grade 3 indicates severe MAC affecting more than 50% of the annulus ^[13].

To determine the MS length, the thinnest portion of the interventricular septum between the left ventricular outflow tract [LVOT] and the right atrium was measured using a perpendicular co-planar view. This measurement was taken from the lowest point of the non-coronary cusp to the tip of the muscular septum ^[14, 15].

Statistical analysis: Numbers and percentages were used to present categorical variables, while mean \pm standard deviation [SD]

or median and interquartile range [IQR] were used to report continuous variables as appropriate. To test the normality of the continuous data, the Shapiro-Wilk test was employed. The MSCT data was compared based on the presence or absence of new PPM. Significance was determined by a p-value lower than 0.05. The analysis of statistics was performed on SPSS Statistics for Windows version 25.0 [SPSS, Inc., USA].

RESULTS

The patients' mean age was 82 years, with 32 female patients included in the study. The mean EuroSCORE II was 2.8. All patients done via femoral approach.

Conduction Disturbance: At the time of discharge, the percentage of patients who required new PPM was 10% [10 out of 100]. Four of these 10 patients [40%] had a pre-existing RBBB. All PPMs were inserted due to complete heart block except for one patient with

new LBBB [QRS duration =179 msec] and 1st degree AV block [PR duration = 330 msec].

MSCT predictors of new PPM post TAVI: We divided the study participants into two groups based on whether they developed a conduction disturbance that necessitated the insertion of a new permanent pacemaker. The MSCT analysis showed no significant statistical difference between the two groups, except for the length of MS and the frequency of mitral annular calcification. The details shown in table [1].

Compared to patients who did not require a new PPM, PPM-recipients were characterized by a shorter MS length [1.8 [0.8, 2.6] vs 3 [2.2, 3.8], p=0.002] and Increased frequency of \geq moderate mitral annular calcification [80% vs 34%, p=0.005].

Examples of clinical cases: An example of CT analysis of patient who did not need a PPM post-TAVI is shown in figure [1]. and another example of patient who required PPM post-TAVI is shown in figure [2].

Table [1]: Computed tomographic characteristics

| | All patients | PPM | No PPM | P value |
|---|------------------|-------------------|------------------|---------|
| | n = 100 | n = 10 | n = 90 | |
| Annulus minimum diameter [mm] | 21.7 \pm 2.4 | 21.1 \pm 2.5 | 21.8 \pm 2.4 | 0.38 |
| Annulus maximum diameter [mm] | 29 \pm 2.8 | 29.7 \pm 3.3 | 28.9 \pm 2.8 | 0.37 |
| Perimeter-derived annulus diameter [mm] | 25.6 \pm 2.3 | 25.7 \pm 2.8 | 25.6 \pm 2.2 | 0.84 |
| Area-derived annulus diameter [mm] | 25 \pm 2.2 | 25 \pm 2.7 | 24.9 \pm 2.1 | 0.91 |
| Annulus perimeter [mm] | 80.5 \pm 7.2 | 80 \pm 8.2 | 80.5 \pm 7.2 | 0.91 |
| Annulus area [mm ²] | 494.5 \pm 90.3 | 496.7 \pm 105.1 | 494.2 \pm 89.1 | 0.93 |
| LCA height [mm] | 16.3 \pm 3.3 | 16.3 \pm 3.9 | 16.3 \pm 3.3 | 0.99 |
| RCA height [mm] | 18.9 \pm 3.5 | 17.7 \pm 3.4 | 19 \pm 3.5 | 0.23 |
| Aortic root angulation \geq 49 | | 1 [10%] | 35 [39%] | 0.95 |
| Aortic root angulation [°] | 46.3 \pm 9.4 | 48.3 \pm 5.2 | 46 \pm 9.7 | 0.27 |
| Membranous septum length [mm] | 2.8 [2.1, 3.8] | 1.8 [0.8, 2.6] | 3 [2.2, 3.8] | 0.002 |
| AV calcification \geq moderate | 80 [80%] | 9 [90%] | 71 [79%] | 0.41 |
| LVOT calcification \geq moderate | 24 [24%] | 3 [30%] | 21 [23%] | 0.64 |
| MAC \geq moderate | 39 [39%] | 8 [80%] | 31 [34%] | 0.005 |



Figure [1]: Example of CT analysis of patient who did not need a PPM post-TAVI. The annular dimension CT analysis [A] with long membranous septum length [B] and no mitral annular calcification [C]

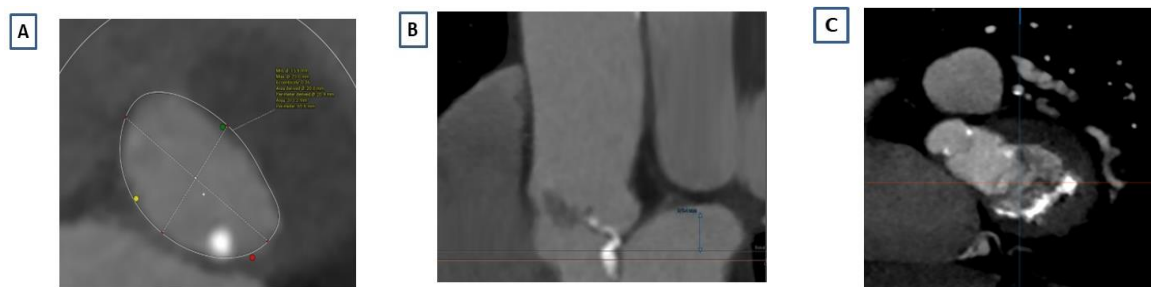

Figure [2]: Example of CT analysis of patient who required PPM post-TAVI. The annular dimension CT analysis [A] with short membranous septum length [B] and severe mitral annular calcification [C]

DISCUSSION

This study explores predictors of PPM-requirement post-TAVI with a contemporary self-expandable platform. The main findings are: 1] At discharge, the rate of new PPM implantation was 10%, 2] MS length, and severity of MAC had found to be predictors of conduction disturbances requiring new PPM post-TAVI at discharge.

During or after TAVI, the conductive system proximity to the aortic annulus makes them vulnerable to conduction disturbances caused by tissue inflammation, oedema, or ischemia [6].

The rate of new PPM in our study was comparable with new PPM rates reported in the observational studies involving the newer generation of Evolut platform [15, 16].

Consistent with data from prior studies across different TAVI platforms, anatomical factors [such as MAC severity and MS length] have been recognized as a major determinant of the risk of new PPM implantation [10, 11].

The INTERSECT registry analysed the effect of MS length on pacemaker requirement post-TAVI among 1811 patients utilizing various TAVI devices. The study revealed that MS length was a significant predictor of PPM for all TAVI platforms except for the ACURATE neo [17].

These above-mentioned predictors in our study or other studies should guide the optimal procedural planning of the procedure, discussion of the risk of new PPM with the patients and include this risk beside the surgical risk score during the heart team discussion. When planning a TAVI procedure, it's crucial to consider device selection, implantation depth, the use of balloon

dilation, ensuring the pacing lead is secure before the procedure, and tele monitoring after the procedure [10, 18]. Additionally, it's important to keep in mind that high implantation can increase the risk of valve embolization, as well as coronary obstruction or difficult coronary access post TAVI [16]. The goal should be to achieve a successful TAVI procedure while maintaining a low rate of new PPM.

Limitations: Our study was carried out at a singular location and involved a relatively limited number of patients, which comes with the inherent limitations of this type of study. The volume of aortic valve, LVOT and mitral annular calcification were not measured, and we did a semi-quantitative assessment only. The Evolut series were the only TAVI devices used in our study and no comparison with other TAVI devices e.g. Sapien series or ACURATE neo platform.

Conclusion: Membranous septum length and mitral annular calcification severity were identified to be significant predictors of new permanent pacemaker implantation after transcatheter aortic valve implantation. Therefore, a comprehensive MSCT analysis could help in the predication and risk stratification of the new PPM rate post TAVI.

Conflict of Interest and Financial Disclosure: None.

REFERENCES

1. Popma JJ, Deeb GM, Yakubov SJ, Mumtaz M, Gada H, O'Hair D, et al.; Evolut Low Risk Trial Investigators. Transcatheter Aortic-Valve Replacement with a Self-Expanding Valve in Low-Risk Patients. *N Engl J Med.* 2019;380[18]:1706-1715. doi: 10.1056/NEJMoa1816885.
2. Mack MJ, Leon MB, Thourani VH, Makkak R, Kodali SK, Russo M, et al.; PARTNER 3

- Investigators. Transcatheter Aortic-Valve Replacement with a Balloon-Expandable Valve in Low-Risk Patients. *N Engl J Med.* 2019;380[18]:1695-1705. doi: 10.1056/NEJMoa1814052.
3. Grube E, Sinning JM. The "Big Five" Complications After Transcatheter Aortic Valve Replacement: Do We Still Have to Be Afraid of Them? *JACC Cardiovasc Interv.* 2019 Feb 25;12[4]:370-372. doi: 10.1016/j.jcin.2018.12.019.
 4. Arnold SV, Zhang Y, Baron SJ, McAndrew TC, Alu MC, Kodali SK, *et al.* Impact of Short-Term Complications on Mortality and Quality of Life After Transcatheter Aortic Valve Replacement. *JACC Cardiovasc Interv.* 2019 Feb 25;12[4]:362-369. doi: 10.1016/j.jcin.2018.11.008.
 5. Faroux L, Chen S, Muntané-Carol G, Regueiro A, Philippon F, Sondergaard L, *et al.* Clinical impact of conduction disturbances in transcatheter aortic valve replacement recipients: a systematic review and meta-analysis. *Eur Heart J.* 2020;41[29]:2771-2781. doi: 10.1093/eurheartj/ehz924.
 6. Moreno R, Dobarro D, López de Sá E, Prieto M, Morales C, Calvo Orbe L, *et al.* Cause of complete atrioventricular block after percutaneous aortic valve implantation: insights from a necropsy study. *Circulation.* 2009 Aug 4;120[5]:e29-30. doi: 10.1161/CIRCULATIONAHA.109.849281.
 7. van Rosendael PJ, Delgado V, Bax JJ. Pacemaker implantation rate after transcatheter aortic valve implantation with early and new-generation devices: a systematic review. *Eur Heart J.* 2018;39[21]:2003-2013. doi: 10.1093/eurheartj/ehx785.
 8. Auffret V, Puri R, Urena M, Chamandi C, Rodriguez-Gabella T, Philippon F, Rodés-Cabau J. Conduction Disturbances After Transcatheter Aortic Valve Replacement: Current Status and Future Perspectives. *Circulation.* 2017;136[11]:1049-69. doi: 10.1161/CIRCULATIONAHA.117.028352.
 9. Ng VG, Hahn RT, Nazif TM. Planning for Success: Pre-procedural Evaluation for Transcatheter Aortic Valve Replacement. *Cardiol Clin.* 2020 Feb;38[1]:103-113. doi: 10.1016/j.ccl.2019.09.013.
 10. Glikson M, Nielsen JC, Kronborg MB, Michowitz Y, Auricchio A, Barbash IM, *et al.*; ESC Scientific Document Group. 2021 ESC Guidelines on cardiac pacing and cardiac resynchronization therapy: Developed by the Task Force on cardiac pacing and cardiac resynchronization therapy of the European Society of Cardiology [ESC] With the special contribution of the European Heart Rhythm Association [EHRA]. *Rev Esp Cardiol [Engl Ed].* 2022;75[5]:430. doi: 10.1016/j.rec.2022.04.004.
 11. Sannour Y, Krishnaswamy A, Kumar A, Puri R, Tarakji KG, Bazarbashi N, *et al.* Incidence, Predictors, and Implications of Permanent Pacemaker Requirement After Transcatheter Aortic Valve Replacement. *JACC Cardiovasc Interv.* 2021 Jan 25;14[2]:115-134. doi: 10.1016/j.jcin.2020.09.063.
 12. Blanke P, Weir-McCall JR, Achenbach S, Delgado V, Hausleiter J, Jilaihawi H, *et al.* Computed Tomography Imaging in the Context of Transcatheter Aortic Valve Implantation [TAVI]/Transcatheter Aortic Valve Replacement [TAVR]: An Expert Consensus Document of the Society of Cardiovascular Computed Tomography. *JACC Cardiovasc Imaging.* 2019 Jan;12[1]:1-24. doi: 10.1016/j.jcmg.2018.12.003.
 13. Higgins J, Mayo J, Skarsgard P. Cardiac computed tomography facilitates operative planning in patients with mitral calcification. *Ann Thorac Surg.* 2013 Jan;95[1]:e9-11. doi: 10.1016/j.athoracsur.2012.07.059.
 14. Hokken TW, van Wiechen MP, Ooms JF, El Azzouzi I, de Ronde M, Kardys I, *et al.* Impact of Interventricular membranous septum length on pacemaker need with different transcatheter aortic valve implantation systems. *Int J Cardiol.* 2021 Jun 15;333:152-158. doi: 10.1016/j.ijcard.2021.02.080.
 15. Jilaihawi H, Zhao Z, Du R, Staniloae C, Saric M, Neuburger PJ, *et al.* Minimizing Permanent Pacemaker Following Repositionable Self-Expanding Transcatheter Aortic Valve Replacement. *JACC Cardiovasc Interv.* 2019;12[18]:1796-807. doi: 10.1016/j.jcin.2019.05.056.
 16. Chen YH, Chang HH, Liao TW, Leu HB, Chen IM, Chen PL, Lin SM. Membranous septum length predicts conduction disturbances following transcatheter aortic valve replacement. *J Thorac Cardiovasc Surg.* 2022;164:42-51.e42. doi: 10.1016/j.jtcvs.2020.07.072
 17. Hokken TW, Muhemin M, Okuno T, Veulemans V, Lopes BB, Beneduce A, *et al.* Impact of membranous septum length on pacemaker need with different transcatheter aortic valve replacement systems: The INTERSECT registry. *J Cardiovasc Comput Tomogr.* 2022 Nov-Dec;16[6]:524-530. doi: 10.1016/j.jcct.2022.07.003.
 18. Lilly SM, Deshmukh AJ, Epstein AE, Ricciardi MJ, Shreenivas S, Velagapudi P, Wyman JF. 2020 ACC Expert Consensus Decision Pathway on Management of Conduction Disturbances in Patients Undergoing Transcatheter Aortic Valve Replacement: A Report of the American College of Cardiology Solution Set Oversight Committee. *J Am Coll Cardiol.* 2020 Nov 17;76[20]:2391-2411. doi: 10.1016/j.jacc.2020.08.050.



International Journal

<https://ijma.journals.ekb.eg/>

Print ISSN: 2636-4174

Online ISSN: 2682-3780

of Medical Arts