

ACCURACY OF CONE BEAM COMPUTED TOMOGRAPHY IN HORIZONTAL LINEAR SKULL MEASUREMENTS

Nada Mohamed El Mowafy ¹, Asmaa Youssry Abd Allah ², Mohamed Adel Nadim ³,
Gihan Gamal El Din El Desouky ⁴

DOI: 10.21608/dsu.2023.155016.1138

Manuscript ID: DSU-2208-1138

KEYWORDS

Linear measurements,
Cone beam computed
tomography, Orthodontics,
Accuracy.

- E-mail address:
nmohamed.484@gmail.com
- 1. Demonstrator at Oral Radiology Department, Faculty of Dentistry- Suez Canal University.
- 2. Assistant Professor of Oral Radiology, Faculty of Dentistry- Suez Canal University.
- 3. Professor of Orthodontics, Faculty of Dentistry, Suez Canal University.
- 4. Professor of Oral Radiology, Faculty of Dentistry-Suez Canal University.

ABSTRACT

Introduction: Over the past century, craniometric measurements have been considered of great significance in the field of dentistry, especially in the field of orthodontics and orthognathic surgery. Over the last decade, the usage of Cone Beam Computed Tomography (CBCT) has tremendously escalated to overcome the drawbacks of 2D imaging techniques. Accordingly, it has been the focus of many studies to evaluate the accuracy of this radiographic technique in obtaining linear skull measurements. **Aim:** The aim of this study was to determine the reliability of linear measurements obtained from CBCT in comparison to direct skull measurements. **Materials and Methods:** This study was conducted on twelve dry human skulls. Three direct horizontal linear parameters were obtained between certain identified landmarks on each skull using a digital caliper. The skulls were subjected to CBCT examination. The measurements were obtained from CBCT 3D Volume Rendering (3D VR) images, then compared to the real skull measurements and statistically assessed for accuracy. **Results:** The results of the current study revealed very good intra and inter-observer agreement regarding all the assessed linear measurements obtained from gold standard and CBCT scans. In addition, CBCT showed non-significant underestimated values with difference ranging from (-0.13 mm, -0.10 %) to (-0.32 mm, -0.34 %) in comparison to direct skull measurements (gold standard). **Conclusion:** Linear measurements derived from CBCT are accurate and reliable and can be confidently used for different maxillofacial clinical applications especially in orthodontics.

INTRODUCTION

The precision of cranial and maxillofacial linear, angular and volumetric measurements is of utmost importance in the dental field owing to their major role in dental and maxillofacial treatment planning and follow-up. Dental researchers have been thriving to innovate new methods for obtaining precise radiographic linear and angular measurements since the reliability and accuracy of linear and angular measurements of the jaws is mandatory for the planning of different dental procedures. Therefore, it is of vital importance to assess the accuracy and reliability of different radiographic techniques ⁽¹⁾.

Cephalometry has become a crucial orthodontic clinical and research tool in the early twentieth century. This radiographic technique

is used extensively to evaluate craniofacial growth and dentofacial defects. Unfortunately, cephalometric measurements have many limitations. Cephalometric radiographs, like all traditional radiographic techniques, convert a three-dimensional (3D) structure to a two-dimensional (2D) image. The overlap of anatomical structures makes it difficult to interpret images and identify landmarks. Additionally, magnification and image distortion may result in reduced measurement accuracy ^(2,3).

In order to overcome the drawbacks of two-dimensional radiography, a shift towards three-dimensional imaging was mandatory. Conventional medical computed tomography (CT) was designed to analyze three-dimensional structures in three spatial dimensions and in doing so, provided a more real image. However, the high radiation dose delivered to the patient and the high expense of this technique limited its use in dentistry ⁽⁴⁾.

Cone Beam Computed Tomography (CBCT) was introduced in the late nineties and soon became the maxillofacial alternative to computed tomography (CT). In comparison to medical CT, CBCT reduced the radiation dosage, achieved high precision in the three spatial planes, and reduced the costs associated with CT, advantages which lead to the rapid increase in the popularity of CBCT ⁽⁵⁾.

The images obtained by CBCT give an accurate representation of maxillofacial area, therefore, aiding in the assessment of dental and skeletal structures. CBCT produces high-quality images of craniofacial structures without any superimposition, distortion or, magnification problems. In addition, it allows image reconstruction in the three orthogonal as well as the non-orthogonal planes. Owing to its high diagnostic reliability, its use in orthodontic diagnosis and treatment planning has grown

tremendously in the past years. Therefore, the aim of this study was to determine the reliability of linear measurements obtained from CBCT in comparison to direct skull measurements ⁽⁶⁾.

MATERIALS AND METHODS

I) Study settings:

The number of skulls used in this study (sample size) was calculated using G*Power software version 3.1.9.2. Twelve skulls were found to be sufficient to detect a power of 80% at a significant level of 5% ($p < 0.05$). The dry human skulls with mandibles that were collected from the Department of Anatomy, Faculty of Medicine, Suez Canal University. The study was performed in the Oral Radiology Department, Faculty of Dentistry, Suez Canal University after being waved from the approval of our research ethical committee number (108/2018), since it was conducted on unidentified twelve human dry skulls.

Inclusion criteria:

The skulls with mandibles used in the present study were chosen to fulfill the following requirements ⁽¹⁾:

1. Absence of fracture and pathological lesions at the examined areas.
2. Absence of metallic restorations (e.g., amalgam filling, implant).

II) Study design:

The principal investigator randomly assigned numbers 1 through 12 to the skulls. Six anatomical landmarks were selected on each cadaver and used for obtaining linear measurements (**Table 1**).

Table (1) Anatomical landmarks used for linear measurements ⁽⁷⁾:

Landmark name and abbreviation	Definition
Jugal (JR-JL)	The uppermost part of the maxillary bone's concavity where it joins to the zygomatic process. (Right and left)
Gonion (GoR-GoL)	A point on the mandibular angle's curvature that can be found by bisecting the angle created by lines tangent to the inferior border of the mandible and the posterior ramus. (Right and left)
Zygion (ZYR-ZYL)	The zygomatic arch's farthest lateral point. (Right and left)

a) Sample preparation

The exact positions of the landmarks were marked on the dry skulls using a blue permanent marker, then, a radiographic radiopaque marker (gutta-percha size 80) was fixed at each landmark for standardization of direct measurements and radiographic identification. The gutta-percha cones were cut into pieces of about 1-1.5 mm in length from the cone tip and subsequently bonded to the chosen landmarks.

b) Linear measurements assessed in the study:

Three measurements were taken between the defined landmarks on each skull ^(7,8):

1. Maxillary width (JR-JL): the distance between the right jugal point and left jugal point.
2. Mandibular width (GOR-GOL): the distance between the right and left gonion (GO).
3. Facial Breadth (ZYR-ZYL): the distance between the zygomatic arch's (ZY) most lateral points on the right and left sides.

III) Direct measurements (Gold standard):

The actual linear measurements between the gutta-percha markers were taken directly on the dry skulls using a precise sliding electronic digital caliper with a measurement range of 0-150 mm and 0.01 mm resolution accuracy. To ensure standardization, the measurements were taken from the outer end of the gutta-percha of one point to the outer end of the gutta-percha of the other point.

All parameters were assessed separately at two different sessions by the principle and the second investigators at two weeks interval for assessment of intra-observer and inter-observer reliability.

IV- Soft tissue simulation

To simulate soft tissue of the patients, ten layers of pink modelling wax covered the skulls providing an average thickness of about 13-17 mm according to Schropp *et al.* ⁽⁹⁾ recommendations.

V- Radiographic Evaluation:

The twelve dry skulls were radiographed using Scanora 3Dx Cone Beam Computed Tomography scanner (Scanora 3DX, Soredex, Finland). The images were used for obtaining linear measurements for analysis and comparison with the gold standard.

The field of view was set at 240x165mm for all images using standard resolution mode. The operating parameters were 90 KVp, 10mA and the effective exposure time was 3.2 seconds. The voxel size was 0.5 mm using a flat panel detector.

The projection data was reconstructed with the machine dedicated OnDemand 3D (Cybermed. Co., Seoul, Korea.) software application. All measurements were assessed twice by the principle and second investigators at two-weeks interval. The measurements were assessed from 3D volume

rendering images. 3D volume rendering (3D VR) represents a virtual model of the skull.

The facial view of 3D images was used for measurement of the maxillary width (JR-JL), while the base of the skull view was used for measurements of the mandibular width (GOR-GOL) and the facial Breadth (ZYZ-ZYL) (**Figure.1**).

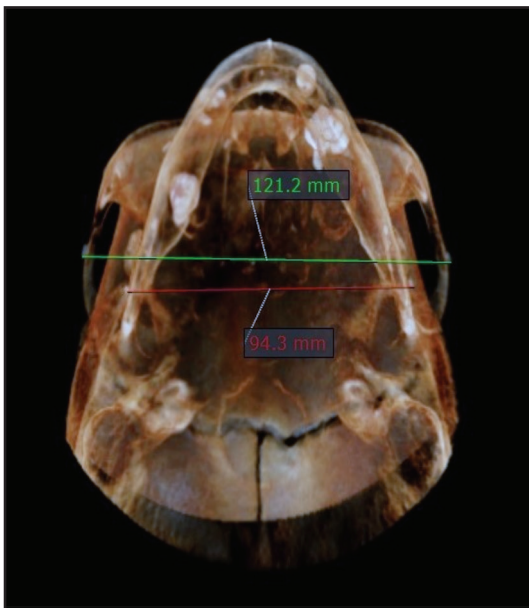


Fig. (1) Measurements of the facial breadth (ZYZ-ZYL) (green line) and mandibular width (GOR-GOL) (red line) from the basal skull view.

VI. Statistical analysis

Measurements obtained directly from the skulls (gold standard) and CBCT images were gathered, examined, and arranged in tables and figures utilizing Microsoft Excel 2016. The collected data was checked for outliers, then, was analyzed and described statistically using SPSS for Mac OS version 26.0

Intra and inter-observer agreement were assessed using Cronbach’s alpha and Interclass correlation (ICC) for the assessed measurements to establish the scale’s internal consistency.

Differences between measurements obtained from CBCT in comparison to the gold standard were assessed using Paired t-test. The significance level was established at $p \leq 0.05$.

RESULTS

1- Reliability analysis

There was high intra and inter-observer agreement regarding all linear measurements with Cronbach’s alpha and ICC value equal to (1.00) for Gold Standard (GS) and CBCT 3D VR measurements (**Tables 2 and 3**).

Table (2) Intra-observer agreement regarding linear measurements in CBCT-3D VR

Linear measurements	CBCT-3D VR / Observer 1						
	reading 1		reading 2		Intra-observer reliability		
	Mean	SD	Mean	SD	Cronbach’s	ICC	Sig.
JUR-JUL	68.77	4.43	68.76	4.47	1.00	1.00	<0.001***
ZYZ-ZYL	125.17	7.30	125.14	7.32	1.00	1.00	<0.001***
GOR-GOL	94.55	5.81	94.52	5.85	1.00	1.00	<0.001***

Significant at $p < 0.05$, < 0.01 , < 0.001 ; NS, non-significant at $p > 0.05$

Table (3) Inter-observer agreement regarding linear measurements in CBCT-3D VR.

Linear measurements	CBCT 3D VR						
	observer 1		observer 2		Inter-observer reliability		
	Mean	SD	Mean	SD	Cronbach's	ICC	Sig.
JUR-JUL	68.77	4.35	68.83	4.51	1.00	1.00	<0.001***
ZYR-ZYL	125.15	7.15	125.18	7.26	1.00	1.00	<0.001***
GOR-GOL	94.53	5.70	94.54	5.84	1.00	1.00	<0.001***

Significant at $p < 0.05$, < 0.01 , < 0.001 ; NS, non-significant at $p > 0.05$

2- Comparison between gold standard and CBCT:

The outcomes of the comparison between gold standard and CBCT measurements are presented in table (4) and figure (2). CBCT showed underestimated values in relation to gold standard regarding all linear measurements. There was a statistical non-significant difference between GS

and CBCT measurements was ($p > 0.05$) regarding all assessed measurements (Table 4 & Figure 2).

The mandibular width (GOR-GOL) recorded the highest difference (-0.32 mm, -0.34 %), while the facial breadth (LOL-MOL) recorded the lowest difference (-0.13 mm, -0.1 %) (Table 4 and Figure 2).

Table (4) Comparison between CBCT-3D VR linear measurements in relation to the gold standard.

Linear measurements	Gold standard		Mean	CBCT-3D VR		T-test
	Mean	SD		Difference		
				Mm	%	
JUR-JUL	69.0	4.3	68.8	-0.21	-0.31	>0.05 ns
ZYR-ZYL	125.3	7.1	125.2	-0.13	-0.10	>0.05 ns
GOR-GOL	94.9	5.8	94.5	-0.32	-0.34	>0.05 ns

Non-significant at $p > 0.05$

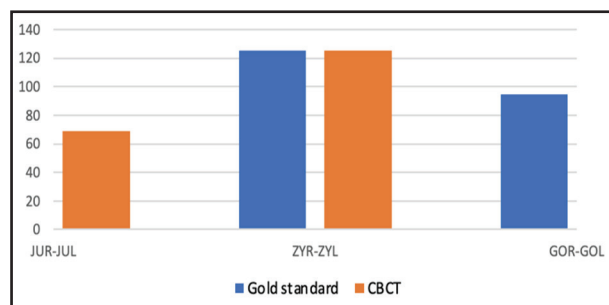


Fig. (2) Bar chart representing comparison between linear measurements of gold standard and CBCT-3D VR.

DISCUSSION

Obtaining accurate linear measurements is of paramount importance in different dental fields, owing to their critical role in treatment planning and follow up of various procedures. This led the dental researchers to innovate new ways for ensuring the production of the highest possible precision levels in this domain⁽¹⁰⁾.

Recently, the use of CBCT has remarkably escalated to overcome the drawbacks of 2D imaging technique because 3D technology offers a more accurate picture of the patient's head. CBCT has become exceedingly popular among dental practitioners especially orthodontists. The transition from 2D to 3D analysis has enabled thorough evaluation prior to, during, and following orthodontic therapy⁽¹¹⁾.

Hence, the focus of the current research was to assess the precision and reliability of horizontal linear measurements obtained from CBCT in comparison to direct skull measurements (gold standard).

Intact skulls free from fractures or pathologies were selected to avoid any factor that could affect the accuracy of landmark identification or produce an abnormal appearance in the radiographic images. In addition, skulls with any metallic restorations were excluded to avoid metallic artifact production and scattering that could adversely affect the accuracy of measurement procedure⁽¹²⁾.

In the present study, six landmarks were identified on every skull and used for obtaining three linear measurements. These specific measurements were chosen based on their high clinical relevance in orthodontics and orthognathic applications. Gutta-percha cones were used as radiopaque markers to demarcate the selected anatomical landmarks. Using a radiopaque marker ensured reproducibility and standardization by prohibiting subjective errors in landmark identification^(7,13).

In order to mimic the actual clinical condition, and simulate soft tissue attenuation, the skulls were coated with ten layers of pink modelling wax to provide an average thickness of about 13-17 mm⁽⁹⁾.

In this study, CBCT measurements were obtained from 3D VR images as they are commonly used by orthodontists and orthognathic surgeons in various

purposes such as cephalometric analysis, cleft palate, impacted or ectopic teeth, assessment of maxillary sinus and orthognathic surgery treatment planning⁽¹⁴⁾.

The results of the current study showed very good intra and inter-observer agreement regarding all linear measurements obtained from gold standard and CBCT scans which indicates the high reliability and reproducibility of the current technique used for assessment.

In addition, all measurements obtained from CBCT showed non-significant underestimated values in comparison to the gold standard.

Several studies assessed the precision of linear measurements obtained from CBCT compared to the gold standard. Of these, the study conducted by Cheung *et al.*⁽¹⁵⁾ who assessed the validity of using certain landmarks (Jugale (J) and Antegonion (Ag)) obtained from CBCT for intermaxillary transverse analysis in comparison to the direct measurements. They found that CBCT was reliable in assessing intermaxillary transverse discrepancy.

Tai *et al.*⁽¹⁶⁾ assessed the reliability of using CBCT in measuring transverse dimensions. CBCT images were obtained from thirty-one randomly selected orthodontic patients with complete permanent dentition. The transverse widths were measured clinically and radiographically using reference points. In agreement with our study, they found that CBCT demonstrated statistically non-significant differences in relation to the clinical situation in the majority of the assessed parameters.

In addition, the results of Ganguly *et al.*⁽¹⁷⁾ concurred with our results. Their study revealed that the vertical and horizontal measurements driven from CBCT images of cadaver heads had no significant difference in comparison to the

skull parameters. According to their results, CBCT showed non-statistically significant underestimation in most of the assessed linear measurements.

Similarly, Garcia *et al.* ⁽¹⁸⁾ assessed the accuracy of CBCT in linear and volumetric obtained from mandibular condyles of human skulls with soft tissues. The measurements taken from the six cadaver heads were utilised as the benchmark. They concluded that CBCT was highly reliable for obtaining linear and volumetric parameters.

Our results were further supported by those reported by Gholinia *et al.* ⁽¹⁹⁾ They used 5 dried human skulls to assess the reliability of cephalometric measurements obtained from CBCT. They found that CBCT linear measurements were similar to the gold standard. They concluded that the accuracy of linear cephalometric measurements obtained from CBCT is high and reliable.

Selim *et al.* ⁽²⁰⁾, evaluated the linear measurement's accuracy in 3D volumetric rendering CBCT images using various voxel sizes. Nine mandibles with radioopaque markers were used in their study. They found that 3D measurements driven from CBCT images with two different voxel sizes were both accurate compared to the direct measurements.

On the contrary, Pittayapat *et al.* ⁽²¹⁾, conducted a study investigating the accuracy of linear measurements obtained from CBCT compared to direct measurements on the skull. Their study revealed that measurements obtained from CBCT showed significant differences in relation to gold standard. This could be attributed to the fact that they did not use radioopaque markers which could have made identification of the anatomical landmarks more difficult. In addition, the dry skulls used in their study were without soft tissue simulation. Therefore, they did not fully represent clinical situations.

Similarly, Rokn *et al.* ⁽²²⁾ assessed the precision and inaccuracies of linear measurements of transverse dimensions utilizing CBCT in comparison with direct clinical measurements. According to their results, the CBCT measurements revealed statistically significant differences. The error range for CBCT scans was between -8.46 percent (underestimation) and 5.21 percent (overestimation). However, they considered that although the measurements revealed statistically significant differences, CBCT technique is still considered an accurate and reliable technique.

Several reasons may have contributed to the different results obtained by the above-mentioned researchers as they did not use radiopaque markers for identification of the anatomical landmarks, which may have added a factor contributing to inaccurate standardization and reproducibility of the measurements obtained. In addition, using different scanning protocols, assessing different linear distances and using different softwares are other factors that can influence the accuracy of the measurements obtained from CBCT ⁽¹³⁾.

CONCLUSION

Linear measurements obtained from CBCT 3D VR are highly accurate and reliable and can be confidently used for different maxillofacial clinical applications.

RECOMMENDATIONS

1. More research is required to assess the accuracy of a larger number of linear and angular parameters derived from CBCT.
2. Although CBCT showed high accuracy and reliability for orthodontic analysis, the high radiation dose accompanying its use does not justify its routine prescription for diagnosis and treatment follow up.

REFERENCES

1. Ulcay T and Kamaşak B. Evaluation of craniometric measurements in human skulls. *J Health Sci Med* 2021; 21:38–44
2. Duraõ AR, Bolstad N, Pittayapat P, Lambrichts I, Ferreira AP and Jacobs R. Accuracy and reliability of 2D cephalometric analysis in orthodontics. *Rev Port Estomatol Med Dentária E Cir Maxilofac* 2014; 55:135–141.
3. Gribel BF, Gribel MN, Frazão DC, McNamara JA and Manzi FR. Accuracy and reliability of craniometric measurements on lateral cephalometry and 3D measurements on CBCT scans. *Angle Orthod* 2011; 81:26–35.
4. Patrick S, Birur NP, Gurushanth K, Raghavan AS and Gurudath S. Comparison of gray values of cone-beam computed tomography with hounsfield units of multislice computed tomography: An in vitro study. *Indian J Dent Res* 2017; 28:66–70.
5. Jain S, Choudhary K, Nagi R, Shukla S, Kaur N and Grover D. New evolution of cone-beam computed tomography in dentistry: Combining digital technologies. *Imaging Sci Dent* 2019; 49:179–190.
6. Venkatesh E and Elluru SV. Cone beam computed tomography: basics and applications in dentistry. *J Istanbul Univ Fac Dent* 2017; 51:102–121.
7. Alexander J, and Richard LJ. *Radiographic Cephalometry: From Basics to 3-D Imaging*, 2nd edition. Chicago: Quintessence 2006:60–75.
8. van Vlijmen OJC, Bergé SJ, Bronkhorst EM, Swennen GRJ, Katsaros C and Kuijpers-Jagtman AM. A comparison of frontal radiographs obtained from cone beam CT scans and conventional frontal radiographs of human skulls. *Int J Oral Maxillofac Surg* 2009; 38:773–778.
9. Schropp L, Alyass NS, Wenzel A and Stavropoulos A. Validity of wax and acrylic as soft-tissue simulation materials used in in vitro radiographic studies. *Dentomaxillofacial Radiol* 2012; 41:686–690.
10. Abdinian M and Baninajarian H. The accuracy of linear and angular measurements in the different regions of the jaw in cone-beam computed tomography views. *Dent Hypotheses* 2017; 8:100–103.
11. Wen J, Liu S, Ye X, Xie X, Li J and Li H. Comparative study of cephalometric measurements using 3 imaging modalities. *J Am Dent Assoc* 2017; 148:913–921.
12. Kamburoğlu K, Kolsuz E, Kurt H, Kılıç C, Özen T, Semra Paksoy C. Accuracy of CBCT Measurements of a Human Skull. *J Digit Imaging*. 2011; 24:787–793.
13. Ghorbanizadeh S, Abdinian M, Faghihian R and Goroohi H. Comparing the accuracy of linear measurements in different image views of Galileos cone-beam computed tomography unit. *SRM J Res Dent Sci*. 2016; 7:58–63.
14. Aksoy S, Kelahmet U, Hincal E, Oz U, Orhan K. Comparison of linear and angular measurements in CBCT scans using 2D and 3D rendering software. *Biotechnol Biotechnol Equip* 2016; 30:777–784.
15. Cheung G, Goonewardene MS, Islam SMS, Murray K and Koong B. The validity of transverse intermaxillary analysis by traditional PA cephalometry compared with cone-beam computed tomography. *Aust Orthod J* 2013; 29:86–95.
16. Tai B, Goonewardene MS, Murray K, Koong B and Islam SMS. The reliability of using postero-anterior cephalometry and cone-beam CT to determine transverse dimensions in clinical practice. *Aust Orthod J* 2014; 30:132–142.
17. Ganguly R, Ramesh A and Pagni S. The accuracy of linear measurements of maxillary and mandibular edentulous sites in cone-beam computed tomography images with different fields of view and voxel sizes under simulated clinical conditions. *Imaging Sci Dent* 2016; 46:93–101.
18. García-Sanz V, Bellot-Arcís C, Hernández V, Serrano-Sánchez P, Guarinos J and Paredes-Gallardo V. Accuracy and Reliability of Cone-Beam Computed Tomography for Linear and Volumetric Mandibular Condyle Measurements. A Human Cadaver Study. *Sci Rep* 2017; 7:11993.
19. Gholinia F and Pourgholi M. Accuracy and precision of measurements obtained from conventional cephalograms and CBCT scan in orthodontics linear diagnostic measurements. *J Dentomaxillofacial* 2020; 10:36–43.
20. Selim M, Dahaba M and Abdalsamad A. Effect of Different Voxel Sizes on Accuracy of 2D and 3D Mandibular Linear Measurements Using CRANEX® 3D Cone Beam Computed Tomography Machine: Preclinical Study. *EDJ* 2021;67: 3231–3235.
21. Pittayapat P, Bornstein MM, Imada TSN, Coucke W, Lambrichts I and Jacobs R. Accuracy of linear measurements using three imaging modalities: two lateral cephalograms and one 3D model from CBCT data. *Eur J Orthod* 2015; 37:202–208.
22. Rokn AR, Hashemi K, Akbari S, Kharazifard MJ, Barikani H, and Panjnoosh M. Accuracy of linear measurements using cone beam computed tomography in comparison with clinical measurements. *J Dent*. 2016; 13:333–339.