

Potential Effects of Horny Goat Weed (*Epimedium grandiflorum*) on The Level of Fertility in Male Rats Infected with Cadmium Chloride: Biochemical and Histopathological Study

Amal Z. Nasef¹, Naglaa A. El-Sheikh

ABSTRACT

The present study aimed to investigate the effect of horny goat weed on the level of fertility in male rats infected with cadmium chloride. The rats were divided into two groups, the first group: Group 1 (6 rats) fed on a basal diet as a negative control group (-ve) and the other main groups (30 rats) were injected with two doses of cadmium chloride (CdCl₂, 0.1%) administered intraperitoneally at 0.1 ml per 100g body weight to cause sterility and classified into five subgroups. Subgroup 1(n:6): fed on the basal diet as a positive control group (+ve). Subgroup 2 feeds on basal diet and given standard drug (Sildenafil Citrate) (SC) (5 mg/kg b w) via a stomach tube daily for 28 days. Subgroup 3,4 and 5 fed on the Horny Goat Weed (HGW) by 10, 15 and 20 % (w/w) of the basal diet weight, respectively. Blood samples were taken after the experiment to assess lipid profiles, liver functions, kidney functions, and serum levels of testosterone (T), luteinizing hormone (LH), and follicle-stimulating hormone (FSH). The testicles were removed for histopathological examination, measuring the testicular tissue hormones and antioxidant enzymes superoxide dismutase, glutathione peroxidase, catalase and malondialdehyde. Results indicated that the HGW treatments improved liver, renal function, lipid profiles, antioxidant enzyme activity and sex hormone levels in both serum and testicular tissue.

In conclusion; The moderate use of horny goat weed may be beneficial for improving male sexual performance and is considered as one of the natural sexual stimulants.

Keywords: Fertility, Horny goat weed, Luteinizing hormone, Cadmium chloride, Liver functions.

INTRODUCTION

About 15-20% of couples struggle to conceive of infertility in this century, and the rate is still rising. Up to 30% of male cases infertility (Kilchevsky and Honig, 2012). Infertility is known as the biological inability of a person to contribute to conception, which may result from either a male or female factor (Nayernia *et al.*, 2004). Also, it is known as men's sperm quality and quantity are consistently declining (Geoffroy-Siraudin *et al.*, 2012). Males are exposed to toxins from the environment at all stages of their lives,

including during the embryonic stage (Loebenstein *et al.*, 2019). Testicular Dysgenesis Syndrome (TDS), which is caused by fetal exposure to environmental toxins, causes male subfertility or infertility as well as reproductive system defects such as cryptorchidism and hypospadias (Skakkebaek *et al.*, 2001). Male subfertility and infertility may be greatly impacted by an increase in testicular cancer and cryptorchidism (Jorgensen *et al.*, 2011).

Among the environmental contaminants is a group of heavy metals has a same link to male infertility as cadmium (Wirth and Mijal, 2010). People exposure to cadmium, through smoking and tainted food, damage and disruption of the testis' vascular system results in male subfertility or infertility in humans and other species (Zhu *et al.*, 2020). They added that the blood-testis barrier, Sertoli cells, and seminiferous tubules are severely structurally damaged by cadmium, which results in the loss of sperm.

Due to the costly, lengthy, and side-effect-filled development of current medications, phytotherapeutic approaches to treating infertility have driven researchers to investigate a variety of plants and polyherbal formulations (Ahmed *et al.*, 2014 and Hamed, 2021). There are more than 50 species of horny goat weed (HGW) in the *Berberidaceae* family genus *Epimedium*. *Epimedium grandiflorum* and *Epimedium sagittatum* are two of the most popular herbs utilized in sexual enhancer products and icariin is the main active component (Ma *et al.*, 2011). Nitric oxide (NO) synthesis in the penis is induced by the plant's active component like icariin, a flavonol glycoside (Shindel *et al.*, 2010). Icariin (ICA) as is the major bioactive flavonoid component and exists in many species of *Epimedium* plants (Pei *et al.*, 2007). The existence of diverse phytochemical elements in *Epimedium* species is what gives rise to their positive benefits. Alkaloids, flavonoids, proteins, glycosides, bioactive peptides, waxes, and amino acids are among the more than 260 phytochemicals, and phytohormones, have been isolated and are known to have beneficial effects (Campbell *et al.*, 2013). Eminent Chinese herbal remedy Horny Goat

DOI: 10.21608/asejaiqsae.2023.315705

¹Dep. of Nutrition & Food Science, Faculty of Home Economics,

Menoufia University, Shibin El-Kom, Egypt

amal_nasef2010@yahoo.com

amal.nasif1@hec.menofia.edu.eg

ORCID ID: <https://orcid.org/0000-0002-7054-8659>

Received, August 10, 2023, Accepted, September 03, 2023.

Weed (HGW), also known as *Epimedium* Herba, is frequently used to cure a variety of illnesses including coronary heart disease, impotence, osteoporosis, and rheumatism (Ye and Chen, 2001).

Among the many pharmacological effects of *Epimedium*'s active constituents are those related to hormone control, yang strengthening, osteoporosis treatment, immune system enhancement, hepatoprotection, anti-cancer, anti-oxidation, anti-lipidemic, anti-aging, and anti-depressant qualities (Munir *et al.*, 2020).

The main goals of this study were to demonstrate the effectiveness of horny goat weed (*Epimedium grandiflorum*), and therapeutic response by assessing antioxidant parameters, reproductive hormones, and testicular tissue structure in CdCl₂ intoxicated male albino rats.

MATERIALS AND METHODS

MATERIALS

Plant Part

Dried horny goat weed (*Epimedium grandiflorum*) was obtained from Shana, a specialized herbs shop in Cairo, Egypt.

Chemicals

The cadmium chloride used to make rats sterile was given by Sigma Chemical Co. Casein was supplied by Morgan Company for Chemicals, Cairo, Egypt. El-Ghomhorya Company for Trading Drugs, Chemicals, and Medical Requirements in Cairo, Egypt. Vitamins and salt combinations, cellulose, choline chloride, L-methionine, all organic solvents, buffers, Sildenafil Citrate, and other analytical chemicals were purchased from El-Ghomhorya Company for Trading Drugs, Chemicals, and Medical Requirements in Cairo, Egypt.

Kits

Gama Trade Company, Cairo, Egypt, provided the kits used to detect AST, ALT, urea, and creatinine.

Rats

36 adult male albino Sprague Dawley rats were procured from the Medical Insects Research Institute, Doki, Cairo, Egypt, and weighed (150 ± 5g). This work was ethically approved by the Institutional Animal Care and Use Committee (IACUC), Menoufia University (Reg. No, MUFHE /F/NFS/13/23).

METHODS

Biological Experiment

Basal Diet

According to AIN (1993), the basic diet has consisted of the following ingredients: oil (10%), minerals and vitamins (1%), protein (10%), choline

chloride (0.2%), methionine (0.3%), cellulose (5%), and corn starch (69.5%). The salts mixture utilized was created following Hegsted *et al.* (1941), while the vitamin mixture component was advised by Campbell (1963).

Induction of rat sterility

Throughout the experiment, cadmium chloride (CdCl₂, 0.1%) was injected twice into healthy male albino rats at a rate of 0.1ml/100g body weight (Rekha *et al.*, 2009).

Experimental Design

36 adult male albino Sprague Dawley rats, weighing (150 ± 5g) were used in this study. During the experiment, rats were kept in individual stainless steel cages at room temperature with a 12-hour light/dark cycle in the animal house of the Faculty of Science at Menoufia University in Egypt. For acclimation, all rats were fed a basal diet for one week before beginning the experiment. The rats were divided into two main groups. The first group (6 rats) fed on the basal diet (SD) as a negative control group (-ve). The second group 30 rats injected with cadmium chloride were classified into five subgroups. Subgroup 1: fed on the basal diet as a positive control group (+ve). Subgroup 2 was fed a basal diet for 28 days and received a conventional medication (Sildenafil Citrate) (SC) (5 mg/kg BW) through a stomach tube each day according to Ahmed and Aslam (2018). Subgroups 3,4 and 5 were fed on the horny goat weed by 10, 15 and 20 % (w/w) of the basal diet weight, respectively. All of the rats had unrestricted access to food and water, and the treatments persisted for a total of 4 weeks.

Blood Sampling and Organs Removal

The method described by Drury and Wallington (1980) was followed. All rats were given a 12-hour fast before being killed using ether anesthesia. From the portal vein, blood samples were taken and put in fresh, dry centrifuge tubes. They were placed in a centrifuge to separate the serum for 15 minutes at 3000 rpm after being allowed to clot for 30 minutes at room temperature. To facilitate further research, the serum was carefully removed and transferred to clean Eppendorf tubes. Prostate glands and seminal vesicles were gathered. The testicles were taken out, washed in saline solution, dried using filter paper, and weighed. Rapidly frozen at - 18°C in ice bags, the right testis was removed to be examined for testicular tissue lipid peroxidation and antioxidant enzymes. The left testis was kept in formalin solution (10%), for histological examination.

Biochemical and hormonal analysis

Serum testosterone concentration was measured according to McCann and Kirkish (1985). Follicle-

stimulating hormone (FSH) and luteinizing hormone (LH) serum levels were measured according to the method described by Ballester *et al.* (2004). Gonadotrophin Releasing Hormone GnRH and KissPeptin were determined by enzyme-linked immunosorbent assay to Chan *et al.* (2011).

In testis tissue, the levels of the enzymes superoxide dismutase (SOD), catalase (CAT), and glutathione peroxidase (GPx) were evaluated according to Masayasu and Hiroshi (1979), Aebi (1984) and Nishikimi *et al.* (1972), respectively. Malondialdehyde (MDA) was estimated according to Ohkawa *et al.* (1979).

According to Patton and Crouch (1977), Schirmeister (1964), and While *et al.* (1970), respectively, serum urea, creatinine, and uric acid were measured. Alkaline phosphatase (ALP), Alanine aminotransferase (ALT), and Aspartate aminotransferase (AST) were all estimated using the techniques described by Tietz (1976), Henry (1974), and Moss (1982), respectively. High-density lipoprotein cholesterol (HDL-c), serum triglycerides (T.G.), and cholesterol were tested in accordance with Fossati and Principe (1982), Richmond (1973), and Allain (1974), respectively. According to Castelli *et al.* (1977) calculation, serum low-density lipoprotein cholesterol (LDL-c) was estimated as mg/dl: LDL Concentration mg/dl = Total Cholesterol - (HDL + VLDL).

According to Lee and Nieman's (1996) formula, serum very low-density lipoprotein cholesterol (VLDL-c) was determined as mg/dl: VLDL-C concentration mg/dl = T G/5

Histopathological analysis

Left testicle was cleaned in xylol, embedded in paraffin, and preserved in a 10% neutral buffered formaldehyde solution at pH 7.5. According to Bancroft *et al.* (1996), 4-5 m thick sections were cut and stained with hematoxylin and eosin (H&E) for a subsequent histological evaluation.

Statistical analysis

When a significant main effect was found, the data were examined using a completely randomized factorial

design (SAS, 1988), and the means were separated using the Newman-Keuls test. Using the SPSS program, differences between treatments were deemed significant ($P \leq 0.05$). In order to evaluate the biological outcomes, one-way ANOVA was performed.

RESULTS AND DISCUSSION

Effect of horny goat weed on rat male sexual organ weights with testicular damage by CdCl₂.

From data in Table (1), it could be noticed that rats with testicular damage by CdCl₂ showed a significant ($p \leq 0.05$) decrease in vesicle 1.26 ± 0.102 , prostate 0.34 ± 0.059 and testes weight 1.50 ± 0.42 compared to the normal rats (-ve). Animal testicles are sensitive organs to CdCl₂, according to Takiguchi and Yoshihara (2006) and Sadik (2008). Male reproductive toxicity and severe testicular damage can be caused by CdCl₂ (Wan *et al.*, 2013). Also, Zhu *et al.* (2020) reported that The testis' circulatory system is disturbed by cadmium. Supplementation rats with SC and HGW (10, 15 and 20 %) for 4 weeks increased the weight of vesicle and prostate ($p \leq 0.05$). The highest excess in the weight of vesicle and prostate were observed in rats supplemented with HGW (10 and 15 %). While there is no significant change in the weight of testes among rat supplemented with HGW (10, 15 and 20 %) and rats supplemented with SC. Williamson *et al.* (1996) claimed that medicinal herbs provide anti-sterility properties through a variety of mechanisms, as well as the impact on sex hormones, regulating menstruation, easing dysmenorrhea, treating an enlarged prostate, and managing menopausal symptoms.

Effect of horny goat weed on testicular hormone levels in rats with testicular damage by CdCl₂.

Data provided in Table (2) illustrated that CdCl₂ caused a significant ($p \leq 0.05$) decrease in serum level of testes hormones (Testosterone, LH and FSH) in rats treated with cadmium chloride compared with normal rats (-ve). With both immediate and long-term consequences, cadmium is a hazardous heavy metal that accumulates in several organs, including the brain, liver, kidney,

Table 1. Effect of horny goat weed on rat male sexual organ weights with testicular damage by CdCl₂

Groups	Vesicle weight (g/100 g BW)	Prostate weight (g/100 g BW)	Testes weight (g/100 g BW)
(-ve)	$1.81 \pm .104^a$	$0.62 \pm .055^{cb}$	1.89 ± 0.40^a
(+ve)	$1.26 \pm .102^d$	$0.34 \pm .059^d$	1.50 ± 0.42^b
(SC)	$1.43 \pm .102^c$	$0.56 \pm .038^c$	1.57 ± 0.084^b
(HGW) (10%)	$1.77 \pm .056^a$	$0.72 \pm .066^a$	1.74 ± 0.38^b
(HGW) (15%)	$1.70 \pm .053^a$	$0.72 \pm .066^a$	1.59 ± 0.19^b
(HGW) (20%)	$1.58 \pm .088^b$	$0.64 \pm .051^b$	1.65 ± 0.17^b

Data are presented as mean \pm SD. Values in the same column with different letters indicate significant differences among groups at $p \leq 0.05$. HGW: Horny Goat Weed; SC: Sildenafil Citrate; CdCl₂: Cadmium Chloride; BW: Body Weight

Table 2. Effect of horny goat weed on testicular hormone levels in rats with testicular damage by CdCl₂

Groups	Testosterone H. (ng/ml)	LH (ng/ml)	FSH (ng/ml)
(-ve)	4.83± 1.65 ^b	40.42± 2.47 ^a	6.33± 1.61 ^a
(+ve)	0.37±0.058 ^d	1.55±0.25 ^e	0.36± 0.038 ^c
(SC)	0.84± 0.049 ^d	3.55±0.49 ^e	1.27±0.22 ^{bc}
(HGW) (10%)	9.87± 1.29 ^a	35.23±2.74 ^b	6.22±1.02 ^a
(HGW) (15%)	3.28± 0.92 ^c	25.98± 3.16 ^c	5.15±1.03 ^a
(HGW) (20%)	1.39± 0.10 ^d	12.18± 1.85 ^d	2.50± 0.69 ^b

Data are presented as mean±SD. Values in the same column with different letters indicate significant differences among groups at $p \leq 0.05$. HGW: Horny Goat Weed; SC: Sildenafil Citrate; CdCl₂: Cadmium Chloride; FSH: Follicle-stimulating hormone and LH: Luteinizing Hormone.

and testicles (Holt and Webb,1987). According to Mahmoud *et al.* (2019) male rats can develop testicular degeneration by administering CdCl₂ intraperitoneally once per week for two weeks at a dose of 1 mg/kg B.W. Treatment rats with HGW (10,15 and 20%) showed a significant increase in the level of testosterone, LH and FSH hormones' compared with (+ve) group, whereas the levels of testosterone, LH and FSH hormones in rats treated with SC did not differ from the positive control group ($p \leq 0.05$). These findings are supported by Kuang *et al.* (1989) stated that *Epimedium sagittatum* has traditionally been used to treat sexual abnormalities like erectile dysfunction and premenopausal issues. Horny goat weed, aids to increase sex drive and restore testosterone and thyroid hormone levels (Qureshi *et al.*, 2017). The best levels of testosterone and LH hormones were found in rats treated with 10% of HGW, as well as the highest level of FSH was noted in rats treated with 10 and 15% of HGW. Also, there is no significant change in the level of testes hormones between rats treated with SC and the positive control group. One of the ingredients in its *Epimedium sagittatum*, icariin, mimics testosterone may enhance testosterone secretion in Leydig cells (Zhang and Yang 2006). Moreover, Chen *et al.* (2014) discovered that testosterone levels dramatically raise with icariin doses from 50 to 100 mg/kg.

Effect of horny goat weed on testicular tissue hormones levels of testes in rats with testicular damage by CdCl₂.

Table (3) showed that Infestation of CdCl₂ led to a significant ($P \leq 0.05$) decrease in GnRH, KissPeptin, T, LH and FSH in positive control groups (+ve) compared to (-ve) groups. The testis is extremely sensitive to CdCl₂ toxicity. Hassanzadeh and Mortazavi (2016) stated that CdCl₂ caused sterility, interstitial fibrosis, bleeding, testicular oedema, and loss of germ cells in a certain mammalian species. When using asexually stimulating drug (SC), hormones levels increased slightly significantly ($P \leq 0.05$) compared to the other HGW groups and (+ve) group. Different treatments of HGW (10-15 and 20%) led to a significant ($P \leq 0.05$)

improvement in hormone levels. Treatment of 10% of HGW was more effective in increasing the testicular tissue hormone levels. These results concurred with those of Sze *et al.* (2010) said that *herba Epimedium* has proven efficacy in improving sexual and neurological functions. Chen *et al.* (2014) LH levels tended to be higher than in the control group at the various doses of *Epimedium sagittatum*, and increased sperm count, which may have been partially attributed to the rise in FSH levels.

Effect of horny goat weed on rats' testicular antioxidant enzyme activity with testicular damage by CdCl₂.

Results in Table (4) showed that in the testicular tissue of the control positive groups as compared to the negative groups, there was an increase in lipid peroxidation (MDA) and a highly significant drop in antioxidant enzymes (SOD, CAT, and GPX). Cadmium anemia is caused by induced oxidative damage to erythrocytes, which also affects the activity of the AOS enzymes: CuZn, SOD, CAT, GSH-Px, GR, and GST as well as GSH, vitamin C, and vitamin E concentrations (Ognjanovic *et al.*, 2003).

After supplementation of rats with SC and HGW, the levels of antioxidant enzymes were increased and MDA decreased in testicular tissue as compared to positive control groups. The highest activity of SOD and CAT was found in rats treated with 10% HGW compared to positive control rats. However, the levels of GPX and MDA in rats treated with 10% HGW did not differ from the negative control group ($p \leq 0.05$). These results may be due to both an increase in the activity of the antioxidant-defense system and an inhibition of lipid peroxidation production. This results agree with Chen *et al.* (2014) discovered that the ability of the testes to fight against free radicals and reduce lipid peroxidation can be improved by icariin at doses of 50 and 100 mg/kg, it was observed. Depending on the dose administered, icariin may have a pro- or anti-oxidative effect in the testes because 200 mg/kg of icariin increases oxidative stress.

Table 3. Effect of horny goat weed on testicular tissue hormones levels in rats with testicular damage by CdCl₂

Groups	GnRH	KissPeptin	T(ng/ml)	LH (ng/ml)	FSH (ng/ml)
(-ve)	126.20±1.59 ^a	8.55±1.53 ^a	7.04±1.63 ^a	41.14±1.63 ^a	6.88±1.63 ^a
(+ve)	2.87±1.63 ^f	0.46±0.001 ^e	0.22±0.001 ^d	2.73±1.09 ^f	0.396±0.001 ^e
(SC)	22.58±1.70 ^e	0.96±0.001 ^{de}	0.66±0.001 ^d	9.53±1.49 ^e	0.963±0.001 ^{de}
(HGW) (10%)	101.72±1.64 ^b	6.16±1.65 ^b	5.69±1.86 ^b	32.0±1.81 ^b	4.68±1.53 ^b
(HGW) (15%)	74.58±2.57 ^c	4.20±1.65 ^c	2.89±1.43 ^c	22.66±1.63 ^c	3.29±1.69 ^{bc}
(HGW) (20%)	48.38±1.82 ^d	2.78±1.46 ^{cd}	1.07±0.016 ^d	15.41±1.55 ^d	2.52±1.15 ^{dc}

Data are presented as mean±SD. Values in the same column with different letters indicate significant differences among groups at p≤0.05. HGW: Horny Goat Weed; SC: Sildenafil Citrate; CdCl₂: Cadmium Chloride; GnRH: Gonadotropin-releasing hormone; T: Testosterone H; LH: luteinizing hormone; FSH: Follicle-stimulating hormone.

Table 4. Effect of horny goat weed on rats' testicular antioxidant enzyme activity with testicular damage by CdCl₂

Groups	SOD (u/mg protein)	CAT (nmol/min/mg protein)	MDA (nmol/mg)	GPX (nmol/min/mg protein)
(-ve)	225.50±1.67 ^a	18.56±1.36 ^a	0.56±0.001 ^d	192.20±1.67 ^a
(+ve)	34.52±5.10 ^f	0.43±0.06 ^e	11.14±1.56 ^a	59.32±3.62 ^e
(SC)	75.03±7.32 ^e	0.99±0.06 ^e	7.20±1.04 ^b	93.18±14.59 ^d
(HGW) (10%)	165.95±13.02 ^b	11.38±1.35 ^b	0.68±0.06 ^d	195.81±4.26 ^a
(HGW) (15%)	141.46±5.19 ^c	4.54±0.71 ^c	1.51±0.27 ^d	152.21±3.88 ^b
(HGW) (20%)	102.84±3.48 ^d	2.86±0.58 ^d	3.18±1.16 ^c	129.16±6.51 ^c

Data are presented as mean±SD. Values in the same column with different letters indicate significant differences among groups at p≤0.05. HGW: Horny Goat Weed; SC: Sildenafil Citrate; CdCl₂: Cadmium Chloride; SOD: Superoxide dismutase; CAT: Catalase; MDA: Malonaldehyde; GPX: Glutathione Peroxidase.

The antioxidation defense system can stop lipid oxidation or break down peroxides to get rid of lots of oxygen free radicals, protecting the body from oxidative stress-related harm. SOD activity and MDA levels roughly reflect tissue oxidative balance (Kang *et al.*, 2012). Herba Epimedii protects tissues and organs by preventing severe oxidative damage, which has an antioxidative effect (Sze *et al.*, 2010).

Effect of horny goat weed on serum liver functions enzymes activities of rats with testicular damage by CdCl₂.

Data in Table (5) showed that the values of AST, ALT and ALP in the positive control group were significantly higher (p≤0.05) than that of the negative control group. Toppo *et al.* (2015) indicated that hepatic enzyme levels like ALT and AST may be significantly altered as a result of Cd-induced liver damage.

Feeding rats with SC and HGW resulted in a significant reduction in the values of AST, ALT and ALP compared to the positive control group. Rats fed on 10% of HGW are considered to be the ideal therapy for ALT and ALP. As the results indicated that the values of AST in rats fed on 10% of HGW were

restored to negative control values. These results agree with Hai *et al.* (2023) observed that rats fed a high-fat diet (HFD) and letrozole had their excess serum levels of (AST) decreased by horny goat weed, a herb similar to icaridin that causes herpes.

Effect of horny goat weed on renal functions of rats with testicular damage by CdCl₂.

According to Table (6)'s findings, there was a significant rise in uric acid, creatinine and urea levels in CdCl₂ treated groups compared with normal rats. Based on population research and animal studies, several studies have suggested that exposure to CdCl₂ may result in kidney damage (Akesson *et al.*, 2005 and Mitsumori *et al.*, 1998).

Feeding rats diets with SC and HGW caused a significant decrease in the range of urea, creatinine and uric acid compared with control- positive rats. Feeding rats a diet with 10% of HGW was more effective in reducing in the range of urea, creatinine and uric acid compared with other concentrations of HGW (15 and 20%), as well as it was observed that no significant differences (P > 0.05) in creatinine and uric acid levels among rats fed with 10% of HGW and negative control rats. Su *et al.* (2022) demonstrated that mice with

diabetic kidney disease treated with Icarin culture had much lower levels of microalbumin/creatinine in urine and serum urea nitrogen, and their nephropathy had significantly improved.

Effect of horny goat weed on lipid profiles of rats with testicular damage by CdCl₂.

Table (7) demonstrated the impact of infection with cadmium chloride on the levels of blood lipids, as it led to a significant increase in the levels of TC, TG, LDL and VLDL. But for HDL, the infection led to a significant decrease compared to the negative control group. Twisk *et al.* (2000) showed that in the cadmium-treated rats, LDL and VLDL cholesterol fractions rose along with an increase in plasma cholesterol.

The use of the drug SC and HGW (10,15 and 20%) led to a significant decrease in TC, TG, LDL and VLDL levels compared to the positive group (+ve). While HDL had an opposite trend. However, the levels of TC, TG, LDL and VLDL in rats supplemented with 10% HGW did not differ from the negative control group ($p \leq 0.05$). Herba Epimedii reduced excess triglyceride buildup, vacuolization staining area in the liver of model rats, which was evidence that it reduced HFD and letrozole-induced fatty liver (Hai *et al.*, 2023). Icarin can control lipid metabolism and treat many metabolic illnesses brought on by aberrant lipid metabolism, including diabetes and obesity (Wang *et al.*, 2020 and Yao *et al.*, 2021).

Table 5. Effect of horny goat weed on serum liver functions enzymes activities (ALT, AST and ALP) of rats with testicular damage by CdCl₂

Groups	ALT (U/L)	AST (U/L)	ALP (U/L)
(-ve)	79.63±2.49 ^e	127.35±2.74 ^d	147.42±2.65 ^f
(+ve)	205.75± 10.75 ^a	285.46±24.96 ^a	396.81±15.50 ^a
(SC)	155.68±6.96 ^b	216.87±14.89 ^b	342.81±5.66 ^b
(HGW) (10%)	91.25±2.30 ^d	142.81±5.66 ^d	188.50±10.33 ^e
(HGW) (15%)	125.93± 12.15 ^c	190.87±3.56 ^c	233.78±10.61 ^d
(HGW) (20%)	132.05±3.67 ^c	226.81±11.27 ^b	296.05±6.59 ^c

Data are presented as mean±SD. Values in the same column with different letters indicate significant differences among groups at $p \leq 0.05$. HGW: Horny Goat Weed; SC: Sildenafil Citrate; CdCl₂: Cadmium Chloride; ALT: Alanine aminotransferase; AST: Aspartate transaminase; ALP: Alkaline phosphatase.

Table 6. Effect of horny goat weed on renal functions of rats with testicular damage by CdCl₂

Groups	Urea(mg/dl)	Creatinine(mg/dl)	Uric acid(mg/dl)
(-ve)	24.20±2.54 ^f	0.58±0.025 ^d	3.31±1.76 ^c
(+ve)	67.76±2.91 ^a	1.31±0.061 ^a	7.14±1.13 ^a
(SC)	55.78±1.35 ^b	1.07±0.069 ^b	6.61±1.00 ^{ab}
(HGW)(10%)	37.06±2.36 ^e	0.60±0.05 ^d	3.87±1.06 ^c
(HGW) (15%)	40.50±1.59 ^d	0.81±0.028 ^c	5.11±1.11 ^{bc}
(HGW) (20%)	49.10±1.69 ^c	0.86±0.026 ^c	5.82±1.06 ^{ab}

Data are presented as mean±SD. Values in the same column with different letters indicate significant differences among groups at $p \leq 0.05$. HGW: Horny Goat Weed ; SC: Sildenafil Citrate; CdCl₂: Cadmium Chloride.

Table 7. Effect of horny goat weed on lipid profiles of rats with testicular damage by CdCl₂

Groups	TC (mg/dl)	TG (mg/dl)	HDL (mg/dl)	LDL (mg/dl)	VLDL (mg/dl)
(-ve)	102.60±2.36 ^e	97.16±2.61 ^e	52.05±2.61 ^a	31.11±3.31 ^e	19.43±0.51 ^e
(+ve)	259.55±11.1 ^a	199.10±1.24 ^a	42.51±1.63 ^c	177.23±12.25 ^a	39.82±0.24 ^a
(SC)	200.02±9.21 ^b	187.75±12.13 ^b	49.64±1.29 ^a	112.82±7.77 ^b	37.55±2.42 ^b
(HGW) (10%)	107.95±8.22 ^e	91.77±6.95 ^e	49.52±1.09 ^a	40.08±6.57 ^e	18.35±1.39 ^e
(HGW) (15%)	131.71±2.79 ^d	121.05±6.83 ^d	51.20±1.05 ^a	56.31±1.93 ^d	24.21±1.36 ^d
(HGW) (20%)	168.81±1.47 ^c	154.92±4.08 ^c	47.14±1.31 ^b	90.69±2.06 ^c	30.98±0.81 ^c

Data are presented as mean±SD. Values in the same column with different letters indicate significant differences among groups at $p \leq 0.05$. HGW: Horny Goat Weed; SC: Sildenafil Citrate; CdCl₂: Cadmium Chloride; TC: Total Cholesterol; TG: Triglyceride; HDL: High-Density Lipoprotein; LDL: Low-Density Lipoprotein; VLDL: Very Low-Density Lipoprotein.

HISTOPATHOLOGICAL EXAMINATION OF TESTES

Microscopically, the testes of rats from group 1 showed the normal histological structure of seminiferous tubule with normal spermatogonial cells and complete spermatogenesis (Figs. 1 & 2). On the contrary, examined sections from group 2 revealed degeneration of spermatogonial cells lining seminiferous tubules with interstitial oedema (Figs. 3 & 4) and vacuolation of Leydig cells (Fig. 4). Meanwhile, sections from group 3 manifested slight degeneration of spermatogonial cells lining seminiferous tubules (Figs. 5 & 6). On the other hand, testes of rats from groups 4, 5 & 6 exhibited normal histological architecture of seminiferous tubules and complete spermatogenesis (Figs. 7, 8, 9, 10, 11 & 12).

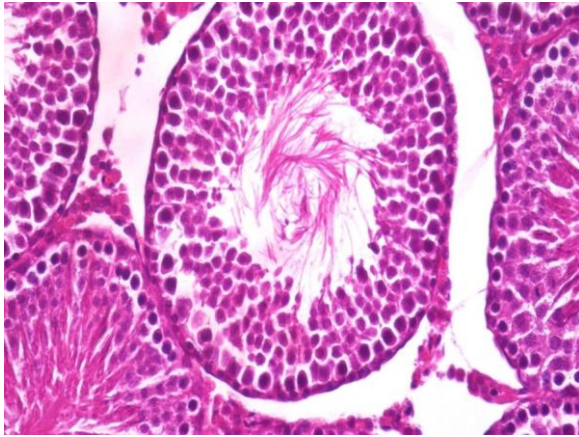


Fig. 1. Normal histological structure of rat testis from group 1 seminiferous tubule with normal spermatogonial cells and complete spermatogenesis (H & E X 400)

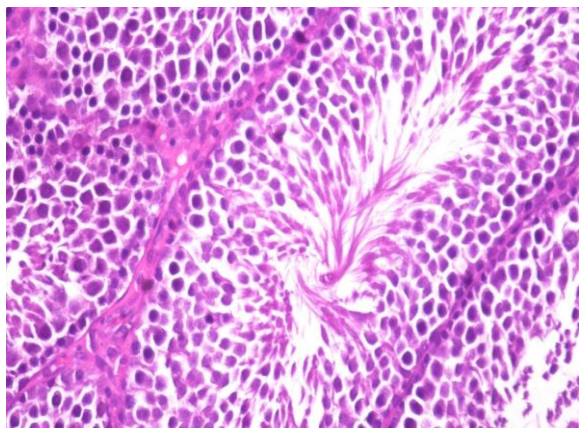


Fig. 2. Normal histological structure of rat testis from group 1 seminiferous tubule with normal spermatogonial cells and complete spermatogenesis (H & E X 400)

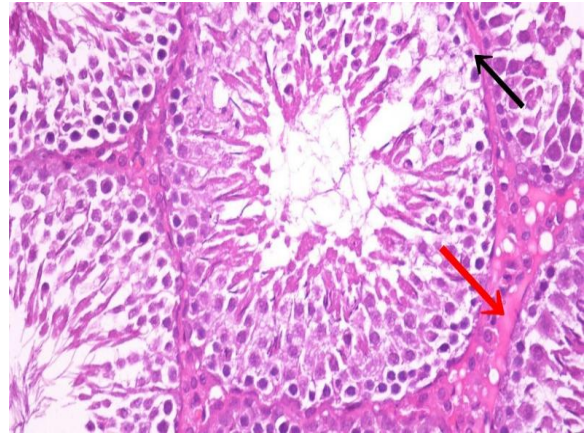


Fig. 3. Rat testis from group 2 degeneration of spermatogonial cells lining seminiferous tubules (black arrow) with interstitial oedema (red arrow) (H & E X 400)

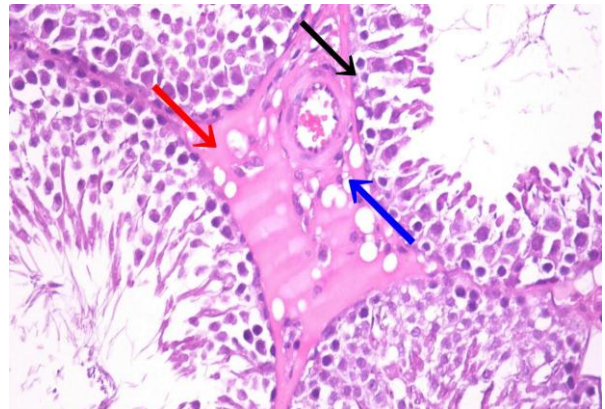


Fig. 4. Rat testis from group 2 degeneration of spermatogonial cells lining seminiferous tubules (black arrow) with interstitial oedema (red arrow) and vacuolation of Leydig cells (blue arrow) (H & E X 400)

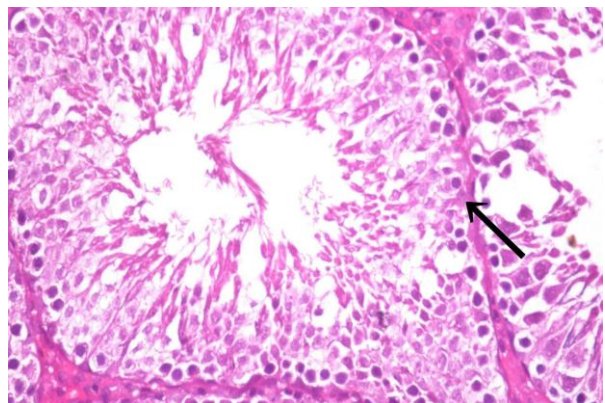


Fig. 5. Rat testis from group 3 slight degeneration of spermatogonial cells lining seminiferous tubules (black arrow) (H & E X 400)

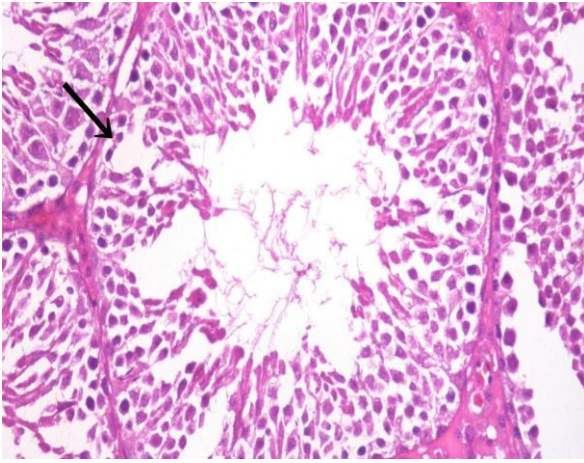


Fig. 6. Rat testis from group 3 slight degeneration of spermatogonial cells lining seminiferous tubules (black arrow) (H & E X 400)

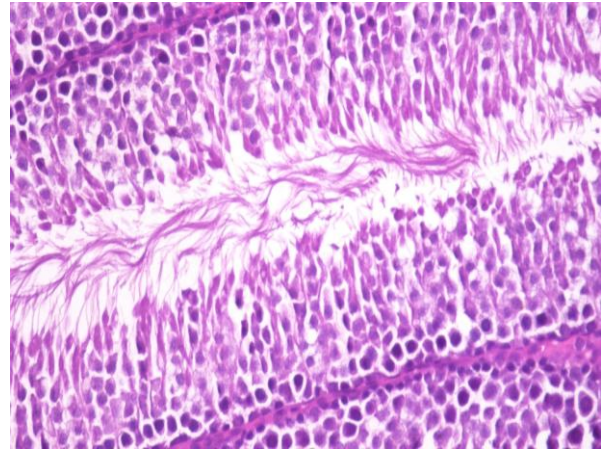


Fig. 9. Rat testis from group 5 normal histological architecture of seminiferous tubules (H & E X 400)

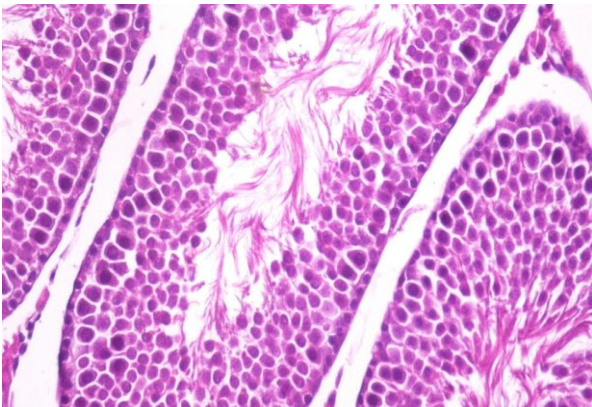


Fig. 7. Rat testis from group 4 normal histological architecture of seminiferous tubules (H & E X 400)

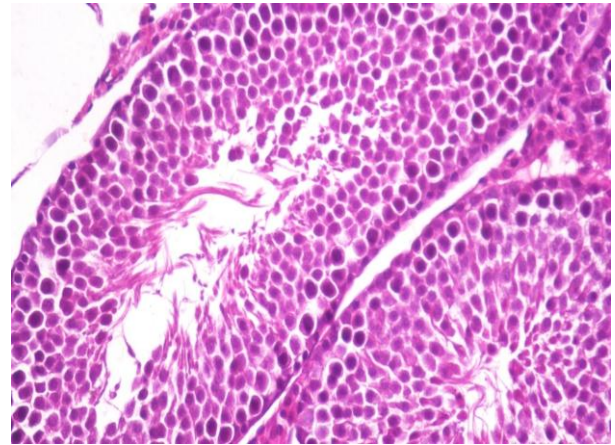


Fig. 10. Rat testis from group 5 normal histological architecture of seminiferous tubules and complete spermatogenesis (H & E X 400)

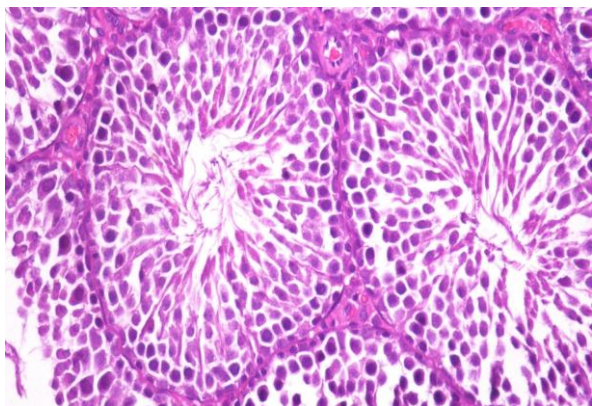


Fig. 8. Rat testis from group 4 normal histological architecture of seminiferous tubules (H & E X 400)

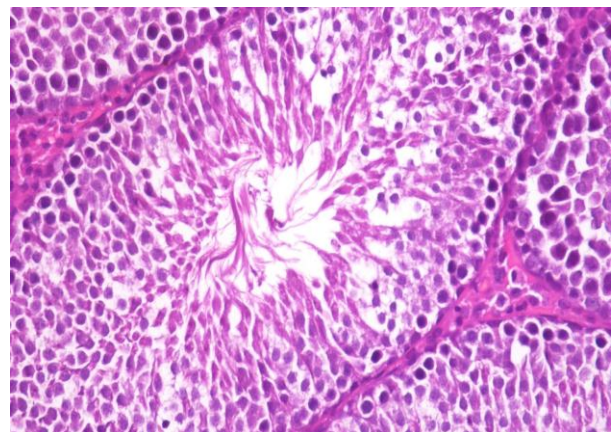


Fig. 11. Rat testis from group 6 normal histological architecture of seminiferous tubules and complete spermatogenesis (H & E X 400)

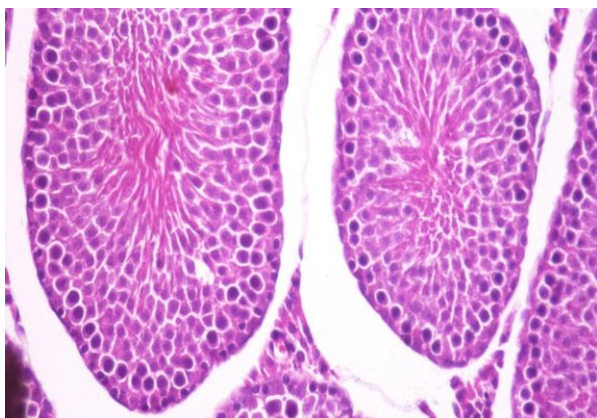


Fig. 12. Rat testis from group 6 normal histological architecture of seminiferous tubules and complete spermatogenesis (H & E X 400)

CONCLUSION

In the current study, treatment with horny goat weed significantly reduced testicular toxicity caused by cadmium chloride and increased male rat fertility. Horny goat weed can be considered as one of the natural sexual stimulants, due to a rise in testosterone and an increase in antioxidant enzyme activity. The effectiveness of herbal anti-sterility medications is encouraging because they reduce the amount of undesirable pharmacological features.

REFERENCE

- Aebi, H. 1984. Catalase in vitro. In: Methods in Enzymology, Academic Press, New York, pp. 479-500.
- Ahmad, M., S. Sultana and S. Fazl-i-Hadi, T. ben Hadda, R. Sofia, M. Zafar, M. Ajab Khan, M. P. Zada Khan and G. Yaseen. 2014. An ethnobotanical study of Medicinal Plants in high mountainous region of Chail valley (District Swat-Pakistan). *J Ethnobiol Ethnomed.* 10 (1):36.
- Ahmed, H. and M.Aslam. 2018. Evaluation of aphrodisiac activity of ethanol extract of *Ganoderma lucidum* in male Wistar rats. *Clinical Phytoscience.* 4:26:42.
- AIN, American Institute of Nutrition. 1993. Purified diet for laboratory Rodent, Final report. *J. Nutrition.* 123:1939-1951.
- Akesson, A., T.Lundh, M. Vahter, P.Bjellerup, J.Lidfeldt, C.Nerbrand, G. Samsioe, U. Strömberg and S. Skerfving. 2005. Tubular and glomerular kidney effects in Swedish women with low environmental cadmium exposure. *Environ Health Perspect.* 113:1627-1631.
- Allain, C.C. 1974. Cholesterol enzymatic colorimetric method. *J. of Clin. Chem.* 20:470-475.
- Ballester, J., M.C. Munoz, J. Dominguez, T. Rigaue, J.J. Guinovart and Z.J.E. Rodrigue. 2004. Insulin-dependent diabetes affects testicular function by FSH-and LH-linked mechanisms. *J. Androl.* 25(5):706-719.
- Bancroft, D., A. Stevens and R. Turner. 1996. Theory and practice of histological techniques. 4th ed, Churchill Livingstone, Edinburgh, London, Melbourne. 386-386.
- Campbell, J. A. 1963. Methodology of Protein Evaluation.RGA Nutr.Document R. 10 Led. 37. June meeting, New York.
- Campbell, N., J. P. Clark, V. J. Stecher, J. W. Thomas, A. C. Callanan, B. F. Donnelly, I. Goldstein and J. C. Kaminetsky. 2013. Adulteration of purported herbal and natural sexual performance enhancement dietary supplements with synthetic phosphodiesterase type 5 inhibitors, *J. of Sexual Medicine.* 10(7): 1842- 1849.
- Castelli, W. P., J. T. Doyle, T. Gordon, C. G.Hames, M. C.Hjortland, S. B. Halley, A. Kagan and W. J. Zuckel. 1977. HDL cholesterol and other lipids in coronary heart disease. The cooperative lipoprotein phenotyping study. *Circulation.* 55: 767-772.
- Chan, Y. M., J. P. Butler, N. E. Pinnell, F. P.Pralong, W. F.Crowley, C. Jr Ren, K. K. Chan and S. B. Seminara. 2011. Kisspeptin resets the hypothalamic GnRH clock in men. *The J. of clinical endocrinology and metabolism.* 96(6), E908-E915.
- Chen, M., J. Hao, Q.Yang and G. Li. 2014. Effects of icariin on reproductive functions in male rats. *Molecules (Basel, Switzerland).* 19(7):9502-9514.
- Drury, R.A. and E.A. Wallington. 1980. Carleton's histological technique 5th ed .London, New York, Oxford University press. P 138.
- Fossati, P. and L. Principe. 1982. Determination of triglycerides. *Clinical Chemistry.* 28: 2077-2078.
- Geoffroy-Siraudin, C., A. D. Loundou, F. Romain, V. Achard, B. Courbiere and M. H. Perrard. 2012. Decline of semen quality among 10 932 males consulting for couple infertility over a 20-year period in Marseille, France. *Asian J. Androl.* 14:584-590.
- Hai, Y., L. Zuo, M.Wang, R.Zhang, M.Wang, L.Ren, C.Yang and J. Wang. 2023. Icarin Alleviates Nonalcoholic Fatty Liver Disease in Polycystic Ovary Syndrome by Improving Liver Fatty Acid Oxidation and Inhibiting Lipid Accumulation. *Molecules (Basel, Switzerland).* 28(2):517.
- Hamed, N.A. 2021. Quinoa Mitigates Chlorfenapyr-Induced Testicular Toxicity in Rats. *Alex. Sci. Exch. J.* 42: 475-486.
- Hassanzadeh, N. and S. Mortazavi. 2016. Sublethal effects of cadmium chloride to testis of zebrafish (*Danio rerio*). *J Persian Gulf.* 7(23):51-60.
- Hegsted, D., R. Mills and E. Perkins. 1941. Salt mixture. *J. Biol. Chem.* 138:459 - 222.
- Henry, R.J. 1974. Clinical Chemist: Principles and Techniques. 2nd, Edition, Hagerstoun (MD), Harcer, ROW. P. 882.
- Holt, D. and M.Webb. 1987. Teratogenicity of ionic cadmium in the Wistar rat. *Arch.Toxicol.* 59(6):443-447.
- Jorgensen, N., M. Vierula, R.Jacobsen, E.Pukkala, A.Perheentupa and H. E. Virtanen. 2011. Recent adverse

- trends in semen quality and testis cancer incidence among Finnish men. *Int. J. Androl.* 34: 37–48.
- Kang, H.K., Y.H. Choi, H. Kwon, S.B. Lee, D.H. Kim, C.K. Sung, Y.I. Park and M.S. Dong. 2012. Estrogenic/antiestrogenic activities of a *Epimedium koreanum* extract and its major components: In vitro and in vivo studies. *Food Chem. Toxicol.* 50:2751–2759.
- Kilchevsky, A. and S. Honig. 2012. Male factor infertility in 2011: semen quality, sperm selection and hematospermia. *Nat. Rev. Urol.* 9:68–70.
- Kuang, A.K., J.L.Chen and M.D.Chen. 1989. Effects of yang-restoring herb medicines on the levels of plasma corticosterone, testosterone and triiodothyronine. *Zhong. Xi. Yi. Jie. He. Za. Zhi.* 9: 737-738, 710.
- Lee, R. and D.Nieman. 1996. Nutrition Assessment. 2nd Ed. Mosby, Missouri, USA. pp 591 – 594.
- Loebenstein, M., J.Thorup, D.Cortes, E. Clasen-Linde, J. M. Hutson and R. Li. 2019. Cryptorchidism, gonocyte development, and the risks of germ cell malignancy and infertility: a systematic review. *J. Pediatr. Surg.* S0022-3468(19):30450-6.
- Ma, H., X. He, Y. Yang, M. Li, D. Hao and Z. Jia. 2011. The genus *Epimedium*: an ethnopharmacological and phytochemical review. *J. Ethnopharmacol.* 134(3):519-541.
- Mahmoud, M., A. Al-Dhalimy and A. Al-Dujaily. 2019. Study of hematological and biochemical changes in sheep and goats infected with theileriosis at Al-Najaf province, Iraq. *Biochem Cell Arch.* 19(1):803-6.
- Masayasu, M. and Y.Hiroshi. 1979. A simplified assay method of superoxide dismutase activity for clinical use. *Clin. Chim. Acta.* 92: 337-342.
- McCann, D. and L. Kirkish. 1985. Evaluation of free testosterone in serum. *J. Clin. Immunoassay.* 8:234-236.
- Mitsumori, K., S. Shibutani, S. Sato, H. Onodera, J. Nakagawa, Y. Hayashi and M.Ando. 1998. Relationship between the development of hepato-renal toxicity and cadmium accumulation in rats given minimum to large amounts of cadmium chloride in the long-term: preliminary study. *Arch Toxicol.* 72:545–552.
- Moss, D.W. 1982. Alkaline Phosphates isoenzymes, *Clin.Chem.* 28: 2007 – 2016.
- Munir, N., Z.Mahmood, M.Yameen and G.Mustafa. 2020. Therapeutic Response of *Epimedium grandiflorum*'s Different Doses to Restore the Antioxidant Potential and Reproductive Hormones in Male Albino Rats. Dose-response: International Hormesis Society. 18(3):1559325820959563.
- Nayernia, K., M. Li and L. Jaroszynski. 2004. Stem cell based therapeutical approach of male infertility by teratocarcinoma derived germ cells. *Hum Mol Genet.* 13(14):1451-1460.
- Nishikimi, M., N.Appaji and K. Yagi. 1972. The occurrence of superoxide anion in the reaction of reduced phenazne methosulfate and molecular oxygen. *Biochem. Biophys Res Commun.* 48:849-854.
- Ognjanovic, B. I., S. Z. Pavlovic, S. D. Maletic, R. V. Zikic, A. S. Stajin, R. M. Radojicic and V. M. Petrovic. 2003. Protective influence of vitamin E on antioxidant defense system in the blood of rats treated with cadmium. *Physiological Research.* 52(5):563-570.
- Ohkawa, H. N. Ohishi and K. Yagi. 1979. Assay for lipid peroxide in animal tissues by thiobarbituric acid reaction. *Ann. Biochem.* 95:351-358.
- Patton, C. J. and S. R. Crouch. 1977. Spectrophotometric and kinetics investigation of the Berthelot reaction for determination of ammonia. *Anal. Chem.* 49:464-469.
- Pei, L.K., W.H. Huang, T.G. He and B.L.Guo. 2007. Systematic studies on quality of main species of Herba Epimedii. *ZhongguoZhong Yao Za Zhi.* 32:2217–2222.
- Qureshi, M., Mehjabeen, Noorjahan, Sh. Muhammad, F. Siddiqui, I. Baig and M. Ahmad. 2017. Phytochemical and biological assessments on *Lipidium meyenii* (maca) and *Epimedium sagittatum* (horny goat weed). *Pak. J. Pharm. Sci.* 30(1), 29-36.
- Rekha, D. K., A.K. Nyanatara, C. Ramswamy, R.P. Sheila, B.M. Ramesh and S.M. Venkappa. 2009. "Infertility in male Wistar rats induced by cadmium chloride: Role of ascorbic acid". *Journal of Chinese Medicine.* 41(11):616-621.
- Richmond, W. 1973. Preparation and properties of a cholesterol oxidase from *Nocardia* sp. and its application to the enzymatic assay of total cholesterol in serum. *Clin.Chem.* 19 (12): 1350.
- Sadik, N. A. 2008. Effects of diallyl sulfide and zinc on testicular steroidogenesis in cadmium-treated male rats. *J. Biochem. Mol. Toxicol.* 22: 345–353.
- SAS. 1988. SAS Users Guide: Statistics version 5th Ed., SAS.Institute Inc., Cary, NC.
- Schirmeister, J. 1964. Creatinine standard and measurement of serum creatinine with picric acid. *Deutsche Medizinische Wochenschrift.* 89: 1018-1021.
- Shindel, A.W., Z.C Xin and G. Lin. 2010. Erectogenic and neurotrophic effects of icariin, a purified extract of horny goat weed (*Epimedium spp.*) in vitro and in vivo. *J Sex Med.* 7(1):1518-1528.
- Skakkebaek, N. E., E. Rajpert-De Meyts, and K. M. Main. 2001. Testicular dysgenesis syndrome: an increasingly common developmental disorder with environmental aspects. *Hum. Reprod.* 16:972–978.
- Su, B., D.Cheng, G.Chen, S.Zhang, L.Wang, X. Wu and S.Tang. 2022. Icariin Attenuation of Diabetic Kidney Disease Through Inhibition of Endoplasmic Reticulum Stress via G Protein-Coupled Estrogen Receptors. *J. of biomedical nanotechnology.* 18(2):488–497.
- Sze, S.C., Y.Tong, T.B.Ng, C.L. Cheng and H.P. Cheung. 2010. Herba *Epimedii*: Anti-oxidative properties and its medical implications. *Molecules.* 15:7861–7870.
- Takiguchi, M. and S.Yoshihara. 2006. New aspects of cadmium as endocrine disruptor. *Environ. Sci.* 13:107–116.
- Tietz, N. M. 1976. Fundamental of Clinical Chemistry, Philade 1 phia, (2) W.B. pp. 53-56.

- Toppo, R., B. K.Roy, R. H.Gora, S. L. Baxla and P. Kumar. 2015. Hepatoprotective activity of *Moringa oleifera* against cadmium toxicity in rats. *Veterinary world*. 8(4):537.
- Twisk. J, D.L. Gillian-Daniel, A.Tebon, L.Wang, PH.R. Barrett and A.D. Attie. 2000. The role of the LDL receptor in apolipoprotein B secretion. *J. Clin Invest*. 105:521–32.
- Wan, H. T., D. D.Mruk, C. K. Wong and C. Y. Cheng. 2013. The apical ESBTB- BM functional axis is an emerging target for toxicant-induced infertility. *Trends Mol. Med*. 19:396–405.
- Wang, M., H.Gao, W. Li and B. Wu. 2020. Icarin and its metabolites regulate lipid metabolism: From effects to molecular mechanisms. *Biomed. Pharm*. 131, 110675.
- While, B. A., M.M. Erickson and S.A. Steven. 1970. *Chemistry for Medical Theologists*. 3 RdEd., C.V. Mosby Company Saint Louis, USA. p.662.
- Williamson, E.M., D.T. Okpako and F.J. Evans. 1996. *Pharmacological methods in phytotherapy research: Selection preparation and pharmacological evaluation of plant material*. Ltd., London. 1:191-212.
- Wirth, J. J. and R. S. Mijal. 2010. Adverse effects of low-level heavy metal exposure on male reproductive function. *Syst. Biol. Reprod. Med*. 56:147–167.
- Yao, W., K.Wang, X.Wang, X.Li, J.Dong, Y.Zhang and X.Ding. 2021. Icarin ameliorates endothelial dysfunction in type 1 diabetic rats by suppressing ER stress via the PPARalpha/Sirt1/AMPKalpha pathway. *J. Cell Physiol*. 236:1889–1902.
- Ye, L. C., and J. M. Chen. 2001. Advances in study on pharmacological effects of Epimedium. *Zhongguo Zhong Yao Za Zhi*. 26:293–295.
- Zhang, Z.B. and Q.T. Yang. 2006. The testosterone mimetic properties of icarini. *Asian J. Androl*. 8:601–605.
- Zhu, Q., X.Li and R. S. Ge. 2020. Toxicological Effects of Cadmium on Mammalian Testis. *Frontiers in genetics*. 11, 527.

الملخص العربي

التأثيرات المحتملة لعشبة العنز علي مستوي الخصويه لدي ذكور الفئران المصابه بكلوريد الكاديوم:

دراسه بيوكيميائيه و هستوباثولوجيه

أمل ناصف زكي ناصف - نجلاء علي الشيخ

المنشط للحويصله وهرمون الملوتن) - وظائف الكبد والكلبي ودهون الدم، كذلك تم استئصال الخصيه لقياس مستويات الهرمونات الجنسيه بها ونشاط الانزيمات المضاده للاكسده بالخصيه. وقد أظهرت النتائج أن استخدام عشبة العنزه أدي إلي تحسن ملحوظ بوظائف الكبد والكلبي ودهون الدم ونشاط الانزيمات المضاده للاكسده ومستويات الهرمونات الجنسيه سواء بالسيرم او الخصيه.

الخلاصة: قد يكون الاستخدام المعتدل لعشبه العنز مفيداً لتحسين الأداء الجنسي للذكور ويعتبر أحد المنشطات الجنسيه الطبيعيه.

الكلمات المفتاحيه: الخصويه، عشبه العنز، الهرمون الملوتن، كلوريد الكاديوم، وظائف الكبد.

هدفت الدراسه الحاليه إلي معرفه تأثير عشبه العنز علي مستويات الخصويه لدي ذكور الفئران المصابه بكلوريد الكاديوم. قسمت الفئران إلي مجموعتين رئيسيتين: المجموعه الرئيسيه الأولي (6 فئران) وهي المجموعه الضابطه السالبه (السليمه). المجموعه الرئيسيه الثانيه: (30 فأر) تم حقنهم داخل التجويف البريتوني بكلوريد الكاديوم بجرعه 1% (1 مل / 100 جرام من وزن الجسم) وذلك لاحداث خلل جنسي بالفئران (عقم) . وتم تقسيمهم إلي خمس مجاميع فرعيه: المجموعه (1) المجموعه الضابطه الموجبه - مجموعه (2) تأخذ سيترات السيلدينافيل (الفياجرا) 5 مجم /كجم كمعلق مائي طوال 28 يوم. المجموعات (3-4-5) تأخذ عشبه العنز بتركيزات 10-15-20% في الوجبه علي التوالي. وفي نهايه التجربه بعد 28 يوم تم تجميع عينات الدم لقياس مستوي الهرمونات الجنسيه (التسترون الكلي - الهرمون