



Original article

Deleterious effect of nandrolone decanoate on the liver of adult male albino rats and the possible ameliorating role of taurine

Rasha. A. Agaga¹, Mohammed Sabry^{1*}, Nehal. A. Amer¹.

¹- Human Anatomy and Embryology department, Faculty of medicine, Zagazig university, Egypt

ARTICLE INFO

Article history:

Received 4 July 2023

Received in revised form 4 september 2023

Accepted 5 september 2023

Keywords:

Nandrolone

Taurine

Liver

caspase 3

α SMA.

ABSTRACT

Background: Nandrolone decanoate (NDD) is a widely used anabolic androgenic steroid as it exhibits androgen-like properties, anabolic effects, and liver-damaging effects. The study's aim is to assess the hepatotoxic damage caused by NDD in adult male albino rats and to elucidate any potential protective effect of taurine in the reduction of this damage. Thirty adult male albino rats were used in this study and were randomly divided into three groups: Control group consisted of 10 rats that did not receive any treatment and received only good diet for 8 weeks. Nandrolone treated (NDD) group: contained 10 rats were injected intramuscularly (by Nandrolone decanoate (5mg/kg B.w) twice / week for 8 weeks. NDD+Taurine group: consisted of 10 rats that had received Nandrolone decanoate by intramuscular injection at a dose of 5mg/kg body weight twice a week for 8 weeks and Taurine by oral gavage at a dose of 100mg/kg body weight every day for 8 weeks The hepatic cells in the NAD-treated group had harmful changes, including dilated, obstructed central and portal veins, a proliferating bile duct, enlarged collagen fibers, and a robust response to caspase 3 and alpha smooth actin. While the NDD+Taurine group showed moderate improvement in general architecture of the liver. **Conclusion:** The study verified the protective effect of Taurine administration on Nandrolone induced hepatic damage.

Introduction

Anabolic-androgenic steroids (AAS) are substances that are derived synthetically from testosterone (Tugyan et al., 2013). Nandrolone is commonly used anabolic androgenic steroid because of its androgenic capability associated with its excellent anabolic properties (Andreato et al., 2013). Nandrolone belongs to the class II of (AAS)

which is composed of 19-nor-testosterone-derivatives (P Busardo et al., 2015).

These steroids can be used for treating conditions resulting from steroid deficiency, such as delayed puberty & hypogonadism and other diseases, for example, bone mineralization, failure of bone marrow and wasting of muscle (Turillazzi et al., 2016).

Nowadays, it is commonly used by athletes, bodybuilders, and weightlifters in order to increase their physical performance and also the muscle bulk due to its beneficial properties such as tissue building properties (Ali et al., 2018).

It was found that AAS abusers use these substances for giving them a sensation of being brave and heroes. It has been noted that AAS has many behavioral alterations effects like delusions, mania, rage and violence causing vicious crimes. (Ahmed and El-Awdan , 2015).

Many scientists recorded many damaging effects of abusing these anabolic drugs that include cardiovascular disorders causing sudden death, acute hepatic inflammation, jaundice, renal disorders and injury of the testes with subsequent infertility, increased blood pressure, and behavioral affections (AL-Kennany and Al-Hamady, 2014).

The accepted dose of nandrolone decanoate is about 50–100 mg every month. but the abusers take doses about 10–100 times over than the above-mentioned doses (Novaes Gomes et al., 2014). The mechanisms that are involved in nandrolone decanoate behavioral changes are oxidative damage, inflammation, disturbance in neurotransmitters and apoptosis of neurons (Pieretti et al., 2013; Tanekar et al., 2013; Rainer et al., 2014).

Taurine is a free amino acid inside the cells, present in high concentrations in the brain of mammals and can be ingested mainly from sea foods (Suárez et al., 2016).

Taurine is a beta amino acid synthesized from cysteine and methionine. It has several many good physiological properties, including antioxidation, detoxification, stabilization of the cell membrane and calcium homeostasis (El-Maraghi et al., 2018).

Additionally, it has an anti-apoptotic effect and exerts many protective effects on several body organs against heavy metal or drug induced toxicity (Isaac, 2019).

2. MATERIALS AND METHODS

2.1. Ethical declaration

The Institutional Animal Care and Use Committee of Zagazig University accepted the rat experiments (approval no: (ZU-IACUC/3/F/420/2022)). The guidelines outlined in the Guidelines for the Care and Use of Laboratory Animals were followed by all maneuvers. All the experiments and animal procedures followed the

ARRIVE guidelines (Kilkenny et al.,2010), the UK Animals Scientific Procedures, the Guide for the Use and Care of Laboratory Animals (Clark et al.,1997).

2.2. Chemicals and drugs

We purchased Nandrolone Decanoate which has the trade name (Deca-Durabolin) from an Organon company in the form of ampoule 25 mg and Taurine from Sigma Chem.Com.,St .Louis, Mo.U.S.A

2.3. Experimental Animals

Thirty male Albino rats were accustomed for a week before being randomly divided into 3 groups (n = 10). The rodents were housed in the Creature House, Personnel of medication Zagazig College, with admittance to food and water not obligatory. Temperature (24 ± 1 °C), relative humidity (55 ± 5 %), ventilation frequency (18 times per hour), and a 12-hour light/dark cycle were all maintained in the housing. The rats were kept in plastic cages with soft chip bedding and four rats per cage. All through the examination, the wood chips were reestablished at regular intervals. Every day, the rats' health was monitored. The researchers took every precaution to prevent pain or discomfort.

2.4. Experimental Design

Thirty rats were randomly classified into three groups, Control group: consisted of 10 rats that did not receive any treatment and received only good diet for 8 weeks. ND group: consisted of 10 rats injected intramuscularly by Nandrolone decanoate (5mg/kg B.w) twice / week for 8 weeks (Tugyan et al., 2013) & (Isaac, 2019). ND+ Taurine group: This group consisted of 10 rats injected intramuscularly by Nandrolone decanoate at a dose of 5mg/kg body weight twice /week for 8 weeks and administered Taurine by oral gavage at a dose of 100mg/kg body weight every day for 8 weeks (Isaac, 2019). At the end of the experimental period, intra-peritoneal injection of 100 mg of thiopental for anaesthetization of the rats in all groups prior to scarification. Each rat underwent a laparotomy, and the liver specimens were thoroughly removed and prepared for histological analysis.

2.5. Histological analysis by Light microscopic examination:

The liver tissue samples of different groups were immersed in formaline neutral buffered solution 10% and later on the tissue were processed for paraffin wax ,the sections were prepared and stained with Haematoxylin and eosin stain (H&E)

(Bancroft et al., 2008), Mallory trichrome stain (prophet et al., 1992) and PAS stain (McMANUS., 1946) and the slides were examined by light microscope at Anatomy department, faculty of medicine Zagazig university

2.6. Immunohistochemical stains:

Sections were deparaffinized in xylene and then dehydrated using ethanol at various ethanol concentrations. The sections were cooked in 0.01 mol/L citrate buffer in a microwave pressure cooker for 20 minutes after endogenous peroxidase activity had been blocked with 3% hydrogen peroxide for 15 minutes. Normal horse serum was used to prevent non-specific binding for 20 minutes at room temperature after the slides had cooled to that temperature. For an additional 30 minutes, the sections were treated with anti-Caspase-3 and anti- α -smooth actin antibodies. The sections will then be stained with avidin-biotin complex (ABC), and ABC chromogen will be used to show where the binding sites are. Between each step, phosphate buffered saline was used to rinse, and at the end, Mayer's hematoxylin was used to counterstain all sections. The packages came from DAKO Life Trade Egypt (sc-56, lab vision, clone PC-10, Santa Cruz Biotechnology Inc., Santa Cruz, USA). (Van Noorden, 1990):

2.7. Histo-morphometrical analysis

Morphometric examination was done on every rat in each group. After immunostaining with the anti-caspase and anti- α -SMA antibodies, perceptible fields across the images captured by the light microscope at 400 \times amplification were selected to evaluate the % area of caspase-3 and α -SMA positive in the hepatic tissues from 10 rats/group. Furthermore, the % area of Mallory's trichrome-positive area and PAS positive area were likewise determined in the captured fields from the 10 rats/group. Image J analysis software (Fiji image j; 1.51 n, NIH, USA) was used at Human Anatomy and Embryology Department, Zagazig University. (Jensen, 2013).

2.8. Statistical analysis:

Numbers are provided as means standard deviation. All statistical analysis was performed using SPSS.19. One-way ANOVA was used to examine the data, and Tukey's post hoc multiple comparisons test was used to compare the groups. Statistics were considered significant for values with $p \leq 0.05$ (Field, 2013).

3. Results

3.1. Histopathological results for Hematoxylin and eosin (H&E) stained sections:

Control group of liver slices stained with H&E shows that the majority of hepatocytes have cytoplasm that is acidophilic and vesicular nuclei. There are a few binucleated hepatocytes. Radiating hepatic cords emerging from the central vein could be observed (fig.1.A1). The Portal area shows normal portal vein and bile duct with cuboidal lining epithelium. Blood sinusoids are present in between hepatic cords (fig1.B1).

While the NDD group shows hepatocellular alterations and a significant alteration of the usual hepatic organization. It is also common to see hepatocytes with darkly colored nuclei and vacuolated cytoplasm. Dilated central vein showing discontinuity of endothelium within of central vein lumen (fig.1.A2). The portal region displayed a dilated, congested portal vein, along with apparent wall thickening and infiltration of mononuclear cells also there is newly formed bile ductile (fig1.B2).

Comparing the H&E-stained liver sections of the NDD + taurine group to those seen in the NDD group, there was some improvement. While some hepatocytes have darkly stained nuclei, the majority of hepatocytes have vesicular nuclei with acidophilic cytoplasm originating from seemingly normal central veins. A few hepatocytes have two nuclei. The endothelial lining of the hepatic cords and the hepatic sinusoids looked to be intact (fig.1.A3). The bile duct, arteriole, and portal vein are all in normal condition. The vesicular nuclei of the majority of hepatocytes contained acidophilic cytoplasm. Other hepatocytes have nuclei that are heavily pigmented (fig1.B3).

3.2. Histological results of collagen fibers using PAS stain

PAS-stained sections from the control group reveal abundant glycogen that caused robust positive PAS reactions in the cytoplasm and cell membranes of the hepatic cells (Fig.2.A). Owing to a lack of glycogen, the cytoplasm and cell membranes of the NDD treated group's hepatocytes show faint positive PAS reactions (Fig.2.B). While the ND + taurine group shows moderate reaction (Fig.2.C).

3.3. Histological results of liver fibrosis using Mallory trichrome

Mallory Trichrome-stained liver slices from the control group show the lining of blood sinusoids and a little quantity of blue colored stained

collagen fibers around the central and portal veins (Fig3 A&B). In contrast to the NDD treated group that demonstrates substantial collagen fiber around the central veins, blood sinusoids and portal area (Fig3 C&D). While NDD+ taurine group shows few depositions of collagen fibers around the central veins, blood sinusoids and portal area. This group showed marked improvement and appears like a control group (Fig3 E&F).

3.4. Immunohistochemical results of Alpha smooth muscle actin immunostaining.

Immunohistochemical stained sections of control groups reveal negative reactions for α SMA in the wall of sinusoids, central and portal veins (Fig4A).

While sections of NDD treated groups reveal strong positive reactions (Fig4B). The NDD+ taurine group reveals moderately positive reactions (Fig4C).

3.5. Immunohistochemical results of caspase 3 immunostaining.

Immunohistochemical stained sections of control groups reveals negative cytoplasmic responses for caspase 3 in hepatocytes (Fig 5A)

and strong positive cytoplasmic responses for caspase 3 in hepatocytes of NDD treated group

(Fig 5B). While hepatocytes from the NDD + taurine group display faint positive cytoplasmic responses for caspase 3 (Fig 5C).

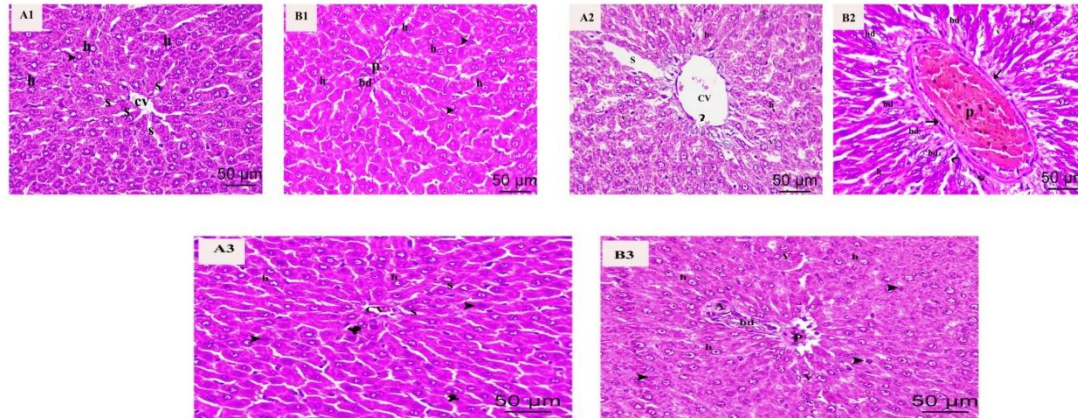
3.6. Morphometric results in different studied groups:

When compared to the control group, NDD treated group had a significantly higher area percentage of collagen fibers. Although it was significantly lower in NDD + taurine group than in NDD group, it was still higher than in the control group (Fig 3 G).

Comparing NDD treated group to the control group reveals a considerably higher area percentage of immunological response to α SMA. Although it was significantly lower in NDD + taurine than in NDD treated group, it was still higher than in the control group (Fig 4D).

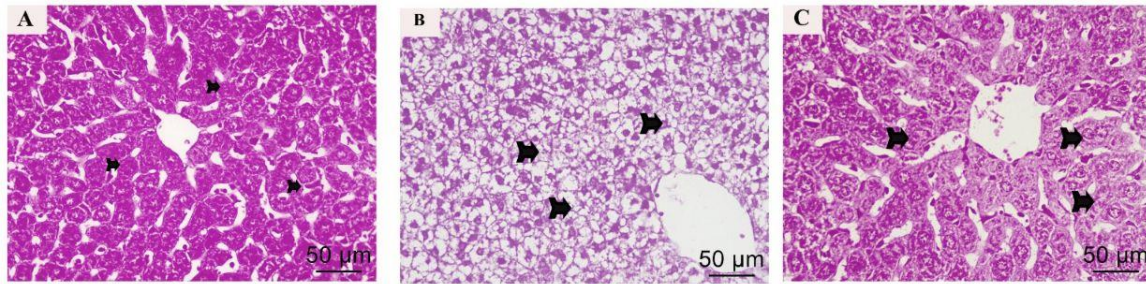
Comparing NDD treated group to the control group reveals a considerably higher area percentage of the immunological response to caspase 3. Although it was significantly lower in NDD + taurine group than in NDD group, it was still higher than in the control group (Fig 5D).

Figure 1. Representative images of H&E-stained sections of rat liver tissues of different experimental groups. control (A1 & B1), NDD treated (A2&B2) and NDD + taurine (A3&B3) groups.



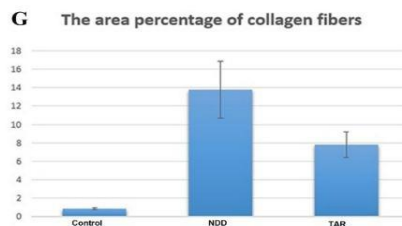
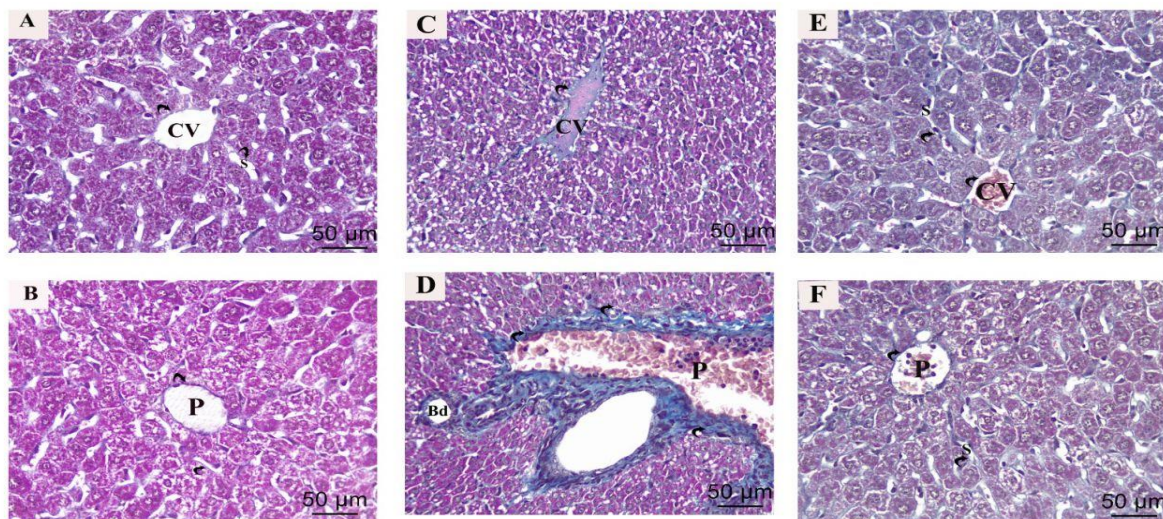
A1: most hepatocytes (h) with vesicular nuclei and acidophilic cytoplasm. Some binucleated hepatocytes (arrowhead) are present. Hepatic cords radiating from normal central vein (cv). Hepatic sinusoids(s) appear narrow, radiating between hepatic cords with intact endothelial lining. B1: Portal area shows normal portal vein (p) and bile duct with cuboidal lining epithelium. Some binucleated hepatocytes (arrowhead) are present. Normal blood sinusoids (s) in between hepatic cords. A2: shows a massive change of the normal hepatic arrangement and hepatocellular changes. Most Hepatocytes (h) with darkly stained nuclei and vacuolated cytoplasm (v) is observed. Dilated central vein (cv) with discontinuity of its endothelium (curved arrow) inside lumen of central vein. B2: The portal area showed dilated congested portal vein (p) with apparent thickening of its wall (straight arrow) and mononuclear cellular infiltration(curved arrows). Newly fomed bile ductules (bd). Most Hepatocytes (h) with dark stained nuclei and vacuolated cytoplasm (v) are observed. A3: shows some improvement in comparison to that observed in the treated group. Most hepatocytes (h) had vesicular nuclei with acidophilic cytoplasm radiating from apparently normal central vein (cv) while other hepatocytes have dark nuclei (arrow head). Some hepatocytes are binucleated(tailed arrow). Hepatic sinusoids (s) appeared narrow, radiating between hepatic cords with intact endothelial lining. B3: Portal area shows normal portal vein(p), bile duct and arteriole (a). Most hepatocytes (h) had vesicular nuclei with acidophilic cytoplasm. Some other hepatocytes have darkly stained nuclei (arrow head). Some hepatocytes are binucleated(tailed arrow). Scale bar = 50 µm, H&E x400.

Figure 2. Representative images of PSA-stained sections of liver among the different experimental groups. Control (A), NDD treated (B) and NDD + taurine (C) groups.



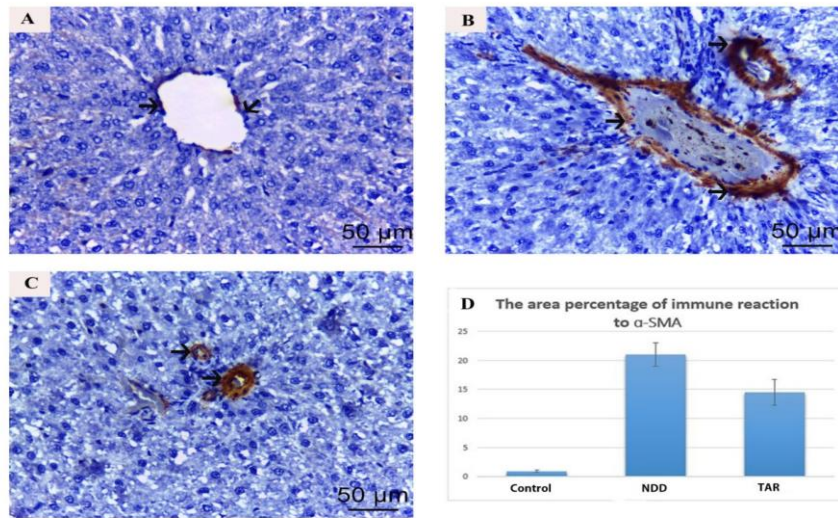
A: reveals strong positive PAS reactions (tailed arrows) in the cytoplasm and cell membranes of hepatocytes. B: reveals weak positive PAS reactions (tailed arrows). C: reveals positive PAS reaction (tailed arrows) in the cytoplasm and cell membranes of hepatocytes. Scale bar = 50 µm, PAS x400.

Figure 3. Representative images of Mallory's Trichrome stained sections of liver among the different experimental groups, control (A&B), NDD treated (C&D) and NDD + taurine (E&F) groups.



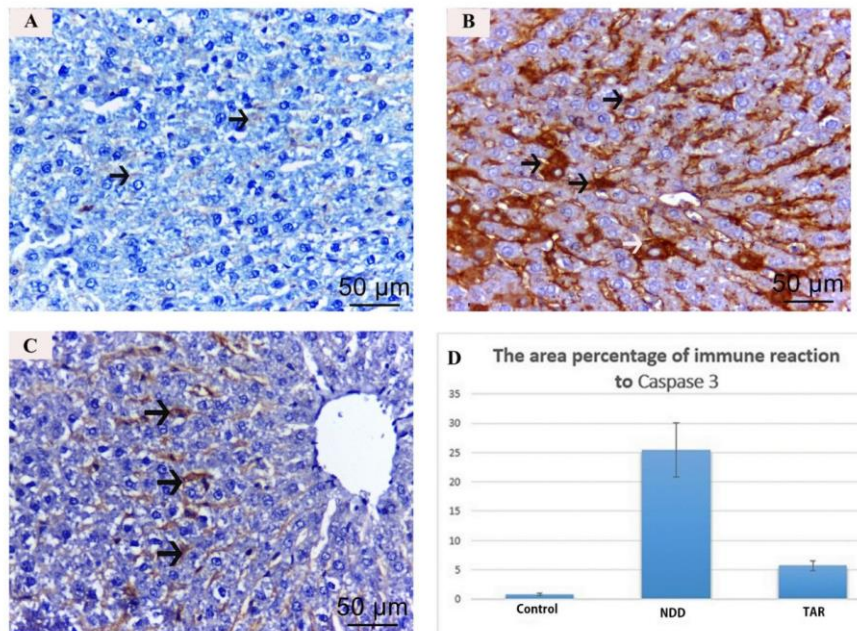
A: scanty amount of blue colored stained collagen fibers (curved arrow) around the central vein (cv), the lining of blood sinusoids. B: reveals few blue colored stained collagen fibers (curved arrow) in the portal area (p). C: shows extensive deposition of collagen fibers (curved arrow) around the central veins and blood sinusoids. D: reveal extensive blue colored stained collagen fibers (curved arrow) in the portal area (p). E: shows moderate deposition of collagen fibers around the central veins (cv) and blood sinusoids (s). F: reveal moderate blue colored stained collagen fibers (curved arrow) in the portal area (p) and blood sinusoids (s). Scale bar = 50 µm, Mallory's Trichrome x400 G: Bar chart for area percent of collagen fibers in different experimental group showing significant elevation of area percent of collagen (x400) in ND treated group as compared to control group at ($p < 0.05$) using One-way ANOVA and Tukey's post hoc multiple comparisons test.

Figure 4. Representative images of sections of rat liver showing α SMA immunoreactivity in the different experimental groups (A) control , (B) NDD treated and (C) NDD + Taurine groups.



A: shows negative immune reaction for α SMA in the wall of central vein (arrows). B: shows strong immune reaction to α SMA in the wall of central vein and portal vein (arrows). C: shows moderate immune reaction to α SMA positivity in the wall of portal vein (arrows). Scale bar = 50 μ m, α SMA x400. (D) Bar chart representing the analysis of the area % α SMA expression of the three different experimental groups indicating significant increase in the expression of area % α SMA (x400) in ND treated group as compared to control group at ($p < 0.05$) using One-way ANOVA and Tukey's post hoc multiple comparisons test.

Figure 5. Representative images of sections of rat liver showing caspase-3 immunoreactivity in the different experimental groups (A) control group, (B) NDD treated and (C) NDD+ Taurine groups.



A: reveals negative cytoplasmic responses for caspase 3 in hepatocytes (arrows). B: reveals strong positive cytoplasmic responses for caspase 3 in hepatocytes (arrows). C: reveals faint positive cytoplasmic responses for caspase 3 in hepatocytes (arrows). Scale bar = 50 μ m, caspase 3 x400. (D) Bar chart representing the analysis of the area % caspase-3 expression (x400) of the three different experimental groups indicating significant increase in the expression of area % of caspase 3 immune reaction in ND treated group as compared to control group at ($p < 0.05$) using One-way ANOVA and Tukey's post hoc multiple comparisons test..

Discussion

The liver plays a critical role in detoxifying various medications, such as barbiturates, steroids, and many industrial solvents. Due to its high functional reserve, hepatic tissues can sustain significant damage before signs of failure become apparent (Isenberg et al., 2000).

Albino rats are commonly used as an experimental model in this study due to their ease of breeding and maintenance. They also provide a convenient and straightforward means of assessing the effects of pollutants (Bouaziz et al., 2005). Furthermore, the liver histology of rats is similar to that of humans, making them an appropriate animal model for investigating the liver's structure and function (Baratta et al., 2009).

The histological examination of the control group's liver tissue revealed a lobular structure consisting of hepatic cords that emanate from the central vein. The hepatic cords comprise polygonal hepatocytes with acidophilic cytoplasm and rounded vesicular nuclei, with a significant number of cells having two nuclei. The hepatic cords are separated by blood sinusoids, while portal triads are present at the lobule's perimeter, with the central vein located at the core of the hepatic lobule. The portal triads consist of hepatic artery branches, portal veins, and intrahepatic bile ducts. These observations are consistent with the findings of previous studies by Apte et al. (2007) and Baratta et al. (2009).

In the NDD treated group, hematoxylin and eosin-stained sections revealed several histological changes, such as disrupted normal hepatic architecture and numerous hepatocytes with cytoplasmic vacuolization. These findings are similar to those reported by Seacat et al. (2003), who observed enlarged hepatocytes with vacuolated cytoplasm.

sherlock and dooly (2002) reported that cytoplasmic vacuolation is an essential initial response to various forms of cellular damage. It occurs due to increased intracellular water resulting from elevated cell membrane permeability. Other potential causes of this vacuolation include hypoxia, lipid accumulation in the cells and ischemia. Additionally, Gutowska et al.(2011) suggested that macrophages with numerous lipid droplets maybe responsible for the occurrence of vacuolated cells.

Furthermore, in the group treated with NDD, some hepatocytes exhibited darkly colored nuclei. Taylor et al. (2008) reported that hyperchromatic nuclei are a degenerative change that indicates apoptosis. This finding is consistent with their research.

The histological examination of Hematoxylin and Eosin-stained sections from the NDD group in this study revealed congested central veins, dilated portal veins, and blood sinusoids. In addition, infiltration of cells was observed at the portal. Hu et al. (2013) suggested that portal hypertension might have caused the central and portal vein congestion and dilation. On the other hand, Puche et al. (2013) proposed that the activation of nearby blood sinusoids, which have contractile properties, resulted in sinusoidal dilatation.

Inflammatory cellular infiltration around the portal and central veins is caused by oxidative stress, which triggers the production of inflammatory mediators (Rahman & Macnee, 2000).

The NDD-treated group in the current study exhibited bile duct proliferation. Richardson et al. (2007) reported that ductular reactions, which manifest as the formation of numerous structures resembling bile ducts in the portal area, are considered proliferative responses to various types of hepatic injury in all humans.

Micalopoulos et al. (2005) suggested that either the proliferative effect of bile salts' stasis on epithelial cells or the trans-differentiation of liver cells into biliary cells may contribute to bile duct proliferation. However, according to Roskams et al. (2004) and Alvaro et al. (2007), this cellular transformation could be triggered by the activation of hepatic stem cells, bile duct cell proliferation, or ductular metaplasia of mature liver cells.

A comparison of the hepatic structure between the NDD+ taurine-treated group and the NDD-treated group in the current study, using hematoxylin and eosin-stained sections, revealed an improvement in the former group. While some hepatocytes had apoptotic black nuclei, others had vesicular nuclei and acidophilic cytoplasm. The central vein was congested and dilated. Moreover, the portal area exhibited a significantly reduced level of cellular infiltration compared to the NDD-treated group. These findings are consistent with those reported by Zou et al. (2015).p

Microscopic analysis of the liver in the NDD + taurine-treated group revealed the presence of binucleated cells. Munglang et al. (2009) suggested that degraded cells may induce the formation of binucleated hepatocytes. Binucleation is considered a form of chromosomal hyperplasia resulting from cellular damage (Saud Alarifi et al., 2013).

Immune-staining of caspase-3 in the cytoplasm of hepatocytes from the control group's

liver slices showed negative reactions. This finding is consistent with the results reported by Zhou et al. (2001).

Liver slices from rats treated with NDD showed a significantly high positive response in the cytoplasm of liver cells when immunostained with caspase-3. These results are consistent with those reported by Soldani and Scovassi (2002), who suggested that reactive oxygen species (ROS) are a significant apoptotic signal. Zhang et al. (2003) further explained that the generation of excessive oxidative stress may stimulate the extrinsic or intrinsic pathways of apoptosis, leading to the activation of the caspase pathway for apoptosis, ultimately resulting in caspase 3 activation (Guicciardi & Gores, 2005).

The positive periodic acid-Schiff (PAS) responses in the cytoplasm and cell membranes of hepatocytes in the control groups indicated that a significant amount of glycogen is present in normal liver tissues. This finding is consistent with the findings of Abu-Dief et al. (2015).

In the current study, Mallory staining was employed to detect collagen fibers in the portal and central veins of liver slices from all control groups. These findings are consistent with the research conducted by Ali et al. (2015) and Alshawash et al. (2011).

Liver slices from all control groups in the current study showed negative cytoplasmic reactions for caspase 3 in the hepatocytes due to a decrease in apoptotic cells in healthy hepatic tissue. These results are consistent with the research conducted by Zhou et al. (2001) and El Kalawy et al. (2017).

In the current study, the NDD-treated group exhibited a mild periodic acid-Schiff (PAS) reaction due to the depletion of glycogen granules. These findings are consistent with those reported by Sakr et al. (2004), who suggested that the decrease in carbohydrates was a result of the liver being under more pressure, leading to higher energy consumption.

Taurine is a major free intracellular amino acid in humans. In the presence of vitamin B6, cysteine and methionine can be converted to taurine in the liver. Taurine is also present in meat and shellfish (Lourenco and Camilo, 2002).

Various transporters facilitate the uptake and absorption of taurine in the small intestine before it can enter cells and tissues (Miyazaki and Matsuzaki, 2014).

The liver is a target organ for the effects of taurine. Taurine has been shown to increase bile acid production, prevent hepatic stellate cell growth, and

reduce oxidative stress and liver fibrogenesis (Miyazaki et al., 2019). Reduced dietary taurine intake can lead to significant liver dysfunction, fibrosis, and mitochondrial dysfunction (Warskulat et al., 2006). Recent studies have demonstrated that taurine can protect against a range of drugs that are oxidized by cytochrome P450 2E1 (Schaffer et al., 2014).

Taurine's protective effects on the liver can be attributed to its anti-oxidative, anti-inflammatory, and membrane-stabilizing properties. Taurine has been shown to reduce transaminases and inflammatory cytokines, increase liver proteins, and activate antioxidant defense mechanisms (Miyazaki et al., 2019; Miyazaki and Matsuzaki, 2014; Niknahad et al., 2017).

Taurine has been shown to reduce the production of fibrogenic mediators in mice with iron overload-induced liver fibrosis. A 40% increase in hepatic taurine levels was found to improve liver function. Taurine's ability to reduce inflammatory mediator levels and improve oxidative stress appears to contribute to the improvement in hepatic fibrosis (Zhang et al., 2014; Gabr et al., 2019).

Taurine has been shown to possess protective properties against various drugs and toxins, according to Elham Nikkhah et al. (2021) who reported that taurine can reduce free radicals and suppress cytochrome P450 2E1 activity. However, the lack of human and clinical data remains a barrier to the use of taurine as a novel therapeutic.

Conclusion

Collectively, our outcomes detected a light on the potential relieving effect of Taurine on the hepatic damage induced by NDD through its antiapoptotic and anti-fibrotic effects. As a result, it's possible that the taurine could be used as a new adjuvant in the prevention strategy in the athletics used NDD.

Funding

The authors have no financial or personal relationship with any third party

Competing Interests

The authors declare that they have no competing interests.

References

- 1- Ali^a, D. M.; Labib^{2b}, D. A. A.; & Mohamed^c, M. M. N.(2018): the protective role of coenzyme Q10 against nandrolone decanoate-induced cardiotoxicity in rats: biochemical, genetic, histological and immunohistochemical

- study: Egypt J forensic sci. appli. Toxicol; 18(1):19-34.
- 2- **Al-Kennany, E. R., & Al-Hamdany, E. K. (2014):** Pathological effects of anabolic steroid (Sustanon®) on liver of male rats: Iraqi Journal of Veterinary Sciences; 28(1):31-39.
 - 3- **Andreato, L. V.; Esteves, J. V. D. C.; Almeida, F. N.; da Silva Ribeiro, T. A.; Barrena, H. C.; Peres, S. B.; & de Moraes, S. M. F. (2013):** Use of the anabolic steroid nandrolone decanoate associated to strength training in Wistar rats. Acta Scientiarum. Biological Sciences; 35(2): 283-291
 - 4- **El-Maraghi, E. F.; Abdel-Fattah, K. I.; Soliman, S. M.; & El-Sayed, W. M. (2018):** Taurine provides a time-dependent amelioration of the brain damage induced by γ -irradiation in rats. Journal of hazardous materials; 359: 40-46.
 - 5- **Isaac, M. R. (2019):** Effects of Anabolic Steroids on the Histological Structure of Renal Cortex of Adult Male Albino Rats and the Possible Protective Role of Taurine. Egyptian Journal of Histology; 42(2): 346-357.
 - 6- **Bancroft, J.D. and Gamble, M. (2008)** Theory and Practice of Histological Techniques. 6th Edition, Churchill Livingstone, Elsevier, China.
 - 7- **Prophet EB, Mills B, Arrington JB, Sobin LH (1992):** laboratory methods in histotechnology, fourth ed. Washington , DC; 132:53-58.
 - 8- **Mcmanus JF (1946):** histological demonstration of mucin after periodic acid. Nature; 158:
 - 9- **Novaes Gomes, F.G.; Fernandes, J.; Vannucci Campos, D.; Cassilhas, R.C.; Viana, G.M.; D'Almeida, V.; de Moraes Rêgo, M.K.; Buainain, P.I.; Cavalheiro, E.A.; Arida, R.M. (2014):** The beneficial effects of strength exercise on hippocampal cell proliferation and apoptotic signaling is impaired by anabolic androgenic steroids. Psychoneuroendocrinology ; 50: 106–117.
 - 10- **Pieretti, S., Mastriota, M., Tucci, P., Battaglia, G., Trabace, L., Nicoletti, F., Scaccianoce, S., 2013:** Brain nerve growth factor unbalance induced by anabolic androgenic steroids in rats. Med. Sci. Sports Exerc; 45:29–35.
 - 11- **Rainer, Q.; Speziali, S.; Rubino, T.; Dominguez-Lopez, S.; Bambico, F.R.; Gobbi, G.; Parolaro, D. (2014):** Chronic nandrolone decanoate exposure during adolescence affects emotional behavior and monoaminergic neurotransmission in adulthood. Neuropharmacology; 83: 79–88.
 - 12- **Suárez, L. M.; Muñoz, M. D.; Del Río, R. M., & Solís, J. M. (2016):** Taurine content in different brain structures during ageing: effect on hippocampal synaptic plasticity. Amino acids; 48(5): 1199-1208.
 - 13- **Tanehkar, F.; Rashidy-Pour, A.; Vafaei, A.A.; Sameni, H.R.; Haghghi, S.; Miladi-Gorji, H.; Motamedi, F.; Akhavan, M.M.; Bavarsad, K. (2013):** Voluntary exercise does not ameliorate spatial learning and memory deficits induced by chronic administration of nandrolone decanoate in rats. Horm. Behav ; 63: 158–165.
 - 14- **Tugyan, K.; Ozbal, S.; Cilaker, S.; Kiray, M., Pekcetin, C.; Ergur, B. U.; & Kumral, A. (2013):** Neuroprotective effect of erythropoietin on nandrolone decanoate-induced brain injury in rats. Neuroscience letters; 533: 28-33.
 - 15- **Turillazzi, E.; Neri, M.; Cerretani, D.; Cantatore, S.; Frati, P.; Moltoni, L.; & Fineschi, V. (2016):** Lipid peroxidation and apoptotic response in rat brain areas induced by long-term administration of nandrolone: the

- mutual crosstalk between ROS and NF-kB. *Journal of cellular and molecular medicine*; 20(4): 601-612.
- 16- **P Busardo, F.; Frati, P.; Di Sanzo, M.; Napoletano, S.; Pinchi, E.; Zaami, S.; & Fineschi, V.(2015):** The impact of nandrolone decanoate on the central nervous system. *Current neuropharmacology*; 13(1): 122-131.
- 17- **Van-Noorden, S. (1990):** principles of immunostaining. In *Histochemistry in Pathology*. By: Filipe M and Lake B, 3rd edition. Churchill Livingstone: 31-40.
- 18- **Jensen, E.C. (2013):** Quantitative Analysis of Histological Staining and Fluorescence Using Image J. *Anat Rec.*, 296: 378–381. <https://doi.org/10.1002/ar.22641>
- 19- **Field, A. (2013).** *Discovering statistics using IBM SPSS statistics*. Sage, New Delhi. p. 395-420.
- 20- **Alvaro, D., Mancino, M. G., Glaser, S., Gaudio, E., Marzioni, M., Francis, H., and Alpini, G. (2007):** Proliferating cholangiocytes: a neuroendocrine compartment in the diseased liver. *Gastroenterology*, 132(1), 415-431.
- 21- **Apte, U., Zeng, G., Thompson, M. D., Muller, P., Micsenyi, A., Cieply, B., Kaestner, K.H., and Monga, S. P. (2007):** β -Catenin is critical for early postnatal liver growth. *American Journal of Physiology-Gastrointestinal and Liver Physiology*, 292(6), G1578-G1585.
- 22- **Guicciardi M and Gores GJ. (2005):** Apoptosis: a mechanism of acute and chronic liver injury. *Gut* .54(7):1024-1033.
- 23- **Gutowska, I., Baranowska-Bosiacka, I., Siennicka, A., Rybicka, M., Baskiewicz, M., Machalinski, B., and Chlubek, D. (2011):** Fluoride effects on cholesterol influx and expression of the scavenger receptor CD36 in THP1 differentiated monocyte/macrophage cells. *Fluoride*, 44(3), 135.
- 24- **Hu, L. S.; George, J. and Wang, J. H. (2013):** Current concepts on the role of nitric oxide in portal hypertension. *World journal of gastroenterology: WJG*, 19(11): 1707-1717.
- 25- **Munglang, M.; Nagar, M. and Prakash, R. (2009):** Liver in carbaryl treated rats—a morphological and morphometric study. *J. Anat. Soc. India*, 58(1): 6-9.
- 26- **Puche, J; Saiman, Y and Friedman, S (2013):** Hepatic Stellate Cells and Liver Fibrosis. *Compr Physiol*, 3: 1473-1492.
- 27- **Rahman, I. and Macnee, W. (2000):** Oxidative stress and regulation of glutathione in lung inflammation. *European Respiratory Journal*, 16(3), 534-554.
- 28- **Richardson, M.M.; Jonsson, J.R.; Powell, E.E.; Brunt, E.M., et al., (2007):** Progressive fibrosis in nonalcoholic steatohepatitis: association with altered regeneration and a ductular reaction. *Gastroenterology*, 133(1), 80-90.
- 29- **Roskams, T. A. ; Theise, N. D. ; Balabaud, C. ; Bhagat, G. , Bhathal, P. S., Bioulac-Sage, P., and Finegold, M. J. (2004):** Nomenclature of the finer branches of the biliary tree: canals, ductules, and ductular reactions in human livers. *Hepatology*, 39(6), 1739-1745.
- 30- **Seacat, A. M., Thomford, P. J., Hansen, K. J., Clemen, L. A., Eldridge, S. R., Elcombe, C. R., and Butenhoff, J. L. (2003):** Sub-chronic dietary toxicity of potassium perfluorooctanesulfonate in rats. *Toxicology*, 183(1-3), 117-131.
- 31- **Sherlock, S. and Dooly, J. (2002):** *Diseases of the liver and biliary system*, 9th ed. Blackwell Scientific River Press; v-vii. <http://www.amazon.com>.

- 32- **Saud Alarifi, D. A., Al-Doaiss, A. A., Ali, B. A., Ahmed, M., and Al-Khedhairi, A. A. (2013):** Histologic and apoptotic changes induced by titanium dioxide nanoparticles in the livers of rats. *International journal of nanomedicine*, 8, 3937.
- 33- **Soldani, C., and Scovassi, A.I. (2002):** Poly(ADP-ribose) polymerase-1 cleavage during apoptosis: an update. *Apoptosis* 7, 321e328.
- 34- **Taylor, R.C.; Cullen, S.P. and Martin, S.J. (2008):** Apoptosis: controlled demolition at the cellular level. *Nature reviews, Molecular cell biology*, 9(3):231-241.
- 35- **Zhang B, Hirahashi J, Cullere X, and Mayadas TN. (2003):** Elucidation of molecular events leading to neutrophil apoptosis following phagocytosis cross-talk between caspase 8, reactive oxygen species, and MAPK/ERK activation. *J Biol Chem*. 278(31):28443-28454.
- 36- **Zhou, Z.; Sun, X. and Kang, Y. J. (2001):** Ethanol-induced apoptosis in mouse liver: Fas- and cytochrome c-mediated caspase-3 activation pathway. *American journal of pathology*, 159(1): 329-338.
- 37- **Zou, W., Liu, W., Yang, B., Wu, L., Yang, J., Zou, T., and Zhang, D. (2015):** Quercetin protects against perfluorooctanoic acid-induced liver injury by attenuating oxidative stress and inflammatory response in mice. *International immuno-pharmacology*, 28(1), 129-135. <https://doi.org/10.1016/j.intimp.2015.05.043>.
- 38- **Abu-Dief, E. E.; Khalil, K. M.; Abdel-Aziz, H. O.; Nor-Eldin, E. K. and Ragab, E.E. (2015):** Histological Effects of Titanium Dioxide Nanoparticles in Adult Male Albino Rat Liver and Possible Prophyllactic Effects of Milk Thistle Seeds. *Life Science Journal*, 12(2):115-123
- 39- **Ali, S. A.; Rizk, M.Z.; Abdelazim, S. A.; Darwish, H. A; and Kadry, M.O. (2015):** Role of potent antioxidants in regulation of smad-2 transcription and TGF- β 1 signaling in Nano sized titanium dioxide-induced oxidative injury in mice liver. *International Journal of Pharmacotherapy*, 5:17-26.
- 40- **Alshawash, M.A.; Abdullah, M.A.; Ismail, S. and Amin, Z.A. (2011):** Hepatoprotective effects of Orthosiphonstamineus extract on thioacetamide-induced liver cirrhosis in rats. *Evid Based Complement Altern Med*: 103039. Available at : <http://www.hindawi.com/journals/ecam/2011/103039.pdf>.
- 41- **Bouaziz, H.; Ghorbe, H.; Ketata, S., Guermazi, F. and Zeghala, N. (2005):** Toxic effects of fluoride by maternal ingestion on kidney function of adult mice and their suckling pups. *Fluoride*, 38(1):23–31.
- 42- **Baratta, J. L.; Ngo, A.; Lopez, B.; Kasabwalla, N.; Longmuir, K. J. and Robertson, R.T. (2009):** Cellular Organization of Normal Mouse Liver: A Histological, Quantitative Immunocytochemical, and Fine Structural Analysis. *Histochem. Cell Biol.*, 131(6): 713-726.
- 43- **Elkalawy, S.A.; hafez, M; Mostafa, A; abdelafattah, LI and kamar, SS (2017):** Histological and immunohistochemical study of the effect of omega-3 fatty acid on ifosfamide- induced liver injury adult male albino rat. *JMH*. 1 (2) : 135 -145.
- 44- **Isenberg, J.S.; Kamendulis, L.M.; Smith, J.H.; Ackley, D.C.; Pugh, G. Jr.; Lington, A.W. and Klaunig, J.E. (2000):** Effects of Di-2-ethylhexyl phthalate (DEHP) on gap-junctional intercellular communication (GJIC), DNA synthesis, and peroxisomal beta oxidation

- (PBOX) in rat, mouse, and hamster liver. *Toxicol. Sci.*, 56(1): 73-85.
- 45- **Micalopoulos, G.K.; Barua, L. and Bowen, W.C. (2005):** Transdifferentiation of rat hepatocytes into biliary cells after bile duct ligation and toxic biliary injury. *41(3): 535-544.*
- 46- **Sakr, S.A.; Abdel Samei, H.A. and Soliman, M.E.(2004):** Exploring hepatotoxicity of benomyl: histological and histochemical study on albino rats. *J Med Sci;4:77-83.*
- 47- **Lourenco, R., and M. E. Camilo. 2002.**“Taurine: A Conditionally Essential Amino Acid in Humans? An Overview in Health and Disease.” *Nutricion Hospitalaria* 17 (6):262–270.
- 48- **Miyazaki, T., and Y. Matsuzaki. 2014.**“Taurine and Liver Diseases: A Focus on the Heterogeneous Protective Properties of Taurine.” *Amino Acids* 46 (1): 101–110. doi:10.1007/S00726-012- 1381-0.
- 49- **Miyazaki, T., S. I. Sasaki, A. Toyoda, M. Shirai, T. Ikegami, Y. Matsuzaki, and A.Honda. 2019.**“Influences of Taurine Deficiency on Bile Acids of the Bile in the Cat Model.” *Advances in Experimental Medicine and Biology* 1155: 35–44. doi:10.1007/978-981-13-8023-5_4.
- 50- **Schaffer, S. W., T. Ito, and J. Azuma. 2014.**“Clinical Significance of Taurine.” *Amino Acids* 46 (1): 1–5. doi:10.1007/S00726-013-1632-8.
- 51- **Warskulat, U., E. Borsch, R. Reinehr, B. Heller-Stilb, I. M€ onnighoff, D. Buchczyk, M.Donner, et al. 2006.**“Chronic Liver Disease Is Triggered by Taurine Transporter Knockout in the Mouse.” *FASEB Journal : official Publication of the Federation of American Societies for Experimental Biology* 20 (3): 574–576. doi:10.1096/fj.05-5016fje.
- 52- **Niknahad, H., A. Jamshidzadeh, R. Heidari, M. Zarei, and M. M. Ommati. 2017.**“Ammonia-Induced Mitochondrial Dysfunction and Energy Metabolism Disturbances in Isolated Brain and Liver Mitochondria, and the Effect of Taurine Administration: Relevance to Hepatic Encephalopathy Treatment.” *Clinical and Experimental Hepatology* 3 (3): 141–151. doi:10.5114/ceh.2017.68833.
- 53- **Elham Nikkhah, Kobra Shirani, Ramin Rezaee & Gholamreza Karimi (2021):** Protective effects of taurine against hepatotoxicity induced by pharmaceuticals and environmental chemicals, *Toxicological & Environmental Chemistry*, DOI: 10.1080/02772248.2021.1892113.
- 54- **Gabr, S. A., N. S. Gabr, and W. M. Elsaed. 2019.**“Protective Activity of Taurine and Molecular Fibrogenesis in Iron Overloaded Hepatic Tissues.” *International Journal of Pharmacology* 15 (3): 418–427. doi:10.3923/ijp.2019.418.427.
- 55- **Zhang, Z., D. Liu, B. Yi, Z. Liao, L. Tang, Y. Dong and M. He. 2014.**“Taurine Supplementation Reduces Oxidative Stress and Protects the Liver in An Iron Overload Murine Model.” *Molecular Medicine Reports* 10 (5): 2255–2262. doi: 10. 3892/mmr.2014.2544.
- 56- **Kilkenny, C. Browne, W. Cuthill, I.C. Emerson, M. Altman, D.G. (2010):** Animal research: reporting in vivo experiments: the ARRIVE guidelines, *Br. J. Pharmacol.* 160 1577–1579,
- 57- **Clark, J.D. Gebhart, G.F. Gonder, J.C. Keeling, M.E. Kohn, D.F. (1997) :** The 1996 guide for the care and use of laboratory animals, *ILAR J.* 38 :41–48.