

Original Article	Radiological Assessment of Egyptian Mandible Morphometric Parameters Using Cone Beam Computed Tomography (CBCT) <i>Eyad M.T. Ali^{1,2}, Wael M. Aboelmaaty³, Shima M. Motawei⁴, and Yasser M. Elbastawisy¹</i> <i>Department of Anatomy, Faculty of Medicine, ¹Mansoura University, Egypt, ²Taibah University, Madinah, KSA, ³Department of Oral and Maxillofacial Radiology, Faculty of Dentistry, Mansoura University, ⁴Department of Forensic Medicine and Clinical Toxicology, Faculty of Medicine, Mansoura University, Egypt.</i>
-------------------------	---

ABSTRACT

Introduction: Accurate appraisal of bone dimensions and morphology is essential for preoperative planning. The present study was conducted to estimate the different morphometric parameters and to determine the mandibular canal and mental foramen location using CBCT.

Material and Methods: CBCT imaging of 48 Egyptians was performed. The mandibles were investigated around the 1st molar, for total height (TH), upper distance (UD), lower distance (LD), total thickness (TT), buccal cortical bone thickness (BCB), lingual cortical bone thickness (LCB) and cancellous bone thickness (CAB), diameter of the mandibular canal (DOM) and gonial angle (GA). Variations in mandible shape and mental foramen sites were also assessed.

Results: A significant difference between the mean TH in both groups was detected, while the mean UD and LD showed insignificant differences. The mean values of TT and CAB were greater in males however the mean BCB and LCB were greater in females. DOM was greater in males but statistically insignificant. Statistically insignificant differences between the mean GA in females (greater) and males were observed. The TH, LD, TT and CAB, DOM showed positive correlations to the age in both groups however the UD, BCB, LCB and GA showed negative correlations. The commonest position of the mental foramen was opposite the apex of the fifth tooth (54.2%). The shape of the mandible were categorized into type A (83.3%), B (0%), C (10.4%) and straight (6.3%).

Conclusion: Mandibular measurements and morphology are unique and their assessment by CBCT becomes crucial before any dental implant.

Received: 25 March 2019, **Accepted:** 22 October 2019

Key Words: Cancellous bone, CBCT, cortical bone, gonial angle, mandible.

Corresponding Author: Eyad M.T. Ali, Ph.D., Department of Anatomy, Faculty of Medicine, Mansoura University, Egypt. **Tel.:** +966543468733, **E-mail:** dreyadmoh@yahoo.com

The Egyptian Journal of Anatomy, ISSN: 0013-2446, Vol. 43 No. 1

INTRODUCTION

Accurate appraisal of bone dimensions and morphology is essential for preoperative planning and effective placement of mandibular implants. The position of different bony channels for the neurovascular bundles like mandibular foramen and canal, lingual, buccal and mental foramina together with the bone height and width, determine the size of the designated implant and its insertion angle. Morphological variations of the mandible are assumed to be influenced by the occlusion and the age of the individual^[1].

Moreover, these measurements may be unique for the individual and vary significantly

between males and females, making them a useful tool in forensic personal identification and sex determination^[2].

Dental implantology becomes a fundamental part of routine dental techniques as it has made great progress and achieves higher success rate. However, one of its common complications is temporary or permanent nerve damage to the inferior alveolar nerve (IAN) that leads to neurological impairment ranging from paresthesia, dysesthesia and anesthesia of the lower jaw. Therefore, a better understanding of the anatomical features of the mandible prior to implantation surgery is strongly acclaimed to avoid these complications^[3].

DOI: 10.21608/EJANA.2019.7192.1005

The bone-implant fixture stability depends on the bone quantity for long-term maintenance. The cancellous and cortical bone thickness is a mandatory factor for a successful implantation. Additionally, the initial stabilization is largely affected by the cortical bone thickness rather than the length of the implant fixture^[4].

The gonial angle, as one of the morphological variations, correlates with the function and shape of the masticatory muscles. There is a controversy about the effect of the individual age and sex on the size of the gonial angle. Although widening of the gonial angle with the increasing age is reported, many articles have reported different results^[5].

The introduction of novel technologies in the dental radiology field have made a great progress in precise evaluation of the dental anatomy and conducting accurate preoperative planning and presents a new effective tool for utilization of the mandible as an aid for personal identification^[6].

Although panoramic radiography is widely used for preoperative diagnosis, it gives inaccurate information because of image distortion and magnifications errors. Therefore, surgeons support the usage of computed tomography (CT) prior to any surgical procedures because of the advantages of clarity of reviewing the anatomy of the surgical region and precise bone shape and measurements. Currently, multislice CT (MSCT) and cone-beam computed tomography (CBCT) are considered as the commonest diagnostic approaches for pre-implant planning^[7].

However, the CBCT images quality is superior to MSCT in appraising cortical and cancellous bone in addition to other tooth related structures. Lately, the course and location of the mental foramen and the mandibular canal have been evaluated using helical CT and CBCT images^[8].

When compared with Conventional CT scans, CBCT has less acquisition time, lower irradiation doses, less artifacts and very worthy three-dimensional resolution in all planes^[6]. High-quality 3-D diagnostic images of the maxillofacial region obtained from CBCT can be studied by using variable representations (multi-planar reformation, 3-D surface rendering) without alteration of the anatomic structures^[9].

Yet, there is no available specific data for these measurements in the mandible of Egyptians, nor previously systematic researches in the literatures have been conducted. Consequently, the objective of this study is to estimate precisely the different morphometric measures and to determine the location of the mandibular canal and mental foramen in the mandible of Egyptians using CBCT imaging.

MATERIAL AND METHODS

Patient selection:

After approval of the study by the Mansoura Faculty of Medicine Institutional Research Board (MFM-IRB), the CBCT images of the mandible of 48 Egyptian patients (19 males and 29 females) of the age range (13-54 years) were examined. The mean age for males was 31.79 ± 11.11 years & for females was 31.79 ± 11.27 years.

Subjects were carefully selected during the period from January 2018 till June 2018. Patients with a history of conditions that alter the morphology of the mandible such as tumors, cysts, trauma, fracture, surgery, inferior alveolar nerve relocation, craniofacial microsomia or hereditary facial asymmetry were omitted from the study. Clinical examination was performed to exclude mandible abnormality or facial asymmetry in all subjects included in the study.

Image acquisition and patient privacy

After obtaining Patients' consents, careful history taking and medical examination were done, and then imaging by CBCT was performed for the selected subjects by the same radiologist to avoid any technical error. One volume of CBCT was done. Moreover, labelling of the CBCT images of each individual were done to keep the patient's confidentiality.

The device used in this study was i-Cat Next Generation Cone-Beam Computed Tomography machine (Imaging Sciences International, ISI, Hatfield, PA, USA). The manufacturer's guidelines were followed and the machine was set at 120 kVp, 5 mAs, scan time 8.9 s, resolution 0.3 mm and the field of view (FOV) varied, depending on whether a single arch or both arches were intended to be scanned. CBCT images were anonymized to keep the patients' confidentiality.

All CBCT images were taken using the lowest-effective dose of radiation.

Evaluation of the images and measurements procedure:

The CBCT raw dicom (Digital Imaging and Communications in Medicine) files were imported and evaluated with a specific imaging analysis software (On demand 3D App version 10.7, Cybermed, Korea) in a Dell Precision Tower 5810 workstation (Dell, Round Rock, TX, USA), with a 32-inch Samsung LED screen with a resolution of 1920 • 1080 pixels in a darkroom. The images brightness and contrast were adjusted using the software image processing tool in order to ensure ideal visualization. All the radiographic findings of the images were simultaneously interpreted by the investigators separately and their findings were compared.

The mandibles were investigated radiographically by CBCT (around the first molar), for the following measurements:

1. Vertical measurements that include the Total Height of the body of the mandible from the inferior border to the alveolar crest (TH), Upper Distance (UD): the distance between the top of the mandibular canal and the top of the alveolar crest and the Lower Distance (LD): the distance between the bottom of the mandibular canal and the base of the mandible (Figure 1, 2).

2. Horizontal measurements: Total Thickness of the mandible from the buccal to the lingual

cortex (TT), Thickness of the buccal cortical bone (BCB), thickness of the lingual cortical bone (LCB) and thickness of the cancellous bone (CAB) (Figures 1,2).

3. Diameter of the mandibular canal (cancellous bone wall of the mandibular canal Included) (DOM) (Figure 3).

4. Measurement of the gonial angle (GA) (Figure 3).

5. Variations in the shape of the mandible.

6. Variations in the site of the mental foramen.

All measurements were made in millimeters (mm) using the above mentioned software. The measurements of the cancellous and cortical bone thicknesses from the alveolar crest were excluded because of atrophic changes or tooth extraction.

Statistical analysis

Data were collected, tabulated and coded with an Excel database and analyzed by SPSS (IBM SPSS Statistics for Windows, Version 20.0. Armonk, NY: IBM Corp). Quantitative data were presented as mean and standard deviation (SD) and qualitative data were offered as number and percentage. Correlation coefficient was used to detect association between different variables. Student’s t-test was used to detect the statistical differences. A P-value was considered significant if it is less than 0.05.

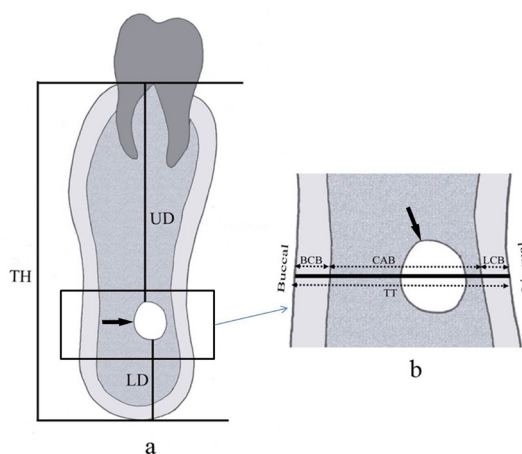


Fig. 1: Schematic diagram of the mandible showing how to measure the vertical (a), the horizontal (b) parameters of the mandible and the diameter of the mandibular canal (arrow). The vertical measurements include total height (TH), upper distance (UD) and lower distance (LD). The horizontal measurements include total thickness (TT), cancellous bone thickness (CAB), buccal cortical bone thickness (BCB) and lingual cortical bone thickness (LCB).

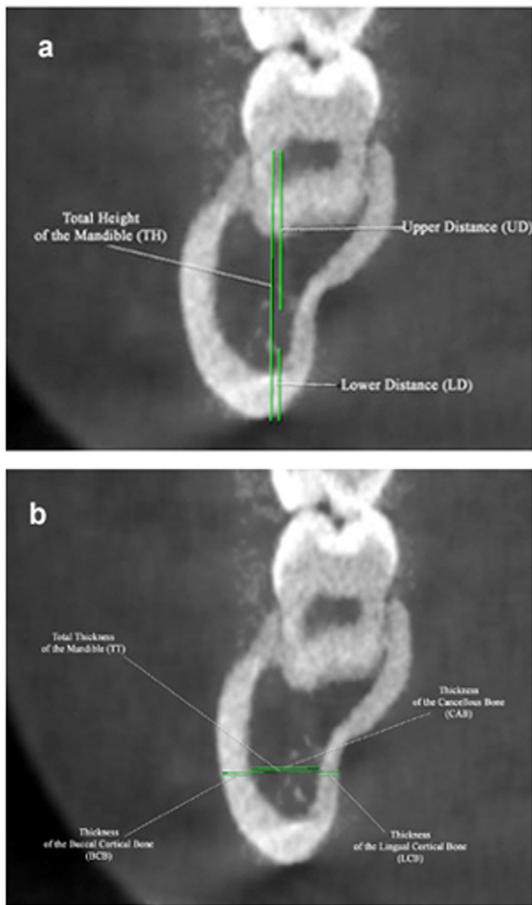


Fig. 2: CBCT image of the mandible (coronal section opposite the first molar) showing both vertical (a) and transverse (b) measurement of the mandible.

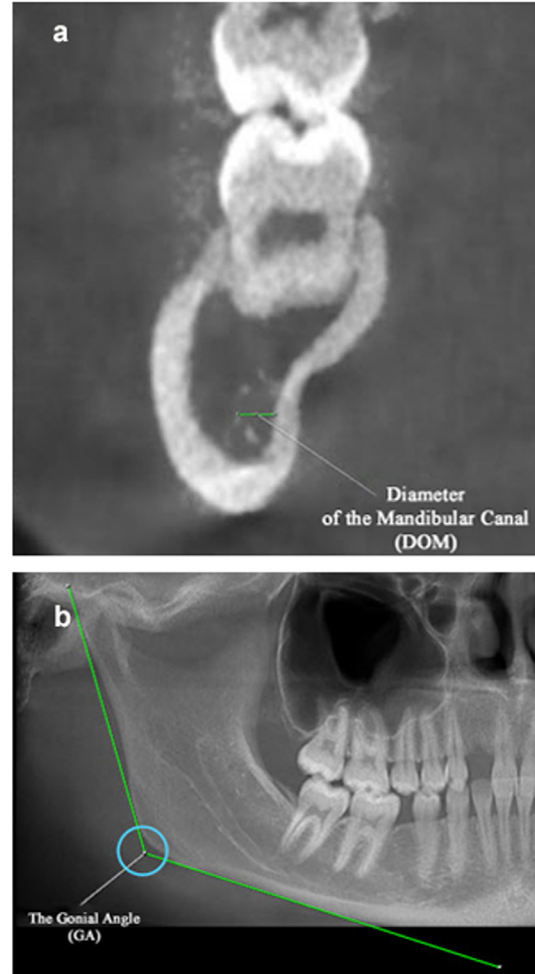


Fig. 3: CBCT images of the mandible showing the way to measure both the diameter of the mandibular canal DOM (a) and the gonial angle GA (b).

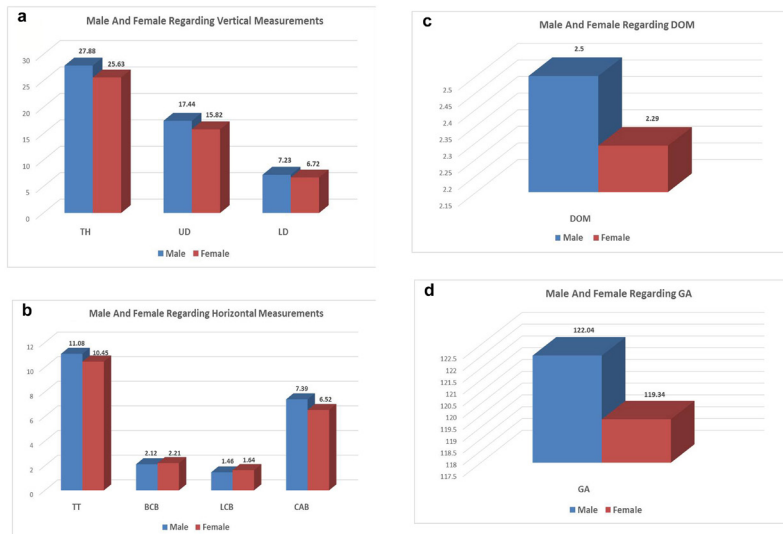


Fig. 4: A histogram illustrating the comparison between the vertical measurements values (a) and the horizontal measurements (b) in both male and female groups. Histogram (c) shows the relationship between the values of the DOM in both males and females and (d) demonstrates the comparison between the GA values in both groups

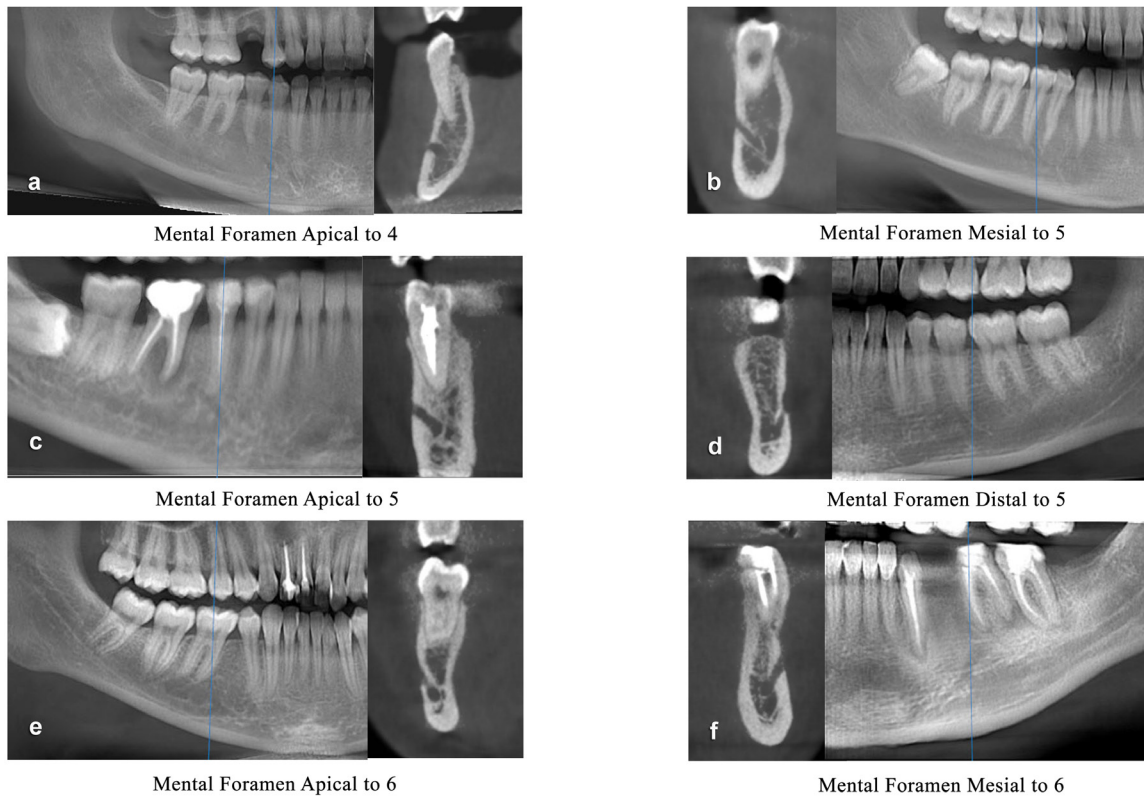


Fig. 5: CBCT images of the mandible showing the variable positions of the mental foramen and its relation to the lower teeth.

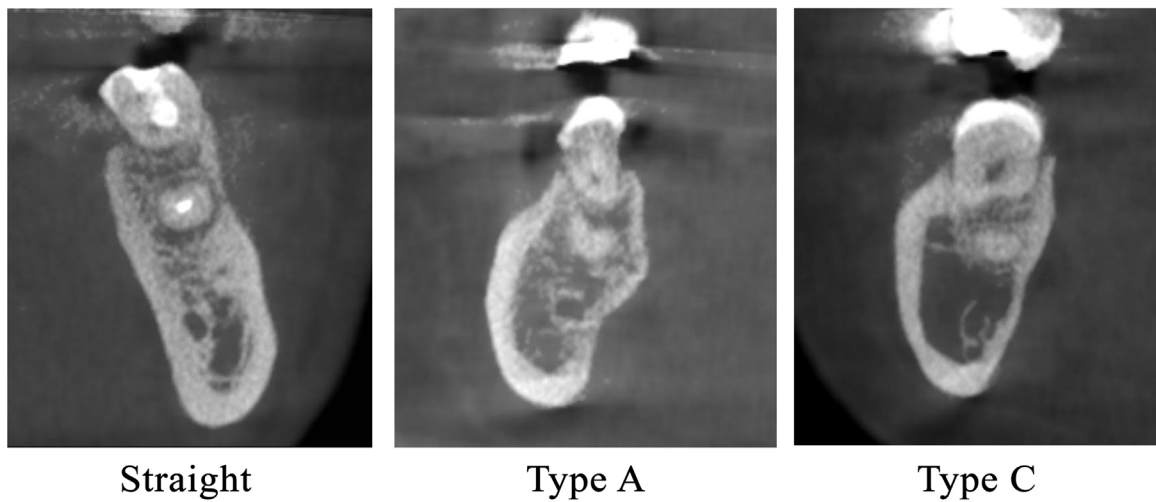


Fig. 6: CBCT image of the mandible showing the different types of the mandible according to its shape in coronal sections. Type A (rounded buccal side and concave lingual side), type C (rounded on both sides) and straight.

RESULTS

Examination of the CBCT scans of the mandible of the 48 Egyptian participants in this study revealed the following measurements:

Vertical measurements

These parameters include the TH, UD and the LD. The TH ranged between 23.65 and 33.70 mm in males while the ranges of values in females groups were 20.91 and 31.22 mm (Table 1). The mean TH was greater in males (27.88 ± 3.35) than in females (25.63 ± 2.58) (Fig. 4).

The UD values extended from 9.95 to 23.05 mm in males while the values in females groups were 9.76 and 21.66 mm. On the other hand, the values of the LD in males ranged between 3.74 and 10.94 mm however in females ranged from 3.62 to 10.15 mm. In male group, the mean UD and LD were determined and found to be 17.44 ± 3.25 and 7.23 ± 2.17 respectively. Meanwhile, the same measurements were estimated to be 15.82 ± 2.53 and 6.72 ± 1.77 respectively in female groups (Table 1) (Fig. 4).

There was a significant difference between the mean TH in males and females groups (P -value > 0.05), while the mean values of the UD and LD showed insignificant differences in both groups (Table 1).

The TH and LD showed positive correlation to the age in both males and female groups however negative correlation was detected regarding the UD (Table 2).

Horizontal (transverse) measurements:

The TT, BCB, LCB, CAB obtained from the analysis CBCT images were considered to be horizontal measurements. As shown in (Table1), the TT ranges from 7.35 to 14.68 mm in males and from 6.95 to 12.79 mm in females.

The mean TT was found to be 11.08 ± 1.96 mm in males and 10.45 ± 1.69 mm in females (greater in males) (Fig. 4).

The BCB values ranged between 1.56 and 2.68 mm in males while the values in females groups

ranged between 1.43 and 2.83 mm. Moreover, the LCB values in males ranged between 0.54 and 2.45 mm however in females 0.63 and 2.60 mm (Table 1).

THE CAB in males fluctuated between 3.67 and 10.50 mm and in females between 3.59 and 9.72 mm (Table 1).

In male group, the mean BCB and LCB were valued and found to be 2.12 ± 0.29 and 1.46 ± 0.43 mm respectively. Meanwhile, the same measurements were estimated to be 2.21 ± 0.37 and 1.64 ± 0.51 mm respectively in female groups. Moreover, the mean CAB were valued and found to be 7.40 ± 1.78 mm and 6.52 ± 1.55 in male and female, respectively (Table 1).

The mean values of the TT and CAB were greater in males than in females however the mean values of the BCB and LCB were greater in females (Fig. 4) and the differences between both groups were insignificant (Table 1).

Positive correlation between the values of TT and CAB to the age in both male and female groups (CAB correlation is significant in females) however negative correlation was detected regarding the BCB and LCB (Table 2).

The DOM

The mean values of the DOM were 2.50 ± 0.46 and 2.29 ± 0.33 in both males (Ranged from 1.77 to 4.05 mm) and females (ranged from 1.77 to 2.97 mm) respectively (Table 1). Greater values of DOM were noticed in males that were statistically insignificant when compared with that of females (Fig. 4). A positive correlation was identified between it and the age in all groups (Table 2).

The gonial angle measurements

The mean GA was estimated and found to be $119.34 \pm 7.82^\circ$ in males and $122.04 \pm 8.20^\circ$ in female group (Table 1). The mean values of the GA were greater in females (Fig. 4) and the differences between both groups were statistically insignificant. The mean values of both GA showed negative correlation to the age in males and females groups (Table 2).

The positions (site) of the mental foramen

As presented in (Table 3), the positions of the mental foramen in relation to the lower teeth were considered. The commonest position was opposite the apex of the fifth (54.2%), then mesial to the fifth (20.8%), mesial to the sixth (12.5%), distal to the fifth (6.3%). Apex of the fourth (4.2%) and the least common opposite the apex of the sixth (2.1%) (Fig. 5).

Shape of the mandible

Was classified into four categories (Fig.6); about 83.3% of cases were categorized as type A (rounded buccal side and concave lingual side). However, type B (concave buccal side and rounded lingual side) were not represented. Moreover, type C (rounded both sides) and straight were represented in about 10.4% and 6.3% respectively (Table 4).

Table 1: Comparison between male and female regarding different parameters

	Female (n=29)				Male (n=19)				<i>p-value</i>
	Mean	S. D	Min.	Max.	Mean	S. D	Min.	Max.	
Age	31.79	11.27	16.00	54.00	31.79	11.11	13.00	53.00	0.9
TH	25.63	2.58	20.91	31.22	27.88	3.35	23.65	33.70	0.01*
UD	15.82	2.53	9.76	21.66	17.44	3.25	9.95	23.05	0.06
LD	6.72	1.77	3.62	10.15	7.23	2.17	3.74	10.94	0.4
TT	10.45	1.69	6.95	12.79	11.08	1.96	7.35	14.68	0.2
BCB	2.21	0.37	1.43	2.83	2.12	0.29	1.56	2.68	0.4
LCB	1.64	0.51	0.63	2.60	1.46	0.43	0.54	2.45	0.2
CAB	6.52	1.55	3.59	9.72	7.40	1.78	3.67	10.50	0.08
DOM	2.29	0.33	1.77	2.97	2.50	0.46	1.77	4.05	0.1
GA	122.04	8.20	105.10	137.60	119.34	7.82	104.90	135.30	0.3

Table 2: Correlation between age and different parameters:

	All group		Male		Female	
	<i>r</i>	<i>p-value</i>	<i>r</i>	<i>p-value</i>	<i>r</i>	<i>p-value</i>
TH	0.040	0.786	0.079	0.747	0.014	0.941
UD	-0.045	0.760	0.138	0.573	-0.198	0.302
LD	0.184	0.210	0.023	0.926	0.314	0.097
TT	0.203	0.166	0.005	0.983	0.355	0.058
BCB	-0.154	0.295	-0.063	0.799	-0.203	0.290
LCB	-0.042	0.775	-0.120	0.625	-0.002	0.993
CAB	0.266	0.067	0.047	0.847	0.443	0.016*
DOM	0.037	0.801	0.067	0.785	0.015	0.938
GA	-0.164	0.264	-0.139	0.572	-0.184	0.340

Table 3: Study group regarding Site of mental Foramen

	No.	%
Apex 4	2	4.2
Apex 5	26	54.2
Apex 6	1	2.1
Distal 5	3	6.3
Mesial 5	10	20.8
Mesial 6	6	12.5
Total	48	100.0

Table 4: Study group regarding the shape of the mandible

Type	No.	%
A	40	83.3%
B	0	0%
C	5	10.4%
STRAIGHT	3	6.3%
TOTAL	48	100%

DISCUSSION

The anatomical landmarks of the oral and maxillofacial regions are individualistic and awareness of their sites is crucial during implementation of local anesthesia and maxillofacial surgeries to avoid complications^[10].

Recently, CBCT is routinely used for orthodontic and implant cases evaluations. This technology provides precise bony landmarks identification and reliable morphological measurements without overlapping of craniofacial structures during image analysis^[11]. Furthermore, it affords 3D images, lower exposure dose of radiation, fast scanning time, together with low price are reported to be the main advantages of CBCT^[12].

The aim of the present study was to assess the anatomical variations of the different morphometric measurements of the mandible and its correlation with age and sex amongst Egyptians using CBCT scans.

Vertical measurements

In the present study, vertical parameters (TH, UD and the LD) were measured. The TH ranged between 23.65 and 33.70 mm in males while

the ranges in females groups were 20.91 and 31.22 mm. The mean TH was greater in males (27.88 ± 3.35) than in females (25.63 ± 2.58). These results were larger than those obtained by Güler *et al.*^[13] and Drikes *et al.*^[14] (23.7 mm in males and 19.3 mm in females) and Lautner *et al.*^[15] (18.3 mm), who investigated the height at first molar via orthopantomograms. Moreover, Orthopantomograms provide data on height, but not on thickness. Therefore, other imaging techniques, such as CT or magnetic resonance imaging, are required.

The UD values extended from 9.95 to 23.05 mm in males while the values in females were 9.76 and 21.66 mm. On the other hand, the values of the LD in males ranged between 3.74 and 10.94 mm however in females from 3.62 to 10.15 mm.

In male group, the mean UD was determined and found to be 17.44 ± 3.25 mm. Meanwhile, the same measurements were estimated to be 15.82 ± 2.53 mm in females, and this goes in agreement with Levine *et al.*^[16].

However, (Güler *et al.*^[13]; Chan *et al.*^[17]; Massey *et al.*^[18]; Lautner *et al.*^[15]) reported less values. Massey *et al.*^[18] in their study estimated the superior distance (11.83 ± 4.42 mm) inferior distance (6.16 ± 1.82 mm) by analyzing micro-CT images of cadaveric mandibles.

Moreover, Lautner *et al.*^[15] found the UD to be 6.936 ± 3.1915 mm by using CT analysis and orthopantomograms of dry mandibles.

According to our results, the mean LD values were found to be 7.23 ± 2.17 mm and 6.72 ± 1.77 mm in male and female groups respectively. Our findings go in agreement with Drikes *et al.*^[14] and higher than those reported by Lautner *et al.*^[15] (6.12 ± 1.07 mm).

Additionally, according to the present work, there was a significant difference between the mean TH in males and females groups (*P*-value 0.01), while the mean values of the UD and LD showed insignificant differences in both groups. The TH and LD showed positive correlation to the age in both males and female groups however negative correlation was detected regarding the UD.

To the best of authors' knowledge, there are no published studies addressing the differences between the vertical measurements in both males and females and their correlations to age of the individual.

The accuracy of measurements by using CT can be modified by 3D reconstruction. Yu and Wang^[19] assume that dry human bone (especially skulls) may present with shrinkage or breakage of fine structure. Perez *et al.*^[20] Described inaccuracy when measuring the distance from the alveolar crest to the mandibular canal with any type of imaging, because of poor definition of canal borders. We and Lautner *et al.*^[15], disagree with this, because we found that cross sectional views give detailed information on the borders of the mandibular canal.

Horizontal (transverse) measurements

The TT, BCB, LCB, CAB obtained from the analysis CBCT images were considered to be horizontal measurements.

The TT ranges from 7.35 to 14.68 mm and from 6.95 to 12.79 mm in males and females respectively. The mean TT was found to be 11.08 ± 1.96 mm in males and 10.45 ± 1.69 mm in females (insignificant difference between two groups; P -value = 0.2). These results agree with the values obtained by Güler *et al.*^[13]; Drikes *et al.*^[14]; Chan *et al.*^[17] and Pyun *et al.*^[21], yet the differences between the two sexes were significant in the first two studies. However, these outcomes vary greatly from those described by Lautner *et al.*^[15] (13.720 ± 2.2131 mm on the right side and 14.01 ± 2.116 mm on the left).

Additionally, Pyun *et al.*^[21] measured the distances between the center of the canal and the outer borders of both lingual (4.06 ± 1.14 mm) and buccal cortical plates (7.17 ± 1.26 mm).

In the present study, the mean BCB was valued and found to be 2.12 ± 0.29 mm in males and 2.21 ± 0.37 mm in females and this goes in consistent with that reported by Lautner *et al.*^[15].

Furthermore, the mean LCB were valued and found to be 1.46 ± 0.43 mm, in male group. Meanwhile, the same measurements were estimated to be 1.64 ± 0.51 mm in female groups.

Moreover, the mean values of the BCB and LCB were greater in females and the differences between both groups were insignificant. However, Deguchi *et al.*^[22] and Zhao *et al.*^[23] showed no significant difference between both groups, but Ono *et al.*^[24] reported divergent outcomes. Meanwhile, these studies reported that male values were greater than in females.

In the present work, the CAB in males fluctuated between 3.67 and 10.50 mm and in females between 3.59 and 9.72 mm. In addition, the mean CAB values were greater in males (7.40 ± 1.78 mm) than in females (6.52 ± 1.55 mm) and the difference was insignificant. However, Momin *et al.*^[25] in their study reported a significant difference in CAB values between male 8.52 ± 1.71 mm and female 4.52 ± 1.20 mm.

In our results, a significant positive correlation between the values of CAB to the age in both groups was detected which is inconsistent with Momin *et al.*^[25] who detected no correlation between patient age and the variability of the mandible CAB thicknesses.

Furthermore, a significant positive correlation between the values of TT to the age in both males and female groups was noted. However negative correlation was detected regarding the BCB and LCB. And according to our knowledge, there is a lack of data in the literature concerning the correlation between the values of TT, BCB and LCB to the age in both males and female groups.

Both COB and CAB and density must be put into consideration to ensure a good blood supply and achieve effective implant insertion. Several literatures Motoyoshi *et al.*^[26] and Stahl *et al.*^[27] reported that the recommended cortical bone thickness for miniscrew placement is = 1.0mm to get perfect stability also linked this thickness to higher miniscrew success rate. According to Momin *et al.*^[25], Miyamoto *et al.*^[28] and Wilmes *et al.*^[29] the stability of the implant depends on the ratio of COB and CAB mainly COB. Cortical bone is more elastic, stronger and more resistant to distortion, and will bear extra-loads than cancellous bone^[25].

The DOM

According to our results, greater DOM mean values were noted in males (2.50 ± 0.46 mm) in

comparison to that obtained in females (2.29 ± 0.33 mm), yet statistically insignificant. A positive correlation was recognized between it and the age in all groups. However, Chrcanovic *et al.*^[30] in their study noticed a statistically significant difference between the mean values of the DOM at the most superior and the most inferior levels. Also a statistically significant difference was observed when comparing the results in both male and females groups.

The gonial angle measurements

In the present research, the mean GA was estimated and found to be $119.34^\circ \pm 7.82$ in males and $122.04^\circ \pm 8.19$ in females. Higher values in males were observed by Xie and Ainamo^[5] ($120.1^\circ \pm 6.2$ to $121.3^\circ \pm 6.7$), Ohm and Silness^[31] ($122.3^\circ \pm 7.3$ to $126.6^\circ \pm 7.2$), Kharoshah *et al.*^[32] ($122.8 \pm 4.3^\circ$) and Al-hababhab^[33] (122.639° to 124.453°). Whereas, lower values were reported by Shilpa *et al.*^[34] ($114.8^\circ \pm 8.341$ to $122.3^\circ \pm 8.722$).

Female mean GA values of our study were lower to those noted by Xie and Ainamo^[5] ($123.2^\circ \pm 6.6$ to $124.1^\circ \pm 6.3$) and Ohm and Silness^[31] ($123.2^\circ \pm 6.6$ to $127.7^\circ \pm 8.2$), but were higher than those obtained by Kharoshah *et al.*^[32] ($121.8 \pm 3.9^\circ$), Al-hababhab^[33] (121.821° to 127.258°) and Shilpa *et al.*^[34] ($114.7^\circ \pm 5.227$ to $122.65^\circ \pm 5.413$).

In our study we noted that the mean values of the GA were greater in females and the differences between both groups were statistically insignificant.

These outcomes were in agreement with those reported by Xie and Ainamo^[5]; Shilpa *et al.*^[34]; Da Costa De Sousa *et al.*^[35]; Olcay Şakar and Tonguç Sülün^[36] but the differences in their reports were statistically significant.

On contrary, Ohm and Silness^[31]; Al-hababhab^[33]; Shahabi *et al.*^[37]; Zangouei-Booshehri *et al.*^[38] determined the GA by using the digital panoramic radiographs; they found that male participants had higher measures when compared to females. Yet the differences were insignificant. Moreover, Kharoshah *et al.*^[32] found that these differences were statistically significant. These sex variations could be explained by superior masticatory power in

male than female, also, due to ethnic group and different morphometric technique used.

In the present work, the mean values of both GA showed negative correlation to the age in both males and females and this was consistent with the outcomes of studies conducted by Dutra *et al.*^[39], Shilpa *et al.*^[34]. The only clarification presented by these authors was that the status of bone mineral of the individuals has no correlation with the GA. On the other hand, Ohm and Silness^[31]; Al-hababhab^[33] and Da Costa De Sousa *et al.*^[35] noticed significant positive correlations and explained their findings by the senile modifications in the mandibular basal bone morphology, decreased bone density and power of contraction of the muscle of mastication.

The positions (site) of the mental foramen

The mental foramen location is a vital landmark, and must be considered before implant placement and surgery to avoid nerve injuries. Being variable, an accurate localization and evaluation is a mandatory process and the obtained data are used as a guide for surgical procedures. In the present study, the mental foramen positions were evaluated and presented as percentages. The commonest position was opposite the apex of the fifth tooth (54.2%), then mesial to the fifth (20.8%), mesial to the sixth (12.5%), distal to the fifth (6.3%), apex of the fourth (4.2%) and the least common position was opposite to the apex of the sixth (2.1%).

There is significant argument in the literatures concerning the position of the mental foramen in different races. Previous reports determined the mental foramen position by measuring its distance from both the midline and the inferior border^[40,41]. Other authors Mraiwa *et al.*^[42] reported that mental foramen location was midway between the inferior mandibular border and the alveolar crest. However, this result could be affected by the crestal bone loss.

The commonest mental foramen position in our results was apical to the 5th mandibular tooth and this goes in consistent with other researches^[12,43-48].

However, Neiva *et al.*^[40]; Sumit Gupta^[47]; Haghanifar and Rokouei^[49]; Oliveira *et al.*^[50]; Rupesh *et al.*^[51] studied the location in their

populations and found it more frequent between the 4th and the 5th tooth which differs from this study.

From the previous results it is settled that the foramen's positions are variable. Teeth extraction and alveolar bone resorption are the main causes for close proximity of the mental foramen, even adjacent, to the alveolar crest^[52]. This close proximity necessitates the surgical exploration of the mental foramen and even transposition of the nerve to create more space prior to implant placement in order to avoid nerve injury^[53]. However, Hori *et al.*^[54] reported a high rate of sensory dysfunction post operatively.

Shape of the mandible

Selecting the proper implant size and angle of installation depend mainly on the shape of the mandible to prevent buccal and lingual perforation. According to the current investigation, the shape of the mandible was categorized into four types (A, B, C and straight). The percentages of each category were evaluated and estimated to be type A (83.3%), type B (0%), type C (10.4%) and straight type (6.3%).

Variable and controversial conclusions were obtained by other researchers, Quirynen *et al.*^[55] reported that type A was rare (2.4%) and that type C was the most frequently detected (69.5%). Moreover, Watanabe *et al.*^[56] described type B as the commonest (58 – 74%) and type C was the rarest (17–36%).

Type A, the most frequently seen in the present study (83.3%), accompanied with higher threat of LCB perforation. Accordingly, the insertion angle of implants should be directed precisely towards the BCB. However, in type B (0%) it should be directed towards the LCB. Additionally, the perforation hazards in type C is the lowest because of the appropriate lingual and buccal cortical bones.

Thus, the variations in results of our study and that described by other authors are attributed mainly to the racial dissimilarities, gender and different age groups which may predispose to discrepancies in the biochemical structure and biomechanical forces.

Moreover, these discrepancies cause alterations in bony tissue organization and remodeling of the mandible and its related joint which are responsible for the morphological features. In addition, non-uniformity of the sample size, diverse radiographic technologies with distinctive magnifications and variable morphometric procedures are proposed to be an explanation.

CONCLUSIONS

Mandibular measurements and morphology are unique for each individual. Their assessment becomes crucial before any dental implant surgery. Moreover, they help in forensic identification of individuals. Introduction of CBCT and keeping dental files for individuals in the modern dental practice would provide a very great help in forensic practice and court evidences.

Males have larger mandible measurements than females, thus it can be used for sex differentiation. CBCT with low dose techniques proved to be rapid, easy, reliable and reproducible for bone examination. CBCT has lower error rates and gives more accurate measurements and descriptions than other commonly used radiologic methods like plain and panoramic X-rays. Moreover, this type of examination foster cooperation between forensic medicine specialists and radiology professionals to use imaging methods as a non-invasive way for documentation and analysis of forensic findings and re-use of the saved files for identification in both living and dead persons.

CONFLICT OF INTERESTS

There are no conflicts of interest.

REFERENCES

1. Huuonen S, Sipilä K, Haikola B, Tapio M, Söderholm AL, Remes-Lyly T, *et al.* Influence of edentulousness on gonial angle, ramus and condylar height. *Journal of Oral Rehabilitation*. 2010;37(1):34–8.
2. Huang H, Xu Z, Shao X, Wismeijer D, Sun P, Wang J, *et al.* Multivariate linear regression analysis to identify general factors for quantitative predictions of implant

- stability quotient values. PLoS ONE. 2017; 12(10):1-11.
3. Kamburoğlu K, Kiliç C, Özen T, Yüksel SP. Measurements of mandibular canal region obtained by cone-beam computed tomography: a cadaveric study. *Oral Surgery, Oral Medicine, Oral Pathology, Oral Radiology and Endodontology*. 2009;107(2):34-42.
 4. Kim H-J, Yu S-K, Lee M-H, Lee H-J, Kim H-J, Chung C-H. Cortical and cancellous bone thickness on the anterior region of alveolar bone in Korean: a study of dentate human cadavers. *The Journal of Advanced Prosthodontics*. 2012;4(3):146-52.
 5. Xie Q-F, Ainamo A. [Association of mandibular angle size with cortical thickness and residual ridge height of the edentulous mandible]. *Zhonghua kou qiang yi xue za zhi = Zhonghua kouqiang yixue zazhi = Chinese journal of stomatology*. 2004;39(5):390-4.
 6. Motawei SM, Wahba BA, Aboelmaaty WM, Tolba EM. "Assessment of frontal sinus dimensions using CBCT to determine sexual dimorphism amongst Egyptian population." *Journal of Forensic Radiology and Imaging*. 2016;6:8-13.
 7. Chen L-C, Lundgren T, Hallstrom H, Chere F. Comparison of different methods of assessing alveolar ridge dimensions prior to dental implant placement. *Journal of periodontology*. 2008;79(3):401-5.
 8. Dreiseidler T, Mischkowski R a, Neugebauer J, Ritter L, Zöller JE. Comparison of cone-beam imaging with orthopantomography and computerized tomography for assessment in presurgical implant dentistry. *The International journal of oral & maxillofacial implants*. 2009;24(2):216-25.
 9. Baratto Filho F, Zaitter S, Haragushiku GA, de Campos EA, Abuabara A, Correr GM. Analysis of the Internal Anatomy of Maxillary First Molars by Using Different Methods. *Journal of Endodontics*. 2009;35(3):337-42.
 10. Chrcanovic BR, Freire-Maia B. Risk factors and prevention of bad splits during sagittal split osteotomy. *Oral and Maxillofacial Surgery*. 2012;16(1):19-27.
 11. Kumar V, Satheesh K. Applications of Cone Beam Computed Tomography (CBCT) in Implant Treatment Planning. *JSM Dentistry*. 2013;1(2):1-7.
 12. Sekerci A, Sahman H, Sisman Y, Aksu Y. Morphometric analysis of the mental foramen in a Turkish population based on multi-slice computed tomography. *Journal of Oral and Maxillofacial Radiology*. 2013;1(1):2.
 13. Güler AU, Sumer M, Sumer P, Biçer I. The evaluation of vertical heights of maxillary and mandibular bones and the location of anatomic landmarks in panoramic radiographs of edentulous patients for implant dentistry. *Journal of Oral Rehabilitation*. 2005;32(10):741-6.
 14. Drikes S, Delcampe P, Sabin P, Lavis JF, Cordier G, Vacher C, *et al.* CT scan study of the mandibular nerve intra-mandibular path. *Revue de Stomatologie et de Chirurgie Maxillo-Faciale*. 2011;112(3): 5-10.
 15. Lautner N, McCoy M, Gaggl A, Krenkel C. Intramandibular course of the mandibular nerve; clinical significance for distraction and implantology. *Revue de Stomatologie et de Chirurgie Maxillo-faciale*. 2012; 113(3):161-8.
 16. Levine MH, Goddard AL, Dodson TB. Inferior alveolar nerve canal position: a clinical and radiographic study. *Journal of oral and maxillofacial surgery : official journal of the American Association of Oral and Maxillofacial Surgeons*. 2007;65(3):470-4.
 17. Chan H-L, Brooks SL, Fu J-H, Yeh C-Y, Rudek I, Wang H-L. Cross-sectional analysis of the mandibular lingual concavity using cone beam computed tomography. *Clinical Oral Implants Research*. 2011;22(2):201-6.
 18. Massey ND, Galil KA, Wilson TD. Determining position of the inferior alveolar nerve via anatomical dissection and micro-computed tomography in preparation for dental implants. *Journal of the Canadian Dental Association*. 2013;79.

19. Yu IH, Wong YK. Evaluation of mandibular anatomy related to sagittal split ramus osteotomy using 3-dimensional computed tomography scan images. *International Journal of Oral and Maxillofacial Surgery*. 2008;37(6):521–8.
20. Perez LA, Brooks SL, Wang HL, Eber RM. Comparison of linear tomography and direct ridge mapping for the determination of edentulous ridge dimensions in human cadavers. *Oral Surgery, Oral Medicine, Oral Pathology, Oral Radiology and Endodontology*. 2005;99(6):748–54.
21. Pyun JH, Lim YJ, Kim MJ, Ahn SJ, Kim J. Position of the mental foramen on panoramic radiographs and its relation to the horizontal course of the mandibular canal: A computed tomographic analysis. *Clinical Oral Implants Research*. 2013;24(8):890–5.
22. Deguchi T, Nasu M, Murakami K, Yabuuchi T, Kamioka H, Takano-Yamamoto T. Quantitative evaluation of cortical bone thickness with computed tomographic scanning for orthodontic implants. *American Journal of Orthodontics and Dentofacial Orthopedics*. 2006;129(6).
23. Zhao H, Gu XM, Liu HC, Wang ZW, Xun CL. Measurement of cortical bone thickness in adults by cone-beam computerized tomography for orthodontic miniscrews placement. *Journal of Huazhong University of Science and Technology - Medical Science*. 2013;33(2):303–8.
24. Ono A, Motoyoshi M, Shimizu N. Cortical bone thickness in the buccal posterior region for orthodontic mini-implants. *International Journal of Oral and Maxillofacial Surgery*. 2008;37(4):334–40.
25. Momin MA, Kurabayashi T, Yosue T. Quantitative and Morphological Evaluation of Cancellous and Cortical Bone of the Mandible by CT. *OMICS Journal of Radiology*. 2014;3(1):1–5.
26. Motoyoshi M, Inaba M, Ono A, Ueno S, Shimizu N. The effect of cortical bone thickness on the stability of orthodontic mini-implants and on the stress distribution in surrounding bone. *International Journal of Oral and Maxillofacial Surgery*. 2009;38(1):13–8.
27. Stahl E, Keilig L, Abdelgader I, Jager A, Bourauel C. Numerical analyses of biomechanical behavior of various orthodontic anchorage implants. *J Orofac Orthop*. 2009;70(2):115–27.
28. Miyamoto I, Tsuboi Y, Wada E, Suwa H, Iizuka T. Influence of cortical bone thickness and implant length on implant stability at the time of surgery - Clinical, prospective, biomechanical, and imaging study. *Bone*. 2005;37(6):776–80.
29. Wilmes B, Rademacher C, Olthoff G, Drescher D. Parameters affecting primary stability of orthodontic mini-implants. *J Orofac Orthop*. 2006;67(3):162–74.
30. Chrcanovic BR, de Carvalho Machado V, Gjelvold B. A morphometric analysis of the mandibular canal by cone beam computed tomography and its relevance to the sagittal split ramus osteotomy. *Oral and Maxillofacial Surgery*. 2016;20(2):183–90.
31. Ohm E, Silness J. Size of the mandibular jaw angle related to age, tooth retention and gender. *Journal of oral rehabilitation*. 1999;26(11):883–91.
32. Kharoshah MAA, Almadani O, Ghaleb SS, Zaki MK, Fattah YAA. Sexual dimorphism of the mandible in a modern Egyptian population. *Journal of Forensic and Legal Medicine*. 2010;17(4):213–5.
33. Al-hababba A. Age and Gender Differences in Gonial Angle, Ramus Height and Bigonial Width in Dentate Subjects. *Pakistan Oral & Dental Journal*. 2012;32(1):81–7.
34. Shilpa B, Sk S, Rk S, Sudha C. Original Research Article Combined Effect of Age and Sex on the Gonial Angle of Mandible in North- Indian Population. 2014;4(2):14–20.
35. Da Costa De Sousa J, Machado FA, Porto Silva PA, Cardinot TM, Babinski MA. Correlation of the gonial angle with condylar measurements on dry mandible:

- A morphometric study for clinical-surgical and physiotherapeutic practices. *European Journal of Anatomy*. 2006;10(3):91–6.
36. Olcay Şakar, Tonguç Sülün Eİ. Correlation of the Gonial Angle Size with Residual Ridge Resorption in Edentulous Subjects. *Journal, Balkan OF Stomatology*,. 2008;12:38–41.
 37. Shahabi M, Ramazanzadeh B-A, Mokhber N. Comparison between the external gonial angle in panoramic radiographs and lateral cephalograms of adult patients with Class I malocclusion. *Journal of oral science*. 2009;51(3):425–9.
 38. Zangouei-Booshehri M, Aghili HA, Abasi M, Ezoddini-Ardakani F. Agreement between panoramic and lateral cephalometric radiographs for measuring the gonial angle. *Iranian Journal of Radiology*. 2012;9(4):178–182.
 39. Dutra V, Devlin H, Susin C, Yang J, Horner K, Fernandes AR. No Title. *Oral Surgery, Oral Medicine, Oral Pathology, Oral Radiology and Endodontology*. 2006;102:663–668.
 40. Neiva RF, Gapski R, Wang H-L. Morphometric analysis of implant-related anatomy in Caucasian skulls. *J Periodontol*. 2004;75:1061–7.
 41. Agthong S, Huanmanop T, Chentanez V. Anatomical variations of the supraorbital, infraorbital, and mental foramina related to gender and side. *Journal of Oral and Maxillofacial Surgery*. 2005;63(6):800–4.
 42. Mraiwa N, Jacobs R, van Steenberghe D, Quirynen M. Clinical assessment and surgical implications of anatomic challenges in the anterior mandible. *Clinical implant dentistry and related research*. 2003;5:219–25.
 43. Ngeow WC, Yuzawati Y. The location of the mental foramen in a selected Malay population. *Journal of oral science*. 2003;45(3):171–5.
 44. AMORIM, MM, PRADO, FB, BORINI, CB, BITTAR, TO, VOLPATO, MC, GROppo, FC, CARIA P. The Mental Foramen Position in Dentate and Edentulous Brazilian's Mandible. *International Journal of Morphology*. 2008;26(4):981-7.
 45. Ilayperuma I, Nanayakkara G, Palahepitiya N. Morphometric Analysis of the Mental Foramen in Adult Sri Lankan Mandibles. *International Journal of Morphology*. 2009;27(4):1019–24.
 46. Agarwal DR, Gupta SB. Morphometric analysis of mental foramen in human mandibles of South Gujarat. *People's J Sci Res*. 2011;4(1):15–8.
 47. Sumit Gupta JSS. ORIGINAL ARTICLE STUDY OF ANATOMICAL VARIATIONS AND INCIDENCE OF MENTAL FORAMEN AND ACCESSORY MENTAL FORAMEN IN DRY HUMAN MANDIBLES Correspondence : NATIONAL JOURNAL OF MEDICAL RESEARCH. 2012;2(1):28–30.
 48. Budhiraja V, Rastogi R, Lalwani R, Goel P, Bose SC. Study of position, shape, and size of mental foramen utilizing various parameters in dry adult human mandibles from north India. *ISRN Anat*. 2013;2013:961429.
 49. Haghanifar S, Rokouei M. Radiographic evaluation of the mental foramen in a selected Iranian population. *Indian Journal of Dental Research*. 2009;20(2):150.
 50. Oliveira , J., Araujo A, C DS, R S, F L. Morphological and Morphometric Study of the Mental Foramen on the M-CP.18 Jianchenjiang Point. *Int J Morpho*. 2009;27(1):231–238.
 51. Rupesh, S., Winnier, J., Sherin, A., Tatu, J., Prasad, A., venugopal R. Radiographic Study of the Location of Mental Foramen in a Randomly Selected Asian Indian Population On Digital Panoramic Radiographs. *J Med Sci*. 2011;11(2):90–95.
 52. Block MS. *Color Atlas of Dental Implant Surgery*. 3th ed. Missouri : Saunders Elsevier;2010.
 53. Morrison A, Chiarot M, Kirby S. Mental nerve function after inferior alveolar nerve transposition for placement of

- dental implants. *Journal (Canadian Dental Association)*. 2002;68(1):46–50.
54. Hori M, Sato T, Kaneko K, Okaue M, Matsumoto M, Sato H, *et al.* Neurosensory function and implant survival rate following implant placement with nerve transpositioning: a case study. *Journal of oral science*. 2001;43(2):139–44.
55. Quirynen M, Mraiwa N, van Steenberghe D JR. Morphology and dimensions of the mandibular jaw bone in the interforaminal region in patients requiring implants in the distal areas. *Clin Oral Implants Res*. 2003;14(3):280–5.
56. Watanabe H, Abdul MM, Kurabayashi T, Aoki H. Mandible size and morphology determined with CT on a premise of dental implant operation. *Surgical and Radiologic Anatomy*. 2010;32(4):343–9.

التقييم الإشعاعي للقياسات المورفومترية للفك السفلي للمصريين باستخدام الأشعة المقطعية المخروطية

إياد محمد طلبة علي^{٢،١*}، وائل محمد صفوت أبو المعاطي^٣، شيماء محمود مطاوع^٤،
ياسر محمد البسطويسي^{٢،١}

^١ قسم التشريح، كلية الطب، جامعة المنصورة، مصر.

^٢ قسم التشريح، كلية الطب، جامعة طيبة، المدينة المنورة، المملكة العربية السعودية.

^٣ قسم أشعة الفم والوجه والفكين، كلية طب الأسنان، جامعة المنصورة، مصر.

^٤ قسم الطب الشرعي وعلم السموم الإكلينيكي، كلية الطب، جامعة المنصورة، مصر.

ملخص البحث

المقدمة: إن التقييم الدقيق لأبعاد العظام وتشكلها ضروري للتخطيط قبل الجراحة، وقد أجريت هذه الدراسة لتقدير المعايير المورفومترية المختلفة للفك السفلي بالإضافة إلى تحديد موقع كلا من قناة الفك السفلي و الثقب الذقني باستخدام الأشعة المقطعية المخروطية.

مواد وطرق البحث: تم إجراء فحص بالأشعة المقطعية المخروطية للفك السفلي حول الضرس (الطاحن) الأول لثمانية وأربعين مصرياً (تسعة عشر ذكراً و تسع وعشرين أنثى)، ولقد تمت دراسات القياسات المورفومترية التالية: الارتفاع الكلي، المسافة العليا، المسافة السفلى، السماكة الكلية، سمك عظم القشرة الشدقية، سمك العظام القشرية اللغوية، سمك العظم الإسفنجي بالإضافة إلى قطر قناة الفك السفلي وزاوية الفك السفلي كما تم تقييم الاختلافات في شكل الفك السفلي ومواقع الثقب الذقني.

النتائج: تم الكشف عن اختلاف ملحوظ إحصائياً بين متوسط الارتفاع الكلي في كلا المجموعتين، في حين أظهر متوسط المسافة العليا، المسافة السفلى اختلافات ضئيلة. كانت القيم المتوسطة للسماكة الكلية و سمك العظم الإسفنجي أكبر عند الذكور ولكن متوسط سمك عظام القشرة الشدقية و القشرية اللغوية أكبر عند الإناث. كان قطر قناة الفك السفلي أكبر عند الذكور ولكن الفرق ليس ذو دلالة إحصائية. وقد لوحظت فروق ذات دلالة إحصائية بين متوسط زاوية الفك السفلي في الإناث (أكبر) والذكور. ولقد أظهر متوسط كلا من الارتفاع الكلي، المسافة السفلى، السماكة الكلية و سمك العظم الإسفنجي بالإضافة إلى قطر قناة الفك السفلي علاقات إيجابية مع العمر في كلتا المجموعتين ولكن أظهرت المسافة السفلى، سمك عظام القشرة الشدقية و القشرية اللغوية و زاوية الفك السفلي علاقات سلبية. ووجد أن الموقع الأكثر شيوعاً للثقب الذقني هو مقابل قمة السن الخامسة (٢، ٥٤٪). تم تصنيف شكل الفك السفلي إلى النوع A (٣، ٨٣٪)، B (صفر)، C (٤، ١٠٪)، وأخيراً النوع المستقيم أو المباشر (٣، ٦٪).

الاستنتاج: إن قياسات ومورفولوجيا الفك السفلي مختلفة ولذلك فإن تقييمها باستخدام الأشعة المقطعية المخروطية

يصبح ضرورة ملحة قبل إجراء أي من عمليات زراعة الأسنان.