

## The Effect of Berberine on Thioacetamide Induced Hepatic Toxicity in Rats

Maha Tharwat Eldeeb<sup>1</sup>, Nahid Mohamed Tphoon<sup>1</sup>, Ahmed Elsayes Abd-ELFattah,<sup>1</sup>Reham Lotfy Younis<sup>1\*</sup>

<sup>1</sup>Medical Physiology Department, Faculty of Medicine, Tanta University, Tanta, Egypt

Submit Date : 13 July 2023  
Accept Date: 29 July 2023

### Keywords

- Thioacetamide
- Hepatotoxicity
- Berberine
- Oxidative stress

### Abstract

**Background:** Most hepatotoxic chemicals primarily harm the liver by lipid peroxidation and oxidative damages. **Aim:** To study the impact of Berberine on thioacetamide-induced hepatic toxicity and its underlying mechanisms. **Methods:** This work was performed on 40 male albino rats. The animals were randomly divided into 4 groups (10 rats each): Control group: was given 0.5 ml saline intraperitoneal injection (IP) twice /week for 8 weeks. Berberine group: was given Berberine (200 mg/kg/day) by oral gavage plus 0.5 ml saline by IP twice /week for 8 weeks. Thioacetamide group: received 200mg/kg thioacetamide I.P. twice /week for 8 weeks. berberine treated group: was given 200mg/kg thioacetamide I.P. twice /week plus Berberine 200 mg/kg/day by oral gavage for 8 weeks. **Results:** Berberine group showed insignificant change in all studied parameters as compared to control group. While thioacetamide group demonstrated significant elevation in serum level of bilirubin, aspartate aminotransferase (AST), alanine aminotransferase (ALT), alkaline phosphatase (ALP), interleukin 6 and hepatic hydroxyproline, with significant decrease in serum level of total antioxidant capacity compared to control and berberine group. However, thioacetamide group treated with Berberine 200 mg showed significant decrease in serum level of AST, ALT, ALP, bilirubin, interleukin 6 and hepatic hydroxyproline, with significant elevation in serum level of total antioxidant capacity as compared to liver toxicity group. **Conclusions:** BBR may be considered a therapeutic agent against hepatic injury, its hepatoprotective mechanism might be mediated via suppression of inflammation, oxidative stress, endogenous antioxidant defense system activation and reduction of DNA damage.

## Introduction

The proto-BBR alkaloid berberine (BBR) and its derivatives show a wide range of pharmacological actions and worth to be mentioned that Chinese traditional medicine had utilized it. BBR has applications in a variety of therapeutic areas, such as inflammation, cancer, hypertension, diabetes mellitus, depression, and many infectious regions, either alone or in combination with other pharmaceutically active substances or in the form of formulations [1].

Thioacetamide (C<sub>2</sub>H<sub>5</sub>NS; TAA), an organosulfur chemical, is utilized in numerous industries, including the paper industry [2]. TAA causes hepatic injury; hence it is regarded as a crucial hepatotoxicity model that mimics the onset and course of human liver disease. DNA, RNA, and protein synthesis are all affected by TAA [3].

As the liver detoxifies both exogenous and endogenous metabolites, it is one of the most essential organs in this context and plays a crucial role in metabolic process, production of bile, and toxin degradation. However, hepatic morbidity and mortality are rising globally each year, which has become an important public health concern [4].

Progressive hepatic fibrosis, one of the defining characteristics of hepatic toxicity, and is a significant factor in the mortality associated with end-stage hepatic disease in individuals with a variety of chronic liver diseases. This underlines the need for a better comprehension of the molecular mechanisms regulating liver fibrogenesis, the development of an alternative diagnostic method, and the identification of new targets for effective anti-fibrotic therapies [5].

The pathogenesis of most liver disorders involves oxidative stress and inflammatory signalling. This

makes the function of antioxidants and anti-inflammatory drugs in the process of protection against several diseases targeting the liver obviously clear [6].

**Materials and Methods:**

**Experimental animals:**

This work was performed on forty adult, local strain, male, healthy albino rats obtained from the Animal House Unit, Faculty of Science, Tanta University, ranging in weight 200±20 g of same age (16-18 weeks). One week prior to the study, the animals were maintained in conventional cages at 25±3°C, 40–50% humidity, a 12-hour light–dark cycle, and unrestricted availability of a standard meal and water for acclimatization and during the experimental period which continued for 8 weeks. All procedures were done in accordance to the ethical committee of Faculty of medicine, Tanta University under code number (34522/2/21).

## Drug preparation

**Berberine:** It was bought as a powder from Sigma-Aldrich (Egypt). Each rat's administered dose was determined based on its weight, was dissolved in Methanol and was given orally (200 mg per kg every day) by gavage orally throughout 8 weeks [7].

**TAA:** It was purchased from Sigma-Aldrich (Egypt) as a powder. The administered amount was calculated for each rat, according to its weight, was dissolved in sterile normal saline solution and 200 mg/kg intraperitoneally administered as an injection twice /week.

## Study design:

The animal had been distributed at random into 4 equal groups (n=10) as follows:

Controls group (10 rats): The rats of this group was given 0.5 ml saline twice weekly by injection intraperitoneally (IP) for 8 weeks.

BBR- sham treated group (10 rats): The rats of this group were given orally BBR (200 mg/kg/day) by gavage plus 0.5 ml saline twice weekly IP for 8 weeks [7].

TAA toxic group (10): The rats of this group received 200mg/kg thioacetamide I.P. twice /week for 8 weeks [8].

BBR treated group (10 rats): The rats of this group were given 200mg/kg thioacetamide I.P. twice /week plus BBR 200 mg/kg/day) by gavage orally for 8 weeks [7].

#### **Blood sampling**

At the end of experimental period (8 weeks), all rats had been scarified by cervical decapitation under general anesthesia by inhaled Isoflurane (induction 2.5%–3%, after that 2%–2.5% maintenance with oxygen) [9] Blood specimens were taken in plastic clean tubes for testing, centrifuging at 3000 rpm for 15 minutes, and then the separated sera went into sterile storage plastic epindorfens and kept at -30oC until use.

#### **Biochemical analysis**

Immunoassay of liver enzymes: Serum aspartate aminotransferase (AST) and serum alanine aminotransferase (ALT) based on the technique stated by Palipoch et al. [10], serum alkaline phosphatase (ALP) based on the technique stated by Adeyemi et al. [11], serum Bilirubin according to the technique stated by Mounieb et al. [12].

Immunoassay of total antioxidant capacity level and Interleukin 6: Serum Assay of total antioxidant capacity level (TAC) by Koracevic et al [13] and serum Interleukin 6 (IL6) by Nordan et al [14].

#### **Tissue sampling:**

Liver tissue samples were dissected carefully in all rats in each group to avoid mechanical trauma and each liver had been weighted and cut transversely into 2 parts, one part was divided into 2 halves. The first half was kept at -30o C for the tissue biochemical assay of Hepatic Hydroxy proline [15]. Liver was homogenized in a suitable buffer. The homogenates had been gathered in plastic clean tubes for testing and then centrifugation was at 3000 r.p.m for 15 min at 4oC and the supernatants were separated in a clean plastic storage epindorfens and kept at -80oc for estimation of hepatic hydroxy proline.

Second half for DNA examination for detection of DNA damage in hepatic tissues by Agarose Gel Electrophoresis by Kasibhatla et al. [16].

#### **Histopathological examination:**

The second part of liver tissue from all rats in each group was preserved in Bouin's fixative for 6 h and subsequently cleaned and kept in 10% phosphate-buffered formalin and embedded in paraffin for histopathological examination [17]. The slaughtered animals were transported with hospital biohazard packages that were specially packaged in accordance with safety and infection control protocols.

#### **Statistical analysis**

SPSS v26 (IBM Inc., Chicago, IL, USA) was used for the statistical analysis. Using the ONE WAY ANOVA (F) test with the post hoc test (Tukey), the quantitative parameters were given as the mean and standard deviation (SD) for the comparison between the information that was accessible. Statistical significance was defined as a two-tailed P value  $\leq 0.05$ .

#### **Results:**

The Effect of Berberine on hepatic enzymes (AST, ALT and ALP):

Regarding ALT, AST and ALP there were as no significant change comparing the control group with the Berberine group. However, there were a significant elevation AST, ALT and ALP when comparing the group of TAA with both the control and Berberine groups. In BBR treated group ALT, AST and ALP were significantly lower compared with the liver toxicity group but still significantly higher compared with both the control and the Berberine groups. (Figure 1)

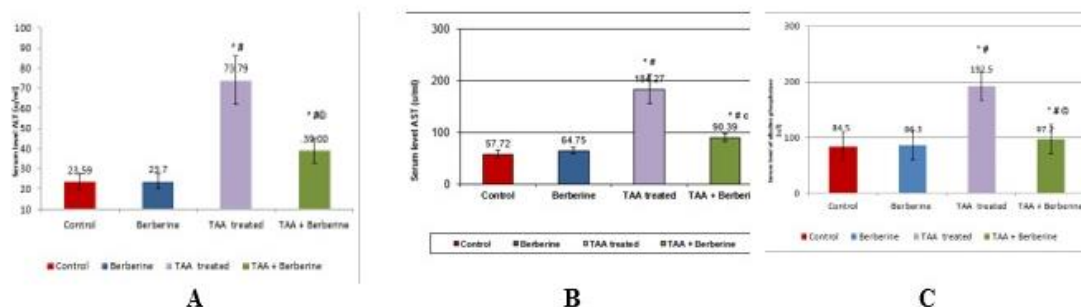
The Effect of Berberine on total bilirubin, TAC and IL-6 level:

There were no significant changes comparing the control group with the Berberine group. However, there were a significant elevation in total bilirubin and IL-6 level when comparing the TAA group with both the control and Berberine groups. In BBR treated group total bilirubin and IL-6 were significantly lower compared with the liver toxicity group but still significantly higher compared with both the Berberine and the control groups.

As regard TAC there was a significant decrease in its level when comparing the TAA group with both the control and Berberine groups. In BBR treated group TAC was significantly elevated compared with the liver toxicity group but still significantly lower compared with both the Berberine and the control groups (Figure 2).

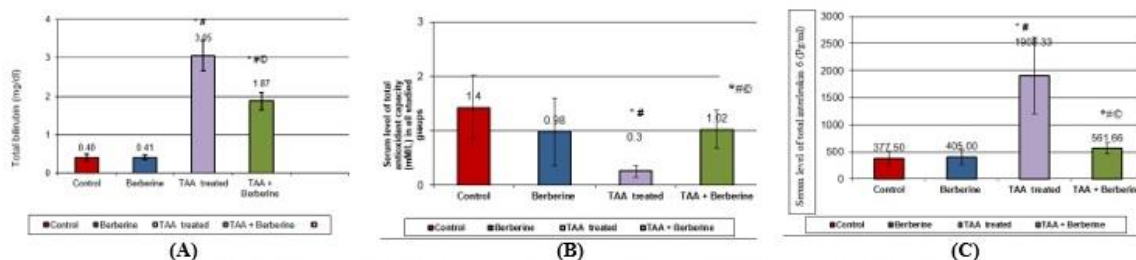
**The Effect of Berberine on Tissue Hydroxyproline:**

There was no significant change in hepatic hydroxyproline level when contrasting the control group with the Berberine group. However, there was a significant increase when comparing the TAA group with both the control and Berberine groups. In BBR treated hepatic hydroxyproline was significantly lower when contrasted with the liver toxicity group but still significantly higher when contrasted with both the control and the Berberine groups. (Table 1).



**Figure 1: Serum level of (A): alanineaminotransferase (ALT) (U/ml), (B): aspartate aminotransferase (AST) (U/ml) and (C): alkaline phosphatase (ALP) (U/L) in all studied groups**

\* significant compared with the group of the controls. # significant compared with the Berberine group. © significant compared with the TAA toxic group. St.D= standard deviation.



**Figure 2: (A): Serum level of total bilirubin (mg/dl), (B): total antioxidant capacity(mM/L) and (C): total Interleukin 6 (pg/ml) in all studied groups.**

\* significant compared with the group of the controls. # significant compared with the Berberine group. © significant compared with the TAA toxic group. St.D= standard deviation

**Table 1: Tissue Hydroxyproline (nmol g<sup>-1</sup>) in all studied groups**

No	Control G1	Berberine G2	TAA treated G3	TAA + Berberine G4	
Mean ± SD	327.5±18.02	255±36.05	1416.7±442.2	769.2±79.4	
F	18.01				
G2 Vs. G1	G3 Vs. G1*	G3 Vs. G2 <sup>#</sup>	G4 Vs. G1*	G4 Vs. G2 <sup>#</sup>	G4 Vs. G3 <sup>©</sup>
>0.05	≤0.05	≤0.05	≤0.05	≤0.05	≤0.05

\* significant compared with the group of the controls, # significant compared with the Berberine group, © significant compared with the TAA toxic group, SD= standard deviation, F= cumulative distribution function

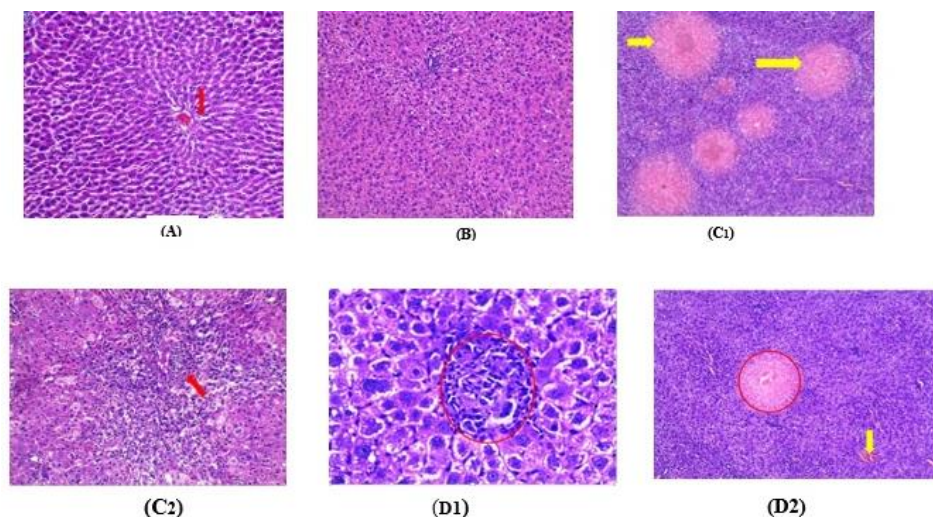
**Histopathological Findings**

Histological examination of control group revealed normal architecture of hepatic tissues in terms of the hepatocytes' inter-anastomosing network organized in single-cell thick plates spaced by vascular sinusoids. The liver is divided into hexagonal lobules, of radiating hepatocyte plates and a central vein.. The traditional lobules are surrounded by portal tracts, no apoptotic figures present. In Berberine group the histopathological examination normal showed normal liver tissue architecture as control group. Specimen from thioacetamide liver toxicity group showed vascular

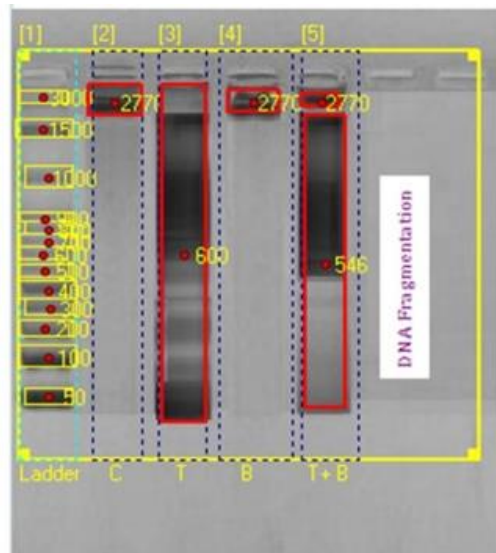
degeneration and focal necrosis with significant number of mononuclear inflammatory cells infiltration that are recruited into the liver following the development of cell injury from thioacetamide exposure with disturbed hepatic lobular architecture. BBR treated group animals' livers showed hepatocytes with minute focal area of inflammatory cellular infiltration. (Figure 3).

**DNA damage**

DNA isolated from liver tissue using agarose gel electrophoresis of control, Berberine, Thioacetamide, Berberine & Thioacetamide groups. Figure 4



**Figure 3:** (A): Normal liver tissue showing normal central vein (red arrow), sinusoids and hepatocytes ,(B): One of Berberine treated group showed sheet of normal hepatocytes withintervening blood vessels of normal caliber, (C1): One of the Thioacetamide toxic group showed multiple areas of coagulative necrosis surrounded by normal hepatocyte (yellow arrows), (C2): One of the Thioacetamide toxic group showed Disturbed hepatic lobular architecture by severe mononuclear inflammatory cell infiltration (red arrows), (D1): One of Thioacetamide and Berberine treated group showed normal hepatocytes with focal mild lymphocytic infiltrate (red circle) and (D2): One of Thioacetamide and Berberine treated group showed large focal area of coagulative necrosis (red circle) admixed with mildly dilated congested central vein( yellow arrow) surrounded by radiating normal hepatocytes and (H&EX100)



**Figure 4:** Fragmentation of DNA

DNA from the control group's hepatic tissues is shown in Lane (2), which exhibits no apoptotic fragmentation of DNA. DNA taken from the hepatic tissues of the Thioacetamide-treated group is represented by Lane (3), which exhibits substantial apoptotic fragmentation of DNA, around at 600 bpm. The DNA in Lane (4), which was taken from the liver tissues of the Berberine-treated group, does not exhibit any apoptotic fragmentation of DNA. Lane (5): represents DNA taken from the liver tissues of the group that received treatment with berberine + thioacetamide and exhibits little apoptotic fragmentation of the DNA.

## Discussion

In hospitals and industries, thioacetamide (TAA) is often used in instead of hydrogen sulphide. It has been defined as a relatively mild carcinogen that modifies the nucleus size and nucleoprotein metabolism of hepatic parenchymal cells, particularly in cells close to the liver's major vein. As a result, TAA is often utilized as a liver toxin in experimental models. [18].

In the present study, rats treated with the TAA group had substantially greater amounts of ALT, AST, ALP, and total bilirubin, which is a marker of liver failure [2]. This is in line with a prior study that claimed elevated blood levels of these enzymes are the signal for identifying liver impairment. [19].

When TAA toxicity affects the liver and the cells' membrane architecture breaks down as a result, these substances leak into the plasma, increasing their quantity in the blood stream [20].

ALP is normally eliminated by the liver through the bile, but in cases of liver damage brought on by hepatotoxins, the liver is unable to properly excrete bile because of increasing conjugation or bile duct obstruction.[21].

The findings of the current study support those of Mohammadzadeh et al. [22], who reported substantial reduction in serum aminotransferases in rats given berberine .Serum amounts of transaminases could significantly decrease because of hepatic parenchyma healing, hepatocyte regeneration, plasma membrane stabilisation, and recovery of liver tissue injury brought on by TAA [23].

From the results of current research, administration of thioacetamide (TAA) considerably raised the level of total bilirubin, this could be as result of TAA hepatotoxicity. The Berberine treated group showed restoration of the hepatic parenchyma, a reduction in centrilobular necrosis, a rise in the conjugation and liver-secreted bile, and a drop in

serum total bilirubin levels [22]. According to the findings of the current study, the administration of (TAA) to rats induces a discernible decrease in the level of TAC.

(TAA) treatment caused liver damage, which may have been caused by the production of oxygen free radicals that enhanced oxidative stress. Additionally, Apoptosis may have a key role in the pathophysiology of the liver damage caused by TAA [24]. Hepatic lipid peroxidation, which is characterized by defects in cell structure and function brought on by the cell membrane's polyunsaturated fatty acids being oxidized by free radicals, may be the secondary reason of the drop in total antioxidant level [25]. It has been amply proven that BBR has anti-oxidative and anti-inflammatory effects [26]. Oxidative stress and inflammation are two major factors that contribute to liver damage.

Clearly, rats co-treated with berberine had significantly greater TAC levels than those managed with TAA alone. These results are in line with evidenced research showing that berberine can be utilized as an antioxidant to stop tissue lipid peroxidation and boost antioxidant enzyme activity [27].

An additional study discovered that BBR decreased oxidative stress by triggering the nuclear factor erythroid-2-related factor-2 (Nrf2) pathway. Nrf2 was discovered to be an antioxidant transcription factor that mediated the development of antioxidant enzymes. Nrf2 also controlled redox status and energy metabolism in cells, and it is now recognized as a key mediator of BBR in lowering oxidative stress, [28]. Additionally, it was discovered that BBR's effect on Nrf2 depends on the AMPK pathway being activated [22].

Our results showed that TAA injection dramatically elevated interleukin-6 levels, indicating a severe inflammatory response. Results of this research are in line with those of Czechowska et al. [29], who stated that hepatocytes exposed to TAA produce chemicals that trigger the production of pro-inflammatory cytokines like interleukin 6. Interleukin 6 levels dropped in berberine-treated rats, pointing to the anti-inflammatory effects of berberine [28,30]. BBR reduces inflammatory damage by preventing neutrophil chemotaxis and oxygen free radical production, as well as by enhancing superoxide dismutase (SOD) activity, inhibiting the production of TNF, improving ischemia reperfusion, and reducing liver damage. [31] The mRNA and protein expression of IL-6 and TNF- in mice is suppressed by berberine because it prevents nuclear translocation of NF-B p65 [32]. Additionally, berberine administration decreased IL-6 gene expression levels, which is in line with the pattern of cytokine secretion [33]. On the other hand, our research revealed markedly higher amounts of Hydroxy proline after TAA injection. Hydroxyproline estimation is regarded as being of paramount value in chronic liver illnesses with severe fibrosis as a noninvasive fibrotic detecting biomarker [34]. This agrees with the results of Yang et al., who observed that TAA-induced liver damage was likewise accompanied by an elevated quantity of hydroxyproline [35].

In our study, BBR affect hepatic liver fibrosis by triggering ferrous-ion redox processes that activated ferroptosis caused by reactive oxygen species (ROS) in liver stellate cells, suggesting a potential method for treating liver fibrosis [36]. Another study using liver fibrosis models caused

by carbon tetrachloride (CCl<sub>4</sub>) came to the same conclusion [37]. It has been amply proven that BBR contains anti-oxidative and anti-inflammatory actions [38], which are important causes of liver fibrosis.

Histopathological analysis, which showed localized necrosis with high numbers of mononuclear inflammatory cells attracted into the liver, validated this finding. After the generation of liver damage and the emergence of cell injury from thioacetamide exposure with disrupted hepatic lobular architecture in the TAA group, when rats were administered berberine, these symptoms subsided. These findings supported those of Amer *et al.* [39], who noted that the liver anatomy of the TAA-treated group had undergone significant changes, including blood sinusoids and central and portal venous congestion. Additionally, it was evident that inflammatory cells had invaded centrilobular regions.

By reducing periportal necrosis, portal inflammation, localized necrosis, inflammation, and apoptosis, we concluded that pathological examination in our study confirmed berberine's hepatoprotective effect [40].

In this study, DNA taken from the liver tissues of the Thioacetamide-treated group revealed DNA fragmentation associated with apoptosis, whereas DNA fragmentation was only marginally detectable in the Thioacetamide group treated with Berberine. The antiapoptotic impact of Berberine was demonstrated in the current study by a decrease in DNA fragmentation, and These results are in line with those of Yang *et al.* [35], who found that Berberine treatment lowers the level of TAA-induced hepatic DNA damage. The antioxidant and anti-inflammatory capabilities of

berberine reduced the percentage of DNA fragmentation [41].

Wang *et al.* [28] found that giving Berberine to rats with fibrotic livers restores mitochondrial function and prevents DNA damage and apoptosis. It was observed that highly degenerated nuclei were infrequently found, and that nuclear content was nearly normal in appearance and organization, following berberine therapy. Also, Mehrzadi *et al.* [40] demonstrated the preventative effect of berberine against DNA damage. Moreover, according to Zargar *et al.* [2], berberine's antioxidant action prevents apoptosis.

The findings of the present research showed that BBR could be used as a treatment for liver damage. The endogenous antioxidant defense system is activated, oxidative stress is inhibited, inflammation and DNA damage is reduced, which may all contribute to the underlying hepatoprotection. To better comprehend and investigate the efficacy and mechanisms, more extensive scientific investigations should be conducted in the future.

### Conclusions

BBR may be considered a therapeutic agent for liver damage. The natural defense mechanism of antioxidants is activated, oxidative stress is inhibited, inflammation is reduced, and damage to DNA is decreased, which may all contribute to the underlying hepatoprotection. The results highlight the value of BBR as a preventative measure against hepatotoxicity caused by TAA.

Financial support and sponsorship: Nil

Conflict of Interest: Nil

### References

1. Eman E, Hemat E, Hanaa H, Safwat Q. Effects of berberine on high-fat/high-sucrose-



- induced nonalcoholic steatohepatitis in experimental rats. *Tanta Medical Journal*. 2019; 47:80.
2. **Zargar S, Wani TA, Alamro AA, Ganaie MA.** Amelioration of thioacetamide-induced liver toxicity in Wistar rats by rutin. *Int J Immunopathol Pharmacol*. 2017; 30:207-14
  3. **Keshk WA, Soliman NA, Ali DA, Elseady WS.** Mechanistic evaluation of AMPK/SIRT1/FXR signaling axis, inflammation, and redox status in thioacetamide-induced liver cirrhosis: The role of *Cichorium intybus* linn (chicory)-supplemented diet. *J Food Biochem*. 2019; 43(8):1-9.
  4. **Zhou M, Deng Y, Liu M, Liao L, Dai X, Guo C, et al.** The pharmacological activity of berberine, a review for liver protection. *Eur J Pharmacol*. 2021; 890:17-36.
  5. **Udomsinprasert W, Jittikoon J. Vitamin d and liver fibrosis:** Molecular mechanisms and clinical studies. *Biomed Pharmacother*. 2019; 109:1351-60.
  6. **Adeyemi WJ, Olayaki LA.** Diclofenac - induced hepatotoxicity: Low dose of omega-3 fatty acids have more protective effects. *Toxicol Rep*. 2018; 5:90-5.
  7. **Zhang Y, Chang X, Song X, Chen C, Chen H, Lu Z, et al.** Berberine reverses abnormal expression of L-type pyruvate kinase by DNA demethylation and histone acetylation in the livers of the non-alcoholic fatty disease rat. *Int J Clin Exp Med*. 2015; 8:7535-43.
  8. **MK M, Abd El-Hamid OM, MA E, Bakr MA.** Biochemical and histopathological effect of probiotics on experimentally induced liver fibrosis in rats. *Benha Med J*. 2016; 31:248-53.
  9. **Bhatia A, Saikia PP, Dkhar B, Pyngrope H.** Anesthesia protocol for ear surgery in Wistar rats (animal research). *Animal Model Exp Med*. 2022; 5:183-8.
  10. **Palipoch S, Punsawad C.** Biochemical and histological study of rat liver and kidney injury induced by Cisplatin. *J Toxicol Pathol*. 2013; 26:293-9.
  11. **Adeyemi OT, Osilesi O, O Adebawo O, D Onajobi F, Oyedemi SO, Afolayan A.** Alkaline phosphatase (ALP), aspartate aminotransferase (AST) and alanine aminotransferase (ALT) Activities in selected tissues of rats fed on processed atlantic horse mackerel (*Trachurus trachurus*). *Advances in Bioscience and Biotechnology*. 2015; 6:139-52.
  12. **Mounieb F, Ramadan L, Akool ES, Balah A.** Propolis alleviates concanavalin A-induced hepatitis by modulating cytokine secretion and inhibition of reactive oxygen species. *Naunyn Schmiedebergs Arch Pharmacol*. 2017; 390:1105-15.
  13. **Koracevic D, Koracevic G, Djordjevic V, Andrejevic S, Cosic V.** Method for the measurement of antioxidant activity in human fluids. *J Clin Pathol*. 2001; 54:356-61.
  14. **Nordan RP, Richards CD, Gauldie J.** Measurement of interleukin 6. *Curr Protoc Immunol*. 2001; 6:6-56.
  15. **Cissell DD, Link JM, Hu JC, Athanasiou KA.** A Modified Hydroxyproline Assay Based on Hydrochloric Acid in Ehrlich's Solution Accurately Measures Tissue Collagen Content. *Tissue Eng Part C Methods*. 2017; 23:243-50.
  16. **Kasibhatla S, Amarante-Mendes GP, Finucane D, Brunner T, Bossy-Wetzel E,**

- Green DR.** Analysis of DNA fragmentation using agarose gel electrophoresis. *CSH Protoc.* 2006;2006.
- 17. Gibson-Corley KN, Olivier AK, Meyerholz DK.** Principles for valid histopathologic scoring in research. *Vet Pathol.* 2013; 50:1007-15.
- 18. Sayan M, Karabulut D, Özdamar S.** Assessment of the protective and therapeutic effect of melatonin against thioacetamide-induced acute liver damage. *J Biochem Mol Toxicol.* 2020; 34:24-50.
- 19. Sang-Ho RA, Ri-Hwa SH, Hak-Chol R, Jong-HR, Hui-Chol R, Ae-Jong R.** Effect of lesimarin against thioacetamide-induced liver cirrhosis in rat, *Brazilian Journal of Pharmaceutical Sciences* 2019; 55:1-9.
- 20. Kalantari H, Foruozandeh H, Khodayar MJ, Siahpoosh A, Saki N, Kheradmand P.** Antioxidant and hepatoprotective effects of Capparis spinosa L. fractions and Quercetin on tert-butyl hydroperoxide- induced acute liver damage in mice *J Tradit Complement Med,* 2018; 8: 120–127.
- 21. Afifi N, El-Erakyb W, Ramadana A, Salama A.** Quercetin protects against thioacetamide induced hepatotoxicity in rats through decreased oxidative stress biomarkers, the inflammatory cytokines; (TNF- $\alpha$ ), (NF- $\kappa$  B) and DNA fragmentation. *Der Pharma Chemica,* 2016; 8:48-55.
- 22. Mohammadzadeh N, Mehri S, Hosseinzadeh H.** Berberis vulgaris and its constituent berberine as antidotes and protective agents against natural or chemical toxicities. *Iran J Basic Med Sci.* 2017; 20:538-51.
- 23. Eftekhari A, Amir H, Rovshan KH, Hasan H, Elham A, Mohammad AE.** Hepatoprotective role of berberine against paraquat-induced liver toxicity in rat, *Environmental Science and Pollution Research* 2020; 27:4969–4975.
- 24. Dwivedi DK, Jena GB.** Simultaneous Modulation of NLRP3 Inflammasome and Nrf2/ARE Pathway Rescues Thioacetamide-Induced Hepatic Damage in Mice: Role of Oxidative Stress and Inflammation. *Inflammation.* 2022; 45:610-26.
- 25. Al Asmari AK, Abbas Manthiri RM, Osman NMA, Al Otaibi AF, Al Asmari SA.** The Beneficial Role of Quercetin on Echis coloratus Snake Venom Induced Hepato-renal Toxicity in Rats *Journal of Biological Sciences.* 2016; 16:112-119.
- 26. Zhang Z, Li B, Meng X, Yao S, Jin L, Yang J, et al.** Berberine prevents progression from hepatic steatosis to steatohepatitis and fibrosis by reducing endoplasmic reticulum stress. *Sci Rep.* 2016; 6:1-13.
- 27. Feng X, Sureda A, Jafari S, Memariani Z, Tewari D, Annunziata G, et al.** Berberine in Cardiovascular and Metabolic Diseases: From Mechanisms to Therapeutics. *Theranostics.* 2019; 9:1923-51.
- 28. Wang Y, Liu Y, Du X, Ma H, Yao J.** The anti-cancer mechanisms of berberine: A review. *Cancer Manag Res.* 2020; 12:695-702.
- 29. Czechowska G, Celinski K, Korolczuk A, Wojcicka G, Dudka J, Bojarska A, et al.** Protective effects of melatonin against thioacetamide-induced liver fibrosis in rats. *J Physiol Pharmacol.* 2015; 66:567-79.

30. Hashemzaei M, Rezaee R. A review on pain-relieving activity of berberine. *Phytother Res.* 2021; 35:2846-53.
31. Warowicka A, Nawrot R, Goździcka Józefiak A. Antiviral activity of berberine. *Arch Virol* 2020; 165: 1935-1945.
32. Ehteshamfar SM, Akhbari M, Afshari JT, Seyedi M, Nikfar B, Shapouri-Moghaddam A, et al. Anti-inflammatory and immunomodulatory impacts of berberine on activation of autoreactive T cells in autoimmune inflammation. *J Cell Mol Med.* 2020; 24:13573-88.
33. Jason MA, Cheng-Chi CH, Wen-Chung H, Ming-Ling K. Berberine Inhibits Pro-Inflammatory Cytokine-induced IL-6 and CCL11 Production via Modulation of STAT6 Pathway in Human Bronchial Epithelial Cells, *Int J Med Sci.* 2020; 17(10): 1464–1473.
34. Gabr SA, Alghadir AH, Sherif YE, Ghfar AA. Hydroxyproline as a Biomarker in Liver Disease. In: Preedy VR, editor. *Biomarkers in Liver Disease.* Dordrecht: Springer Netherlands; 2016. p. 1-21.
35. Yang HY, Kim KS, Lee YH, Park JH, Kim JH, Lee SY, et al. *Dendropanax morbifera* ameliorates thioacetamide-induced hepatic fibrosis via  $\text{tgf-}\beta\text{1/smads}$  pathways. *Int J Biol Sci.* 2019; 15:800-11
36. Yi J, Wu S, Tan S, Qin Y, Wang X, Jiang J, et al. Berberine alleviates liver fibrosis through inducing ferrous redox to activate ROS-mediated hepatic stellate cells ferroptosis. *Cell Death Discov.* 2021; 7:37-54.
37. Bansod S, Saifi MA, Godugu C. Molecular updates on berberine in liver diseases: Bench to bedside. *Phytother Res.* 2021; 35:5459-76.
38. Liu X, Wang L, Tan S, Chen Z, Wu B, Wu X. Therapeutic effects of berberine on liver fibrosis are associated with lipid metabolism and intestinal flora. *Frontiers in Pharmacology.* 2022; 13:12-36
39. Amer MG, Mazen NF, Mohamed AM. Caffeine intake decreases oxidative stress and inflammatory biomarkers in experimental liver diseases induced by thioacetamide: Biochemical and histological study. *Int J Immunopathol Pharmacol.* 2017; 30:13-24
40. Mehrzadi S, Fatemi I, Esmailizadeh M, Ghaznavi H, Kalantar H, Goudarzi M. Hepatoprotective effect of berberine against methotrexate induced liver toxicity in rats. *Biomed Pharmacother.* 2018; 97:233-9
41. Li X, Xu S, Zhang Y, Li K, Gao XJ, Guo MY. Berberine depresses inflammation and adjusts smooth muscle to ameliorate ulcerative colitis of cats by regulating gut microbiota. *Microbiol Spectr.* 2022; 10:20-72.