

Three Years Evaluation of Single Versus Two Implants Retained Mandibular Overdenture Regarding Marginal Bone Loss, Gingival and Plaque Indices: A Randomized Controlled Clinical Trial

Ali Abdulghani AlSourori¹, Sherihan Hanafy Salem^{2,3}, Radwan Saleh Algabri⁴, Marwa Hassan Mostafa*²

¹ Department of Prosthodontics, Faculty of Oral and Dental Medicine, Nahda University Beni Suef, Egypt

² Departments of Fixed and Removable Prosthodontics, Oral and Dental Research Institute, National Research Center, Cairo, Egypt

³ Department of Prosthodontics, Faculty of Oral and Dental Medicine, Ahram Canadian University, Egypt

⁴ Department of Prosthodontics, Rawda Center, Egypt

*Corresponding author: Marwa Hassan Mostafa, Mobile: (+20) 01098771295, E-mail: Dr_marwa_hassan@yahoo.com

ABSTRACT

Background: Completely edentulous patients' primary concerns with mandibular dentures are lack of stability and retention, along with a diminished ability to chew. Nevertheless, when dental implants were developed, it was feasible to prevent these issues and considerably improve the functional activities. **Objectives:** Estimating the marginal level of the bone and peri-implant soft tissue response around single versus two implants retained mandibular over-dentures was the goal of this investigation. **Materials and methods:** 24 completely edentulous patients with a mean age of 56 years (13 males and 11 women) were carefully chosen for this investigation. Selected patients were divided at random into 2 equal groups, 12 each. It was chosen whether to place with a single implant (GI) or two inter-foramina implants (GII) in the mandible. The implants had been attached to locator attachments after a three-month healing period, and the denture had been delivered with the retentive components integrated into the denture base. Estimates of marginal bone loss and peri-implant soft tissue response were taken at the three-, six- to twelve-months', and three-year follow-up exams. In G II, 24 implants were inserted, compared to 36 in G I. All participants finished the three-year follow-up period. **Results:** Regarding marginal loss of bone, the two-implant group (GII) displayed less amount of loss in comparison to single implant group (GI) but this difference was not significant from statistical point of view. Regarding the plaque index and gingival index, the findings revealed that there were no significant differences between the patients in either group. **Conclusion:** In comparison to one implant-retained mandibular overdenture, marginal bone loss was reduced with two implant-retained mandibular overdentures. However, single implant mandibular overdentures appear to a substitute option for the management of edentulous persons in poor socioeconomic categories.

Keywords: Marginal Bone Loss, Single Implants Overdenture, Mandibular Over-Dentures, Implant Retained Over-dentures, Peri-Implant Soft Tissue Parameters.

INTRODUCTION

Completely edentulous people who accept wearing conventional complete dentures nonetheless complain about difficulty chewing or eating hard or solid meals. They frequently cut back on their dietary intake or start eating only certain foods, which results in a loss of important nutritional values. Patients who wear complete dentures may experience lower levels of happiness and a lower quality of life as a result ^[1,2]. Therefore, effective prosthetic treatment depends on evidence-based thorough treatment planning, which should take into account a number of fundamentals, including patient preferences and needs, anatomical restrictions, and prosthetic limitations ^[3].

Many patients want an implant-retained denture but can't afford one due to financial constraints. In such cases, the use of an overdenture may be an option if there is only one mandibular implant present. In individuals who wear dentures, two-implant overdentures significantly increase stability, retention, and quality of life. Mandibular two-implant overdentures were discovered to be superior to all alternative treatments, including removable complete dentures, bar-style implant overdentures, and magnet-style implant overdentures, in terms of peri-implant

outcomes ^[3,4]. However, the low economic level of developing citizens is the major barrier to this suggestion. Hence, the mandibular single-implant overdenture concept was promoted as a satisfactory replacement for the two-implant mandibular overdenture in order to stabilize the lower denture. Regarding the older population's health and economic situation, the single-implant mandibular over-dentures concept may be beneficial ^[5].

Implant-supported restorations are frequently accompanied by concerns about marginal bone loss. It is defined as the loss of bone around the implant, particularly at the crestal level, over time. Several factors can contribute to marginal bone loss, such as implant design, surgical technique, loading protocol, and prosthetic design. The use of implant-retained overdentures has been a widespread treatment option for mandibular edentulism. However, there is still argument regarding the optimal number of implants necessary to provide adequate support for overdenture and decrease marginal bone loss ^[6].

The following parameters were used to determine implant success: implant mobility, implant pain, radiolucency along the whole length of the implant,

and marginal (crestal) loss of bone (more than 1.5 mm). Suppuration and hemorrhage were frequently associated with success at the peri-implant soft tissue level [7].

Kim et al. carried out a systematic review that examined the criteria for mandibular implant overdentures and provide standardised evaluation standards. They discovered that linking the complete endurance rate is essential for implant evaluation. Additional standards for peri-implant tissue evaluation include attached gingiva level, probing depth, plaque index, bleeding index, and marginal loss of bone [8].

For dental implants to be successful in the long run, the peri-implant bone tissue must be preserved. The prosthesis, peri-implant soft tissue, and the implant are the most often used factors for assessing success in implant dentistry, together with the patient's subjective evaluation [7]. The criteria for defining dental implant success are continuously contested; however, osseointegration achievement and preservation are recognized as crucial elements, making marginal bone loss (MBL) an important aspect [6].

Marginal bone loss (MBL) is impacted by numerous factors, including surgical trauma, prosthetic considerations, implant design, bone foundation, patient behaviors, implant-abutment link, and patients' overall health [6,8,9].

Consequently, this clinical trial was implemented to assess the success criteria at implant level including marginal loss of bone and success at peri-implant soft tissue level including plaque index and gingival index in the single-implant mandibular retained over-denture versus two implants retained mandibular overdentures. The research question was, "Will a single-implant mandibular retained over-denture result in a higher success rate than a two-implant mandibular retained over-denture in a completely edentulous mandible?". This trial was done following authorizations established in the CONSORT, Statement for reporting RCT.

MATERIALS AND METHODS

Trial Design and Setting:

A parallel group, 1:1 allocation ratio randomized clinical trial (RCT) was intended for the investigation. From June to December 2019, 24 patients with entire edentulous (13 men and 11 women), with an average age of 56, were chosen from the Prosthodontics Department's Outpatient Clinic at Nahda University's Faculty of Oral and Dental Medicine in Beni Sewif, Egypt.

The following groups were randomly assigned to the patients:

- Intervention (Group 1): each patient received a single implant-retained mandibular overdenture.

- Control group (Group 2): each patient received two inter-foramina implants and retained a mandibular over-denture.

Ethical considerations:

The study protocol was approved by the Ethical Committee of the Faculty of Oral and Dental Medicine, Nahda University, Beni Sewif, Egypt, no. 030223. All participants signed an informing consent, which was translated into Arabic for the patients' benefit, after a thorough explanation of the goals of the study. The Helsinki Declaration was followed throughout the study's conduct.

Participants: (Sample size calculation):

To be 80% confident that a difference in means of greater than 10 will not be excluded by the bounds of a two-sided 95% confidence interval, twenty-four patients must be included (12 in each group).

Eligibility criteria:

The patient's eligibility for the study was initially assessed to see if they were suitable for participation. A clinical examination, a radiological analysis, and a medical history questionnaire made up this evaluation.

Interventions and Study Procedures:

Before the patients were divided into two groups, a conventional complete denture was made for each patient by following traditional methods. Patient grouping (randomization method) using a research randomizer, the 24 patients were divided into two identical groups, each with 12 patients, for the purpose of random sequence generation (<https://www.randomizer.org/>).

Blinding:

Evidently, neither the participants nor the healthcare professionals could be blinded regarding the number of implants inserted, but the healthcare professionals were instructed to refrain from discussing possible treatments with the patients. An unbiased assessor who was unaware of the kind of intervention evaluated the parameters for peri-implant tissue and marginal bone loss. The statistician was blinded.

Radiographic stent fabrication:

The completed mandibular complete dentures were duplicated to create a radiographic stent, and the patient was instructed to wear both the stent and upper complete denture during the imaging procedure to stabilise the stent. Following the completion of radiographic imaging, the radiographic stents were modified by drilling three channels of 2 mm at the midline and canine portions on either side of each stent so that it could be employed as a surgical stent.

Surgical procedure

After receiving anesthesia, the patients in group II received two vertically released crestal incisions in the bilateral canine region. The crestal incision was performed in the anterior midline in participants in Group I. After the surgical stent had been introduced, a twisted guiding drill was used to mark the bone for the site of the implants, and the drill's sequence was then employed to do the osteotomy. The osteotomy site was successively drill-drilled using surgical drills, as directed by the manufacturer (Dentis Surgical Kit; Dentis Co., Ltd., Korea).

Osteotomies were performed using three larger-diameter drills. The root-form self-tapping implant was then inserted by its fixture mount and put into its position in the prepared osteotomy site (Dentis Implant System; Dentis Co, Ltd, Korea). The principal stability was evaluated following drilling with the final drill (3.7 mm x 12 mm). After being correctly placed, the flap was interruptedly stitched with black silk.

After three months, a second stage of surgery was carried out. Measurements of secondary stability were made to confirm functional loading. The implant's location was established using the surgical stent. There was barely any crestal incision. It was removed the cover screw. For two weeks, healing abutments were set up. The suitable height locator attachment (Dentis; Kerator, New York, USA) was then employed in accordance with the height of the peri-implant mucosa.

Prosthetic Pickup Procedure:

Following the protocol for delayed loading, the pick-up was completed following intraoral denture verification. The metal housings, nylon caps, and male attachment components (the housing-cap assembly) were snapped onto the locator abutments. To pick up the locator cap attachments intraorally, cold-curing resin (Rebaron self-curing acrylic; GC Corporation, Tokyo, Japan) was used. Next, the residual ridges' occlusion and adaptability were examined.

Radiographic Evaluation (Assessment of the Marginal bone loss):

Direct digital radiography (DDR) using Digora (Orion Corporation, Soredex Medical Systems, Helsinki, Finland) computerized system was applied. This system employs an electronic imaging plate coupled with the Rinn XCP periapical sensor holder (Rinn Corporation XCP instruments for extension cone paralleling technique, USA) and individually constructed radiographic acrylic templates for performing standardized digital images for loaded implants.

Radiograph exposure method: Standardised periapical radiography was carried out with the aid of an XCP (extension cone paralleling) sensor holder and a custom, individual bite registration record constructed of putty rubber base imprint material (Zetaplus, Zhermack, Italy). This sensor holder was

made up of a guiding ring, a directing rod, and a biting block.

Three slots on the biting block were used to install the X-ray sensor. A putty rubber base impression material was folded around the bite block in order to ensure consistent sensor repositioning for each radiograph, and a bite registration record was obtained with the mouth closed in order to use the artificial tooth indentations as a guide for future sensor holder orientation. The exposure was carried out after flushing the X-ray cone with the guiding ring. For upcoming trips, the putty was set aside.

With the same dental long cone X-ray device, all of the periapical radiographic exposures were taken (Dentotime, Simenens Co., Germany) utilizing the same sensor and same exposure parameters (70Kv, 6 mA, 35 cm focal distance). In order to evaluate the marginal bone loss around dental implants, imaging was done on the twenty-four patients at the baseline, three, six, and 1, 2, and three years. Assessment of little bone loss:

It was determined how much bone was lost marginally: With the help of the Digora programme, a line perpendicular to the implant's long axis and tangential to its apex was first drawn. The mesial and distal halves of the implant were separated from one another by still another line. This line was drawn tangentially to the implant's flutes, extending from the alveolar crest to the first line. The measurements were performed three times at various reading times, and the average of the three attempts was noted. Each implant's mesial and distal bone loss measures during the course of the follow-up periods were averaged out to determine their mean values.

Clinical evaluation of peri-implant tissue:

Both the gingival index (GI) according to **Löe and Silness** ^[10] and the plaque index (PI) according to **Mombelli et al.** ^[11] were noted.

Using a pressure-sensitive plastic periodontal probe that has been calibrated (Vivacare TPS, Vivadent, Schaan, Liechtenstein). Lingually, mesially, buccally, and distally were the four places where the PI and GI were recorded surrounding each implant (Figure 1 and Table 1).

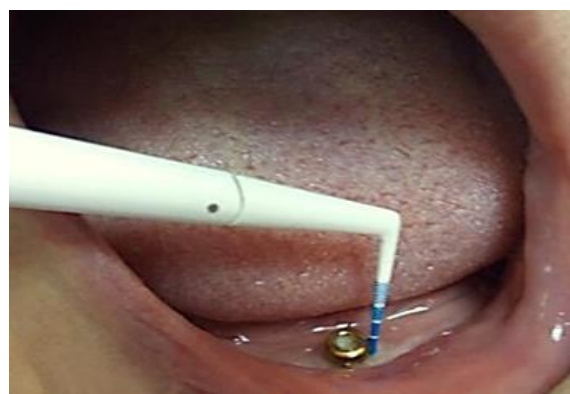

Figure (1): Indices measurement using a plastic probe.

Table (1): Plaque and gingival indices according to Mombelli *et al.* ^[11].

Modified Plaque Index	Gingival Index
Score 0: No detection of plaque.	Score 0: No bleeding when a periodontal probe is passed along the gingival margin adjacent to the implant.
Score 1: Plaque only recognized by running a probe across the smooth marginal surface of the implant. Implants covered by plasma spray in this area always score 1.	Score 1: Isolated bleeding spots visible.
Score 2: Plaque can be seen by the naked eye.	Score 2: Blood forms a confluent red line on margin.
Score 3: Abundance of soft matter.	Score 3: Heavy or profuse bleeding.

The measurement was performed by passing a plastic periodontal probe parallel to the long axis of the implant from the edge of the marginal gingiva at specified distances of 3, 6, and 9 mm. For all patients, the measures were taken twice at the mesial, distal, buccal, and lingual sides with the same probing force. A periodontist (A) who was blind to the study groups evaluated clinical and radiographic parameters after receiving training and calibration from two different dentists. This was done for objectivity's sake.

Statistical analysis

The mean and standard deviation (SD) values were used to represent numerical data. To determine normalcy, the Shapiro-Wilk test was applied. The marginal bone loss data were normally distributed, and groups were contrasted using one-way ANOVA and Tukey's post hoc analysis. The findings were compared using repeated measures ANOVA within each group. Other non-parametric data were evaluated using the Freidman's test and Nemenyi post hoc test for comparison within each group and Mann-Whitney U test for intergroups comparisons. For all tests, the significance level was set at p 0.05. R statistical analysis programme for Windows, version 4.1.3, was used to conduct the statistical investigation.

RESULTS

The study sample included 24 completely edentulous patients (13 males and 11 women), with an average age of 56. Twelve implants were inserted in the intervention group (GI), as opposed to twenty-four in the control group (GII). The three-year follow-up period for every participant was finished (Figure 2).

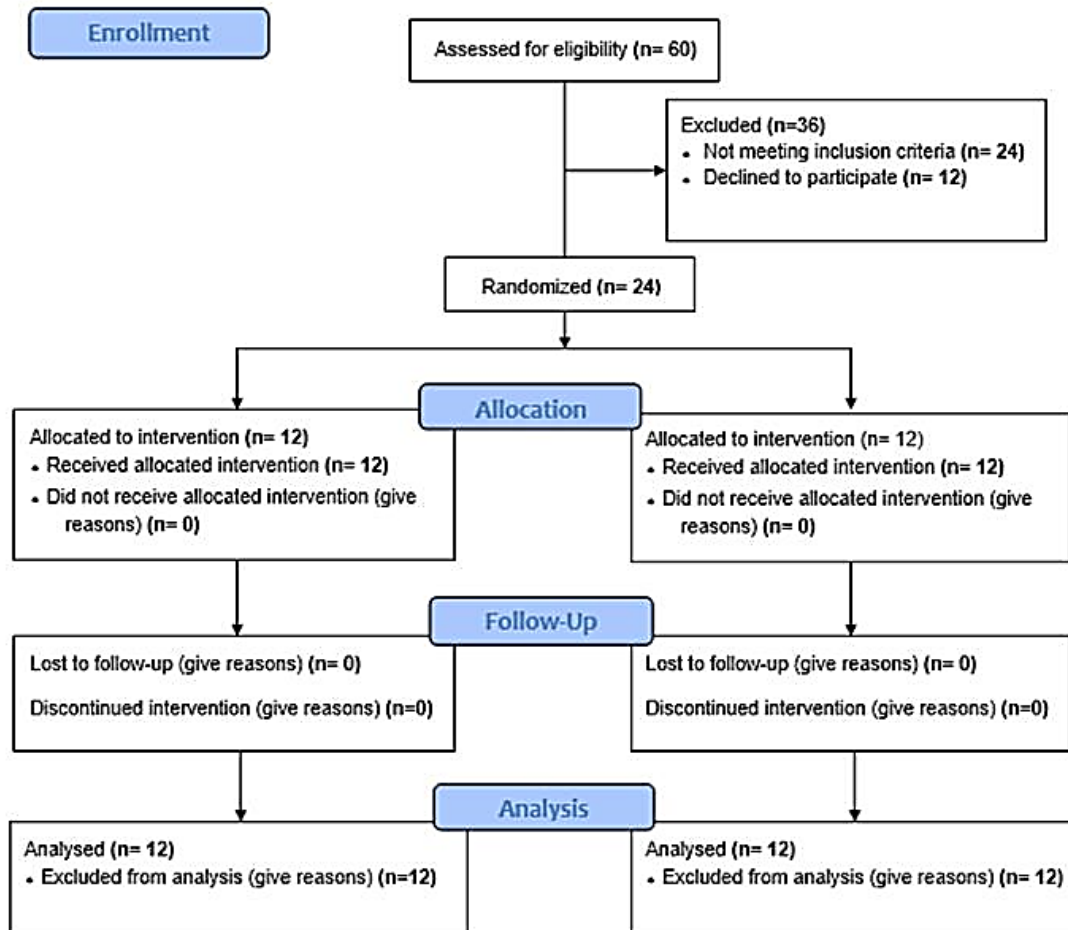


Figure (2): CONSORT flow chart

In table 2's results for between- and within-group comparisons of marginal bone loss, at any of the time points, there was no statistically significant difference between the two groups. The values of bone loss in both groups increased statistically significantly between baseline and three years. All of the findings were statistically significant for post-hoc pairwise comparisons involving a single implant. They were all statistically significant for two implants, with the exception of the difference between 2 and 3 years. Figure (3) provides the average and standard deviation for marginal bone loss.

Table (2): Inter- and intragroup comparison of marginal bone loss (mm)

Interval	Marginal bone loss (mm) (Mean±SD)		f-value	p-value
	Single implant	Two implants		
Baseline	0.36±0.12	0.32±0.10	0.73	0.470
3 months	0.73±0.13	0.71±0.14	0.46	0.652
6 months	1.03±0.16	0.98±0.16	0.89	0.384
12 months	1.26±0.20	1.32±0.15	0.81	0.427
2 years	1.47±0.17	1.46±0.16	0.12	0.904
3 years	1.61±0.13	1.56±0.17	0.81	0.425
f-value	312.61	370.43		
p-value	<0.001*	<0.001*		
Baseline-3 years	1.25±0.14	1.23±0.12	0.31	0.758

Within the same vertical column, several superscript letters signify a statistically significant difference; *significant (p<0.05)

Table 3's plaque index comparisons between and within groups revealed that there was no difference between the two groups over time. For both groups, the measured index values increased significantly. From the baseline to the third year, post hoc pairwise comparisons for a single implant revealed that values assessed at 2 and 3 years were considerably greater than those at baseline and at 3 months. Additionally, they showed that the value was significantly greater than the baseline value at 3, 6, and 12 months.

They demonstrated that the values for the two implants group at 2 and 3 years, as well as at 12 months, were considerably greater than the values at baseline and at 3 months. Additionally, they showed values that were significantly greater than baseline values when evaluated at 3 and 6 months. Figure (4) displays the plaque index's mean and standard deviation.

Table (3): Inter- and intragroup comparison of plaque index

Interval	Plaque index (Mean±SD)		u-value	p-value
	Single implant	Two implants		
Baseline	0.54±0.33	0.60±0.45	76.50	0.814
3 months	1.27±0.42	1.46±0.58	86.50	0.407
6 months	1.52±0.45	1.71±0.46	88.50	0.347
12 months	2.02±0.64	2.19±0.39	86.00	0.424
2 years	2.10±0.41	2.23±0.39	80.50	0.628
3 years	2.29±0.37	2.27±0.29	77.50	0.766
q-value	49.75	48.21		
p-value	<0.001*	<0.001*		
Baseline-3 years	1.75±0.43	1.67±0.42	84.00	0.492

Within the same vertical column, several superscript letters signify a statistically significant difference; *significant (p<0.05).

As shown in table 4's gingival index comparison results for both inter- and intragroup comparisons, there was no difference between the two groups at any point. For both groups, the measured index values increased significantly. Starting from baseline until 3 years, for single implant, value assessed at baseline was considerably lower than other periods, according to post hoc pairwise comparisons. For two implants group, they showed 2 and 3 years as well as 12 months values to be significantly greater than baseline and 3 months values. Moreover, they exhibited values measured after 3 and 6 months to be significantly higher than baseline value. Mean and standard deviation values for gingival index are presented in figure (5).

Table (4): Inter- and intragroup comparison of gingival index

Interval	Gingival index (Mean±SD)		u-value	p-value
	Single implant	Two implants		
Baseline	0.60±0.33 ^B	0.50±0.34 ^C	84.00	0.492
3 months	1.31±0.37 ^A	1.44±0.34 ^B	87.00	0.393
6 months	1.69±0.47 ^A	1.81±0.37 ^{AB}	86.00	0.427
12 months	2.10±0.69 ^A	2.29±0.40 ^A	81.50	0.599
2 years	1.96±0.35 ^A	2.17±0.44 ^A	90.00	0.297
3 years	1.88±0.31 ^A	2.12±0.33 ^A	100.50	0.081
q-value	41.56	49.29		
p-value	<0.001*	<0.001*		
Baseline-3 years	1.27±0.39	1.62±0.45	105.00	0.056

Within the same vertical column, several superscript letters signify a statistically significant difference; *significant (p<0.05).

DISCUSSION

This parallel group trial was designed to evaluate the hypothesis that peri-implant tissues supporting an overdenture in the group utilizing a single implant can exhibit a standardized result when compared to those in the group using two implants.

Because it is more dependable and accurate, the Digora software was utilized to calculate the degree of bone loss. Instead of using panoramic radiographs for the peri-implant alveolar bone evaluation, long cone paralleling radiographs were employed since they remove distortion and had a lower magnification [12,13].

The graduated plastic periodontal probe was used to evaluate the periodontal condition around dental implant to avoid the scratch of metal surface of implant and lead to plaque accumulation and predisposing to peri-implantitis [14].

The study compared the outcomes of single and two implant mandibular overdentures over a 3-year period, concentrating on loss of bone, plaque index, and gingival index. Results revealed no significant difference in loss of bone between the two groups, plaque and gingival indices. However, both groups showed a significant increase in all three measures starting from baseline until 3 years. Accordingly, the hypothesis was refused.

The obtained results can also be explained by the fact that greater marginal bone loss plaque index and gingival index could be accredited to improper oral hygiene by the patients. The study highlights the importance of regular check-ups and maintenance to prevent further deterioration of oral health. Therefore, the findings of this prospective clinical investigation revealed that neither the clinical nor radiographic conditions significantly differed.

According to the study's findings regarding marginal bone loss, tables (2, 3) and figure (3) revealed that there was a statistically significant difference in the rate of crestal bone height loss between the two groups over time. According to the study, the two-implant group demonstrated less crestal bone loss than the single implant group. In the single implant group, the mean crestal bone resorption was 1.61 ± 0.13 mm, whereas in the two-implant group, it was 1.56 ± 0.17 mm. These findings are consistent with earlier research [15-21].

Moreover, the use of two implants may also provide better support and distribution of occlusal forces, which can lower chances of implant failure and marginal loss of bone. In contrast, single implant-retaining mandibular overdentures may be less stable and more prone to movement and slippage, which can lead to increased marginal bone loss. However, it's essential to point out that research findings comparing single and two implant mandibular overdentures are conflicting and further research is needed [5, 22-25].

In accordance with our results, previous study [26] revealed that marginal bone loss decreases with

increasing the number of implants. While disagreements were found with former studies [23,24,27].

Regarding plaque and gingival indices, the result of this study in tables (3, 4) and figures (4, 5) revealed, by time, statistical insignificant difference between the two groups. Single implant showed less plaque and gingival indices. The possible explanation of this result might be related to the assumption that the accumulation of microbiota in peri-implants soft tissue increase with the increase in number of implants.

In all groups, plaque and gingival indices significantly grew over time at all evaluated sites. On the other hand, past studies [28,29] showed that these characteristics did not significantly increase over time. The fact that the majority of the patients in this study were not properly taking care of their oral hygiene may be what caused the different results.

In line with findings from earlier studies [30, 31], which showed a negligible rise in these parameters after a year, we discovered that the two-implant group had considerably higher plaque and gingival scores. The severe oral hygiene regimen that patients were required to follow in previous trials may be to blame for the disparity, while the hygienic measures of most patients looked at in our study proved to be unsatisfactory.

Overall, this study's findings revealed no statistically significant differences in the patient populations in the two groups, suggesting that a single implant might be utilised as an alternative to two implants to maintain a mandibular overdenture. This finding is in line with past studies by [16, 18, 22, 32].

When more compelling data for it develops, particularly with long-term outcomes beyond 5 years, the mandibular single-implant overdenture may eventually be the minimum standard advised for compromised elderly edentulous patients, especially those of poor socioeconomic status.

CONCLUSION

The following conclusions can be pinched in light of the study's limitations:

The use of two implants may provide better outcomes in terms of marginal bone loss. However, the use of two implants may also increase the cost of treatment and require more invasive surgery. The decision to use one or two implants should therefore be made on a case-by-case basis, taking into account the patient's specific needs and preferences as well as their financial circumstances.

Supporting and sponsoring financially: Nil.

Competing interests: Nil.

REFERENCES

1. **Das K, Jahangiri L, Katz R (2012):** The first-choice standard of care for an edentulous mandible: a Delphi method survey of academic prosthodontists in the United States. *J Am Dent Assoc.*, 143:881–889.
2. **Thomason J, Lund J, Chehade A et al. (2003):** Patient satisfaction with mandibular implant overdentures and

- conventional dentures 6 months after delivery. *Int J Prosthodont.*, 16:467–473.
3. **Thomason J, Feine J, Exley C et al. (2009):** Mandibular two implant-supported overdentures as the first choice standard of care for edentulous patients—the York Consensus Statement. *Br Dent J.*, 207:185–186.
 4. **Rashid F, Awad M, Thomason J et al. (2011):** The effectiveness of 2-implant overdentures: a pragmatic international multicenter study. *J Oral Rehabil.*, 38:176–184.
 5. **Mahoorkar S, Bhat S, Kant R (2016):** Single implant supported mandibular overdenture: A literature review. *J Indian Prosthodont Soc.*, 16: 75–82.
 6. **Galindo-Moreno P, León-Cano A, Ortega-Oller I et al. (2015):** Marginal bone loss as success criterion in implant dentistry: beyond 2 mm. *Clin Oral Implants Res.*, 26:28–34.
 7. **Papaspyridakos P, Chen C, Singh M et al. (2012):** Success criteria in implant dentistry: a systematic review. *J Dent Res.*, 91:242–248.
 8. **Kim H, Shin S, Lee J (2014):** Standardizing the evaluation criteria on treatment outcomes of mandibular implant overdentures: a systematic review. *J Adv Prosthodont.*, 6:325–332.
 9. **Monje A, Suarez F, Galindo-Moreno P et al. (2014):** A systematic review on marginal bone loss around short dental implants (<10 mm) for implant-supported fixed prostheses. *Clin Oral Implants Res.*, 25: 1119–124.
 10. **Löe H, Silness J (1963):** Periodontal disease in pregnancy. I. Prevalence and severity. *Acta Odontologica Scandinavica*, 21: 533–551.
 11. **Mombelli A, van Oosten M, Schurch E et al. (1987):** The microbiota associated with successful or failing osseointegrated titanium implants. *Oral Microbiology and Immunology*, 2: 145–151.
 12. **Frederiksen N (1995):** Diagnostic imaging in dental implantology. *Oral Surgery, Oral Med Oral Pathol Oral Radiol Endo-dontics*, 80:540–554.
 13. **Wismeijer D, van Waas M, Mulder J et al. (1999):** Clinical and radiological results of patients treated with three treatment modalities for overdentures on implants of the ITI Dental Implant System. A randomized controlled clinical trial. *Clin Oral Implants Res.*, 10:297–306.
 14. **Heitz-Mayfield L (2008):** Peri-implant diseases: diagnosis and risk indicators. *J Clin Periodontol.*, 35: 292-304.
 15. **Cordioli G, Majzoub Z, Castagna S (1997):** Mandibular overdentures anchored to single implants: a five-year prospective study. *J Prosthet Dent.*, 78: 159–65.
 16. **Kronstrom M, Davis B, Loney R et al. (2014):** A Prospective randomized study on the immediate loading of mandibular overdentures supported by one or two implants; A 3 year follow-up report. *Clin Implant Dent Relat Res.*, 16: 323-329.
 17. **Tavakolizadeh S, Vafae F, Khoshhal M et al. (2015):** Comparison of marginal bone loss and patient satisfaction in single and double-implant assisted mandibular overdenture by immediate loading. *J Adv Prosthodont.*, 7: 191–198.
 18. **Kronstrom M, Davis B, Loney R et al. (2017):** Satisfaction and clinical outcomes among patients with immediately loaded mandibular overdentures supported by one or two dental implants: Results of a 5-year prospective randomized clinical trial. *Int J Oral Maxillofac Implants*, 32:128–36.
 19. **Kant B, Ranjan M, Kumar A et al. (2019):** A randomized controlled trial comparing the radiographic evaluation of crestal bone resorption in single implant versus two implant-retained overdentures. *J Fam Med Prim Care*, 8:1594–1598.
 20. **Kumar V, Arya G, Singh P et al. (2021):** A meta-analysis for evaluation of marginal bone level changes at dental implants. *Natl J Maxillofac Surg.*, 12: 13–16.
 21. **Pardal-Peláez B, Dib A, Guadilla Y et al. (2023):** Marginal bone loss and treatment complications with mandibular overdentures retained by two immediate or conventionally loaded implants—A randomized clinical trial. *Prosthesis*, 5(1): 295–309.
 22. **Alqutaibi A, Esposito M, Algabri R et al. (2017):** Single vs two implant-retained overdentures for edentulous mandibles: a systematic review. *Eur J Oral Implantol.*, 10(3): 243–61.
 23. **Gill H, Nagpal A, Vaidya S et al. (2021):** Analysis of marginal bone loss and residual ridge resorption in conventionally loaded single and two implant supported overdentures. *International Journal of Drug Research and Dental Science*, 3: 14-17.
 24. **Hauck K, Trentin M, Skiba T et al. (2021):** Clinical and satisfaction outcomes of using one or two dental implants for mandibular overdentures: preliminary short-term follow-up of a randomized clinical trial. *Int J Implant Dent.*, 7: 10-15.
 25. **Gaur T, Goswami R, Mowar A et al. (2023):** Marginal bone level measurements of unsplinted implants used for mandibular overdentures: A six-month randomized prospective clinical study comparing early and delayed loading protocols. *Cureus*, 15: 35210. doi: 10.7759/cureus.35210.
 26. **Khoshhal M, Vafae F, Moradi O et al. (2016):** Evaluation of clinical and radiographic signs of implants in patients with implant retained mandibular overdentures. *Avicenna J Dent Res.*, 9: 29360–29360.
 27. **Cooper L, Moriarty J, Guckes A et al. (2008):** Five-year prospective evaluation of mandibular overdentures retained by two microthreaded, TiOblast nonsplinted implants and retentive ball anchors. *Int J Oral Maxillofac Implants*, 23(4):696-704.
 28. **Turkyilmaz I, Tözüm T, Tumer C et al. (2006):** A 2-year clinical report of patients treated with two loading protocols for mandibular overdentures: early versus conventional loading. *J Periodontol.*, 77: 1998–2004.
 29. **Liao K, Kan J, Rungcharassaeng K et al. (2010):** Immediate loading of two freestanding implants retaining a mandibular overdenture: 1-year pilot prospective study. *Int J Oral Maxillofac Implants*, 25: 784–790.
 30. **Meijer H, Raghoobar G, Van 't Hof M (2003):** Comparison of implant-retained mandibular overdentures and conventional complete dentures: a 10-year prospective study of clinical aspects and patient satisfaction. *Int J Oral Maxillofac Implants*, 18: 879–885.
 31. **Visser A, Raghoobar G, Meijer H et al. (2005):** Mandibular overdentures supported by two or four endosseous implants. A 5-year prospective study. *Clin Oral Implants Res.*, 16: 19–25.
 32. **AlSourori A, Mostafa M, Kaddah A et al. (2018):** Impact of single implant versus two-implant mandibular retained overdentures on retention and success rate in totally edentulous patients. A randomized controlled clinical trial. *Journal of Osseointegration*, 10: 79–86.