

## Zancolli Lasso Technique Versus Brand Technique in Hand Clawing: A Comparative Study of Functional Outcomes

ABDELKHALEK M. SALLAM, M.B.B.Ch.\*; HASHEM M. AYAD, M.D.\*;  
HAMDY S. ABDALLAH, M.D.\*\* and SAMIR M. GHORABA, M.D.\*

The Departments of Plastic & Reconstructive Surgery\* and General Surgery\*\*, Faculty of Medicine, Tanta University

### ABSTRACT

**Background:** Ulnar nerve palsy has a negative impact on basic daily activities. The ulnar nerve lesions seem to be far worse than the median and radial nerves. Tendon transfer offers the sole solution in neglected cases of ulnar nerve injuries by providing active-controlled motion. Tendon transfers are performed to eradicate claw deformity and restore hand grip.

**Objective:** To evaluate the effectiveness of the Zancolli Lasso procedure (ZLP) vs. Brand technique "Extensor Carpi Radialis Longus Transfer" in treating hand clawing.

**Patients and Methods:** Twenty patients who suffered from isolated ulnar nerve palsy, regardless the level of injury, with hand clawing after one year or more from the initial injury time with no clinical signs of nerve recovery participated in this prospective study. Ten patients were operated on using the Zancolli Lasso procedure (group A), and ten patients used Extensor Carpi Radialis longus tendon transfer (group B). Prior to and following surgery, patients underwent both subjective and objective evaluations.

**Results:** Group A showed significantly shorter operative time, while Group B showed better Hand Assessment Tool (HAT) score and hand grip measurements. Both groups showed significant differences in the variable PIP and DIP joint range of motion.

**Conclusion:** ZLP is an easier surgical choice for claw deformity correction with shorter operative time, while ECRL bestows better handgrip improvement and patient-reported outcomes. Thus, ECRL is favored in manual workers, whereas ZLP is favored in patients with medical comorbidities whenever a shorter operative time is recommended.

**Key Words:** Claw hand – Ulnar – Zancolli – Brand – Tendon transfer.

**Level of Evidence:** Level IV, therapeutic study.

**Disclosure:** No conflict of interest.

**Ethical Committee:** The Ethics Committee of Tanta University's Faculty of Medicine gave its authorization before the investigation was carried out (34826/8/21). All patients provided written consent after being fully informed.

**Correspondence to:** Dr. Abdelkhalak M. Sallam  
E-Mail: sallabdo1@gmail.com

### INTRODUCTION

Daily life is severely impacted by ulnar nerve palsy. Therefore, ulnar nerve palsy should be promptly managed to evade these formidable consequences [1].

The ulnar nerve lesions seem to be far worse than the median and radial nerves. Murovic (2009) analyzed outcomes in 1837 lesions of the three nerves at all levels. Primary repair success rates for the median and radial nerves at different levels were 91%, higher than the ulnar nerve success rate (73%). The success rates of secondary suturing and grafting on the median nerve were 78% and 68%, respectively, compared to 69% and 67% for the radial nerve and (69% and 56%) for the ulnar nerve [2,3].

Tendon transfer offers a sole solution in neglected cases of ulnar nerve injuries by providing active-controlled. Tendon transfers are performed to treat claw hands and improve hand function [4].

The selection of the appropriate surgical technique usually depends on the donor's muscle availability, joint mobility, the patient's normal routine, and the surgeon's background [5].

The balance between the extensor and flexor tendons controlling the Metacarpophalangeal as well as the inter-phalangeal joints is regained through either weakening the flexor strength through the Zancolli technique or strengthening the extensor tone through Brand's technique.

Correction of grip strength and claw finger deformities is crucial for people with temporary paralysis. For this, the Zancolli Lasso technique (ZLP) [6] or ECRL 4-tail techniques [7] are suggested. On the other hand, many sources recommend the FDS 4-tail technique for correcting asyn-

chronous finger movements in long-standing cases of extensor lag [8].

We reviewed the literature and found no evidence supporting one technique.

*This study aims to:*

Compare the ZLP and the Extensor Carpi Radialis Longus Transfer regarding their functional results for hand clawing, including hand grip assessment, total range of motion for both the ring and little fingers and the HAT score.

## PATIENTS AND METHODS

Twenty patients were enrolled in this prospective observational trial with neglected ulnar nerve injury at the Department of Plastic Surgery, Tanta University. The study extended between September 2021 and September 2022. The Ethics Committee of Tanta University's Faculty of Medicine gave its authorization before the investigation was carried out (34826/8/21). All patients provided written consent after being fully informed.

*Patients:*

*Inclusion criteria:*

All patients suffering from isolated ulnar nerve palsy with hand clawing after one year or more from the initial time of injury with no clinical signs of nerve recovery were included in the study.

*Exclusion criteria:*

*Patients who met any of the following characters were excluded:*

- 1- Flexor digitorum profundus palsy to the little and ring finger.
- 2- Skeletal instability.
- 3- Poor skin coverage.
- 4- Joint stiffness.
- 5- Brachial plexus injury.

*Methods:*

Patient histories, physical exams, and standard laboratory tests such as complete blood count, prothrombin time, and activity were all performed.

*Twenty patients were randomly assigned to 2 groups using computer-generated numbers:*

- Group A: 10 patients were operated upon using the FDS Lasso transfer (Zancolli's Lasso Procedure).
- Group B: 10 patients were operated upon using the Extensor Carpi Radialis Longus (ECRL) Transfer.

*Study measures:*

- 1- Range of motion: (ROM) was measured with the aid of goniometry, applied for both the proximal inter-phalangeal (PIP) and the metacarpophalangeal (MCP) [9].
- 2- Hand grip assessment: Handgrip strength (HGS) was the effort required to grab an object and was essential for many daily activities. It was measured easily using a Jamar dynamometer [10].
- 3- Hand Assessment tool (HAT score): Patients reported outcomes using The Hand Assessment Tool (HAT Score) [11]. For better understanding, the original document was translated into Arabic. The higher score indicates a greater disability.

*Operative steps:*

*Marking of the incisions was done according to each group:*

- Group A: Zancolli Lasso Technique for both little and ring fingers [6].
  - Incision: For each of the two medial fingers, a lax S incision was made and extended from the end of the palm to the start of the interphalangeal crease.
  - Careful dissection of the underlying subcutaneous tissue with cautious identification of the neurovascular bundles.
  - Identification of A1 and A2 pulleys was done. In between, the flexor tendon sheath was identified.
  - Nearly 2mm transverse incision was done in the flexor sheath to retrieve the Flexor digitorum superficialis (FDS) tendon once cut distally.
  - The FDS tendon was identified at the insertion point by the 2 slips, with the FDP tendon passing in between.
  - Both Slips were cut (Fig. 1-A), then the FDS tendon was retracted from the flexor sheath.
  - At the MCP joint level, a prolene suture (USP 4-0, 1/2 circle body, continuous mattress sutures) was used to extract the proximal stump of each tendon, loop it around the A1 pulley, and then suture it to itself. (Fig. 1-B).
  - Adjusting the loop length to get the best results for claw correction.
  - The tourniquet was gradually deflated, recording the time of removal.
  - Hemostasis and closure:
- After meticulous hemostasis by bipolar electrocautery, the skin was closed with prolene sutures USP 4-0, 1/2 circle cutting body needle, and interrupted mattress sutures.

- The final position of the PIP and MCP joints was checked at the end of surgery (Fig. 2).
- Dressing: Sterile dressing was done, and patients were splinted with MCPs in full flexion and IPJs in full extension.

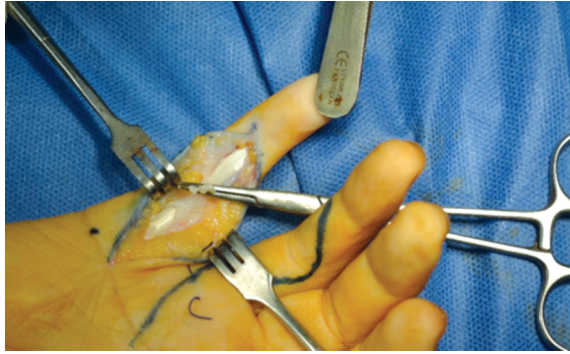


Fig. (1-A): Cutting the Flexor digitorum superficialis tendon at its insertion.

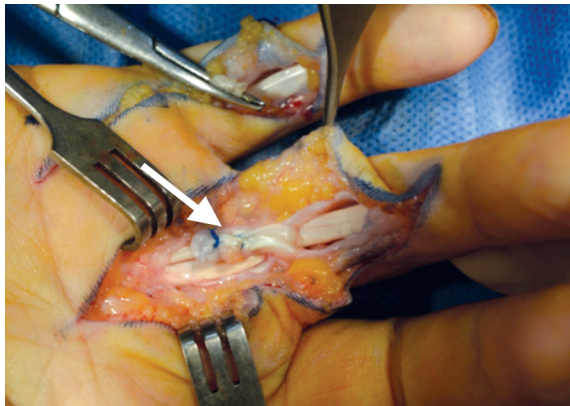

Fig. (1-B): Each tendon's proximal stump (shown by the white arrow) was retracted, wrapped around the A1 pulley, and then sutured on itself at the level of the MP joint.

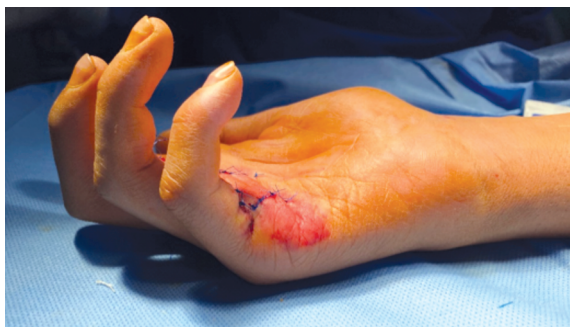

Fig. (2): Intraoperative results of the Zancolli technique for claw correction.

- Group B: ECRL transfer technique [7].
- Retrieving the ECRL tendon: There was only one vertical incision slightly distal to the wrist crease overlying the base of the 2<sup>nd</sup> metacarpal bone (Fig. 3-A).
- Nearly 5cm proximal to the wrist joint, another vertical incision was made overlying the dorsal

aspect of the radius so that the tendon could be retracted proximally.

- The tendon was driven volarly, curving over the lateral aspect of the radius.
- Another transverse incision was made volarly proximal to the wrist by 5cm (Fig. 3-B).
- Harvesting the Fascia Lata graft (15cm x 8cm) through a longitudinal lazy S incision along the lateral aspect of the contralateral thigh.
- The graft was then fashioned into 2 tendon extensions.
- Each extension was sutured to the volarly transpositioned ECRL tendon by prolene sutures USP 4-0, 1/2 circle body, and continuous mattress sutures (Fig. 3-C).
- The 2 extensions were then tunneled through the carpal tunnel.
- A mid-palmar transverse incision was made to pass the 2 grafts to their destination.
- A lateral longitudinal small lazy S incision was performed along the radial border of the proximal phalanx.
- The neurovascular bundles were carefully identified.
- Prolene sutures USP 4-0, a 1/2-inch circular body needle, and continuous mattress sutures were used to attach the graft to the lateral band of the extensor mechanism (Fig. 3-D).
- Adjusting the length of the extension grafts to get the best results for claw correction.
- The tourniquet was gradually deflated, recording the time of removal.
- Hemostasis and closure:

After meticulous hemostasis by bipolar electrocautery, the skin was closed with prolene sutures USP 3-0, 1/2 circle cutting body, and interrupted mattress sutures.

- The final position of the PIP and MCP joints was checked at the end of surgery.
- Dressing: Sterile dressing was done, and patients were splinted with MCPs in full flexion and IPJs in full extension.

#### Postoperative follow-up:

- Postoperative care: Prophylactic antibiotics (e.g., twice-daily iv amoxicillin and clavulanic acid) and analgesics (NSAIDs and acetaminophen) were administered for 48-72 hours after surgery. Hands were raised to reduce postoperative edema.
- Physical rehabilitation started 3 weeks after the surgery.

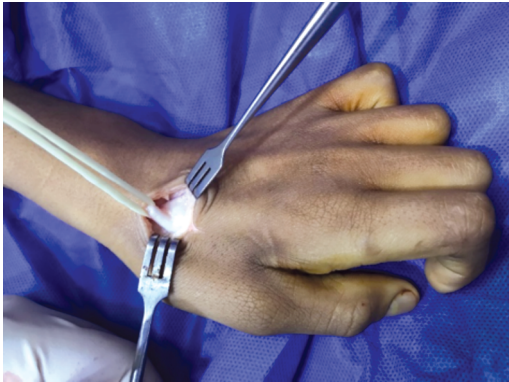


Fig. (3-A): At the end of the radius, a tiny vertical incision was made to cut the ECRL tendon.

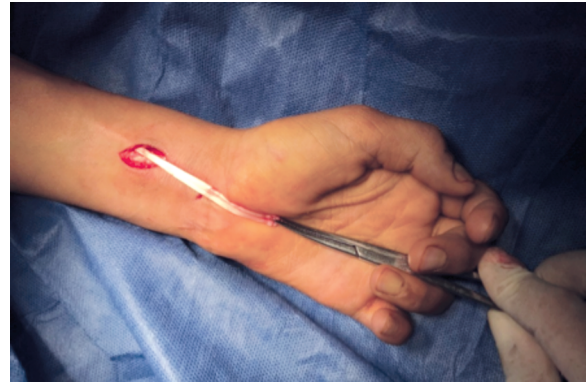


Fig. (3-B): A second vertical incision was made 5-6cm proximally to remove the ECRL tendon.

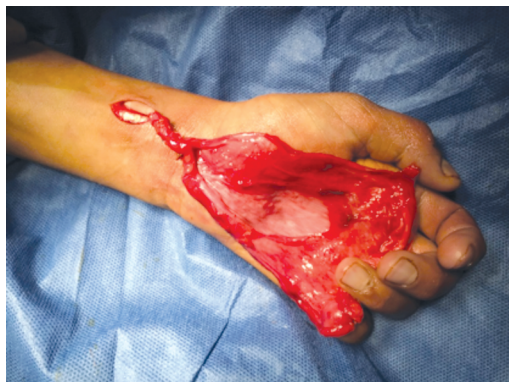

Fig. (3-C): The ECRL tendon was sutured to tendon grafts.

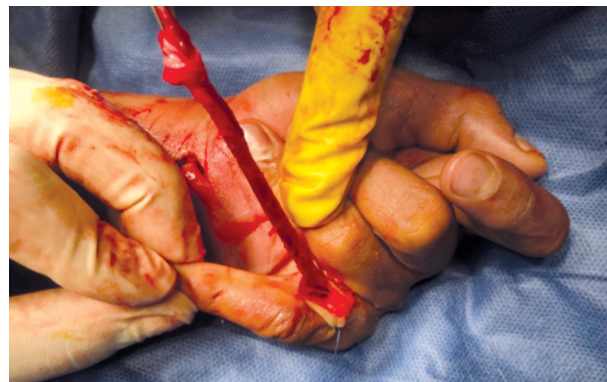

Fig. (3-D): The tendons were sewn into the side bands.

#### Study Measures:

A- Subjective assessment using HAT score.

B- Objective assessment at time intervals of 1, 3, 6, and 12 months after surgery:

a- Photographs were taken concentrating on the lateral view of the supinated hand to notice the claw deformity correction roughly as shown in Figs. (4,5). The following tips were considered:

- 1- The camera was set to take pictures of the highest possible quality.
- 2- A plain background was used, and distracting backgrounds were avoided.

3- The patient was positioned in a good light.

4- The camera was held steady to ensure the picture was focused and at the same distance from all patients.

b- Hand grip strength.

c- Range of motion of the PIP and MCP joints.

#### Statistical analysis:

This was done efficiently using the Statistical Package for the Social Sciences (SPSS) (Version 24.0, SPSS Inc., Chicago, IL, USA). A *p*-value of less than 5% indicated statistical significance.

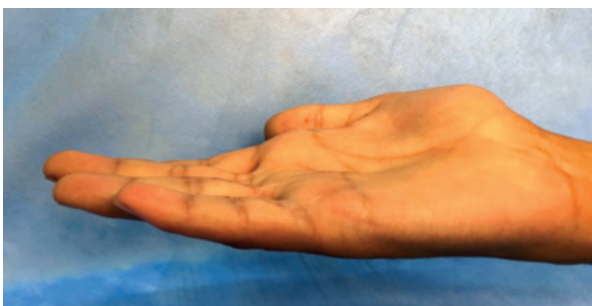

Fig. (4): Lateral view showing the correction of a right hand clawing 12 months post-operative using Zancolli lasso technique.

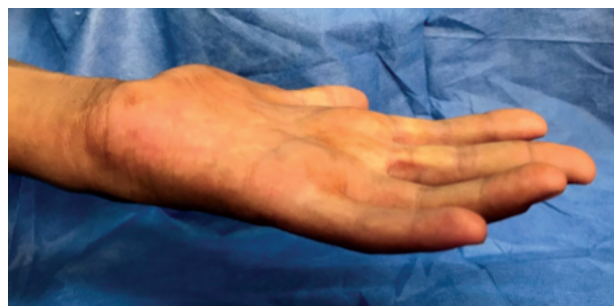

Fig. (5): Lateral view showing the correction of a left hand clawing 12 months post-operative using Brand technique.

**RESULTS**

The present study included 20 patients. Ten patients were operated on using the Zancolli Lasso technique and considered group A, whereas another 10 patients were operated on using Extensor Carpi Radialis longus tendon transfer and named group B.

**I- Demographic data of patients:**

The demographic data were recorded for all patients (Table 1). Neither group differed significantly in age, sex, smoking, work environment, or prevalence of dominant-hand injuries.

**II- Injury surgery interval:**

The range of injury surgery interval was (1.43-3) years with a mean ± SD was 2.09±0.58 for group A and 2.09±0.79 for group B (Table 2).

**III- Operative time:**

The operative time ranged from 50 to 70 minutes, with a mean ± SD was 58.30±6.55 for group A and from 96 to 120 minutes for group B, with a mean ± SD was 110.60±7.06 for group B. So, there was a statistical difference between the 2 groups (Table 2).

Table (1): Comparison between the two studied groups according to demographic data.

Demographic data	Group A (n=10)		Group B (n=10)		Test of sig.	p
	No.	%	No.	%		
<b>Sex:</b>						
Male	8	80.0	6	60.0	$\chi^2=0.952$	FE <sub>p=0.628</sub>
Female	2	20.0	4	40.0		
<b>Age (years):</b>						
Min. - Max.	13.0-42.0		17.0-55.0		$t=0.970$	0.345
Mean ± SD.	27.60±9.17		32.50±13.08			
Median (IQR)	27.50 (22.0-34.0)		30.50 (21.0-44.0)			
<b>Manual work:</b>						
No	6	60.0	4	40.0	$\chi^2=0.800$	0.371
Yes	4	40.0	6	60.0		
<b>Dominant hand:</b>						
No	4	40.0	5	50.0	0.202	1.000
Yes	6	60.0	5	50.0		

FE: Fisher Exact test. SD : Standard deviation.  
 $\chi^2$ : Chi-Square test. IQR: Inter Quartile Range.  
 $t$  : Student  $t$ -test. U : Mann Whitney test.  
 \* :  $p \leq 0.05$  is Statistically significant.

Table (2): Comparison between the two studied groups according to injury surgery interval and operative time.

Injury surgery interval (years)	Group A (n=10)	Group B (n=10)	$t$	$p$
Min. - Max.	1.43-3.0	1.0-3.86	0.023	0.982
Mean ± SD.	2.09±0.58	2.09±0.79		
Median (IQR)	2.0 (1.50-2.50)	2.0 (1.71-2.29)		
<b>Operative time:</b>				
Min. - Max.	50.0-70.0	96.0-120.0	17.176*	<0.001*
Mean ± SD.	58.30±6.55	110.60±7.06		
Median (IQR)	57.50 (54-64)	112.0 (108-115)		

$\chi^2$ : Chi-Square test. SD : Standard deviation.  
 FE: Fisher Exact test. IQR: Inter Quartile Range.  
 $t$  : Student  $t$ -test. U : Mann Whitney test.  
 \* : Statistical significance was noted when  $p \leq 0.05$ .  
 $p$ :  $p$ -value for comparing between the studied groups.

Table (3): Active range of motion of the medial 2-fingers.

	Group A (n=10)	Group B (n=10)	t	p
<i>Active range of motion of MCP joint of medial 2 fingers:</i>				
Flexion °				
Preoperative	38.30±8.79	38.70±7.30	0.111	0.913
Postoperative	84.20±5.67	82.80±7.30	0.479	0.638
p1	<0.001*	<0.001*		
Extension °				
Preoperative	29.80±9.07	24.40±8.03	1.410	0.176
Postoperative	11.20±1.48	12.30±1.77	1.511	0.148
p1	<0.001*	0.001*		
<i>Active range of motion of PIP joint of medial 2 fingers:</i>				
Flexion °				
Preoperative	84.20±5.67	82.80±7.30	0.479	0.638
Postoperative	72.90±6.76	75.0±6.77	0.694	0.496
p1				
Extension °				
Preoperative	11.20±1.48	12.30±1.77	1.511	0.148
Postoperative	7.0±2.58	6.70±2.0	0.290	0.775
p1	<0.001*	<0.001*		

FE: Fisher Exact test.  
 $\chi^2$ : Chi-Square test.

t: Student t-test.  
 \*: Statistical significance was noted when  $p \leq 0.05$ .

IV- Initial appearance of clinical signs of recovery:

By comparing the 2 groups, the time needed for clinical recovery for group A ranged from 3 to 6 months, while it was 3 to 8 months for group B. The statistically insignificant difference was illustrated in (Fig. 6).

IV- Study measures:

The patient reported outcomes exemplified in the HAT score. In contrast, objective assessment parameters included key hand grip strength, Resting position, and range of motion of both MCP and PIP joints.

1- HAT score:

Patients expressed more satisfaction with hand function when the score was lower. No significant

difference existed between the groups in terms of patient satisfaction (Fig. 7).

2- Handgrip:

Group A ranged from 20 to 25 preoperatively, which was improved to 26-31 postoperatively, while group B ranged from 21 to 25 preoperatively, markedly improved to 30-37 postoperatively, with statistical difference favoring group B (Fig. 8).

3- Total active range of motion:

Improvements in active MCP and PIP flexion and extension range of motion were not significantly different between groups as seen in Table (3).

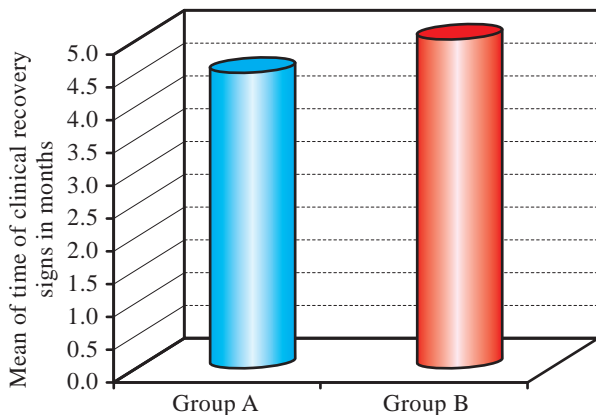


Fig. (6): Comparison between the two studied groups according to the time of clinical recovery signs.

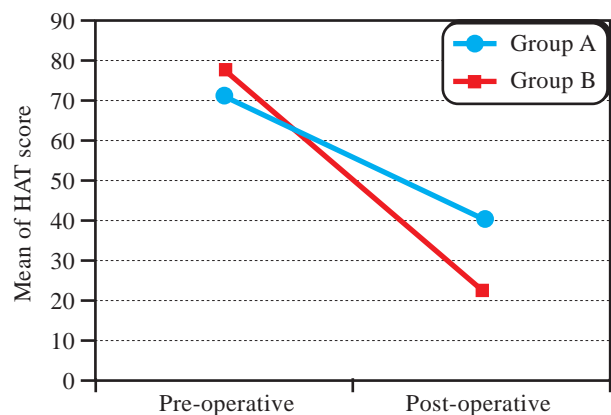


Fig. (7): The HAT scores were compared between the groups.

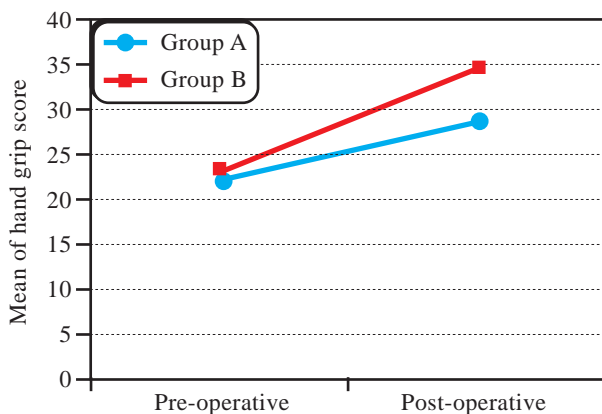


Fig. (8): Scores on the HAT were compared between the groups.

## DISCUSSION

Ulnar nerve palsy should be treated as early as possible to prevent severe repercussions that interfere with the patient's daily activities. Motor recovery of the distal hand muscles is generally rare after an injury to the ulnar nerve at or above the elbow. Only 20% of M4 or M5 outcomes are reported in most series at these levels. These subpar outcomes have led to more publications on nerve transfer than nerve graft or repair [12,13]. As a natural progression from nerve grafting and healing, nerve transfer provides an additional reconstructive option. However, after one year of failed reinnervation, the hand's nearly complete intrinsic muscle atrophy restricts this technique, and such poor patients have no hope for reinnervation [14]. Tendon transfers offer a solution in neglected cases of ulnar nerve injuries, providing active-controlled motion. Tendon transfers are performed to treat claw hands and improve hand function [3].

Before the advent of the nerve transfer notion, many authors desperately favored tendon transfer over nerve surgery in high ulnar nerve lacerations. T Ozkan et al., investigated the effectiveness of three tendon transfer procedures for treating permanent ulnar nerve paralysis with a mean paralysis time equal to 43 months for all groups combined. Results favored a rapid shift to tendon transfer techniques after 12 months, with a mean of 24 months [8].

Static techniques of tendon transfer, as palmar capsulodesis of the MCP joint, Riordan static tenodesis, Parkes static tenodesis or Fowler's wrist tenodesis, shorten the palmar capsules of the finger MCP joints or create "checkrein" ligament tenses to prevent hyperextension, just if passive flexion of their MCP joints leads to an extension of their PIP joints (the Bouvier maneuver) [15]. Unfortun-

nately, neither technique can restore the usual pattern of finger flexion. Furthermore, they may stretch out over time, causing the deformity to repeat [16].

Dynamic tendon transfer has always been an unparalleled surgical choice. The Zancolli lasso technique and Brand's ECRL transfer are the most popular anti-claw techniques. No previous clinical trial, to the best of our knowledge, compared between the two techniques. Most surgeons consider them as favorable techniques, as described by T Ozkan et al., [8] and MA Abd Elmoktader et al., [17].

This study compared the functional outcomes of the Zancolli lasso technique versus Brand's ECRL transfer in neglected cases of ulnar claw hand deformity. Twenty patients with ulnar claw hand deformity were enrolled in the study and assorted into 2 groups, A and B, 10 patients each. The Zancolli lasso tendon transfer technique managed group A patients, whereas Brand's ECRL transfer was executed as a management plan for group B patients. The patients were followed-up regularly over 12 months.

Patient selection criteria were strictly confined to isolated ulnar nerve palsy presented with hand clawing after one year or more from the initial time of injury who did not develop any clinical signs of nerve recovery. Demographic data included the patient characteristics: Age, sex, smoking, the incidence of injury to the dominant hand, and the prevalence of manual workers in both groups. The variety of demographic data enriched this thesis with no statistical significance between the 2 groups limiting the confounders.

Due to the possibility that ulnar nerve damage is a component of a more severe complicated injury, we excluded Flexor digitorum profundus palsy to the little and ring finger, any skeletal instability, Poor skin coverage, Joint stiffness and brachial plexus injury to make the 2 cohorts more coherent.

The mean operative time for group A was 58.3 minutes, whereas group B exhibited 110.6 minutes, with a statistical difference between the two techniques. This may explain the popularity of the Zancolli lasso among surgeons.

Based on the case series of V. Verma et al., (2022), the hand was cast-immobilized with the MCP joint 90° flexed, the IP joints extended, and the wrist 10°-20° flexed with some postoperative joint stiffness [18]. On the contrary, the joint complications were nil in the present study. This may

be attributed to using a splint instead of cast-immobilization.

Unlike Baltzer H. et al., [19], who used the Disabilities of the Arm, Shoulder, and Hand score (DASH score) to assess the hand function reported by the patient, we preferred the HAT score as the DASH score mainly assesses the shoulder and arm functions, whereas the HAT score concentrates on only hand functions. In this study, Group A ranged from 60 to 82 preoperatively, lowered to 33 to 49 postoperatively, while Group B ranged from 65 to 90 preoperatively and became 19-32 postoperatively. This reflects the patient's satisfaction with the ultimate statistically significant results tipping the scales toward group B.

In their 44 patients' study, T Ozkan et al., (2003) recorded 27 and 24 preoperative grip strength for the ZLP and ECRL groups, while postoperative results showed 31 and 28, respectively. They documented the lowest results for the ECRL group [8]. The present study's mean preoperative grip strength values for the ZLP and ECRL groups were 22 and 23, respectively, with superior postoperative results of 28 and 34. Unlike T Ozkan et al., whose injury surgery interval was 43 months, ours was the same for both groups, with an equal mean of 24 months [8]. Short injury-surgery interval may be a crucial contributing factor to the outcome of tendon transfer. Also, owing to the extra muscle added to the flexor/extensor equilibrium in the ECRL group, hand grip results were convincing and matched with the Diaz-Garcia RJ review [4].

The ZLP group saw a net increase in grip strength of 25% compared to preoperative values, whereas the ECRL group saw a net increase of 47%. A significant improvement in the range of motion was markedly witnessed and fortified with statistical results.

In 1992, J.W. Brandsma et al., demonstrated how the unregulated traction of the central slip during FDS harvesting could result in swan-neck deformity [20]. Accordingly, many patients had one digit with swan-neck malformation. This difference may be pertinent to the patients recruited in his study. Out of 127 patients with claw-hand deformity and loss of thumb opposition, only 15% suffered. Also, some of his patients represented complex injuries, including combined median and ulnar nerves.

#### Conclusion:

Based on the previous studies, ZLP and ECRL transfer were nearly considered the most common

techniques used for claw hand correction. Nevertheless, these studies enrolled different techniques for different injuries and did not shed light on the 2 most familiar techniques, putting them in one crucible.

This is the only randomized controlled trial we know that directly compares the two methods. Regardless of the surgical approach, all patients were equally allocated into 2 groups for a valid comparison as much as possible. The final evaluation of all patients was done during the 12<sup>th</sup> month of follow-up. Measures of the outcomes can be divided into 2 major categories: patient-reported outcomes and objective assessment methods.

Group A was operated at a shorter operative time when compared to Group B. The patient-reported outcomes, in other words, the HAT score, documented that group (B) patients notably reported lower disability.

Regarding the objective methods of assessment of hand grip strength, group (B) patients exhibited a higher mean hand grip strength which is statistically significant with a  $p$ -value  $<0.001$ . In contrast, the 2 groups showed no significant difference regarding the hand's resting position and the active ROM.

#### REFERENCES

- 1- McCormick C.A., Rath S., Patra P.N., Pereira J. and Wilkinson M.: A qualitative study of common functional problems experienced by people with complete ulnar nerve paralysis. *Lepr. Rev.*, 79 (2): 154-61, 2008.
- 2- Murovic J.A.: Upper-extremity peripheral nerve injuries: a Louisiana State University Health Sciences Center literature review comparing the operative outcomes of 1837 Louisiana State University Health Sciences Center median, radial and ulnar nerve lesions. *Neurosurgery*, Oct. 65 (4 Suppl): A11-7, 2009.
- 3- Lan C.Y., Tien H.Y., Lin Y. Te, Hsu C.C., Lin C.H. and Chen S.H.: Prognosis of Traumatic Ulnar Nerve Injuries: A Systematic Review. *Ann. Plast. Surg.*, 82 (1S Suppl 1): S45-52, 2019.
- 4- Diaz-Garcia R.J. and Chung K.C.: A Comprehensive Guide on Restoring Grasp Using Tendon Transfer Procedures for Ulnar Nerve Palsy. *Hand Clin.*, 32 (3): 361-8, 2016.
- 5- Gardenier J., Garg R. and Mudgal C.: Upper extremity tendon transfers: A brief review of history, common applications, and technical tips. *Indian Journal of Plastic Surgery*, 53 (2): 177-90, 2020.
- 6- Zancolli E.A.: Claw-Hand Caused by Paralysis of the Intrinsic Muscles. *J Bone Joint Surg.*, 39 (5): 1076-80.
- 7- Brand P.W.: Tendon Grafting Illustrated by a New Operation for Intrinsic Paralysis of the Fingers. *Journal of Bone and Joint Surgery-British Volume*, 444-53, 1961.



- 8- Özkan T., Özer K. and Gülgönen A.: Three tendon transfer methods in the reconstruction of ulnar nerve palsy. *Journal of Hand Surgery*, 28 (1): 35-43, 2003.
- 9- White D.J.: *The Hand*. In: Norkin C.C., White D.J., editors. *Measurement of Joint Motion: A Guide to Goniometry*, 5e. New York, NY: McGraw-Hill Education, 2016.
- 10- Rantanen T., Guralnik J.M., Sakari-rantala R., Simonsick E.M., Ling S. and Fried L.I.: Disability, Physical Activity, and Muscle Strength in Older Women: The Women's Health and Aging Study, 80 (February): 130-5, 1999.
- 11- Naidu S.H., Panchik D. and Chinchilli V.M.: Development and Validation of the Hand Assessment Tool. *Journal of Hand Therapy*, 22 (3): 250-7, 2009.
- 12- Vastamäki M., Kallio P.K. and Solonen K.A.: The results of secondary microsurgical repair of ulnar nerve injury. *J. Hand Surg. Br.*, Jun. 18 (3): 323-6, 1993.
- 13- Jaquet J.B., Luijsterburg A.J., Kalmijn S., Kuypers P.D., Hofman A. and Hovius S.E.: Median, ulnar, and combined median-ulnar nerve injuries: Functional outcome and return to productivity. *J. Trauma*, Oct. 51 (4): 687-92, 2001.
- 14- Domeshek L.F., Novak CB, Patterson J.M.M., Hasak J.M., Yee A., Kahn L.C., et al.: Nerve Transfers-A Paradigm Shift in the Reconstructive Ladder. *Plast. Reconstr. Surg. Glob Open*, Jun. 7 (6): e2290, 2019.
- 15- Gottschalk H.P. and Bindra R.R.: Late Reconstruction of Ulnar Nerve Palsy. *Orthopedic Clinics of North America*, 43 (4): 495-507, 2012.
- 16- Riordan D.C.: Tendon transfers in hand surgery. *Journal of Hand Surgery [Internet]*, 8 (5): 748-53. Available from: [http://dx.doi.org/10.1016/S0363-5023\(83\)80264-0](http://dx.doi.org/10.1016/S0363-5023(83)80264-0), 1983.
- 17- Abd Elmoktader M.A., Mekky M., Sholkamy K. and Nageh M.: Evaluation of Different Modalities of Tendon Transfer in Ulnar Nerve Palsy. *Egypt J. Hosp. Med.*, 75 (6): 3000-5, 2019.
- 18- Verma C.V., Bhosale K.S., Thatte M.R. and Sawant A.D.: Outcomes of Tendon Transfer Surgery for Correction of Ulnar Claw Hand: A Case Series. *J. Hand Surg. Glob. Online*, 1-8, 2022.
- 19- Baltzer H, Woo A., Oh C. and Moran S.L.: Comparison of Ulnar Intrinsic Function Following Supercharge End-to-Side Anterior Interosseous-to-Ulnar Motor Nerve Transfer. *Plast. Reconstr. Surg.*, Dec. 138 (6): 1264-72, 2016.
- 20- Brandsma J.W. and Ottenhoff-DE Jonge M.W.: Flexor Digitorum Superficialis Tendon Transfer for Intrinsic Replacement. *Journal of Hand Surgery*, 17 (6): 625-8, 1992.