

IMPACT OF HYPERBARIC OXYGEN THERAPY ON IGA LEVELS IN PATIENTS WITH MAXILLARY DEFECTS OF BENIGN ORIGIN RESTORED WITH PMMA PROSTHESIS (RANDOMIZED CLINICAL TRIAL)

Nancy Nader El-Sherbini* 

ABSTRACT

Aim: This study aimed to evaluate the effect of hyperbaric oxygen therapy sessions on the levels of IgA.

Materials and Methods: Eight patients were selected from the outpatient maxillofacial clinic with Class I acquired maxillary defects. The patients were randomly divided into two equal groups for whom will receive hyperbaric oxygen therapy. **Group I:** Patients with maxillary defects received hyperbaric oxygen therapy sessions. (HBOT) Prosthesis construction started 1 month after surgery. **Group II:** Patients with maxillary defect but didn't receive hyperbaric oxygen sessions. (NHBOT). Prosthesis construction 3 months after surgery. Conventionally processed and cured heat-cured PMMA obturators were constructed for both groups. For measuring IgA levels in saliva ELISA test was used. Saliva samples were collected immediately before the denture was delivered to the patient, one month and three months following insertion.

Results: For group HBOT, The mean values recorded for the Salivary IgA were 75.390 ± 12.699 , 80.100 ± 11.438 , and 81.650 ± 11.799 (mg/dL) immediately, after 1 month, and after 3 months respectively. Regarding group NHBOT, The mean values recorded for the Salivary IgA were 83.65 ± 11.739 , 93.55 ± 12.043 , and 95.05 ± 11.413 (mg/dL) immediately, after 1 month, and after 3 months respectively.

Conclusion: HBOT improved the tissue response to inflammatory conditions, however, the healing effects of hyperbaric oxygen therapy can last up to 12 months. If, and therefore when the maintenance phase of treatment is reached needed treatment one or two days per week may be required.

KEYWORDS: Acquired maxillary defects, Salivary IgA, ELISA test, Hyperbaric oxygen therapy.

* Associate Professor, Department of Prosthodontics, Faculty of Dentistry, Cairo University, Egypt

INTRODUCTION

Hyperbaric oxygen therapy (HBOT) is described as the exposure to 100% intermittent pure oxygen in a hyperbaric chamber above atmospheric pressure, hyperbaric oxygenation treatment (HBOT) has been utilized for medicinal purposes for more than five decades.¹ Due to the onset of different metabolic events at the tissue level, its mode of action is characterized by hyperoxia and the formation of reactive oxygen molecules.¹ According to clinical recommendations patients breathe almost entirely oxygen during sessions that span 60 to 120 minutes, three to four times per week. Additionally, this therapy makes it simple to move oxygen to the body's tissues. The chamber's increased pressure raises the blood's oxygen content. So, it promotes the healing of wounds and therefore decreases the recovery time for patients.² Hyperbaric oxygen has been described as "a therapy in search of diseases."^{2,3} Hyperbaric oxygen therapy (HBOT) is a sort of treatment used to hasten the recovery of infections where tissues are oxygen-starved, gangrene, wounds that won't heal, and carbon monoxide poisoning. By supplying oxygen-rich plasma to tissues deficient in oxygen. Damage to the body's blood vessels from wounds results in the discharge of fluid, which seeps into the tissues and causes swelling. As a result of the swelling depriving the injured cells of oxygen, tissue begins to deteriorate.⁴ While oxygenating the tissues, HBOT lowers edema. With HBOT, the vicious cycle of swelling, oxygen deprivation, and tissue death is broken. **HBOT prevents "reperfusion injury.** "When the blood supply is restored to the tissues after they have been depleted of oxygen, serious tissue damage takes place. For example, when a crush injury interrupts blood flow, a chain of events inside the damaged cells causes the generation of dangerous oxygen radicals. These chemicals have the potential to permanently harm tissues.⁵ They stop blood flow by causing the blood vessels to constrict. HBOT is also used in plastic, aesthetic, and reconstructive surgery, for the management of compromised skin grafts, flaps, and thermal burns.^{6,7}

Secretory IgA, an immunoglobulin generated by plasma cells in connective tissues and transported by the duct cells of the major and minor salivary glands, is the biggest immunologic component of saliva. IgA functions as an antibody to bacterial antigens neutralizes viruses on mucosal surfaces, and aggregates or clumps bacteria to prevent their attachment to host tissues.⁴ Submandibular, sublingual, and parotid salivary glands generate salivary immunoglobulin A (sIgA). Compared to the parotid, the submandibular and sublingual glands secrete more sIgA. The autonomic nervous system regulates these glands in distinct ways.⁴ IgA that is not linked to antigens, or free IgA, has an anti-inflammatory effect. This is beneficial for a body part that comes into contact with substances that can cause an excessive inflammatory reaction.^{5,6} The hallmark of mucosal immunity has been described as secretory immunoglobulin A (SIgA). It is the most significant humoral immunity mediator in mucosal tissues. It has a brief half-life, which is three to six days. It makes up more than 80% of all antibodies made by human lymphoid tissues linked with mucosa. Particularly in the upper respiratory tract, sIgA predominates.^{7,8}

Serum IgA changes indicate mucosal inflammation anywhere in the gastrointestinal tract, but sIgA changes indicate mouth cavity involvement.⁹

For removable complete and partial prostheses, PMMA continues to be the material of choice. PMMA materials are widely used because of their accessibility, affordability, and reliance on basic processing tools. Despite global improvements in dental training, materials, and practices, the fracture, unpleasant odour, and allergy to PMMA could not be avoided.¹⁰

Therefore this study was conducted to study the impact of hyperbaric oxygen therapy on the immunological reaction of tissues supporting maxillary obturator constructed from conventional PMMA (polymethyl methacrylate).

MATERIALS AND METHODS

Eight patients were selected from the outpatient maxillofacial clinic, Prosthodontic Department, Faculty of Dentistry, Cairo University.

Inclusion criteria:

- Class I acquired maxillary defects.
- Age range (40-55).
- Non-smokers.
- Controlled health condition as diabetes or hypertension.
- All patients with acquired defects due to benign neoplasms.

Exclusion criteria:

- Based on detailed medical history and medical reports; Patients with medical conditions involving the respiratory system, Claustrophobia, Eustachian tube dysfunction, pregnancy, seizures, and high fever which contraindicate HBOT.
- Patients with defects of malignant origin.
- Patients refused to be involved in the study.

Patients were informed about the nature of the study and allowed to sign a written consent.

The patients were randomly divided into two equal groups for whom will receive hyperbaric oxygen therapy.

Group I: Patients with maxillary defects received hyperbaric oxygen therapy sessions. (HBOT).

Group II: Patients with maxillary defect but didn't receive hyperbaric oxygen sessions. (NHBOT).

Hyperbaric oxygen therapy:

Group I; Received a protocol of five sessions of hyperbaric oxygen therapy (HBOT), for 60 minutes at 2.5 ATA once a day for five sequential days 1 week after surgery.^{11,12} Prosthesis construction started 1 month after surgery.

For group II; Prosthesis construction started 3 months after surgery.

Prosthesis construction:

Maxillary and mandibular preliminary impressions were made after blocking the undercut area for the maxillary defect with vaselinated gauze to avoid the escape of the impression material into the defect. The custom tray was constructed using cold-cure acrylic resin. Border molding of the defect side was done and final impressions with Elastomeric Impression Materials Polyvinyl Siloxane (PVS) (Aquasil Soft Putty/Regular Set. Manufacturer DENSPLY DETREY GmbH, 78467Konstanz. GERMANY) were made and poured with type III dental stone to produce the master casts. Occlusion blocks were constructed conventionally. A maxillary face bow record was made to mount the upper cast on a semi-adjustable articulator, the mandibular cast was mounted according to a centric relation record obtained from the patient using the check bite technique. Setting up of acrylic resin teeth (non-anatomical cross linked). Try in of the waxed obturator was done and patients' approval was obtained. The waxed obturator was then conventionally processed using heat-cured PMMA. Laboratory remounting was done after processing to refine occlusion before insertion in the patient's mouth. The finished dentures were adjusted for extension, retention, and stability and occlusal refinement was made. Clinical remounting of the dentures was done to refine occlusion.

Finished and polished obturators were delivered to the patients, with restrictions on oral hygiene measures.

Obtaining saliva samples:

Saliva samples were collected immediately before the denture was delivered to the patient, one month and three months following insertion. The patient was instructed not to eat anything before saliva samples collection and the samples were collected at 10 a.m in a sterile special graduated

tube and placed in an ice box until finally stored in a deep freezer at (-20C°) till time of analysis. Levels of salivary IgA were detected using the ELISA test (ELISA kit, Mabtech, USA).

Day 1: ELISA plate was coated with MT57 antibody (monoclonal antibody) (diluted to 2µg/ml in PBS (phosphate buffered saline); pH 7.4) by adding 100µl/well then was incubated overnight at 4-8°C. **Day 2:** The plate was washed twice with PBS (200µl/well). Then blocked by adding 200µl/well of PBS with 0.05% Tween 20(PBS-Tween) (detergent) containing 0.1% BSA (incubation buffer), incubated for 1 hour at room temperature. Then washed five times with PBS-Tween. Human IgA standard was prepared by reconstructing the contents of a standard vial in 500µl of PBS to make

up a stock solution of 50µg/ml. The stock solution was used immediately. 100µl/well of samples diluted in incubation buffer was used for the test and incubated for 2 hours at room temperature. The plate was then washed again. 100µl/well of MT20-ALP (anti-human IgA monoclonal antibody alkaline phosphatase-conjugated antibodies) diluted 1:1000 in incubation buffer were added and incubated for 1 hour at room temperature. The plate was washed again 100/well of substrate solution-nitrophenyl-phosphate pNpp. were added. The optical density was measured using an ELISA reader.

Two way ANOVA test was used and the Tukey-Kramer Multiple Comparisons test was used to investigate significant differences among the groups.

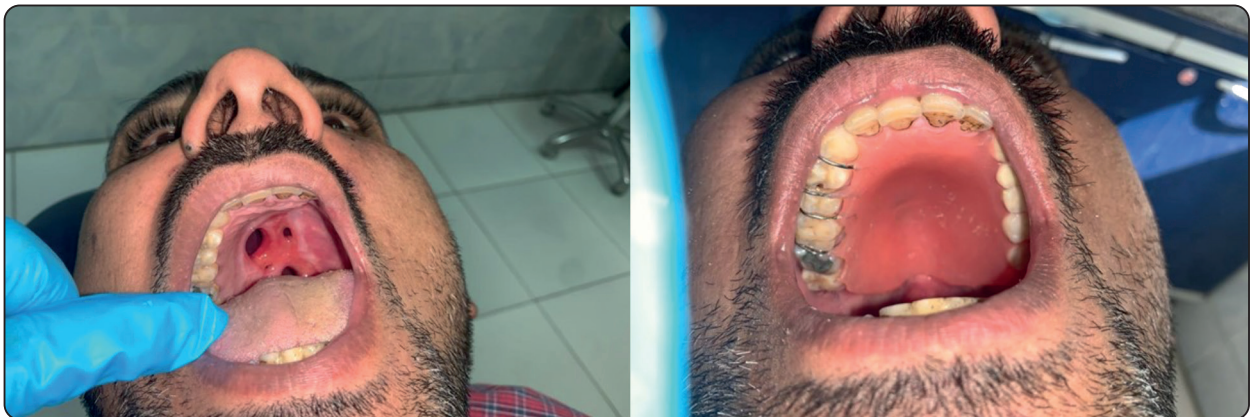

Fig. (1) Hemi-maxillectomy defect and prosthesis in place



Fig. (2) ELISA Kit for human IgA and its reader

RESULTS

For group HBOT, The mean values recorded for the Salivary IgA were 75.390±12.699, 80.100±11.438, and 81.650±11.799 (mg/dL) immediately, after 1 month, and after 3 months respectively.

Regarding group NHBOT, The mean values recorded for the Salivary IgA were 83.65±11.739, 93.55±12.043, and 95.05±11.413 (mg/dL) immediately, after 1 month, and after 3 months respectively.

TABLE (1) Mean Salivary IgA (mg/dL) for both groups along the follow-up period.

Follow up	Group I (HBOT)	Group II (NHBOT)	P value
Immediately	75.39±12.699	83.65±11.739	0.3244
1 month	80.1±11.438	93.55±12.043	0.0380*
3 months	81.65±11.799	95.05±11.413	0.0367*
p value	0.487	0.0690	

Effect of Time on Salivary IgA:

No significant change was found over time in both groups for IgA levels (P=0.487 for group I and P= 0.069 for group II)

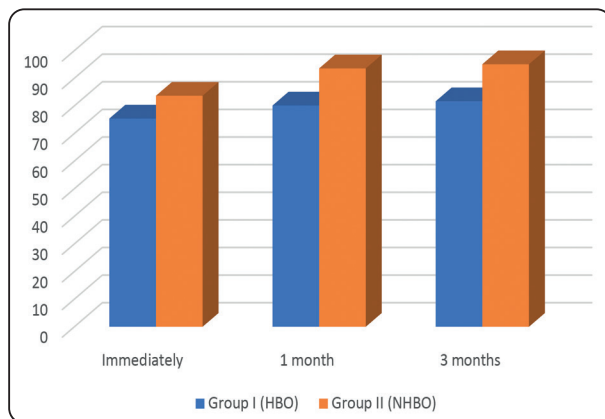


Fig. (3) Bar chart showing the IgA levels of both groups over the whole period.

Effect of HBO therapy (IgA)

Immediately, There was no significant difference between both groups P=0.3244

However, after 1 month, Group HBOT showed significantly lower levels than Group NHBOT (P=0.0380). The same findings were recorded after 3 months, Group HBOT showed significantly lower levels than Group NHBOT (P=0.0367)

DISCUSSION

The immune system relies heavily on salivary immunoglobulin A (slgA), particularly when it comes to the host defense in mucosal locations. It serves as a barrier to stop antigens from sticking to the mucosal epithelium’s surface and promotes the neutralization of microorganisms at the mucosal locations.^{13,14} It can neutralize bacteria intracellularly, mediate antibody-dependent cell cytotoxicity (ADCC), and transfer through epithelial tissue. It works in saliva and other exogenous secretions, and when moving across the epithelium, it exerts its antimicrobial capabilities within the epithelial cell. IgA that is not linked to any antigens, or free IgA, possesses anti-inflammatory properties.¹⁵ This is helpful in a region of the body where there are many substances that can cause an exaggerated inflammatory response.¹⁵ Salivary immunoglobulin A (slgA) has a variety of characteristics, some of which are anti-inflammatory because they may prevent tissue damage brought on by an excessive inflammatory response.¹⁶

In the studied groups I and II patients the levels of IgA µg/l were within the normal range which was reported to be 50-480 µg/l in all samples obtained.

One month after delivery there was a mild increase in the level of IgA although still within the normal range it was attributed to the presence of an intraoral appliance which may have resulted in the alteration of oral microflora due to change in the ecological environment of the mucosa covered by the denture.

At the third interval, the concentration again showed a mild increase in IgA this was attributed to that the minor salivary glands could no longer become stimulated and became used to the presence of the prosthesis in the oral cavity.

In HBOT therapy (group I) the changes in the level of IgA were although still mild increase one month after insertion but were less than the amount of increase for NHBOT (group II) this was attributed to HBO therapy that enhances the oxygenation, decreases the edema and modifies the healing and immune responses. In conclusion, HBOT's increase in dissolved oxygen has the potential to change how tissues react to disease and damage. HBOT promotes lesion healing by boosting fibroblast activity, angiogenesis, and leukocyte function.¹⁷⁻¹⁹.

HBOT can counteract the poisons produced by specific bacteria. Additionally, it increases the oxygen saturation level in the tissue. This allows them to protect themselves from infections. The medication also improves white blood cells' ability to spot and get rid of invaders.²⁰⁻²³ Collagen and new skin cells are encouraged to grow by HBOT. By encouraging the growth of new blood vessels, it achieves this. Additionally, it promotes the cell's creation of particular substances like vascular endothelial growth factors. Endothelial cells, which are crucial for healing, are drawn to and stimulated by these.²⁴

Therefore it could have a promising future in the dental field to be served topically for treating many challenging cases, such as non-healing ulcers, peri-implantitis, dry sockets, osteochemonecrosis, and increased success rate of healing in heavy smokers and uncontrolled diabetics. So due to these reasons stated above the NHBOT group showed higher levels compared to the HBOT.

CONCLUSION

Within the limitations of this study it was concluded that:

HBOT improved the tissue response to inflammatory conditions, however, the healing effects of

hyperbaric oxygen therapy can last up to 12 months. If, and therefore when the maintenance phase of treatment is reached needed treatment one or two days per week may be required

Clinical trials with a greater number of patients and longer follow-up periods are recommended.

REFERENCES

1. Cannellotto, M.; Romero-Feris, D.; Pascuccio, M.M.; Jordá-Vargas, L. Aplicaciones Médicas de Las Cámaras de Oxigenación Hiperbárica de Nueva Generación/Medical Applications of New Generation Hyperbaric Oxygenation Chambers. *Rev. Asoc. Médica Argent.* 2018;131:12-20.
2. Weaver LK, Hopkins RO, Chan KJ, Churchill S, Elliott CG, Clemmer TP, Orme JF Jr, Thomas FO, Morris AH. Hyperbaric oxygen for acute carbon monoxide poisoning. *N Engl J Med.* 2002; 347:1057–1067.
3. Gabb G, Robin ED. Hyperbaric oxygen: a therapy in search of diseases. *Chest* 1987;92:1074-82
4. Myers RAM. Hyperbaric oxygen therapy for trauma: crush injury, compartment syndrome, and other acute traumatic peripheral ischaemias. *Int Anesthesiol Clin* 2000; 38: 139–151.
5. Bassetto, F.; Bosco, G.; Kohlscheen, E.; Tocco Tussardi, I.; Vindigni, V.; Tiengo, C. Hyperbaric Oxygen Therapy in Plastic Surgery Practice: Case Series and Literature Overview. *Il G. Chir.* 2019;40:257–275.
6. Marx RE. Radiation injury to tissue. In: Kindwall EP, ed. *Hyperbaric medicine practice.* Flagstaff, Ariz.: Best, 1994:447-503
7. Kaye D. Effect of hyperbaric oxygen on Clostridia in vitro and in vivo. *Proc Soc Exp Biol Med* 1967; 124:360–366.
8. Clow A., Lambert S., Evans P., Hucklebridge F., and Higuichi Kan investigation into asymmetrical cortical regulation of salivary sIgA in conscious man using trans-cranial magnetic stimulation. *Int. J. Psycho Physiology.* 2003; 47:57-64.
9. Miletic I.D., Schiffman S.S., Miltec V.D., and Sattely-Miller E.A.: Salivary IgA secretion rate in young and elderly persons. *J. Physiology and Behavior.* 1996; 60:24-29
10. Cortesy B. and Spertini F. secretory immunoglobulin A: from mucosal protection to vaccine development. *J Biol. Chem.* 1999; 380:1251-62.

11. Diebel L.N., Liberati D.M., Diglio C.A., and Brown W.J.: immunoglobulin A modulates inflammatory responses in an in vitro model of pneumonia. *J. Trauma.* 2005; 59: 1009-1106.
12. Edgar M, Dawes C, O'Mullane D` (2004): *Saliva and oral health.* 3rd ed. London: BDJ Books;
13. Savage N.W., Barnad K., Shirlaw P., Rahman D., Mistry M., Escudier M.P., Sanderson J.D., Challacombe S.J: serum and salivary IgA antibody responses to *Saccharomyces cerevisiae*, *Candida albicans* and *Streptococcus mutans* in orofacial granulomatosis and Crohn's disease. *Clin.Exp. Immun J.* 2004; 135:483-489.
14. Anusavice KJ, (2003): *Phillips' science of dental materials.* 11th ed. St. Louis: W.B. Saunders.
15. Sahar KH. Abdel-Bary, Usama A.M El Dakrory. Effect of hyperbaric oxygen therapy on the osseointegration around implants after mandibular reconstruction by distraction osteogenesis. *Egyptian dental journal.*2020; 66, 495:505
16. Eid HS, El Sayed W. The effect of hyperbaric oxygen therapy on improving bony stability in LeFort I maxillary advancement. *UHM* 2011; 38: 215-224.
17. Costalonga M, Herzberg MC. The oral microbiome and the immunobiology of periodontal disease and caries. *Immunol Lett.* 2014;162:22–38.
18. Miletic I.D., Schiffman S.S., Miltec V.D., and Sattely-Miller E.A. Salivary IgA secretion rate in young and elderly persons. *J. Physiology and Behavior.* 1996; 60:24-29
19. Madar R, Straka S, Baska T.: Detection of antibodies in saliva an effective auxiliary method in surveillance of infectious diseases. *Bratisl Lek Listy* 2002; 103: 38-41
20. Ladizinsky D, R David. New insights into oxygen therapy for wound healing. *Wounds.* 2010; 22:294–300
21. Marcarelli M, Trovato L, Novarese E, Riccio M, Graziano A. Rigenera protocol in the treatment of surgical wound dehiscence. *Int Wound J.* 2017; 14:277–281.
22. Thom SR. Hyperbaric oxygen: its mechanisms and efficacy. *Plast Reconstr Surg.* 2011; 127:131S–141S.
23. Re, K.; Patel, S.; Gandhi, J.; Suh, Y.; Reid, I.; Joshi, G.; Smith, N.L.; Khan, S.A. Clinical utility of hyperbaric oxygen therapy in dentistry. *Med. Gas. Res.* 2019; 9: 93–100
24. Dequanter D, Jacobs D, Shahla M, Paulus P, Aubert C, Lothaire P. The effect of hyperbaric oxygen therapy on treatment of wound complications after oral, pharyngeal and laryngeal salvage surgery. *Undersea Hyperb Med.* 2013; 40:381–385.