



## COMPARISON BETWEEN CONE BEAM CT AND TMJ DIGITAL TRACING TO RECORD THE BENNETT ANGLE AND THEIR EFFECT ON THE OCCLUSION OF COMPLETE DENTURE

Sara Medhat <sup>1</sup>, Maie Mohammed Shaker ElGhannam <sup>1\*</sup>

### ABSTRACT

**Objective:** The objective of this study was to compare and evaluate the efficacy of cone beam CT and TMJ digital tracing in determining the Bennett angle, as well as their effect on the complete denture occlusion. **Subjects and methods:** A sample of ten edentulous individuals were chosen, with an average age of 55 years. Every patient was provided with a complete denture, and the setting of artificial teeth was executed based on the principle of bilateral balanced occlusion. Then, the Bennett's angle was measured while the patient was in the lateral right and left movements by TMJ digital tracing (ARCUS digma II) and cone beam CT. These values of Bennett angles from different methods were applied to the semi-adjustable articulator to evaluate the balanced occlusion. **Results:** The values of Bennett angle on right and left sides, which were recorded by TMJ digital tracing (ARCUS digma II), and cone beam CT showed no significant differences ( $P > 0.05$ ) using paired t-test (at 95% confidence interval). TMJ digital tracing method records the mandibular movement in real time of patient movement by the electronic sensors also, the cone beam CT has 3D image in real-time, but it does not make any difference in the clinical performance of the balanced occlusion of complete denture. Bennett's angle was approximately similar to the two methods. **Conclusion:** Within the limitations in the current study, no significant difference between TMJ digital tracing (ARCUS digmaII) and cone beam CT in the recording of Bennett angle, and there is no significant difference between their effect on balanced occlusion.

**KEYWORDS;** Bennett angle, Arcus digma, CT, Occlusion.

### INTRODUCTION

Prosthetic rehabilitation relies heavily on restoring what has been lost, and every attempt is made to restore natural function. Successful treatment depends not only on accurate findings but also on the exact replication and recording of these findings. Research on the condylar mechanism and endeavors to record mandibular movement can be traced back to the latter part of the 18th century. The objective of conducting a movement recording is to replicate the occlusion and mandibular pattern of

movement of the patient with utmost precision in the articulator<sup>(1)</sup>.

The Bennett angle relates to the initiation and termination of condylar displacement or motion and is defined by the anatomical structure of the medial wall of the glenoid cavity. It is practical to transmit data from a mean articulator through the quantification of angular displacement in degrees. The accuracy of lateral condyle guidance in the fabrication of complete dentures can have a significant impact on the fit and function of the denture <sup>(2)</sup>.

---

1. Lecturer, Removable Prosthodontic Department, MTI University, Cairo, Egypt

• **Corresponding author:** maieshaker@gmail.com

The lateral movement of the mandible is commonly referred to as the chewing motion. The act of mastication is responsible for the mechanical breakdown of food during eating. The studies divided it into two distinct aspects, namely the working and balancing sides. The condyle that undergoes downward, anterior, and medial movement is commonly known as the balanced side. The side that moves laterally is known as the working side<sup>(3)</sup>.

An accurate registration of condylar guidance and its transfer to a semi-adjustable articulator is important during complete denture construction. It is intended to simulate the mandibular positions or movements of the patient within the normal range of the functional contact of the teeth. Thus, the condylar guidance of the articulator must be adjusted to approximate the condylar elements factors within the temporomandibular joint<sup>(4,5)</sup>.

Radiographic approaches are better for condylar guidance because they use stable bone markers and are not affected by the operator or patient neuromuscular control<sup>(6)</sup>. Recent studies in cone beam computed tomography (CBCT) have made prosthetics more precise, safer, and less expensive, leading to their extensive application<sup>(7)</sup>. CBCT is a cutting-edge technology that provides multiplanar segments in three dimensions without superimposition. However, CBCT exposes the patient to ionizing radiation, making it necessary to weigh the benefits against the potential risks<sup>(8)</sup>.

To overcome such limitations, TMJ Digital Tracing (ARCUS digmaII) system with an electronic ultrasonic sensor capable of registering and analyzing mandibular movement in three dimensions to obtain condylar guidance on a computer system monitor<sup>(9)</sup>. The mandibular movement can be displayed in real-time on the monitor, and the condylar guidance can be identified. This method is quick and non-invasive, making it a suitable choice in many dental clinics<sup>(10,11)</sup>.

## SUBJECTS AND METHODS

The design of the clinical research was conducted on ten patients who were completely edentulous. Participants were chosen if their ridges were covered with firm, dense, and compressible mucosa devoid of any TMJ disorder symptoms. Exclusion criteria included mandibular movement or limited mouth opening, mandibular deviation, and muscle spasm or tenderness.

All patients consented to this dental treatment, were informed about the study's procedures, and signed a written consent form with the approval of the Research Ethics Committee (REC) with code REC-CL-23-01. The patient's medical and dental history and extraoral and intraoral clinical examination were recorded.

### The denture construction:

For all patients, a primary and final impression of the upper and lower ridges was taken using a conventional technique to create the final cast. For the upper and lower trial denture bases, auto-polymerizing acrylic resin and modeling wax were used. The face-bow record was established with a Hanau spring bow. The maxillary cast was mounted to the (Hanu 96 H2) semi-adjustable articulator Whip Mix, USA. A wax interocclusal record was used to record the centric relation. Mounting the mandibular cast; attach the lower cast to the lower part of the articulator using plaster of Paris and centric relation record wax. Centric relation registration wax was removed from the lower record block and placed in cool water.

The setting of teeth utilized semi-anatomical teeth. Teeth were properly aligned to balanced occlusion. The denture was waxed up and the denture was tried in. The plaster index for the upper trial denture was made on the articulator, and the trial dentures were processed into the heat-cured acrylic resin.

Using a plaster index, clinical remounting for occlusal adjustment of the completed denture was performed to eliminate any occlusal disharmony.

### **Complete denture duplication:**

For each patient, complete dentures were duplicated by the conventional method for experimental work. Lateral condylar angles were recorded by using two modalities.

All patients were divided into two groups of 5 patients in each. In the first group, the patients were asked to wear experimental dentures to record right and left lateral angles by using arcus digma II. While the right and left lateral angles were recorded in the second group by using cone beam CT.

After recording the lateral angles, the patients in the first group were asked to wear a denture to record the right and left lateral angles by using cone beam CT. While the right and left lateral angles were recorded in the second group by using arcus digma II.

#### **a) TMJ digital tracing (ARCUS digma II) is shown in (Fig.1.a).**

Preparing phase After blocking off all undercuts with stone to create the cast, lower denture was poured. The lower denture was placed on the cast. the mandibular clutch was modified with light-cured acrylic resin to fit on the lower denture. A festoon shape was created by molding the light cure on the cervical area of the teeth. After shaping, a side bench light cure device cured the acrylic. To prevent any movement between the clutch and denture, compound material was used to further fixate the clutch to the lower denture with light cure acrylic resin. The patient's head was immobilized using the ARCUS Sevo face bow attached to the patient's ear plug.

Patient was asked to wear the connection unit on his neck to transmit the electronic waves of mandibular motion to the ARCUS digma II basic unit. The information was inserted on the initial page of the ARCUS digma II basic unit while working on it (date, doctor name, and patient name). The screen

was checked through all sensors were connected by the green light for each sensor. The "Measuring programs" window was opened, the measuring option was chosen to calculate the angle, articulator, protar articulator, and arbitrary axis.

The axis was shown on the monitor as a comment for the pointer attached to the lower bow to determine the arbitrary site of the left and right condyle and the infraorbital notch.

The patient was asked to slide the mandible in maximum lateral motion right and left motion. The patient was instructed to begin, and by pressing the foot control, the device started recording and tracing the movement. The patient was asked to repeat this movement three times and the device took the average to give the right and left lateral condylar guidance angle which is reported by the device to the final report as shown in the graph of movement and value of angles. (Fig.1.b)

#### **b- Cone Beam Computerized Tomography (CBCT) scanning method:**

The study employed the utilization of the CBCT CRANEX 3Dx apparatus. Two images were captured per patient, one in the centric position and another in the lateral right orientation. The patient was placed in an upright position on the apparatus, and the visual field was aligned with the aid of laser lines. Subsequently, the patient was instructed to achieve centric occlusion by closing his teeth in centric position, followed by performing a lateral right movement of the mandible. The digital delineation of the outline of condyles in both centric and lateral right positions resulted in the creation of three-dimensional images. Three-dimensional superimposition of images was performed. Frankfort line extends from the external auditory meatus's highest point to the deepest point of the inferior orbital rim. The lateral condylar path was derived by drawing a tangent line to the condyles during maximum intercuspation and in the lateral right position.

The angle between two tangent lines was measured. This procedure was made twice for each balancing condyle of the same patient and the mean angle was obtained and tabulated. Then the angles were measured again by the same method on the left side. The measured angles tabulated for each patient were then applied on the articulators to record the balanced occlusion. (Fig .1.c)

**The effect of Bennett angle records on balanced occlusion**

In order to achieve symmetrical occlusal contact at the premolar and molar regions during centric relation and to eliminate any interference during protrusive and lateral relations, duplicate dentures and occlusal adjustments were made. The articulator was centrally locked. For both the maxillary

and mandibular dentures, the second molars were removed. One-centimeter square metal plates covered with graphic paper were placed in the lower second molar positions. In place of the maxillary second teeth, metal tubes with internal diameters of 0.44 mm were luted using auto-polymerizing acrylic resin.

The articulator was adjusted in a posterior and lateral direction towards the working side until the upper and lower buccal cusps were aligned, after which the centric lock was locked. An indelible pencil was used to create a mark on the incisal table with the intention of determining the precise position of the incisal pin at the cusp-to-cusp position. This mark is utilized to adjust the amount of lateral displacement in subsequent recordings and measurements.

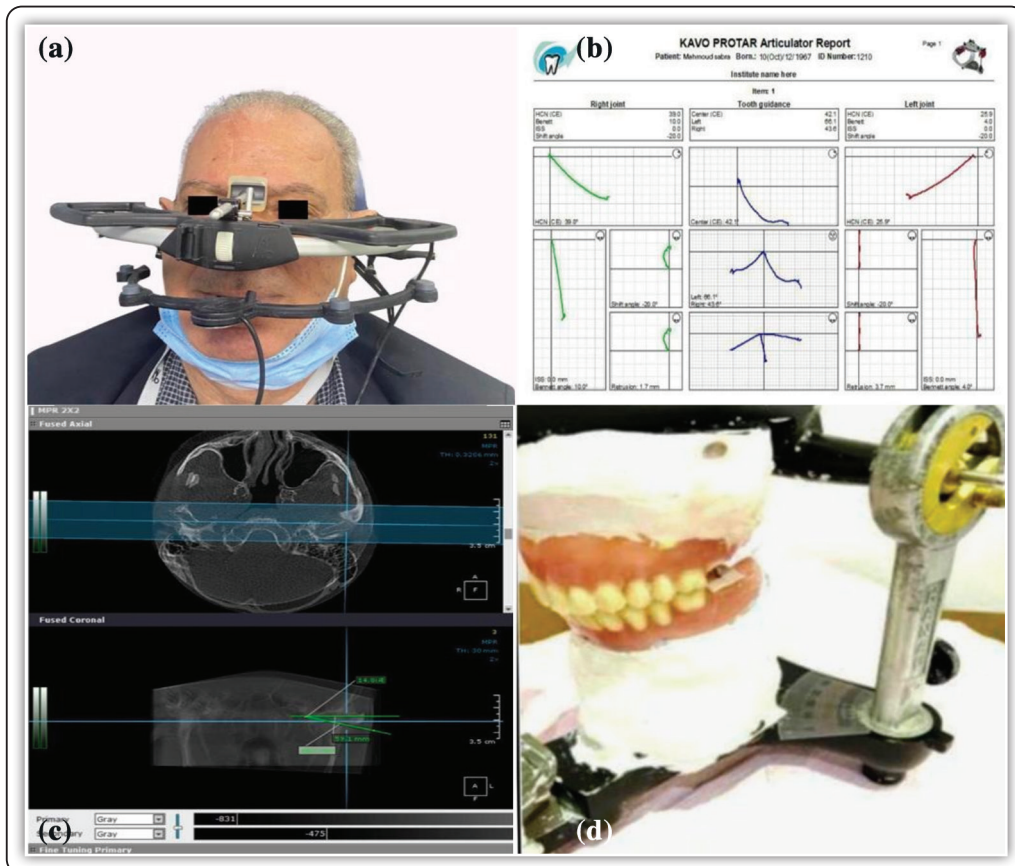


FIG (1) (a): Arcus digma II. (b): Report of arcus digma II. (c): Cone beam CT. (d): Measure of balanced occlusion

The lines that were perpendicular to each other were drawn in the mesiodistal and buccolingual orientations, traversing through the midpoint of the recording paper. Following each adjustment of the lateral condylar guidance, a metal needle with a pointed end measuring 0.22 mm was introduced into the metal tube located in the maxillary second molar on the right side in a downward direction until it made an indentation on the recording paper situated on the plate in the lower second molar region.

Measurements were taken using a digital caliper to determine the distance between each indentation and the mesiodistal and buccolingual lines, as well as the direct distance between each indentation and the intersection of the mesiodistal and buccolingual perpendicular lines. These measurements were subsequently recorded. The buccolingual distance measurements were deemed +ve if the indentation was located towards the buccal aspect of the mesiodistal line, and -ve if it was towards the lingual aspect. The mesiodistal distance measurements were deemed +ve when the indentation was located mesial to the buccolingual line and -ve when it was situated distal to it. The identical protocols for recording and measuring were applied to the left side.

All data were collected to compare the two methods and evaluate their effects on balanced occlusion. (Fig .1. d)

**RESULTS**

Numerical data were presented as mean and standard deviation (SD) values. Shapiro-Wilk’s test was used to test for normality. Data were normally distributed and were analyzed using paired t-test. The significance level was set at  $p < 0.05$  within all tests. Statistical analysis was performed with R statistical analysis software version 4.1.3 for Windows.

**TABLE (1)** Intergroup comparisons of Bennett angle

Side	Bennet angles (Mean±SD)		t-value	p-value
	Arcus digma	CBCT		
<b>Right</b>	12.63±5.96	14.72±3.17	<b>0.79</b>	<b>0.414</b>
<b>Left</b>	7.33±3.44	10.84±1.55	<b>5.19</b>	<b>0.072</b>

\*Significant ( $p < 0.05$ )

**TABLE (2)** Intergroup comparisons of Bennet angle record and their effect on occlusion.

Side	Measurement	Bennet angle records (Mean±SD)		t-value	p-value
		Arcus digma	CBCT		
<b>Right</b>	<b>MD</b>	2.36±0.16	1.71±0.53	<b>10.03</b>	<b>0.025*</b>
	<b>BL</b>	1.69±0.39	1.48±0.61	<b>0.70</b>	<b>0.441</b>
	<b>Direct</b>	2.59±0.36	2.31±0.32	<b>2.05</b>	<b>0.212</b>
<b>Left</b>	<b>MD</b>	2.46±0.18	1.90±0.12	<b>38.87</b>	<b>0.002*</b>
	<b>BL</b>	1.63±0.07	1.55±0.52	<b>0.13</b>	<b>0.735</b>
	<b>Direct</b>	2.46±0.50	2.21±0.31	<b>2.10</b>	<b>0.207</b>

\*Significant ( $p < 0.05$ )

## DISCUSSION

In this study, there is a comparison between different methods TMJ digital tracing (ARCUS digmaII), and cone beam CT to determine the Bennett angle and evaluate their effect on bilateral balanced occlusion. All the patients were selected to have normal jaw relationship and assessed clinically to have normal temporomandibular joint, Because the relationship has not been established between occlusion and temporomandibular disorder (TMD), there might be an association between these two variables, TMD can influence the movement of the mandible, to avoid the source of error in addition to obtaining satisfied records from the patients<sup>(12)</sup>.

The present investigation yielded statistically insignificant differences in the tested variables, which is not surprising given the limitations of the selected sample and its age.

This study revealed an insignificant difference between the two methods and there is no difference between the right and left side and insignificant difference in their effect on balanced occlusion, this comes in agree with, Hernandez et al<sup>(13)</sup> found no significant differences between right and left Bennett angle values exhibited no variation on both sides and there is no significant difference.

The TMJ digital tracing uses electromagnetic sensors to track the position of the condyles, The ARCUS digma system, which uses an electronic sensor to measure condylar guidance in a manner similar to the pantograph, will enable clinics and technicians to measure more quickly and accurately<sup>(14)</sup>.

In agree with this study, using a CT image in the clinic can be avoided if landmarks can be located directly. In situations where direct digitization of the landmark poses a challenge, it is possible to integrate 3D CT with motion tracking data in a manner that preserves precision. Furthermore, the findings of our study indicate that both optoelectric and electromagnetic locators can be selected by researchers and clinicians without compromising precision or accuracy<sup>(15)</sup>.

In agree with this study, in recent years, there has been significant progress in the advancement of diagnostic imaging technology, particularly in the field of computed tomography. The utilization of measurement techniques with absolute precision enables us to derive benefits and conduct in-depth morphological analyses<sup>(17)</sup>.

Accurate measurement of parameters, such as the Bennett angle and movement, is crucial for effective prosthetic and gnathological rehabilitation. The volumetric acquisition of CT provides comprehensive data pertaining to the dental and bone structures of the masticatory system. The determination of centric relation, right laterality, and left laterality was made. The utilization of Cone Beam images was employed in the current investigation to document Bennett's angle and movement<sup>(18)</sup>.

The present study is inconsistent with the arcus digma, there are still problems with inconvenience, the production of clinical errors, and a lack of data. Further research is needed to overcome these issues and provide a new, reliable approach<sup>(19)</sup>.

In counter to this study, and according to previous research<sup>(16,20)</sup>, radiographic techniques have been found to be more precise compared to other clinical methods. This is due to the fact that radiographic measurements utilize stable bony landmarks and are not dependent on the neuromuscular control of the operator or patient.

Balanced articulation refers to the occlusal contacts between the maxillary and mandibular teeth, which occur initially during maximum intercuspation and persist during movements along specific guidance pathways, including working, balancing, and protrusive pathways that are developed on the occlusal surface of the teeth. It is considered to be the most effective occlusion for complete dentures. To maintain the dentures when the mandible moves into eccentric postures, balanced occlusion is essential.<sup>(21,22)</sup>

In addition to the accuracy of the measurement methods, the use of bilateral balanced occlusion in completely edentulous patients has been shown to improve patient satisfaction and oral function. A study that bilateral balanced occlusion was associated with improved masticatory efficiency and overall patient satisfaction in complete denture patients<sup>(23)</sup>.

## CONCLUSION

There is an insignificant difference between cone beam CT and TMJ digital tracing for recording the Bennett angle and their effect on the occlusion of complete dentures. Both methods can be used interchangeably for this purpose, depending on the clinician's preference.

## RECOMMENDATION

ARCUS digmall seemed reliable in interchangeability and promising to be used in Bennett angle as cone beam CT, so it can be used as an alternative technique for that. Further study for Arcus digmaII in the complete denture to evaluate its effect on occlusion.

## REFERENCES

1. Praveena K, Ajay R, Devaki V, Balu K, Preethisuganya S, Menaga V. A comparative evaluation of lateral condylar guidance by clinical and radiographic methods—Hanau's formula revisited. *Journal of Pharmacy & Bioallied Sciences*. 2021 Jun;13 (1):537.
2. Bahig D, Ahmed Shawky A. Evaluation of Retention and Assessment of Biting Force Distribution of a Complete Denture Fabricated Using 3D Printed Custom Trays with Arcus Digma Versus Conventional Method (A Cross Over Study). *Ain Shams Dental Journal*. 2021 Sep 1;23(3):120-30.
3. Shetty R, Shetty S, Shetty N, Pinge SS, Zahid M, Suhaim KS. Comparative Evaluation of Lateral Condylar Guidance Angle Measured Using Hanau's Formula & Lateral Interocclusal Records. *Journal of Evolution of Medical and Dental Sciences*. 2021 Jun 28;10(26):1917-21.
4. Sharma A, Sharma I, Kaushik M, Kumar A, Chowdhury HC. Various concepts of occlusion in full mouth rehabilitation: A review. *Int J Appl Dent Sci*. 2020;6(3):560-4.
5. Abdeen R, Shaker M, ElSaadany H. Effect of Different Condylar Guidance Registration Records on Balanced Occlusion of Complete Denture. *Advanced Dental Journal*. 2022 Apr 1;4(2):123-37.
6. EL-Ghiaty MA, El-Ghany A, Mostafa M, El-Kilani NS, Abdeen RM. Effect of Different Horizontal Condylar Guidance Registration Methods, and Articulators on Bilateral Balanced Occlusion of Complete Denture. *Al-Azhar Dental Journal for Girls*. 2022 Oct 1;9(4):571-80.
7. Bahaa El-Din SM, El-Ghany A, Mostafa M, El-fattah A, Amany A, Kholief DM. Comparison between tracing method and cone beam imaging for recording Bennett movement. *Al-Azhar Dental Journal for Girls*. 2019 Jan 1;6(1):31-6.
8. Lassmann Ł, Nowak Z, Orthlieb JD, Żółtowska A. Complicated Relationships between Anterior and Condylar Guidance and Their Clinical Implications—Comparison by Cone Beam Computed Tomography and Electronic Axiography—An Observational Cohort Cross-Sectional Study. *Life*. 2023 Feb;13(2):335.
9. Application of ARCUS digma I, II systems for full mouth reconstruction: a case report. *Journal of Dental Rehabilitation and Applied Science*. 2016;32(4):345-50.
10. Yuan Y, Liu Q, Yang S, He W. Four-Dimensional Superimposition Techniques to Compose Dental Dynamic Virtual Patients: A Systematic Review. *Journal of Functional Biomaterials*. 2023 Jan 6;14(1):33.
11. Sójka A, Huber J, Kaczmarek E, Hędzulek W. Evaluation of mandibular movement functions using instrumental ultrasound system. *Journal of Prosthodontics*. 2017 Feb;26(2):123-8.
12. Ganugapanta VR, Ponnada SR, Gaddam KP, Perumalla K, Khan I, Mohammed NA. Computed tomographic evaluation of condylar symmetry and condyle-fossa relationship of the temporomandibular joint in subjects with normal occlusion and malocclusion: a comparative study. *J Clin & Diag Res: JCDR*. 2017; 11:29-33.
13. Hernandez AI, Jasinevicius TR, Kaleinikova Z, Sadan A. Symmetry of horizontal and sagittal condylar path angles: An in vivo study. *Cranio*. 2010; 28:60–6.
14. Mage K, Čelić R, Čimić S, Dulčić N. Usporedba parametara za programiranje prilagodljivih dentalnih artikulacija upotrebom voštanih ekscentričnih registrata i uređaja Arcus Digma. *Acta stomatologica Croatica: International journal of oral sciences and dental medicine*. 2019 Sep 26;53(3):213-23.

15. Baltali E, Zhao KD, Koff MF, Keller EE, An KN. Accuracy, and precision of a method to study the kinematics of the temporomandibular joint: a combination of motion data and CT imaging. *J Biomech.* 2008 Aug 7;41(11):2581-4.
16. Shreshta P, Jain V, Bhalla A, Pruthi G. A comparative study to measure the condylar guidance by the radiographic and clinical methods. *J Adv Prosthodont.* 2012 Aug;4(3):153-7.
17. Dygas S, Szarmach I, Radej I. Assessment of the Morphology and Degenerative Changes in the Temporomandibular Joint Using CBCT according to the Orthodontic Approach: A Scoping Review. *Biomed Res Int.* 2022 Feb 1; 2022.
18. Kim YI, Cho BH, Jung YH, Son WS, Park SB. Cone-beam computerized tomography evaluation of condylar changes and stability following two-jaw surgery: Le Fort I osteotomy and mandibular setback surgery with rigid fixation. *Oral Surgery, Oral Medicine, Oral Pathology, Oral Radiology, and Endodontology.* 2011 Jun 1;111(6):681-7.
19. Mage K, Čelić R, Čimić S, Dulčić N. Comparison of Parameters for Programming Adjustable Dental Articulators by Using Wax Eccentric Records and Arcus Digma Device. *Acta Stomatologica Croatica.* 2019;53(3):213-23.
20. Amarnath GS, Kumar U, Hilal M, Muddugangadhar BC, Anshuraj K, Shruthi CS, et al. Comparison of cone beam computed tomography, orthopantomography with direct ridge mapping for pre-surgical planning to place implants in cadaveric mandibles: An *ex vivo* study. (“Comparing the precision of panoramic radiography and cone-beam computed”) *J Int Oral Health.* 2015; 7:38–42.
21. Goldstein G, Kapadia Y, Campbell S. Complete denture occlusion: best evidence consensus statement. *Journal of Prosthodontics.* 2021 Apr;30(S1):72-7.
22. Lemos CA, Verri FR, Gomes JM, Santiago Junior JF, Moraes SL, Pellizzer EP. Bilateral balanced occlusion compared to other occlusal schemes in complete dentures: A systematic review. *Journal of oral rehabilitation.* 2018 Apr;45(4):344-54.
23. Moradpoor H, Arabzade Hoseini M, Savabi O, Shirani M. Patient satisfaction with an occlusal scheme of conventional complete dentures: A randomized clinical trial (part I). *Journal of oral rehabilitation.* 2018 Jan;45(1):41-9.