



CORONALLY ADVANCED FLAP IN CONJUNCTION WITH HYALURONIC ACID APPLICATION TO TREAT LOCALIZED GINGIVAL RESSION

Mohammed Ahmed Abdel Aziz Salem ¹, Abdel Fattah Mahmoud Amer ², Mostafa Mohammed Hosny ²

ABSTRACT

Objectives: The coronally advanced flap (CAF) is a set of techniques that combines surgery with the inclusion of different regenerative materials and biologic factors to achieve both functional attachment apparatus regeneration and root coverage. The tensile strength of granulation tissue is dramatically increased by HA, which also stimulates blood clot formation and causes angiogenesis. The purpose of this study was to see how well coronally advanced flap operations combined with hyaluronic acid treatment worked for miller class I single gingival recession. **Subjects and Methods:** The two contralateral locations at the split mouth were randomized so that a patient might function as his or her own control. One side was treated with coronally advanced flap with hyaluronic acid application (CAF + HA; test group), whereas the other was treated with coronally advanced flap alone (control group). Keratinized tissue was assessed for recession depth, probing pocket depth, and clinical attachment level. **Results:** CAF/HA sides showed a lower Recession depth than CAF sides. The decrease in probing depth was higher in CAF/HA sides than CAF sides. CAF/HA sides showed a lower clinical attachment loss than CAF sides. The decrease in CAL was higher in CAF/HA sides than CAF sides. The increase in Keratinized tissue was non-significantly higher in CAF/HA sides than CAF sides. **Conclusion:** In Miller Class I single gingival recession, combining hyaluronic acid with the CAF treatment increases the likelihood of obtaining root coverage and improving recession reduction.

KEYWORDS: Gingival recession, miller class I, CAF, hyaluronic acid.

INTRODUCTION

Gingival recession (GR) is a frequent symptom of long-term chronic periodontal disease, and its severity and prevalence increase as people age. Nearly half of the population is thought to have at least one site root surface exposed region of at least 1 mm in length⁽¹⁾. Patients with GR frequently

suffer cosmetic issues as a result of the increased clinical crown height, and they may also experience dental hypersensitivity. Although the cause of GR is multifaceted, biological and functional concerns related with mucogingival disorders necessitate therapy. Several categorization schemes for the GR have been developed, but Miller's classification is the most appropriate and widely used.

1. Dentist, Ministry of Health
2. Professor, of Oral Medicine, Periodontology, Diagnosis and Oral Radiology, Faculty of Dental Medicine (Boys, Cairo) Al-Azhar University
3. Assistant Professor, of Oral Medicine, Periodontology, Diagnosis and Oral Radiology, Faculty of Dental Medicine (Boys, Cairo) Al-Azhar University

• **Corresponding author:** ms1571705@gmail.com

The important aspects in the treatment of gingival recession, according to one theory, are to avoid increasing marginal tissue recession and to make plaque management methods easier in the affected area⁽¹⁾. There are a variety of non-surgical and surgical options for treating gingival recession. Norberg introduced the coronally repositioned periosteal flap operation in 1926⁽¹⁾. Prato et al suggested the term coronally advanced flap (CAF)⁽²⁾, which is a combination of surgical procedures with the addition of various regenerative materials and biologic factors with the goal of obtaining both functional attachment apparatus regeneration and root coverage.

Hyaluronic acid (HA) is a fundamental component of the extracellular matrix in practically all tissues. Its principal function is to bind water and facilitate the transit of essential metabolites, allowing these tissues to retain structural and homeostatic integrity⁽³⁾. HA activates metalloproteinase inhibitors and prevents tissue breakdown⁽⁴⁾. It is one of the most hygroscopic compounds known in nature, and it serves as a space filler, lubricant, and protein excluder, among other things⁽⁵⁾.

It has been demonstrated that HA significantly increases the tensile strength of the granulation tissue,⁽⁶⁾ stimulates the blood clot formation,⁽⁷⁾ induces angiogenesis process,⁽⁸⁾ increases osteogenesis,⁽⁹⁾ and does not interfere in the calcification nodules during bone formation⁽¹⁰⁾. Additionally, it was found that HA facilitates cell migration and differentiation during tissue formation and repair of both soft and hard tissues⁽¹¹⁾. An interesting finding was that HA showed ability to improve the periodontal ligament cell viability, and even early osteogenic differentiation in vitro⁽¹²⁾. In view of these, a combined procedures that include performing CAF with application of HA as treatment modality for Miller's class I GR may be value. Thus, the present study was designed and undertaken, hopefully, to draw the light on this area of periodontal and esthetic concern.

SUBJECTS AND METHODS

Study Design

This study was a randomized clinical trial and split mouth.

Study Setting and Population

Patients with miller class I single gingival recession were recruited. Those patients were selected from Outpatient Clinic of the Department of Oral Medicine, Periodontology, Oral Diagnosis and Oral Radiology, Faculty of Dental Medicine, Boys, Cairo, Al Azhar University.

Inclusion Criteria

Age ≥ 18 years, presence of at least one buccal recession (depth ≥ 2 mm) with no loss of interproximal attachment classified as Miller class I in the anterior maxillary or mandibular area (central and lateral incisors, canine, and first and second premolars) and associated with esthetic problems and/or dental hypersensitivity were included.

Exclusion Criteria

Smokers, systemic diseases or pregnancy, systemic antibiotic therapy in the last 6 months, active periodontal disease at sites (probing pocket depth < 4 mm and no bleeding on probing).

Ethical Consideration

Nature of the study was explained to patients, a written consent form was signed. And this study was approved by ethical number 765/4475.

Sample size

Power analysis indicated at least 26 Miller class I single gingival recession would be sufficient to demonstrate statistical significance at the $p < 0.05$ level with a power of (at least) $\geq 80\%$. According to the following formula: $n = (Za + Zb) \cdot 2 \cdot (SD) \cdot 2 / (d) \cdot 2$. where $SD = 0.46$ and $d = 0.5$ mm. The data are shown as mean and standard deviation⁽¹⁶⁾.

Intervention

The two contralateral locations were randomised at the split mouth level by the flip of a coin for a patient to function as his or her own control. One side of each patient was treated with coronally advanced flap with hyaluronic acid application (CAF + HA; test group), while the other side was treated with coronally advanced flap alone (control group) (control group).

Surgical procedure: Figure (1)

Two oblique and divergent releasing incisions extending beyond the mucogingival junction (MGJ) were done under local anaesthesia. At the buccal aspect of the affected tooth, an intra-sulcular incision was made. Split thickness surgical papillae were raised with care. A full thickness flap was used until the MGJ was raised, and then a tiny periosteal elevator was used. Following that, a partial thickness flap was lifted beyond the MGJ, resulting in a passive coronal displacement of the flap by reducing residual tension. A curette was used to gently plan the roots up to 1 mm from the bone crest. The anatomic interdental papillae were de-epithelialized with great care. Only CAF was conducted on the control group. In the test group, cross-linked Hyaluronic acid was applied to the root surface prior to flap suture. The substance is a hyaluronic acid gel with a high concentration. It is characterised by a sluggish rate of deterioration. HA is only available as a single-use cartridge. The cartridge was put into a cartridge syringe with 23G needles, as advised by the manufacturer, and the HA was administered to the denuded root surface until it was entirely coated. Finally, the flap was moved coronally and sutured to encompass the CEJ. The suture began with vertically interrupted sutures and apical-coronal releasing incisions to relieve tension and facilitate coronal displacement for the final coronal sling suture. 6-0 sutures were used, indistinctly distributed in each group.

Post-surgical protocol

Anti-inflammatory medicines were used to manage post-operative discomfort and edema. Patients were given 600 mg of ibuprofen at the conclusion of the surgery and told to take another pill 6 hours later; further dosages were only recommended if necessary. During the 5 days, amoxicillin (1 g every 12 hours) was also given. All patients were told to use an ice pack on the operative region on a regular basis. All patients were told to stop brushing their teeth and prevent any damage to the surgery site. For the first two weeks, a rinse with 0.12 percent chlorhexidine digluconate was given twice daily. Sutures were removed two weeks following surgery, and patients were encouraged to brush with a gentle post-surgical toothbrush. Patients were recalled for follow-up (and professional oral hygiene/maintenance procedures and clinical measurements as needed).

Evaluation

Clinical evaluations

Using a calibrated periodontal probe, the following clinical measures were performed at baseline and 6 months after surgery:

1. Recession depth (Rec): Measured from the CEJ to the gingival margin on the considered tooth.
2. Probe pocket depth (PPD).
3. Clinical attachment level (CAL)
4. Keratinized tissue (KT): Measured from the gingival edge to the MGJ.

Statistical analysis of the data:

Data were entered into a computer and analyzed using IBM SPSS software package version 20.0. (IBM Corporation, Armonk, NY). Number and percent were used to describe qualitative data. Range (minimum and maximum), mean, standard deviation, and median were used to characterise quantitative data. The significance of the acquired results was assessed at a 5% level.

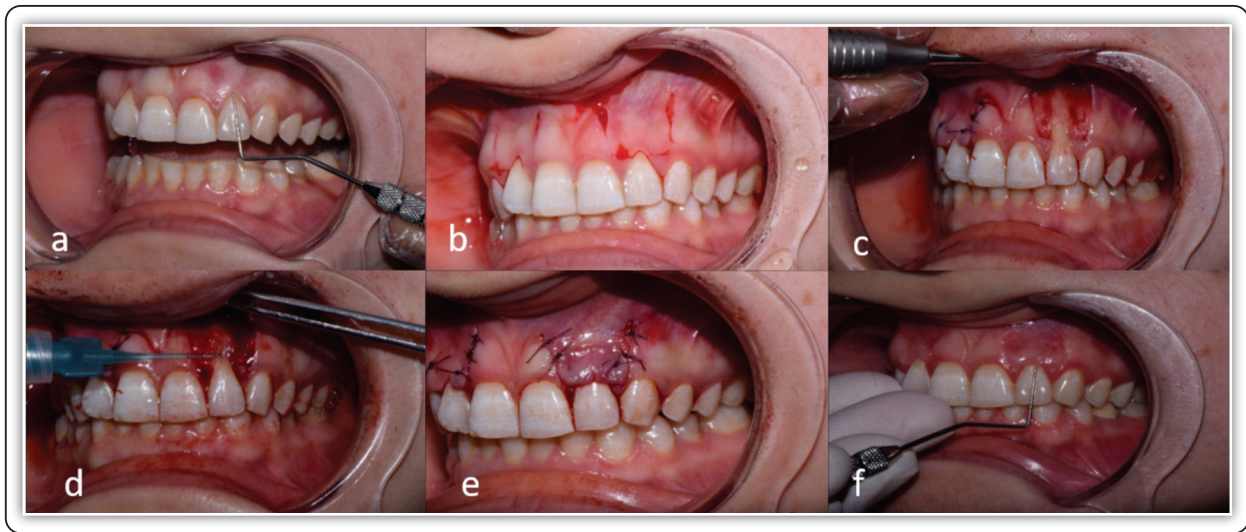


FIG (1) a, Miller class I gingival recession on the maxillary left lateral incisors, b, Releasing incisions, c, Flap reflection, d, Hyaluronic acid, hyaDENT application, e, Suturing the flap, f, Follow up.

RESULTS

Mean ±SD of the studied patients were 32.89 ± 3.52. Male was (33.3 %) and Female was (66.7 %).

TABLE (1) Comparison between CAF/HA and CAF according to recession depth (n = 26)

	CAF/HA	CAF	T	P
Recession depth				
Baseline	2.67 ± 0.79	2.78 ± 0.51	0.610	0.559
6 Months	0.61 ± 0.86	1.72 ± 0.79	10.000*	<0.001*
Probing depth				
Baseline	1.78 ± 0.67	1.61 ± 0.49	1.414	0.195
6 Months	1.06 ± 0.17	1.22 ± 0.36	2.000	0.081
Decrease	0.72 ± 0.67	0.39 ± 0.42		
CAL				
Baseline	4.44 ± 1.07	4.39 ± 0.82	0.286	0.782
6 Months	1.67 ± 0.97	2.94 ± 1.04	8.693*	<0.001*
Decrease	2.78 ± 0.87	1.44 ± 0.98		
Keratinized tissue				
Baseline	3.33 ± 1.0	3.78 ± 0.67	1.512	0.169
6 Months	4.78 ± 0.94	4.28 ± 0.67	1.897	0.094
Increase	1.44 ± 0.77	0.50 ± 0.35		

Data was expressed using Mean ± SD.

t: Paired t-test

p: p value for comparing between CAF/HA and CAF

*: Statistically significant at p ≤ 0.05

Table (1) summarizes Comparison between the two sides. CAF/HA sides showed a lower Recession depth than CAF sides. At baseline, there was a statistically non-significant difference between both sides (p=0.559). At 6 months, there was a statistically significant difference between both sides (p=0.001). The decrease in probing depth was higher in CAF/HA sides than CAF sides. CAF/HA sides showed a lower clinical attachment loss than CAF sides. The decrease in CAL was higher in CAF/HA sides than CAF sides. The increase in Keratinized tissue was non-significantly higher in CAF/HA sides than CAF sides.

DISCUSSION

Gingival recession is a typical clinical finding in individuals with good oral hygiene standards, with more than 90% of patients having it (13). The most common causes for these individuals to seek therapy are buccal exposure of roots with aesthetic deficits and dentinal hypersensitivity. Gingival recession treatment remains a difficulty for therapists, as it has been in previous years. In conjunction with physiological probing pocket depths, the ultimate

aim of root covering techniques is full repair of the recession defect with an aesthetic look equivalent to nearby healthy soft tissues⁽¹⁴⁾.

Several surgical procedures have previously demonstrated that root coverage at particular recession locations may be achieved in a number of ways with good results. Connective tissue grafts (CTG) and enamel matrix derivatives (EMD) in combination with a coronally advanced flap (CAF) have been shown to provide the highest probability of obtaining complete root coverage (CRC) in Miller classes I and II single gingival recessions when compared to CAF alone⁽¹⁵⁻¹⁷⁾. In practically all tissues, hyaluronic acid (HA) is a substantial component of the extracellular matrix. The major function of HA is to bind water and facilitate the transit of essential metabolites, allowing these tissues to retain structural and homeostatic integrity. It has been shown that HA enhances granulation tissue tensile strength, accelerates clot formation, and causes angiogenesis⁽¹⁸⁾. We anticipated that because HA has been shown to aid wound healing, it could also improve the results of CAF root coverage. The effects of adjunctive HA administration in conjunction with CAF in Miller class I single gingival recession therapy were compared to CAF alone in this research. At 6 months following treatment, both sides CAF/HA and CAF showed a statistically significant decrease in Rescission depth, probing depth CAL, according to the findings of this study. At 6 months, the CAF/HA sides had a greater drop in Recession depth and probing depth CAL than the CAF sides. CAF/HA and CAF exhibited a statistically significant increase in mean keratinized tissue at 6 months on both sides. Keratinized tissue increased in a non-significant way.

Pilloni et al⁽¹⁹⁾ studied the potential benefits of adjunctive hyaluronic acid (HA) administration in the coronally advanced flap (CAF) surgery in single Miller class I/recession type 1 (RT1) gingival recession therapy, which agreed with our findings. The test group (2.7 mm) had a statistically

significant lower rescission than the control group (1.9 mm; $p= 0.007$). PPD levels were found to be somewhat higher in both groups, but statistically significant. There was no statistically significant difference in KT gain amongst the treatments. For single Miller class I/RT1 gingival recession sites, supplementary administration of HA was successful in achieving CRC.

In addition, Bevilacqua et al⁽²⁰⁾ found that topical use of 0.8 percent HA gel in conjunction with modified Widman flap (MWF) surgery increased CAL and gingival recession coverage more than MWF surgery alone in a clinical investigation. As a result, the use of hyaluronic acid might significantly speed up the healing processes, which would validate our findings.

In the therapy of recession, Rajan et al⁽²¹⁾ compared CAF+HA to CAF+SCTG. They discovered substantial variations in PPD between the groups, with the test group outperforming the control group (HA). They discovered significant changes in the other clinical measures (Rec, KTW, CAL, and MRC) after 3 months but not at the conclusion of the research.

It's worth noting that both sides of the CAF/HA and CAF demonstrated a statistically significant decrease in probing depth after 6 months in the current research. CAF/HA teams had a greater drop in probing depth than CAF sides. This finding, together with the test group's increased recession coverage, demonstrates the HA application's positive impact. A recent study found that scaling and root planning along with scaling and root planning had a positive effect on HA PPD decrease^(22, 23).

Shirakata et al⁽²⁴⁾ examined the repair of gingival recessions treated with coronally advanced flap (CAF) with or without cross-linked hyaluronic acid (HA) in dogs on a clinical and histological level. Following treatment with CAF and HA, histologic evidence of periodontal regeneration of gingival recession defects was seen.

This is owing to the fact that HA has been described as a strong anti-inflammatory drug capable of modulating wound healing by scavenging inflammatory cell-derived reactive oxygen species⁽²⁵⁾. Because of its biological capabilities in wound healing, HA may improve clinical outcomes in the treatment of gingival recessions⁽²⁵⁻²⁷⁾.

Given that wound stability is an important aspect in achieving a good outcome in regenerative periodontal operations, it's possible that the increased root coverage was due to the wound stability established at the surgical sites. It's reasonable to presume that the increased root coverage seen at the study's test locations is due to HA's recognised angiogenic role as an hydrating agent, and its property of enhancing connective tissue cells^(28, 29).

A recent RCT, on the other hand, compared CAF + HA against CAF alone. No significant changes were identified in any of the clinical measures, according to the researchers⁽³⁰⁾. In conclusion, doctors should initially focus on susceptibility factors and modifiable situations when designing a treatment approach, while raising the patient's awareness of gingival recession. CAF paired with a connective tissue graft (CTG) is regarded the best predictable therapeutic option for single and multiple recession defects in circumstances when surgery is required. If there is a contraindication to taking a CTG from the palate or if the patient prefers not to have a donor site surgery, hyaluronic acid might be a useful therapy option.

CONCLUSION

Within the limitations of this study; in Miller Class I single gingival recession, combining hyaluronic acid with the CAF treatment increases the likelihood of obtaining root coverage and improving recession reduction.

REFERENCES

1. Smith RG. Gingival recession. Reappraisal of an enigmatic condition and a new index for monitoring. *J Clin Periodontol* 1997;24(3):201-5.
2. Agarwal SK, Jhingran R, Bains VK, Srivastava R, Madan R, Rizvi I. Patient-centered evaluation of microsurgical management of gingival recession using coronally advanced flap with platelet-rich fibrin or amnion membrane: A comparative analysis. *Eur J Dent* 2016;10(1):121-33.
3. Dahiya P, Kamal R. Hyaluronic Acid: a boon in periodontal therapy. *N Am J Med Sci* 2013;5(5):309-15.
4. Laurent TC, Fraser JR. Hyaluronan. *Faseb J* 1992; 6(7):2397-404.
5. Bansal J, Kedige SD, Anand S. Hyaluronic acid: a promising mediator for periodontal regeneration. *Indian J Dent Res* 2010;21(4):575-8.
6. Vantinen E, Viljanto J. Tensile strength of new connective tissue formed in pretreated viscose cellulose implants. *Ann Med Exp Biol Fenn* 1965;43(4):257-9.
7. Scully MF, Kakkar VV, Goodwin CA, O'Regan M. Inhibition of fibrinolytic activity by hyaluronan and its alcohol ester derivatives. *Thromb Res* 1995;78(3):255-8.
8. West DC, Hampson IN, Arnold F, Kumar S. Angiogenesis induced by degradation products of hyaluronic acid. *Science* 1985;228(4705):1324-6.
9. Pilloni A, Bernard GW. The effect of hyaluronan on mouse intramembranous osteogenesis in vitro. *Cell Tissue Res* 1998;294(2):323-33.
10. Pilloni A, Rimondini L, De Luca M, Bernard GW. Effect of hyaluronan on calcification-nodule formation from human periodontal ligament cell culture. *J Appl Biomater Biomech* 2003;1(1):84-90.
11. Pirnazar P, Wolinsky L, Nachnani S, Haake S, Pilloni A, Bernard GW. Bacteriostatic effects of hyaluronic acid. *J Periodontol* 1999;70(4):370-4.
12. Fujioka-Kobayashi M, Muller HD, Mueller A, Lussi A, Sculean A, Schmidlin PR, et al. In vitro effects of hyaluronic acid on human periodontal ligament cells. *BMC Oral Health* 2017;17(1):44.
13. Kassab MM, Cohen RE (2003) The etiology and prevalence of gingival recession. *J Am Dent Assoc* 134:220–225
14. Cairo F, Pagliaro U, NieriM(2008) Treatment of gingival recession with coronally advanced flap procedures. A systematic review. *J Clin Periodontol* 35:136–162

15. Chambrone L, Pannuti CM, Tu YK, Cambrone LA (2012) Evidence-based periodontal plastic surgery II. An individual data meta-analysis for evaluating factors in achieving complete root coverage. *J Periodontol* 83:477–490
16. Cairo F, Nieri M, Pagliaro U (2014) Efficacy of periodontal plastic surgery procedures in the treatment of localized facial gingival recessions. A systematic review. *J Clin Periodontol* 41:S44–S62
17. Chambrone L, Tatakis DN (2015) Periodontal soft tissue root coverage procedures: a systematic review from the AAP regeneration workshop. *J Periodontol* 86:S8–S51
18. Dahiya P, Kamal R (2013) Hyaluronic acid: a boon in periodontal therapy. *N Am J Med Sci* 5:309–315
19. Pilloni A, Schmidlin PR, Sahrman P, Sculean A, Rojas MA. Effectiveness of adjunctive hyaluronic acid application in coronally advanced flap in Miller class I single gingival recession sites: a randomized controlled clinical trial. *Clin Oral Investig*. 2019 Mar;23(3):1133–1141.
20. Bevilacqua L, Eriani J, Serroni I et al (2012) Effectiveness of adjunctive subgingival administration of amino acids and sodium hyaluronate gel on clinical and immunological parameters in the treatment of chronic periodontitis. *Annali di Stomatologia* 3:75–81
21. Rajan P, Rao NM, Nera M, Rahaman SM (2015) Hyaluronon as an adjunct to coronally advanced flap for the treatment of gingival recession defects. *Natl J Integr Res Med* 6:94–100
22. Johannsen A, Tellefsen M, Wikesjö U, Johannsen G (2009) Local delivery of hyaluronan as an adjunct to scaling and root planing in the treatment of chronic periodontitis. *J Periodontol* 80:1493–1497
23. Eick S, Renatus A, Heinicke M, Pfister W, Stratul SI, Jentsch H (2013) Hyaluronic acid as an adjunct after scaling and root planing: a prospective randomized clinical trial. *J Periodontol* 84:941–949
24. Shirakata Y, Nakamura T, Kawakami Y, Imafuji T, Shinohara Y, Noguchi K, Sculean A. Healing of buccal gingival recessions following treatment with coronally advanced flap alone or combined with a cross-linked hyaluronic acid gel. An experimental study in dogs. *J Clin Periodontol*. 2021 Apr;48(4):570–580.
25. Moseley R, Waddington RJ, Embery G (2002) Hyaluronan and its potential role in periodontal healing. *Dent Update* 29:144–148
26. Casale M, Moffa A, Vella P, Sabatino L, Capuano F, Salvinelli B, LopezMA, Carinci F, Salvinelli F (2016) Hyaluronic acid: perspectives in dentistry. A systematic review. *Int J Immunopathol Pharmacol* 29:572–582
27. Ferguson EL, Roberts JL, Moseley R, Griffiths PC, Thomas DW (2011) Evaluation of the physical and biological properties of hyaluronan and hyaluronan fragments. *Int J Pharm* 420:84–92
28. Calvin M (1998) Cutaneous wound repair. *Wounds* 10:12–32
29. ChenWY, Abatangelo G (1999) Functions of hyaluronan in wound repair. *Wound Repair Regen* 17:79–89
30. Kumar R, Srinivas M, Pai J, Suragimath G, Prasad K, Polepalle T (2014) Efficacy of hyaluronic acid (hyaluronan) in root coverage procedures as an adjunct to coronally advanced flap in Miller class I recession: a clinical study. *J Indian Soc Periodontol* 18:746–750