

# Transport bone distraction osteogenesis of mandibular midline defect using custom made modified external device

## Case Report

*Snehal B Bansod , Jagriti Lahiri*

*Department of Oral and Maxillofacial Surgery, Maitri College of Dentistry and Research Center, Anjora, Durg-491001, Chattisgarh, India*

### ABSTRACT

For a Reconstructive surgeon, Facial skeleton reconstruction is yet quite an arduous procedure, even though there is a wide range of reconstructive options present.

Distraction osteogenesis is a process of slow bone expansion in which new bone is generated in an osteotomy gap in response to tension stresses placed across the bone gap .Transport distraction osteogenesis is an unconventional reconstructive modality in the armamentarium of a maxillofacial reconstructive surgeon with obvious advantages of osteogenesis and histogenesis from the residual host tissues after tumor ablative surgeries or trauma and also precludes donor site morbidity .

This paper renounces that the procedure of Transport bone distraction Osteogenesis of mandibular midline defect after radical resection of Ameloblastoma in the anterior segment of the mandible, using custom made Modified light weight external device and which was later followed by rehabilitation after healing of mandibular segments with the help of Osseointegrated trans-osseous dental implants and dental prosthesis.

**Keywords :** Ameloblastoma ,Distraction Osteogenesis, mandible reconstruction, trifocal Transport Distraction Osteogenesis  
**Received:** 18 July 2023 , **Accepted:** 7 August 2023.

**Corresponding Author:** Jagriti Lahiri , Department Of Oral and Maxillofacial Surgery, Maitri College of Dentistry And Research Centre, Anjora ,Durg , **Mobile:** +9007833453 , **E-mail:** drlahiri23@gmail.com  
**ISSN:** 2090-097X, July 2023, Vol. 14, No. 3

### INTRODUCTION

Ameloblastoma is a true neoplasm of odontogenic epithelial origin, which usually occurs in the mandible [1,3] .

Major manifestations include cortical bone expansion along with perforation having a high recurrence rate. It often happens to invade surrounding soft tissues.

Ameloblastoma is naturally seen to have a locally aggressive behaviour, seemingly having a malignant potential. Quite a significant disfiguration becomes notable. Main clinical features include pain, asymmetric appearance inducing difficulty in speech and even difficulty in articulation [2,4].

The indication for surgical treatment is quite advisable but still has got a lot of controversy. Enucleation and curettage are conservative treatment approaches having High recurrence rates, requiring repeated procedures [3,4].

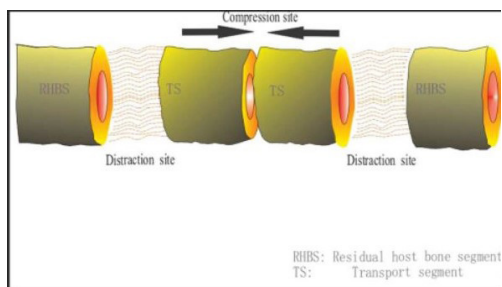
On the other hand, marginal or segmental mandibulectomies have relatively quite low recurrence rates but lead to major deformities. In 1987 Ilizarov developed the Distraction Osteogenesis (DO) technique and introduced this reconstruction method for MRA to scientific community. Consequently, in 1992

MacCarthy reported the first successful application of DO treatment on mandible [5,6,7]. In a typical DO procedure, a manual distractor is used. A standard DO protocol consists of four phases: bone osteotomy and device installation, latency, activation, and consolidation [5,8,9] .

Transport distraction osteogenesis remains a probable good prognostic treatment choice for mandibular reconstruction. Although it requires dental rehabilitation due to loss of dentition. In this case the Authors used customised light weight external transport distraction device and a reconstruction plate which was placed to fill the mandibular continuity defect, highlighting the procedure for trifocal distraction osteogenesis.

Trifocal distraction osteogenesis [Figure 1] modality works by compression osteosynthesis which results in formation of two simultaneous distraction regenerates (bifocal distraction osteosynthesis) which is obtained when two transport discs are created from both residual bone segments. Thereafter, both residual bone segments are simultaneously moved centripetally towards each other so that they meet in the center of the defect here in the symphyseal region. Hereby, subsequently gets compressed ( monofocal compression osteosynthesis)

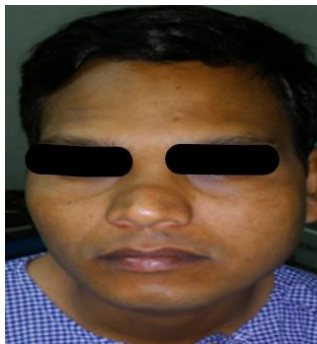at the docking site in the center of the defect <sup>[10]</sup>.



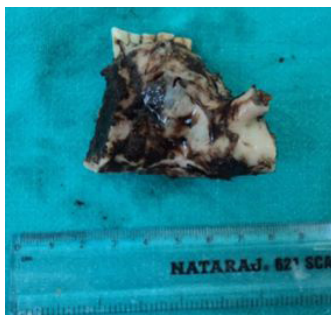
**Figure 1**

**CASE REPORT**

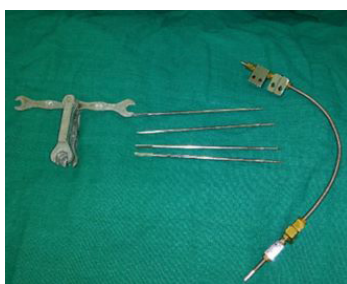A 35 year old male reported to our department with complaint of swelling in the anterior portion of lower jaw. The swelling was of diffused size involving the symphysis and extending upto both parasymphysis region of the mandible( **Figure 2** )



The patient underwent an incisional biopsy and was diagnosed as Plexiform Ameloblastoma. The patient underwent resection of mandible with a clear margin of 1.5 cm on both sides( **Figure 3** ) .

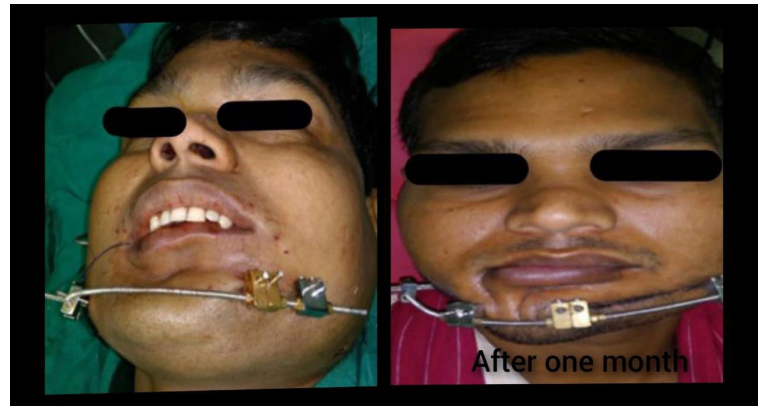

The reconstruction of the defect was planned by a procedure known as Trifocal distraction osteogenesis ( **Figure 4** ).



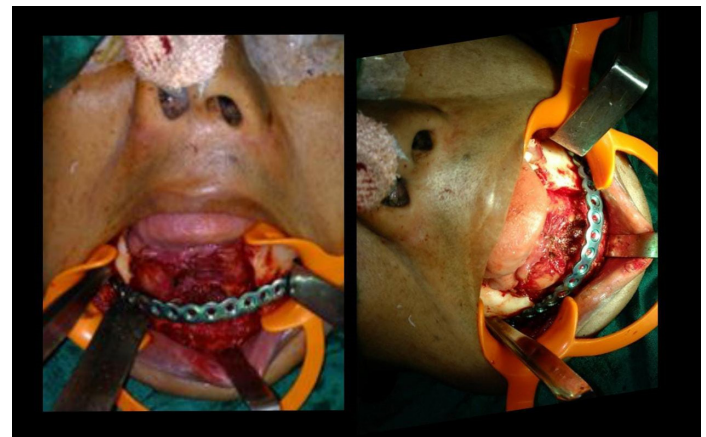
A light weight custom made device was designed in which a brass distraction arm was fabricated to make the device light weight. External fixtures with Schanz pins were used to transport the bone segments across the defect.

Thus, we were able to fabricate a very light weight external transport distraction device ( **Figure 5** ).

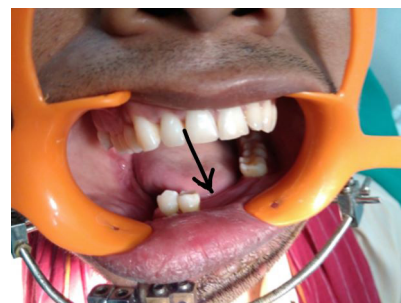

The residual mandible was stabilised with the help of a reconstruction plate maintaining the right occlusion of the residual segments.

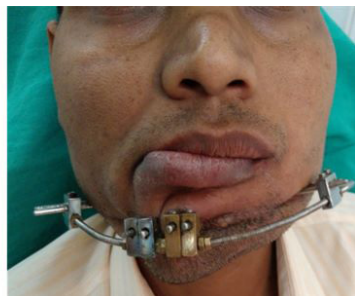
A transport bone segment was created of size 1.5 cm on both sides which was then fixed fixed thereafter with the help of Schanz pin to the external fixator arm( **Figure 6** ).



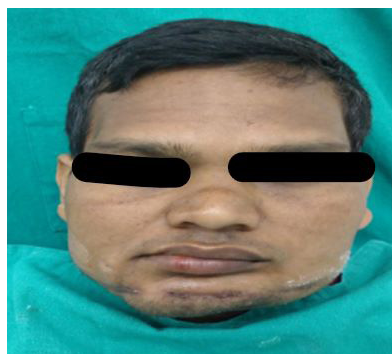After a latency period of 7 days, the distraction was started at a distraction rate of 1mm / day and a radiograph was taken to evaluate . The distraction was carried out till the apposition of the distraction segments ( **Figure 7** ).



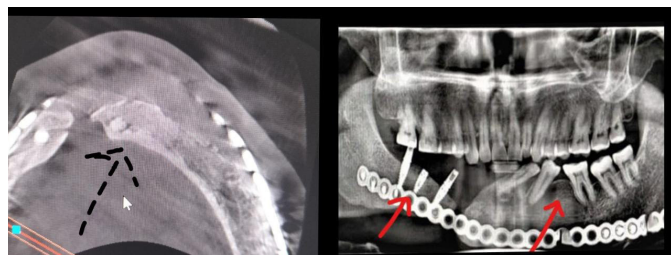
Distraction device was left in situ for consolidation of the distracted bone( **Figure 8** ).



The device was later on easily removed (**Figure 9**) after the consolidation under Local Anaesthesia.



The patient underwent further rehabilitation with transosseous implants and fixed partial dentures (**Figure 10**).



## DISCUSSION:

Distraction Osteogenesis characterizes slow bone expansion in which new bone is generated in an osteotomy gap in response to tension stresses placed across the bone gap [10]. Distraction Osteogenesis has been proved as quite a successful treatment modality pursued for patients with maxillo-mandibular skeletal defects. DO is a method of regenerating new bone tissue with using gradual supply of tensile stress across the osteotomized site<sup>[5,10]</sup>. Preoperative treatment planning is important to determine the correct placement and to apply the correct vector because implementing transport distraction osteogenesis around a curve of the mandible presents specific challenges. The external device allows significant vector control in all plane of space by following the reconstruction plate. The reconstruction of the defect planned by the procedure known as Trifocal

distraction osteogenesis needs an external device which should not be heavy, as the patient has to carry the device during the whole treatment. The external devices available in market are heavy and expensive titanium devices. So a light weight custom made device was designed in which a brass distraction arm was fabricated to make the device light weight. External fixtures with Schanz pins were used to transport the bone segments across the defect.

Transport distraction osteogenesis is done to preserve skeletal function after resection of large segmental bone defects, creating a distraction focus and resulting on small portion of healthy bone which will act as transport segment. Then using an external ring fixator, the latter segment is slowly distracted in the defect direction. This creates regenerated tissue resulting in bone union and a bridged effect. After the process of successful docking, which is achieved when the transportation segment heals with the adjacent bone. It is possible to foresee the timing of docking by measuring the distance between two bones on radiographs and calculating the number of days required to achieve contact based upon the distraction rate [4]. Although it is found to have some complications like loosening soft tissue, loosening of pins, chronic pain, non-weight-bearing lameness, multiple surgeries and even amputations<sup>[4,11,12,13]</sup>. The distraction device used by Constantino (1995) consisted of an external semicircular frame attached to the mandible by two pairs of pins and to the transport disc by a transport tram which is quite bulky, unlike the reconstruction plate used in this case which is light weight. Therefore the reconstruction of the mandible with customised made modified external device transport distraction osteogenesis can be used to provide bone contour simultaneously and rehabilitation of the dentition with dental implants after the treatment of ameloblastoma with resection. Further studies are needed in this technique. Novel devices can be manufactured with current 3 d imaging and cad/cam planning. 3 d printing can be used to make customised devices with automated distraction rates.

## DECLARATION OF PATIENT CONSENT:

Hereby, the Authors certify that we have obtained all appropriate patient consent forms. In the form, the patient has given his consent for his images and other clinical information. The patient understands that his name and initials will not be published and due efforts will be made to conceal his identity, but anonymity cannot be guaranteed.

## FINANCIAL SUPPORT AND SPONSORSHIP:

The authors received no financial support for the research, authorship and publication of the article.

## CONFLICT OF INTEREST

There are no conflicts of interest.

---

**REFERENCES**


---

1. Reconstruction of a Neocondyle Using Transport Distraction Osteogenesis Suzanne U. Stucki-McCormick, Robert M. Fox, and Ronald D. Mizrahi [https://doi.org/10.1016/S1073-8746\(99\)80044-9](https://doi.org/10.1016/S1073-8746(99)80044-9).
2. Transport Distraction Osteogenesis for Maxillomandibular Reconstruction: Current Concepts and Applications R. S. Neelakandan • Darpan Bhargava J. Maxillofac. Oral Surg. (July-Sept 2012) 11(3):291–299 DOI 10.1007/s12663-011-0329-3.
3. Plate-guided transport distraction osteogenesis of mandible after the excision of an ameloblastoma with inferior alveolar nerve preservation and dental implant treatment: A case re... Article in Oral and Maxillofacial Surgery Cases · January 2019 DOI: 10.1016/j.omsc.2018.100092.
4. Distraction Osteogenesis: Biological Principles and Its Application in Companion Animals WRITTEN BY Guilherme Domingos, Henrique Armés, Isabel Dias, Carlos Viegas and João Requicha; Submitted: April 26th, 2019 Reviewed: August 13th, 2019 Published: October 2nd, 2019 DOI: 10.5772/intechopen.89157.
5. Review of automatic continuous distraction osteogenesis devices for mandibular reconstruction applications Article in BioMedical Engineering OnLine · April 2020 DOI: 10.1186/s12938-020-00761-8.
6. Ilizarov GA. The principles of the Ilizarov method. Bull Hosp Jt Dis Orthop Inst. 1987;48(1):1–11.
7. Peacock ZS, et al. Automated continuous distraction osteogenesis may allow faster distraction rates: a preliminary study. J Oral Maxillofac Surg. 2013;71(6):1073–84.
8. Ilizarov GA. The tension-stress effect on the genesis and growth of tissues: Part II. The influence of the rate and frequency of distraction. Clin Orthop Relat Res. 1989;239:263–85.
9. Cano J, et al. Osteogenic alveolar distraction: a review of the literature. Oral Surg Oral Med Oral Pathol Oral Radiol Endod. 2006;101(1):11–28.
10. Snehal B. Role of transport bone distraction osteogenesis in neocondyle genesis for temporomandibular joint surgical defects: a case report. Egyptian Journal of Oral and Maxillofacial Surgery. 2014;5:16–22.
11. Asada N, Tsuchiya H, Kitaoka K, et al. Massive autoclaved allografts and autografts for limb salvage surgery: A 1-8 year follow-up of 23 patients. Acta Orthopaedica Scandinavica. 1997;68:392-395.
12. Dernell WS, Withrow SJ, Straw RC. Clinical response to antibiotic impregnated methylmethacrylate bead implantation of dogs with severe infections after limb sparing surgery and allograft replacement: 18 cases (1994-1998). Veterinary and Comparative Orthopaedics and Traumatology. 1998;11:94-99.
13. Ortiz-Cruz E, Gebhardt MC, Jennings LC, et al. The results of transplantation of intercalary allografts after resection of tumors. A long-term follow-up study. The Journal of Bone and Joint Surgery. American Volume. 1997;79:97-106.