

The Effect of Diabetes Mellitus Type 1 on the Retinal Ganglion Cell Layer

Ali Khalil Awadallah, Mervat El Shabrawy El Gharieb, Mohamed Fawzy Mohamed Abbas*

Department of Ophthalmology, Faculty of Medicine, Suez Canal University, Egypt.

*Corresponding author: Mohamed Fawzy Mohamed Abbas, Mobile: 01006789195

E-mail: mhmdfawzi2512@gmail.com

ABSTRACT

Background: Retinal ganglion cell layer (RGC) layer has a very significant role in collecting the visual input from the retina and transmitting the electrical signals to the brain for the creation of a visual image. Unfortunately, that image is affected by many illnesses and type 1 diabetes mellitus (T1DM) is considered one of the commonest chronic illnesses in the world and in Egypt specifically.

Aim and objectives: To assess the impact of diabetes mellitus type 1 on the ganglion cell layer, which may help in early detection and prevention of diabetic retinal complications and hence improve the quality of vision among diabetic patients.

Subjects and methods: This case-control trial included 100 eyes of 50 cases separated to fifty eyes of diabetic persons and the same eyes of healthy control. The study was conducted at Department of Ophthalmology, Faculty of Medicine, Suez Canal University.

Results: There was a statistically significant alteration amongst the studied groups as regard optical coherence tomography (OCT) of eyes, correlation between duration of DM, (Comparison between ganglion cell layer (GCL) thickness in OCT and level of DM control) and correlation between severity and duration of diabetes and OCT measurements.

Conclusion: Diabetes has an early impact on the organisation of the neuronal retinal layers macular ganglion cell complex (GCC), which in most of the patients under study even occurred before retinal vascular alterations in addition to vision impairment. Most of the GCC quadrants were statistically significantly thinner in diabetic type I patients compared to healthy controls.

Keywords: Retinal Ganglion Cell Layer, Diabetes Mellitus Type 1, OCT

INTRODUCTION

Hyperglycemia and inadequate insulin levels to maintain metabolic demand characterize type 1 diabetes mellitus, an autoimmune disease that affects an ever-increasing number of people around the world ⁽¹⁾.

Acute, potentially fatal, symptomatic hyperglycemia is the hallmark of diabetes with type 1. Symptoms of diabetes tend to be less severe and the period amongst the onset of symptoms and the diagnosis of diabetes is longer in adolescents and adults who are fifteen and above ⁽²⁾. When the renal threshold for glucose excretion is exceeded, the earliest clinical indicators of diabetes in children are polyuria as well as polydipsia, followed by a slow metabolic breakdown along with characteristic symptoms ⁽³⁾.

Noninvasive optical coherence tomography (OCT) was designed to be fast in terms of its hardware besides software qualities, and it displays excellent levels of precision and also definition in the identification of early in addition minute changes in retinal morphology ⁽⁴⁾.

Coherence in Optics: The thickness of the different retinal layers can be determined by using tomography to create a cross sectional image of the retina. The axons of the retinal ganglion cells form a layer that may be measured in thickness; this layer is known as the retinal nerve fiber layer (RNFL). Despite the fact that this method does not assess RGC numbers directly, the fact that axonal loss precedes retinal ganglion cell loss means that it is expected to be a valid surrogate marker of RGC numbers. This technology is advantageous.

since it is noninvasive and may be performed in vivo to track retinal ganglion cell degeneration in real time ⁽⁵⁾.

From photoreceptors via bipolar cells to ganglion cells is the simplest and most typical route for these signals to travel from the eye to the brain. Action potentials from retinal ganglion cells travel along the optic nerve to the brain ⁽⁶⁾. The dorsal lateral geniculate nucleus is a major destination for RGC axons because it serves as a relay station for light information en route to the visual cortex and further areas convoluted in traditional picture vision. Some retinal ganglion cell axons also carry visual data, such as circadian photoentrainment, from the retina to other parts of the brain ⁽⁷⁾.

The International Diabetes Federation predicts that by 2030, there will be an estimated 23.9 million African people living with diabetes, up from an estimated 12.1 million in 2010. Cataracts along with diabetic retinopathy, a degenerative condition of the retina's tiny blood vessels, are two ways that diabetes can impair vision ⁽⁸⁾.

The goal of this work was to estimate the influence of diabetes type one on the ganglion cell layer, which may help in early detection and prevention of diabetic retinal complications and hence improve the quality of vision among diabetic patients.

PATIENTS AND METHODS

The trial was performed as a case-control trial. It was conducted in the ophthalmology outpatient clinic in

the Suez Canal University Hospital, on 100 eyes of 50 persons divided to 50 eyes of diabetic patients and 50 eyes of healthy control. The cases included 11 (44%) males and 14 (56%) females while the control included 13 (52%) males and 12 (48%) females.

Inclusion criteria

For the study group: Aged between 20-40 years old, both sexes and diagnosed with type 1 diabetes mellitus. For the control group: Aged between 20-40 years old and not affected by T1DM.

Exclusion Criteria: Participants with any concurrent eye diseases, e.g., cataract, glaucoma, corneal opacity, glaucoma, retinal diseases or diabetic retinopathy, Participants with any recent or past eye surgical interference, who refused to participate at the study, History of ocular trauma, OCT Image signal quality <60% and motion artifacts which prevented the accurate analysis of data.

Sampling:

The number of samples needed was determined by the following equation:

- $n = (Z_{\alpha/2})^2 \times P(1-P) / d^2$
-

Where:

- **n** = required sample size
- **Z_{α/2}**=A normal deviation reflect the type I error =1.96
- **P** =the prevalence of T1DM for 10-19.9⁽⁹⁾.
- **d** =the accuracy of estimate (how close the true population) = 0.08
- $n = (1.96)^2 \times 0.04(1-0.96) / (0.08)^2$ ⁽¹⁰⁾.

So, by calculation, the sample size was to be 23 cases and with 10% dropout was 25 cases for each group.

Methodology

Information was compiled using a standard data sheet, and all participants included in the study had the following: History taking, clinical evaluation and investigations.

OCT examination protocol:

OCT scanning was done for all the patients after the clinical examination. Six successive OCT scans were taken for each eye, with a set length of 6 mm for each scan as well as a uniform angular orientation of 30 degrees in a radial spoke pattern centered on the fovea.

When doing an optical coherence tomography scan, the center of the image was aligned with the person's fixation, which was then confirmed to be in the fovea. In cases with eccentric or imperfect fixation, the external fixator was used and adjustments were done to centralize the scans on the center of the fovea.

Ethical considerations:

All the procedures of the study were approved by the Ophthalmology Department. The trial protocol was approved by the local Ethics Committee of Suez Canal University.

Research participants provided written informed consent, and those enrolled were free to withdraw from the trial at any moment without consequence. All data concerning these patients were kept confidential. Patients were informed about the results of the study and were instructed and treated accordingly and all data were coded and were not used for any other purposes other than this study. This work has been carried out in accordance with The Code of Ethics of the World Medical Association (Declaration of Helsinki) for studies involving humans.

Statistical analysis

Microsoft Excel was employed to collect and analyze any information. SPSS (Statistical Package for the Social Sciences) version 21.0 (SPSS Inc., Chicago, Illinois, USA) was utilized for the analysis. Means, standard deviation (SD), and range were used to characterize the statistical dispersion of numerical data. Case percentages and frequencies were used for qualitative data. T-tests was used to compare quantitative variables and chi-square tests was used to compare qualitative variables. Spearman and Pearson correlations were used to identify data relationships. A comparison was judged significant if the P-value was ≤ 0.05.

RESULTS

The age of included subjects ranged between 20-40 years. Regarding age and gender, there was no evident statistically significant disparity amongst the two groups (Table 1).

Table (1). Demographic characteristics of patients in each group

		Study group N=25 patients		Control group N= 25 patients		p-value
Age (years): Mean ±SD		34.52± 2.66		33.64± 2.53		
Gender: N (%)	Male	11	44	13	52	0.571
	Female	14	56	12	48	

Group 1 had a significantly lesser total, sup. and inf. GCL thickness in the right eye, in addition to lesser total, sup. and inf. GCL thickness in the left eye, when compared with group 2 (Table 2).

Table (2): OCT of eyes of both studied groups

		DM group N=50 eyes		Control group N = 50 eyes		p- value
		Mean	±SD	Mean	±SD	
OD	Sup	64.36	3.76	67.76	2.54	<0.0001*
	Inf	65.00	3.95	67.28	2.98	0.002*
	Total	64.16	3.48	68.08	2.45	<0.0001*
OS	Sup	64.96	3.26	67.68	2.25	<0.0001*
	Inf	64.60	4.46	67.12	3.09	0.002*
	Total	64.72	3.73	67.36	2.71	<0.0001*

*: Significant, OD: oculus dexter, OS: oculus sinister

The duration of DM disease had negative connection that was statistically significant with superior, total and inferior quadrant GCL thickness in both eyes (Table 3).

Table (3): Correlation between duration of DM among patients' group and OCT measurements

DM group (N=50 eyes) Duration of disease			
		r	p-value
GCL thickness	Sup	-0.602	<0.0001*
	Inf	-0.771	<0.0001*
	Total	-0.685	<0.0001*

*: Significant, GCL: ganglion cell layer

The level of HbA1C had a statistically and practically significant negative association with total, superior and inferior quadrant GCL thickness in both eyes (Table 4).

Table (4): Correlation between HbA1C among patients' group and OCT measurements

Study group, N=25 (HbA1C)			
		r	p-value
GCL thickness	Sup	-0.702	<0.0001*
	Inf	-0.639	<0.0001*
	Total	-0.694	<0.0001*

*: Significant, GCL: ganglion cell layer, OCT: Optical coherence tomography

There was statistically lower GCL thickness in OCT in uncontrolled DM group than controlled DM group (Table 5).

Table (5): Comparison between GCL thickness in OCT and level of DM control

	Controlled DM N=16		Uncontrolled DM N=34		p-value
	Mean	±SD	Mean	±SD	
Sup	66.63	1.93	63.74	3.70	0.005*
Inf	68.75	1.48	62.94	3.71	<0.0001*
Total	67.25	1.95	63.12	3.42	<0.0001*

*: Significant

Sup: superior ophthalmic vein.

Inf: inferior ophthalmic vein.

It was found that all of OCT measures were statistically significantly negatively correlated with HbA1C and the duration of diabetes (Table 6).

Table (6): Correlation between severity and duration of diabetes and OCT measurements

	Duration of DM		HbA1C	
	r	p	r	p
OD sup	-0.589	<0.0001	-0.697	<0.0001
OD inf	-0.78	<0.0001	-0.738	<0.0001
OD total	-0.634	<0.0001	-0.75	<0.0001
OS sup	-0.625	<0.0001	-0.671	<0.0001
OS inf	-0.768	<0.0001	-0.823	<0.0001
OS total	-0.737	<0.0001	-0.769	<0.0001

*: Significant

OD: oculus dexter

OS: oculus sinister

Sup: superior ophthalmic vein.

Inf: inferior ophthalmic vein.

CASE 1

Glaucoma Analysis - Macula

Triton plus(Ver.10.13)

Print Date : 31-May-20



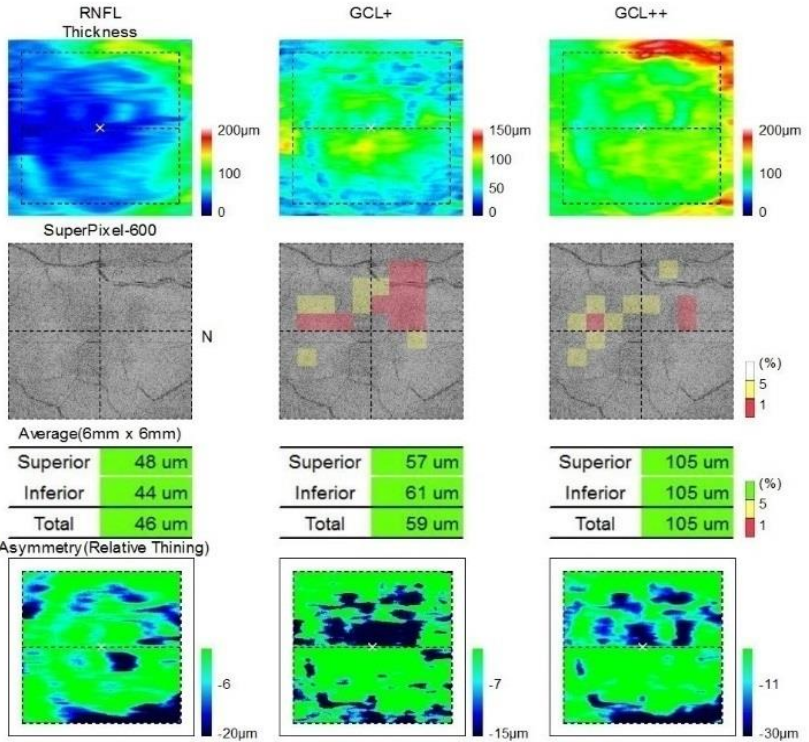
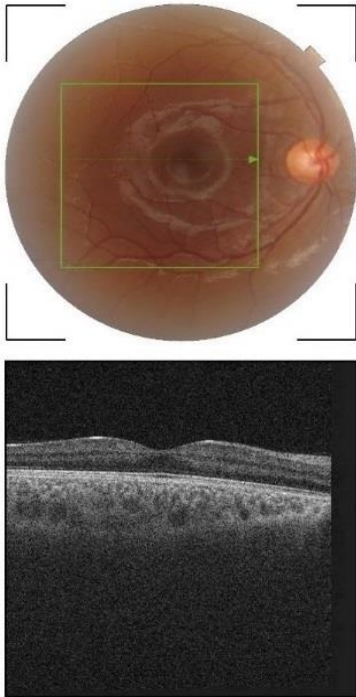
ID : 79867

Ethnicity :
Gender : Female
DOB : 00-Jan-87

Technician :
Fixation : OD(R) Macula
Scan : 3D(H)(7.0 x 7.0mm - 512 x 256)

Name :

OD(R) TopQ Image Quality: **60** mode: Fine(2.0.7)
Capture Date: 21-Jun-20 O.E.M.:1.000x



Comments :

Figure (1): OCT of right eye of 33 male participant shows total GCL thickness 59 μ m, 57 μ m superiorly and 61 μ m inferiorly.

CASE 2

Glaucoma Analysis - Macula

Triton plus(Ver.10.13)

Print Date : 21-Mar-20



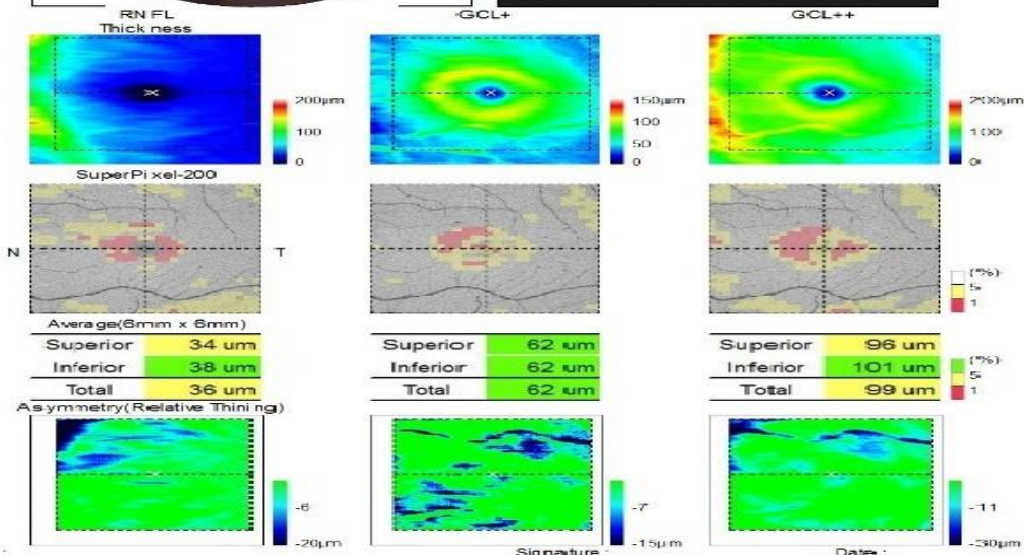
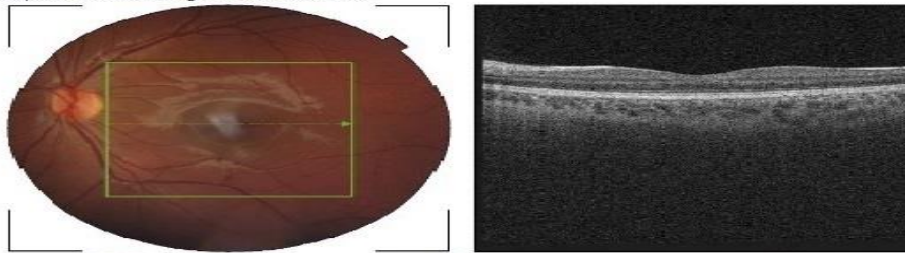
ID : s1003

Ethnicity : Caucasian
Gender : Female
DOB : 02-Mar-83

Technician :
Fixation : OS(L) Macula
Scan : 3D(H)(7.0 x 7.0mm - 512 x 256)

Name :

OS(L) TopQ Image Quality: **67** mode: Fine(2.0.7)
Capture Date: 05-Aug-19 O.E.M.:1.000x



Comments :

Figure (2): OCT of left eye of 38 female participant shows total GCL thickness 62 μ m, 62 μ m superiorly and 62 μ m inferiorly.

DISCUSSION

Capillary nonperfusion, vessel hyperpermeability, and neovascularization are the hallmarks of diabetic retinopathy (DR), one of the most prevalent microvascular consequences of type 1 diabetes mellitus⁽¹¹⁾. The traditional pathophysiology of diabetic retinopathy proposed that it is predominantly a vascular illness, where alterations in the endothelium cells of retinal vessels cause the blood-retina barrier to break down, increasing vascular permeability⁽¹²⁾. Researchers have hypothesized that in diabetes individuals, a neurodegenerative process with neuronal cell death, particularly retinal ganglion cells, precedes vascular alterations⁽¹³⁾.

Our results have revealed that the diabetic group had a numerically and statistically significant reduced total, sup., and inf. GCL thickness in both eyes when paralleled with the control group. This is in line with a trial by **Mahmoud et al.** in which persons with diabetes had significantly thinner superior and inferior GCCs compared to participants without diabetes⁽¹⁴⁾. Also, **Martin et al.** discovered that GCL thickness decreased by twenty to twenty-five, 14 weeks after diabetes was diagnosed⁽¹⁵⁾ and **Chen et al.** showed that those with T1 DM without diabetic retinopathy had considerably smaller GC-IPL thicknesses in all quadrants than controls⁽¹⁶⁾.

Since the macular region contains over fifty percent of the total RGCs and because retinal ganglion cell bodies are ten to twenty times larger than their axons, retinal ganglion cells in the macular region can be more prone to change if something goes wrong in the face of neurodegenerative processes⁽⁹⁾.

Our results show that the total GCL thickness, as well as the GCL thickness in the both upper in addition to lower quadrants of both eyes, were negatively correlated with DM illness duration. Similarly, **Gundogan et al.** discovered a negative as well as statistically significant correlation among disease duration and RNFL abundance over the world⁽¹⁰⁾.

This discrepancy amongst trials may be attributable to the fact that retinal neurodegeneration in young children is likely caused by chronic dysregulation of blood glucose rather than the length of DM. Therefore, intensive insulin treatment for type 1 diabetes in young children may prevent or halt neurodegeneration by effectively controlling blood glucose levels.

Our study results have revealed that the level of HbA1C had significantly negative connection with total, superior and inferior quadrant GCL thickness in both eyes. This is according to the results of the **Mikhail et al.** study, which discovered that in the group of uncontrolled diabetics (those with HbA1c levels higher than 9%), there was a significant negative association between the superior, average and inferior GCC quadrant thickness and a positive relationship between focal loss volume, whereas in the group of controlled diabetics (those with HbA1c levels lower than 7%),

there was a positive association amongst the average and inferior G⁽¹⁷⁾.

In the current trial, there was statistically significant lower GCL thickness in OCT in uncontrolled diabetes mellitus group than controlled DM group, and there was lower GCL thickness in OCT in controlled diabetes mellitus group than healthy control group however this difference was statistically insignificant.

It is probable that m-GCIPL thinning is an excellent marker for tracking DRN due to the potential predictive relevance it may have for the development of DR. It is feasible that in NDR eyes, diabetic retinopathy may initially manifest itself in RGC dendrites along with cell bodies at the macula (i.e., the ganglion cell layer as well as the inner-plexiform layer), and that after diabetic retinopathy has developed, it may then principally manifest itself in RGC axons (i.e., the p-RNFL layer). Alternately, the weakening of the p-RNFL could be concealed by vascular leakage brought on by the breach of the blood-retinal barrier and swelling of glial cells within peripapillary arteries. This would be the more likely scenario. Due to this, the weakening of the p-RNFL could not be noticeable during the early stages of DR.

In our study, there was statistically significant lower GCL thickness in OCT in DM with diabetic retinopathy group than diabetes mellitus with NO DR group. This is consistent with the meta-analysis by **Jansson et al.**, which included only 8 trials with small sample sizes and found that diabetic people with mild diabetic retinopathy or no DR may have retinal thinning. Based on these results, the authors hypothesized that retinal neurodegeneration precedes overt retinal vasculopathy as an early stage of DR⁽¹⁸⁾.

In our trial, there was lower GCL thickness in OCT in DM without DR group than healthy control group, however, this difference was statistically insignificant except for superior GCL, and there was statistically alteration among the three DR severity levels regarding all OCT measurements, and when comparing each two groups separately there was statistically significant lower GCL thickness in moderate and severe DR than those with mild DR all OCT measurements.

Ng et al. indicated that RGC neurons are more susceptible to injury in diabetic participants than healthy controls before the emergence of evident microvascular DR lesions, as well as that this damage progresses with the development of more severe types of diabetic retinopathy. People with diabetes without clinically obvious DR had OCT measurements consistent with GC-IPL as well as RNFL thinning, but not outer retinal thinning. The GC-IPL was also less thick among individuals with moderate to severe DR compared to those with diabetes but no DR.

In the diabetic population, GC-IPL was thinner in those with moderate to severe diabetic retinopathy compared to those without diabetic retinopathy. It indicates that RGC loss is gradual in subsequent severe

types of diabetic retinopathy development. RGC loss is represented by GC-IPL thinning, which begins before microvascular lesions become visible⁽¹⁹⁾.

A prior trial conducted by **Demir et al.** utilizing several OCT techniques to quantify various RGC parameters, such as ganglion cell complex thickness, did not find a significant association among the loss of RGC and a rise in the severity of DR⁽²⁰⁾.

Our research does include certain caveats and restrictions. To begin, we conducted research on a limited sample of people with diabetes as well as healthy control volunteers. Due to the low number of participants, the statistical power to distinguish small distinctions across groups was severely compromised. Second, because we only had a small number of patients involving severe diabetic retinopathy, we were unable to conduct a specific investigation of the link between the two conditions. Last but not least, a test of the visual field was not carried out during this research project since we did not anticipate a significant loss of ganglion cells.

CONCLUSION

Diabetes has an early impact on the organization of the neuronal retinal layers, which in most of the patients under study even occurred before retinal vascular alterations and vision impairment. Comparing diabetic type I individuals to healthy controls revealed that the majority of the GCC quadrants were statistically significantly smaller in diabetes type I people. There was a significant inverse correlation among the width of the GCL and the levels of HA1C, as well as the duration of DM.

DECLARATIONS

- **Consent for publication: I attest that all authors have agreed to submit the work**
- **Availability of data and material: Available**
- **Competing interests: None**
- **Funding: No fund**
- **Conflicts of interest: no conflicts of interest**

REFERENCES

1. **Barcala-Tabarozzi A, Castro C, Dewey R et al. (2013):** Cell-based interventions to halt autoimmunity in type 1 diabetes mellitus. *Clin Exp Immunol.*, 171(2):135-46. doi: 10.1111/cei.12019.
2. **Yi B, Huang G, Zhou Z (2016):** Different role of zinc transporter 8 between type 1 diabetes mellitus and type 2 diabetes mellitus. *J Diabetes Investig.*, 7(4):459-65. doi: 10.1111/jdi.12441.
3. **Ostrauskas R, Žalinkevičius R, Jurgevičienė N et al. (2011):** The incidence of type 1 diabetes mellitus among 15-34 years aged Lithuanian population: 18-year incidence study based on prospective databases. *BMC Public Health.* 813:1-10. doi: 10.1186/1471-2458-11-813
4. **Tang J, Kern T (2011):** Inflammation in diabetic retinopathy. *Prog Retin Eye Res.*, 30(5):343-58. doi: 10.1016/j.preteyeres.2011.05.002.
5. **Chen Y, Li J, Yan Y, Shen X (2016):** Diabetic macular morphology changes may occur in the early stage of diabetes. *BMC Ophthalmology.* 16(12): 1-7. doi: 10.1186/s12886-016-0186-4.
6. **Pickard G, So K, Pu M (2015):** Dorsal raphe nucleus projecting retinal ganglion cells: Why Y cells? *Neurosci Biobehav Rev.*, 57:118-31. doi: 10.1016/j.neubiorev.2015.08.004.
7. **Do M, Yau K (2010):** Intrinsically photosensitive retinal ganglion cells. *Physiol Rev.*, 90(4):1547-81. doi: 10.1152/physrev.00013.2010.
8. **Burgess P, MacCormick I, Harding S et al. (2013):** Epidemiology of diabetic retinopathy and maculopathy in Africa: a systematic review. *Diabet Med.*, 30(4):399-412. doi: 10.1111/j.1464-5491.2012.03756.x.
9. **Van-Dijk H, Verbraak F, Kok P et al. (2010):** Decreased retinal ganglion cell layer thickness in patients with type 1 diabetes. *Invest Ophthalmol Vis Sci.*, 51(7):3660-5. doi: 10.1167/iovs.09-5041.
10. **Gundogan F, Akay F, Uzun S et al. (2016):** Early neurodegeneration of the inner retinal layers in type 1 diabetes mellitus. *Ophthalmologica.* 235(3):125-32. doi: 10.1159/000442826.
11. **Frank R (2004):** Diabetic retinopathy. *N Engl J Med.*, 350:48-58 DOI: 10.1056/NEJMra021678.
12. **Cheung N, Mitchell P, Wong T (2010):** Diabetic retinopathy. *Lancet.* 376(9735):124-36. doi: 10.1016/S0140-6736(09)62124-3.
13. **Antonetti D, Klein R, Gardner T (2012):** Diabetic retinopathy. *N Engl J Med.*, 366(13):1227-39. doi: 10.1056/NEJMra1005073.
14. **Mahmoud D, Abdulwahab A, Ali D (2018):** Correlation of peripapillary retinal nerve fiber layer thickness and ganglion cell complex thickness with the severity of diabetic retinopathy. *Delta J Ophthalmol.*, 19:117-121. Doi: 10.4103/djo.djo_69_17.
15. **Martin P, Roon P, Van E et al. (2004):** Death of retinal neurons in streptozotocin-induced diabetic mice. *Investigative Ophthalmology and Visual Science.*, 45: 3330-3336. doi:https://doi.org/10.1167/iovs.04-0247.
16. **Chen J, Kardon R (2016):** Avoiding clinical misinterpretation and artifacts of optical coherence tomography analysis of the optic nerve, retinal nerve fiber layer, and ganglion cell layer. *J Neuroophthalmol.*, 36(4):417-438. doi: 10.1097/WNO.0000000000000422.
17. **Mikhail M, Saif M, Mohammad S (2021):** Correlation of retinal nerve fiber layer and ganglion cell complex thickness with glycosylated hemoglobin in diabetic patients. *Delta Journal of Ophthalmology.* 22(1):34. Doi:10.4103/DJO.DJO_57_20.
18. **Jansson R, Raeder M, Krohn J (2015):** Photopic full-field electroretinography and optical coherence tomography in type 1 diabetic retinopathy. *Graefe's Archive for Clinical and Experimental Ophthalmology.* 253(7):989-997. DOI 10.1007/s00417-015-3034-y.
19. **Ng D, Chiang P, Tan G et al. (2016):** Retinal ganglion cell neuronal damage in diabetes and diabetic retinopathy. *Clinical and experimental ophthalmology.* 44(4):243-250. https://doi.org/10.1111/ceo.12724
20. **Demir M, Oba E, Sensoz H et al. (2014):** Retinal nerve fiber layer and ganglion cell complex thickness in patients with type 2 diabetes mellitus. *Indian J Ophthalmol.*, 62(6):719-20. doi: 10.4103/0301-4738.136234.