

## A Morphologic and Morphometric Study of the jugular foramen of the adult human skulls: an osteological study in Upper Egypt.

By

Mohammed, A.Desouky (a),Salwa, M. Ouies (b) andAbeer,F. Abd EL Naeem(c).

(a) Professor of anatomy & Embryology. Faculty of Medicine. Al-MiniaUniversity.

(b) Lecturer of anatomy& Embryology. Faculty of Medicine .SohagUniversity.

(c)Assistant lecturer.Anatomy & Embryology department. Sohag University.

### Abstract:

**Background:**Jugular foramen is one of the foramen at the base of skull lies between the occipital bone and the petrosal portion of the temporal bone. It allows passage of important nervous and vascular elements, such as the glossopharyngeal, vagus accessory nerves, and the internal jugular vein. Glomic tumors, schwannomas, metastatic lesions and infiltrating inflammatory processes are associated with this foramen, which can account for injuries of related structures. Variability in anatomical aspect of jugular foramen has been studied by many workers in different part of the world.

**Aims & Objective:**Tostudy the variability in shape and size of jugular foramen which has clear cut relationshipwith size of internal jugular vein and presence or absence of dome.

**Materials andMethods:** Present study has been designed to study on 100 skulls (100×2=200 foramen).

**Result:** In the study Bilateral presence of dome has been found in 98% of cases. Both unilateral and bilateral complete septation have been observed. The mean diameters on the right side were more than the left.

**Conclusion:**The clinical significance of jugular foramen is very important during surgeries. Therefore, the dimensions of jugular foramen is very much necessary.

**Key words:**Jugular foramen,internal jugular vein,dome,skull.

### INTRODUCTION

The jugular foramen is considered as the complex foramen due to itsirregular shape, surgical access, and contribution of two bones in itsformation (Kumar et al., 2015). It lies between the occipital bone andpetrous part of temporal bone(Pereira et al., 2010).

It is divided into three compartments:(petrosal, sigmoid and intrajugular part) according to the structures whichpassed through the jugular foramen (Vaidyanathan et al., 2014).Petrosal portion contains the inferior petrosal sinus. Sigmoid portionreceives the sigmoid sinus. Intrajugular portion contains cranial nervesIX, X and XI (Vijisha et al., 2013 and Sakthivel et al., 2014).

A dome is a bony roof present in the Jugular foramen(Patel and Mehta,2014).The foramen can have many variations in its shape and size. Most of theintracranial and extracranial lesions of posterior cranial fossa may affectthe structures in jugular foramen in addition to intrinsic abnormalities(Khanday et al., 2013).

The so-called anomalies of the jugular bulb such as glomic tumors arerelated with the jugular foramen, as they come in direct contact withstructures that cross it, like the internal jugular vein, the internal carotidartery, and the cranial nerves (Pereira et al., 2010 and Gupta et al.,2014). Moreover, Pathologies like meningiomas, paraganglionomas,schwanomas and

other inflammatory lesions of inner ear are known to affect the structures in jugular foramen (Khanday et al., 2013).

**MATERIALS AND METHODS**

The present study was undertaken on 100 dry, adult human skulls irrespective of sex, randomly selected obtained from Anatomy department of medical College of Qena, Sohag, Assiut and El-Menya university. The observations were measured on both Right & Left sides in each skull measured.

- The antero-posterior and transverse diameter of the foramen were measured (Kumar et al., 2015). The average, largest, and smallest sizes of the different foramina were listed.
- observation for septations: Complete or incomplete (Gupta et al., 2014).
- Observation of presence or absence of dome (Patel and Mehta, 2014).

**RESULTS**

**A) Dome:** All of skull had dome on the right foramen but only 89% of skulls had dome on the left side (figure 4a).

**B) Diameters:** The jugular foramen had the following diameters:  
On the right side: AP ranged from: 5.26 to 16.83mm. Transverse diameter ranged from 7.66 to 17.54mm.  
On the left side: AP diameters ranged from 5.43 to 13.4mm. Transverse diameter ranged from 6.35 to 17.49mm.

The mean AP and T diameters were shown in (Table 1) and (Figure 1):

	Mean AP.	Mean Transverse
Right	9.79± 2.25mm**	12.84±2.24mm*
Left	8.95±1.94mm**	11.97±2.52mm*

**Table ( 1):** mean AP and T diameters of jugular foramen in 100 adult skull.

\*p<0.05(significant) and \*\*p<0.01(highly significant).

There was highly significant increase in AP. diameter in the right side in comparison to left side p= 0.01 (p≤0.05).

Also there was significant increase in transverse diameter in right side in comparison to left side p=0.024 (p≤0.05).

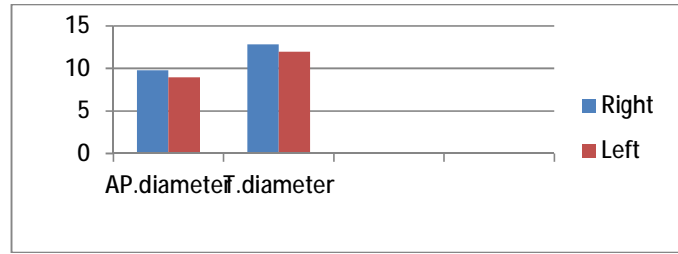
All these data were measured using a digital vernier calliper with an accurate resolution up to 0.01mm (Sethi et al., 2014).

**Morphometric and Statistical analysis:**

The metric data was analysed statistically with SPSS version 16 (Sethi et al., 2014).

Statistical evaluations were performed for each measurement:

- The mean, ± standard deviation of mean).
- The student comparisons t-test, and value were performed to determine if there was a significant difference between the right and left sides (Sangari et al., 2015). Finally the significance was considered according to the level of significance p value as follows:  
P ≥ 0.05 non significance.  
P\* ≤ 0.05 significant.  
P\*\* ≤ 0.01 highly significant.  
P\*\*\* ≤ 0.0001 very high significant.



**Figure (1):** .mean AP and T diameters of jugular foramen in 100 adult skulls.  
C) Septation: on the right side: 22% had complete septum,71% had partial septation and 7% no septum was present. On the left side: 20% complete septation, 77% had partial septation and 3% no septation(Figure 2,3and 4b,c,d).

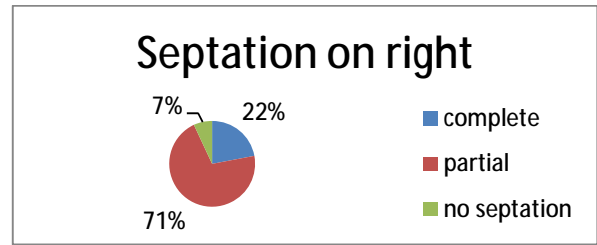


Figure (2): Septation of right jugular foramen in 100 adult skull.

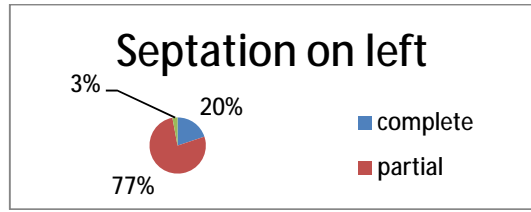



Figure (3): Septation of left jugular foramen in 100 adult skull.



**Figure (4):** (A)dome (B)and(C) complete separation of jugular foramen. (D) partial separation of jugular foramen.

**DISCUSSION**

The jugular foramen is difficult to understand and to access surgically; the problems in exposing this foramen are due to its deep position and the adjacent structures such as carotid artery anteriorly, the facial nerve laterally, hypoglossal nerve medially and vertebral artery inferiorly (Gupta et al., 2014).

The size and shape of the jugular foramen are associated to the size of the internal jugular vein and the presence or absence of a dome for superior bulb.The right foramen is frequently larger than the left. The dissimilarity in size of the two internal jugular veins is already noticeable in the human embryo at the 23 mm stage

and perhaps is due to the differences in the pattern of development of the right and left brachiocephalic veins (**Khanday et al., 2013; Shanmugam and Babu, 2015**).

The mean AP measurements and transverse measurements in the present study were 9.79 and 8.95.5mm on right and 12.84 and 11.97mm on left side respectively. They were near to the figures reported by **Idowu, 2004** who found the mean transverse diameter is 13.9 mm on the right side, and 14.11 mm on the left side, and the mean width of 10.2 mm on the right side, and 9.57 mm on the left side in Nigerian skulls.

**Pereira et al., 2011** studied total 111 skulls (of southern Brazil) and it was noticed that mean transverse diameter was 15.82mm on right side and 15.86mm on left side; mean sagittal diameter was 9.21mm on right side and 8.65mm on left side.

Another study was done by **Sakthivel et al., 2014** on 46 jugular foramen revealed that the mean AP diameter on right side was 10.06mm, on the left it was 8.83mm, while transverse diameter on the right was 11.58mm, on the left was 10.74mm. Also **Gupta et al., 2014** who made a study 100 jugular foramen said that the mean AP diameter on right side was 11.22mm, on the left side was 9.52mm. The mean transverse diameter on the right was 16.52, on the left was 16.02mm.

According to **Wysocki et al., 2006** results variation can be explained by racial and individual factors. As to the individual factors, these authors mention the significant correlation between the size of the jugular foramen with skull volume, thus pointing to the significance of cranial capacity for brain venous drainage.

The obtained results regarding complete or partial septum which were 21.8% complete, 70.9% partial and 7.2% no septation, are far from **Patel**

**and Singel, 2007** who found complete septation on the right side in 23.1% of the foramina, and 17.6% in foramina of the left side, besides partial septa in 49.5% on the right side and 59.3% on the left side. **Kumar et al., 2015** found that complete septation on the right side was in 16.17% of foramina and on the left was 8.82%.

As to presence of domed bony roof in the jugular foramen (100% R, 98% L) the results are different from the result of **Sturrock, 1988** who reported 30% on the right side, and 6% on the left side, and results are also different from those done by **Patel and Singel 2007 and Khanday et al., 2013** who found that the dome was present in 60% of the right foramina 49% of the left foramina and absent bilaterally in 25.3% of skulls. The size of the dome is for accommodation of superior jugular bulb of internal jugular vein.

Tumors involving jugular foramen and nearby structure requires microsurgical approach to enter into this region. In most of the cases, we have to drill the nearby bones around the jugular foramen for proper exposure. And the tumor tends to alter the normal anatomy of the foramen by eroding and invading it. Therefore, it is not possible to have correct anatomic visualization of the foramen in presence of such pathologies. Hence, a detailed knowledge of the jugular foramen is needed to all the neurosurgeons while doing surgery in this region (**Singla et al., 2012; Gupta et al., 2014**).

## CONCLUSION

The present study observed variation in the size of jugular foramen sizes. The foramen were larger on the right than the left in Upper Egypt. The large variation of the JF equally reported in various studies is possibly due to constitutional, racial and/or genetic factors. Comparison of some parameters was impaired by the scarce

data regarding genus and the different approaches to measure this foramen as well.

## REFERENCES

- 1- **Idowu, O.E. (2004):** The jugular foramen - A morphometric study. *Folia Morphol (Warsz)*, 63:419–22.
- 2- **Gupta, C., Kurian, P., Seva, K.N., Kalthur, S.G. and D'Souza, A. S. (2014):** A morphological and morphometric study of jugular foramen in dry skulls with its clinical implications. *J Craniovertebr Junction Spine*, 5 (3): 118–121.
- 3- **Khanday, S., Subramanian, R.K., Rajendran, M., Hassan, A.U. and Khan, S.H. (2013):** Morphological and Morphometric Study Of Jugular Foramen In South Indian Population. *Int J Anat*, Vol 1(3):122-27.
- 4- **Kumar, A., Ritu and Akhtar, J., (2015):** Variations in jugular foramen of human skull. *Asian J of Med Sci*, 6 (2): 95-98.
- 5- **Patel, R. and Mehta, C.D. (2014):** Morphometric study of Jugular Foramen at base of the skull in South Gujarat region. *IOSR Journal of Dental and Medical Sciences*. 13(9): 58-61.
- 6- **Patel, M.M. and Singel, T.C. (2007):** Variations in the structure of the jugular foramen of the human skull in Saurashtra region. *J Anat Soc India*, 56(2): 34-37.
- 7- **Pereira, G.A., Lopes, P.T. and Santos, A.M. (2010):** Morphometric aspects of the jugular foramen in dry skulls of adult individuals in Southern Brazil. *J Morphol Sci*, 27:3–5.
- 8- **Sakthivel, K. M., Balaji, T. K., Moni, A. S., Narayanan, G. Sathish and Kumar, K. (2014):** Study of Jugular Foramen – A Case Report. *Journal of Dental and Medical Sciences*, 13, (8): 63-67.
- 9- **Sangari, S.K., Dossous, P.M. Heineman, T. and Mtui, E.P. (2015):** Dimensions and Anatomical Variants of the Foramen Transversarium of Typical Cervical Vertebrae. *Anatomy Research International*.
- 10- **Shanmugam, J. and Babu, K.Y. (2016):** Morphometric Analysis of Jugular Foramen. *International Journal of Science and Research (IJSR)*, 5 (8):160-162.
- 11- **Sethi, M., Vasudeva, N. and Mishra, S. (2014):** Study of foramen transversaria of first cervical vertebrae and its variations. *OA Anatomy*, 17;2(3):25.
- 12- **Singla, A., Sahni, D., Aggrawal, A., Gupta, T. and Kaur H. (2012):** Morphometric study of the jugular foramen in North West Indian population. *J Postgrad Med Educ Res.*, 46:165–71.
- 13- **Sturrock, R.R. (1988):** Variations in the structure of the jugular foramen of the human skull. *Journal of Anatomy*, 160(49):227- 230.
- 14- **Vaidyanathan, V., Nair, D., Juvekar, S. L. and D'Souza, C. (2014):** Jugular foramen chondrosarcoma. *Ind J Otol*, 20(2): 86-88.
- 15- **Vijisha, P., Bilodi, A.K. and Lokeshmaran. (2013):** Morphometric study of jugular foramen in Tamil Nadu region. *Natl J Clin Anat*, 2:71–4.
- 16- **Wysocki, J., Reymond, J., Skarzynski, H. and Wrobel, B. (2006):** The size of selected human skull foramina in relation to skull capacity. *Folia Morphologica*, 66: 301-308.

