

Assessment of prosthetic complications of customized and electrical welded frameworks in maxillary implant fixed detachable prosthesis (split mouth study)

Nora Mohamed Sheta¹

Aim: This study was conducted to assess prosthetic complications, passive fit, chair side visits numbers and duration, cost and cost effectiveness of customized and electrical welded frameworks in maxillary implant fixed detachable prosthesis.

Materials and Methods: This split mouth study was performed on six completely edentulous patients received maxillary fixed detachable prosthesis, where Group I: customized framework while Group II: electric welded framework. During prosthetic construction period for both frameworks, passive fit was done using gone screw test. Assessments of prosthetic complications were evaluated 3 and 6 months later. Numbers and duration of visits, total cost and cost effectiveness were calculated.

Results: Comparison between both groups revealed insignificant difference regarding all prosthetic complications. After 3 months and 6 months. The evaluation of the passive fit revealed that in customized framework was significantly higher than electric welded group in yes, while was significantly lower in no. In group I C/E ratio (93.5) was higher than group II (85.7), as the total cost in group I was (9350), while in group II was (7150). In number of needed visits, group I (6.83 ± 0.75) was significantly higher than group II (3.16 ± 0.41) as $P < 0.05$. In duration of needed visits, group I (330 ± 11.3) was significantly higher than group II (150 ± 8.5).

Conclusion: Maxillary fixed detachable prosthesis supported by customized or electric welded framework show no difference regarding the prosthetic complication while the electric welded framework shows highly passive fit when compared to the customized one. The cost, cost effectiveness, numbers of visits are lower and visits duration is shorter in electric welded framework when compared to the customized one.

Keyword: fixed detachable. customized electric welded. prosthetic complication passive fit

1. Associate Professor of Oral and Maxillofacial prosthodontics Department, Faculty of Dentistry, Cairo University, Cairo, Egypt.

Corresponding author: Nora Mohamed Sheta, email: nora.sheta@dentistry.cu.edu.eg

Introduction:

Treatment planning of edentulous maxilla for implant placement faced much difficulty to select a favorable prosthetic option. There are several factors to determine the type of the prostheses used; the available soft tissue and bone (quantity and quality), lip support, smile line, interarch space, phonetic and esthetic demands.^{1,2} The location number and distribution of the implants, the cost and time required to fabricate and maintain the prosthesis considered factors for selection between fixed and removable implant-retained prostheses.^{3,4}

Fixed detachable prosthesis is defined as "A fixed dental prosthesis that replaces the entire dentition and accompanying structures of the maxillae or mandible; it cannot be removed by the patient."⁵ it offers several advantages, preservation of the underlying bone compare to the conventional complete denture as it will be supported by multiple implants that allows favorable stress distribution, the characteristic of a fixed prosthesis and retrievable which improve patient satisfaction compared to removable options.⁶

The most difficult aspect of fixed detachable frameworks has always been achieving passivity. Lack of passivity of the prosthesis is the most common cause of the prosthetic complication. It produces internal stresses in the framework of the prosthesis, the implants, and the bone surrounding the implant resulting mechanical complications as screw loosening, screw fracture, or framework fracture, as well as prosthesis fracture or biological complications.⁷ In addition to that the lack of passive fit will cause frictional and misfit resistance created within the screw if there are minor differences between the two mating components. To compensate for such strain at the interface, the screw bends and deforms, resulting in a lower clamping force. As a result of the lesser clamping force,

subsequent screw loosening or fatigue fracture will occur, so passive fit is essential in screw retained prosthesis.⁸

The methods of fabrication of frameworks of fixed detachable prosthesis have different options. Traditional 1-piece casting, casting and laser, electric welding, casting and spark erosion, copy, computer numeric-controlled milling, or computer-aided design and computer-aided manufacturing are all options for fabricating a prosthetic framework.⁹

The customized metal framework with cobalt chromium alloy one of the most used design and material to support the implant fixed detachable prosthesis. it is reasonably priced, biocompatible, and good mechanical qualities. The high modulus of elasticity improves the stress distribution of the framework and reduces its thickness, allowing more room for prosthetic teeth and denture base resin,¹⁰ however the inherent property of the casting technique makes full-arch framework fabrication using Co-Cr alloys in conventional techniques challenging.¹¹

The "Electro welded methods for intraoral welding are described in the literature. It depends on the formation of an electric arc between two electrodes underneath an argon gas flux used to connect implants to bars. It produces high strength welding devices joint compared to other technique."¹²

Hence, this study was conducted to compare the prosthetic complications, the passivity, cost effectiveness and number of visits between the cast metal framework and electric welded framework under sectional fixed detachable maxillary prosthesis (split mouth study) during follow up period 3 and 6 months

Materials and Methods

This split mouth study was performed on six completely edentulous patients

received maxillary fixed detachable prosthesis, where Group I: customized framework while Group II: electric welded framework.

The patients were selected according to a strict inclusion and extrusion criteria for implant placement from outpatient clinic of Prosthodontic Department, Cairo University. Patients or representatives must provide written, informed consent before any study procedures. All patients should have sufficient interarch space to allow room for framework construction. Conventional complete dentures were delivered to all the patients.

Implant installation

The patient's maxillary denture was duplicated to be used as a guide for the fabrication of radiographic and surgical templates. CBCT were done for proper treatment planning for implant position.

Six implants of 4.1 mm x 10mm dimension (Biomate medical devices technology co., ltd, Taiwan (R.O.C) was placed in the maxillary arch of each patient with predefined positions (15, 13, 11, 21, 23, and 25) with the help of a surgical template. A submerged healing protocol was followed after all implants were installed with optimum primary stability (insertion torque 35N/cm). The maxillary denture was modified to serve as an implant-supported interim prosthesis.

Framework construction

After a 4-month osseointegration period, second-stage surgery was performed and healing abutments were placed. (Fig 1) Each eligible patient received both treatments and randomly allocated to the right and left side of the arch (each patient served as his own control, the customized and welded framework). Each type of the framework was constructed on 3 implants in one side of the arch

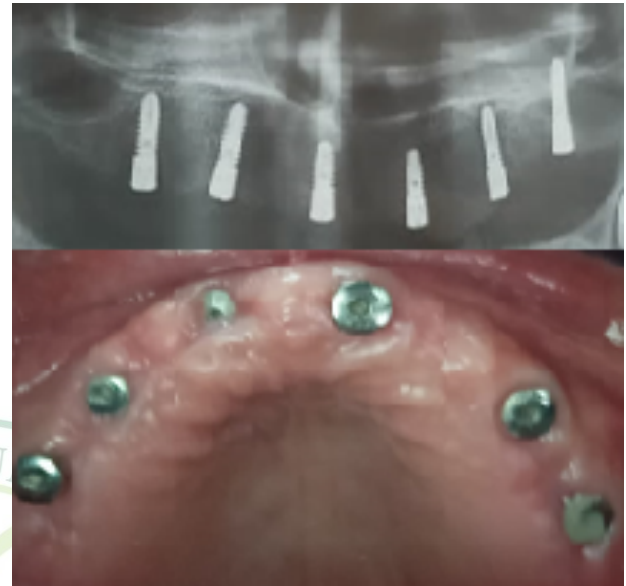

Fig 1: six implants placed in predetermined position in the maxilla

Group I: customized framework construction

An open tray impression was done. Impression coping were fastened over 3 implants on one side of patient's arch, an unsplinted impression was taken using addition silicone impression material in a single step manner with putty and light consistency. (Zhermack Spa, Badia Polesine, Rovigo, Italy)

The implant analogues were fastened over the impressions coping (impression post open tray, Biomate Medical Devices Technology Co., Ltd, TAIWAN (R.O.C) injecting gingival mask then pouring a stone model. Over the obtained stone model, splinting of the open tray impression copings was performed using Duralay resin to obtain a jig that will be further separated and resplinted intraorally. A splinted pick-up impression was carried out inside the patient's mouth with the re-splinted jig.

The new impression was poured into extra-hard stone after fabricating a gingival mask. Acrylic verification jig was constructed over the impression coping to verify the accuracy of the final impression.

One screw test is used to check passivity inside the patient mouth. If the one screw test revealed a non-passive structure, jig separation and intraoral assemblage was performed. In this case the cast around the non-passive analogue is grinded and reattached it in its new position with dental stone.¹³

An occlusal silicon index (Sil-Tech, Ivoclar Vivadent, Amherst, NY, USA) covering the incisal edges and the occlusal half of the mandibular denture teeth set-up was fabricated to facilitate accurate dimension of the customized framework.

On the verified master analogue model, UCLA abutment (UCLA screw-retained dental abutment, Biomate, Taiwan) fastened over implant analogues. Waxing up, spurring and casting of the customized frameworks were done (Fig2). The resultant framework was tried inside the patient's mouth to insure passivity of fit. In case of framework misfit, separation was performed using a disc, followed by intraoral splinting using Duralay resin and soldering. After framework soldering, another try-in will be done to ensure framework fit

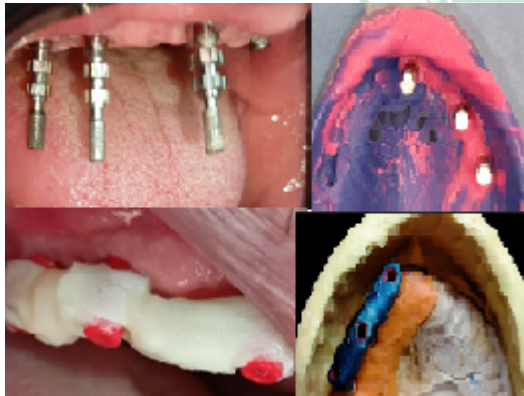

Fig 2 steps of customized framework

Group II: Electric welded framework construction

A shaped welded abutments (Shaping screw-retained dental abutment, Biomate, Taiwan) were fastened on the 3 implants on

the other side of patient arch after removal of the healing cap. A preexisting or prepared flat surface area of the abutment served as the welding point. A round titanium bar (1.2 mm in diameter) was shaped following the curvature of the implants positioned.

The welding processes using the Electrical Syncrystallization Unit (JDweld sncrystalization unit, Modena Italy) take place and protected by an argon gas supply. The equipment allows the welding of metallic elements directly intraorally. The titanium bar and the prepared side of the shaped abutment to be welded were placed between the two electrodes of a welding clamp. The energy is transferred to the electrode being in contact with the parts to weld, warms up to the point of fusion, good tissue retraction and protection was done and using a current coolant to eliminate harmful effect on soft tissue. The welding cycle is started first by Pre-gas (an oxygen-free welding allows prior to the actual fusion) then welding, and finally post-gas to ensure the absence of oxygen and subsequent oxidation during cooling. Sound from the machine is produced in few seconds indicated the ending of welding process. The electric welded framework is created by welding the titanium bar to the shaped abutments. Checking of the passive fit using one screw test was done as mentioned before.

Pick up of the complete denture

The patient's maxillary complete dentures were modified to be a fixed detachable prosthesis. The final pick-up of the framework into the denture was done using Luxa pick-up material (Luxa pick-up material, DMG Chemisch-Pharmazeutische, Hamburg | Germany). After pick up, the prosthesis unscrewed from the implant and now the both frameworks embedded inside the denture. Then the final prosthesis was sectioned at the mid line resulting in two separate super structures. And the palatal surface was removed. Finishing and

polishing was done then finally the prosthesis screwed again into the implants (Fig 3).

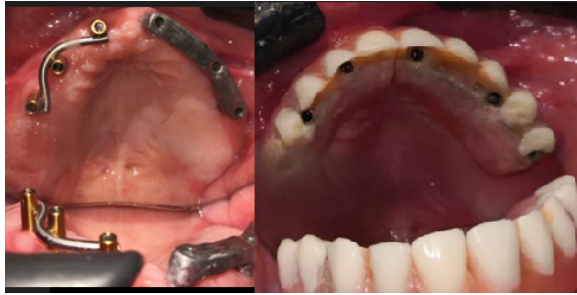


Fig 3: Electrical welded and customized framework and final pick up prosthesis

Patients were informed about the importance of following the instructions, attending follow up visits and how to maintain good oral hygiene.

Outcomes were reported as a binary data for each patient, passive fit of both frameworks were checked during both frameworks construction period. Visual inspection for the prosthesis was done without any intervention in case of any signs or symptoms of complications. If either visual inspection or patient complaint revealed any prosthetic complication, the clinician transacted with the complication with the proper action as the following: Over all prosthesis loosening (due to screw loosening) treated by screw Re-tightening. Prosthetic/abutment screw fracture was managed by screw retrieval then screw replacement. Tooth fracture was treated by replacement of another tooth. The follow up period was 3 and 6 months. The number and chair side time of patient visits from the second stage surgery were recorded and also the cost effectiveness of both treatment modalities was evaluated. The costs were comprised of implants materials, and prosthodontic treatment, as well as laboratory fees.¹⁴ In addition, treatment time and health care resource consumption were recorded in visits during the follow up period. The cost-effectiveness ratio (The C/E ratio) represents the difference in costs divided by the

difference in effectiveness (survival percentage of prosthesis (no complication) over a time of the prosthetic procedures after 6 months.¹⁵

Statistical analysis:

All quantitative data were presented as mean & standard deviation, while qualitative data were presented as frequency and percentage. Statistical analysis was performed with SPSS.¹⁶ (Statistical Package for Scientific Studies), Graph pad prism & windows excel

Results

1-Prosthetic complications

Assessment of the prosthetics complication during the follow up period 3 month and 6 month as the following:

Screw looseness, only 1 case revealed screw looseness (16.66%) in customized framework group, while in electric welded group there was no screw looseness (0%)

Screw fracture: There was no screw fracture observed in both groups (0%).

Teeth fracture: customized framework group, there was no teeth fracture observed (0%) while only one case revealed teeth fracture in electric welded (16.6%)

Comparison between both groups was performed by using Chi square test which revealed insignificant difference as $P > 0.05$, regarding all prosthetic complications. Comparison between yes & no revealed that no was significantly higher than yes in both groups after 3 months and 6 months regarding all complications as shown in table 1

Table (1): Frequency and percentage of different prosthetic complications

			Group I (customized Framework)		Group II (Electric Welded framework)		P value (Chi square test)
			N	%	N	%	
At 3 months	Screw looseness	Yes	1	16.66	0	0	0.31
		No	5	83.44	6	100	0.31
		P value	0.026*		0.0009*		
	Screw fracture	Yes	0	0	0	0	-----
		No	6	100	6	100	1.000
		P value	0.0009*		0.0009*		
Teeth fracture	Yes	0	0	1	16.66	0.31	
	No	6	100	5	83.44	0.31	
	P value	0.0009*		0.0009*			
At 6 months	Screw looseness	Yes	1	16.66	0	0	0.31
		No	5	83.44	6	100	0.31
		P value	0.0009*		0.0009*		
	Screw fracture	Yes	0	0	0	0	-----
		No	6	100	6	100	1.000
		P value	0.0009*		0.0009*		
Teeth fracture	Yes	0	0	1	16.66	0.31	
	No	6	100	5	83.44	0.31	
	P value	0.0009*		0.0009*			

2-Passive fit

The Evaluation of the passive fit was done using one screw test during framework construction for both groups. In customized framework group yes (100%) was significantly higher than no (0%), while in group electric welded group no (100%) was significantly higher than yes (0%). Also, comparison between both groups revealed that in customized framework was significantly higher than electric welded group in yes, while was significantly lower in no with p value <0.0001 as shown in figure 4

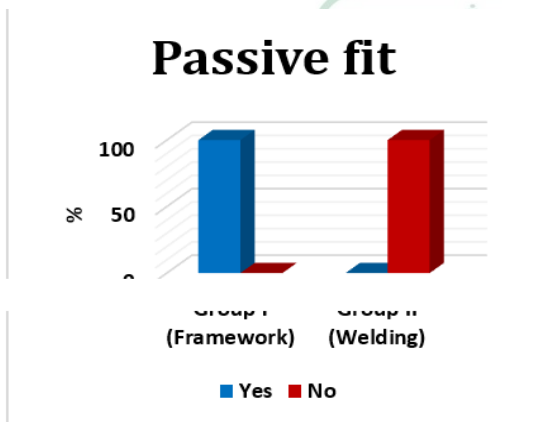


Fig4: Bar chart representing passive fit of both groups

3-Cost effective analysis (C/E)

The C/E ratio was calculated by dividing the average cost by the percentage of prosthetic success after 6 months (no complication). In group I C/E ratio (93.5) was higher than group II (85.7), as the total cost

in group I was (9350), while in group II was (7150). Also, survival rate in group I was (100%), while in group II was (83.4%) as recorded in table 2 and figure 5&6

Table (2): Total cost L E, survival rate and cost/effectiveness ratio in group I & II:

		Cost	Survival rate	C/E ratio
Group I customized Framework	Implant abutment lab	7000 LE	100	93.5
	Transfer and analog	2100 LE		
	Complete denture	250 LE		
	Total	9350 LE		
Group II Electric welded framework	Group II(Electric Welded framework)	6000 LE	83.4	85.7
	wire electric welding machine	900 LE		
	Complete denture	250 LE		
	Total	7150 v		

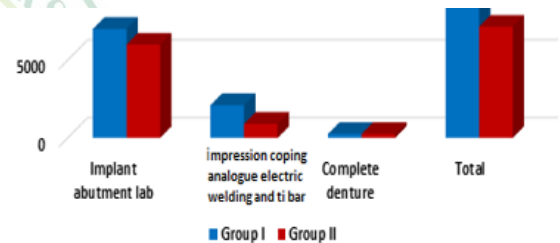


Figure (5): Bar chart representing the cost and total cost in both groups.

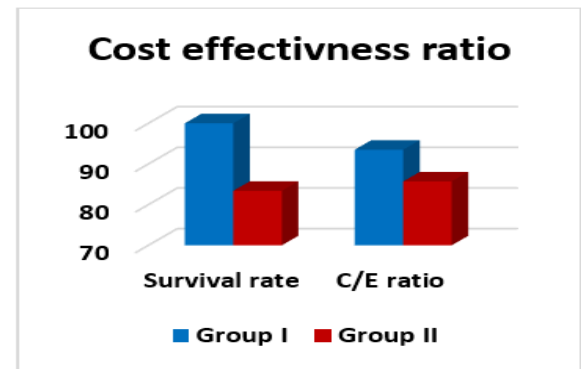


Figure (6): Bar chart representing C/E ratio and survival rate in both groups.

4-Evaluation of needed visits

In number of needed visits, group I (6.83 ± 0.75) was significantly higher than group II (3.16 ± 0.41) as P < 0.05. In duration of needed visits, group I (330 ± 11.3) was significantly higher than group II (150 ± 8.5) as P < 0.05.

Discussion

The optimum numbers of implants placed in maxilla to support fixed detachable prosthesis are six implants without any cantilever. It allows more distribution that resulting more predictable prosthodontic survival.¹ This study is a split mouth; the prosthesis is segmented from the midline with both treatment modalities. Implants with sectional prosthesis have been reported in the literature with high prosthetic success rate comparable to one piece prosthesis.¹⁶

During the construction period for both group, testing of the passivity were done using one screw test. Comparison between both groups revealed that in customized framework was significantly higher than electric welded group in yes, while was significantly lower in no with p value <0.0001. Passive fit is considered to be one of the most important requirements for the integrity of the entire prosthetic structure. to avoid unevenly distributed stresses which led to complications.⁷ To provide passive fit or a strain-free superstructure, the framework should, theoretically, induce absolute zero strain on the supporting implant components and the surrounding bone in the absence of an applied external load.¹⁷ Lack of passive fit is related to the numerous clinical and laboratory procedures during the fabrication of customized frameworks as possible distortion can occur during the impression procedure, fabrication of the master cast, fabrication of the framework patterns, investing and casting procedures, or during framework insertion.¹⁰ Therefore the presence of prefabricated implant components (titanium bars and shaped abutment) and electric welding intraorally are the essentials cause for the passivity of the group II.¹⁹ Intraoral welding done directly in the oral cavity, therefor the chance of errors or distortions caused by impressions is avoided where sufficient fixation and implant

stability are critical to avoid the possibility of micro movements and implant loss.²⁰

Prosthetic complications play an essential role in implant success to recognize the long-term serviceability of the prosthesis and it is a mirror for the passivity.²¹ lack of passivity produce internal stresses in the framework, the implants, and the bone resulting in mechanical complications as screw loosening, fracture of screw, framework or prosthesis .The results revealed that there was only one case showed screw looseness during the follow up period (16.66%) in customized framework group, while in electric welded group there was no screw looseness (0%) ,this may be due to slight lack of passivity, abutment-screw loosening are the most frequent prosthetic complication according to dental implant therapy.²²

In the electric welded group only one case showed teeth fracture after 3 month and another case showed teeth shipment after 6 months, this may be due to mechanical parameters such as occlusal load, force direction, and the shape of the restorative material. Improvements in resin shear bond strength and durability may be able to reduce these issues.²³ it also may be due to small diameter of titanium bar from the customized framework so led to more stress over it.

Regarding the number of needed visits, group I (6.83 ± 0.75) was significantly higher than group II (3.16 ± 0.41) as $P < 0.05$. In duration of needed visits, group I (330 ± 11.3) was significantly higher than group II (150 ± 8.5) as $P < 0.05$. this is belongs to multiple prosthetic procedure to loaded the implants in group I including unsplinted-splinted impression, multiple verification jig used , checking of the frameworks passivity, multiple visits is used and the adjustment of the frameworks needed long duration compared to group II and due to impression procedure ,verification jig ,soldering and reassembly of the framework.¹²

It has been demonstrated that there is a possibility of intraoral welding of metal prosthodontic components without risk, soft tissue damage, or discomfort to the patient, and hence eliminating the costly and time-consuming process of impression taking with its inherent inaccuracies.²⁴⁻²⁵ The study clarified that In group I C/E ratio (93.5) was higher than group II (85.7). Also, survival rate in group I was (100%), while in group II was (83.4%). The cost included: the cost of implants and its accessories, the impression coping and analogue used in group I, the titanium bar and the use of the Electrical Syncrystallization Unit renting and the laboratory fees for the complete denture as the total cost in group I was (9350), while in group II was (7150).

Conclusion

Maxillary fixed detachable prosthesis supported by customized or electric welded framework show no difference regarding the prosthetic complication while the electric welded framework shows highly passive fit when compared to the customized one. The cost, cost effectiveness, numbers of visits are lower and visits duration is shorter in electric welded framework when compared to customized one.

References

1. Di Francesco F, de Marco G, Gironi Carnevale UA, Lanza M, Lanza A. The number of implants required to support a maxillary overdenture: a systematic review and meta-analysis. *Journal of Prosthodontic Research*. 2019 Jan 1;63(1):15–24.
2. Wang IC, Barootchi S, Tavelli L, Wang HL. The peri-implant phenotype and implant esthetic complications. Contemporary overview. *Journal of Esthetic and Restorative Dentistry* [Internet]. 2021 Jan 1 [cited 2022 Feb 28];33(1):212–23.
3. Kulkarni PN, Bulbule NS, Kakade DM, Hakepatil N v. Radiographic stents and surgical stents in implant placements: An overview. *International Journal of Current Research and Review*. 2019 Jun 1;11(12):11–5.
4. Oh WS, Oh J, Jin Q. Bone loss in the anterior edentulous maxilla opposing two-implant-supported overdentures vs complete dentures: a systematic review and meta-analysis. *Quintessence Int* [Internet]. 2020 [cited 2022 Feb 28];51(9):722–31.
5. Ferro KJ, Morgano SM, Driscoll CF, Freilich MA, Guckes AD, Knoernschild KL, McGarry TJ, Twain M. The glossary of prosthodontic terms. *J prosthet dent*. 2017 May;117(5S):e1-05.
6. Zimmermann, P. (2018). Prosthodontic Solutions for Elderly Patients 2018 December14(2) 131-140 implants in elderly patients *Forum Implantologicum*
7. uzayan MM, Yunus NB. Passive Fit in Screw Retained Multi-unit Implant Prosthesis Understanding and Achieving: A Review of the Literature. *J Indian Prosthodont Soc* [Internet]. 2014 Mar [cited 2019 Aug 27]; 14(1):16–23.
8. Lee KY, Shin KS, Jung JH, Cho HW, Kwon KH, Kim YL. 1. Lee KY, Shin KS, Jung JH, Cho HW, Kwon KH, Kim YL. Clinical study on screw loosening in dental implant prostheses: a 6-year retrospective study. *J Korean Assoc Oral Maxillofac Surg* [Internet]. 2020 Jun 30 [cited 2022 May 4];46(2):133. Available from: /pmc/articles/PMC7222622/
9. Drago C, Howell K. Concepts for Designing and Fabricating Metal Implant Frameworks for Hybrid Implant Prostheses. *J Prosthodontic* [Internet]. 2012 Jul 1 [cited 2022 May 5]; 21(5):413–24.
10. Ender A, Attin T, Mehl A. In vivo precision of conventional and digital methods of obtaining complete-arch dental impressions. *The Journal of prosthetic dentistry*. 2016 Mar 1;115(3):313-20.
11. Longoni S, Sartori M, Davide R. A simplified method to reduce prosthetic misfit for a screw-retained, implant-supported complete denture using a luting technique and laser welding. *The Journal of prosthetic dentistry*. 2004 Jun 1;91(6):595-8.
12. Degidi M, Gehrke P, Spanel A, Piattelli A. Syncrystallization: A technique for temporization of immediately loaded implants with metal-reinforced acrylic resin restorations. *Clin Implant Dent Relat Res*. 2006;8(3):123–34.
13. Saad a. al-Harbi :implant supported milled bar mandibular overdenture with locator attachments: clinical considerations and laboratory techniques *international dentistry sa* 2006 8,(6) 54-64
14. Schweizerische Zahnärzte-Gesellschaft (1994). Zahnarzt-Tarif undTarif für zahntechnische Arbeiten. Schweizerische Zahnärzte-Gesellschaft. (Order at info@sso.ch or download fromwww.sso.ch..
15. da Mata Patrick F. Allen,Michael C, Denis O,Gerald M and Noel W Cost-effectiveness of ART restorations in elderly adults: a randomized

- clinical trial *Community Dent Oral Epidemiol* 2014; 42; 79–87
16. Lambert FE, Weber HP, Susarla SM, Belser UC, Gallucci GO. Descriptive analysis of implant and prosthodontic survival rates with fixed implant-supported rehabilitations in the edentulous maxilla. *J Periodontol* [Internet]. 2009 Aug [cited 2022 Apr 29];80(8):1220–30.
 17. Sahin, S., & Çehreli, M. C. (2001). The Significance of Passive Framework Fit in Implant Prosthodontics: Current Status. *Implant Dentistry*, 10(2), 85–92.
 18. Benic, G. I., & White, G. S. (2011). Accuracy of implant casts generated with splinted and non-splinted impression techniques for edentulous patients : an optical scanning study. 1–6.
 19. Longoni S, Sartori M, Davide R. A simplified method to reduce prosthetic misfit for a screw-retained, implant-supported complete denture using a luting technique and laser welding. *The Journal of prosthetic dentistry*. 2004 Jun 1;91(6):595-8.
 20. Fogli V, Camerini M, Lauritano D, Carinci F. Success and high predictability of intraorally welded titanium bar in the immediate loading implants. *Case Reports in Dentistry*. 2014 May 22;2014.
 21. Maló P, de Araújo Nobre M, Lopes A, Ferro A, Botto J. The All-on-4 treatment concept for the rehabilitation of the completely edentulous mandible: A longitudinal study with 10 to 18 years of follow-up. *Clin Implant Dent Relat Res*. 2019. doi: 10.1111/cid.12769
 22. Kourtis S, Damanaki M, Kaitatzidou S, Kaitatzidou A, Roussou V. Loosening of the fixing screw in single implant crowns: predisposing factors, prevention and treatment options. *J Esthet Restor Dent* [Internet]. 2017 Jul 8 [cited 2022 May 28];29(4):233–46.
 23. Fischer K, Stenberg T, Hedin M, Sennerby L. Five-year results from a randomized, controlled trial on early and delayed loading of implants supporting full-arch prosthesis in the edentulous maxilla. *Clin Oral Implants Res* [Internet]. 2008 May [cited 2022 Jun 3];19(5):433–41.
 24. Degidi M, Daprile G, Piattelli A. Implants inserted with low insertion torque values for intraoral welded full-arch prosthesis: 1-year follow-up. *Clinical implant dentistry and related research*. 2012 May;14:e39-40.
 25. Degidi M, Nardi D, Piattelli A. A six-year follow-up of full-arch immediate restorations fabricated with an intraoral welding technique. *Implant Dentistry*. 2013 Jun 1;22(3):224-31.