










INTERNATIONAL JOURNAL OF MEDICAL ARTS



Volume 5, Issue 9, September 2023

<https://ijma.journals.ekb.eg/>



Print ISSN: 2636-4174

Online ISSN: 2682-3780



Available online at Journal Website
<https://ijma.journals.ekb.eg/>
 Main Subject [Neurosurgery]



Original Article

Evaluation of Clinical Outcome after Gaserian Ganglion Radiofrequency Thermocoagulation For the Treatment of Trigeminal Neuralgia

Saied B. Alaskary ^{*1}, Ali Salah Khedr ²

¹ Department of Neurosurgery, Faculty of Medicine, Al-Azhar University, Cairo, Egypt

² Department of Neurosurgery, Faculty of Medicine, Suez Canal University, Ismailia, Egypt

ABSTRACT

Article information

Received: 17-08-2023

Accepted: 24-09-2023

DOI: 10.21608/IJMA.2023.229865.1780.

*Corresponding author

Email: saidbasheer11@gmail.com

Citation: Alaskary SB, Khedr AS. Evaluation of Clinical Outcome after Gaserian Ganglion Radiofrequency Thermocoagulation For the Treatment of Trigeminal Neuralgia. IJMA 2023 September; 5 [9]: 3607-3612. doi: 10.21608/IJMA.2023.229865.1780.

Background: Trigeminal neuralgia is a common cause of severe annoying facial pain that has a great effect on patient's life, and in drug resistant cases gaserian ganglion radiofrequency is minimally invasive, safe and effective procedure specially in patients not fit for microvascular decompression [MVD].

Aim of the work: To evaluate clinical outcome after Gaserian Ganglion radiofrequency thermocoagulation treatment of trigeminal neuralgia.

Patients and Methods: We performed Gaserian Ganglion radiofrequency thermocoagulation on 25 patients with primary trigeminal neuralgia and followed them for 12 months after surgery to compare our findings with those of other authors in the literature.

Results: 100% of cases showed immediate post RF pain relief and VAS decreased from 9.8 to 0.24. the recurrence rate after 6 months of follow up was 8% [2 cases] and after 1 year was 20% [5 cases]. 100% developed facial hypoesthesia but improved gradually and only 2 patients, [8%] still complaining of ipsilateral hypoesthesia after 2 months. 12% of patients developed mild facial swelling that subsided over 1 to 2 weeks, and 12% developed grade 4 masticatory weakness that improved over 1 month, while there were no patients recorded with anesthesia dolorosa, corneal affection, CSF leak, meningitis or vascular injury.

Conclusion: The results were quite satisfying in terms of pain reduction, and the risks of any problems are minimal and transient at best.

Keywords: Trigeminal neuralgia; Tic douloureux; Radiofrequency thermocagulation; Gaserian Ganglion.



This is an open-access article registered under the Creative Commons, ShareAlike 4.0 International license [CC BY-SA 4.0] [<https://creativecommons.org/licenses/by-sa/4.0/legalcode>].

INTRODUCTION

An innocuous stimulus can set off a painful episode of trigeminal neuralgia, a type of neuropathic facial pain characterized by stabbing or electric shock-like pain in the distribution territory of one or more divisions of the trigeminal nerve. Concomitant continuous pain, i.e. a background discomfort between the paroxysmal attacks, is experienced by a subset of people with TN [[formerly described as atypical TN]]^[1].

TN with or without concurrent chronic pain, must be diagnosed solely on clinical grounds. Idiopathic TN, in which no underlying cause can be identified, classic TN, in which an anomalous vessel causes morphologic changes of the trigeminal root close to its entry into the pons, and secondary TN, which results from major neurologic disease such as multiple sclerosis or tumors at the cerebellopontine angle, all require diagnostic testing^[2].

Debilitating neuropathic pain from TN can make even the most fundamental human tasks, such touching the face, talking, eating, and drinking, impossible. TN has been linked to negative mental health outcomes, such as anxiety, depression, and disturbed sleep, according to an epidemiological study^[3]. TN occurs at a rate of 12.6 to 27.0 per 100,000 people each year, and it is more common in women [60%] than males [40%] for unknown causes^[4].

Converging data suggests that root entrance zone compression causes neurological disease. The entrance zone is thought to be especially vulnerable to pressure since it is where myelination switches from being done by peripheral Schwann cells to being done by central oligodendroglia. Hyperexcitability and the ability to generate ectopic impulses that appear as spontaneous pain are hallmarks of demyelinated afferents, as has been repeatedly demonstrated in animal models^[4].

TN treatment typically begins with conservative medical care. Carbamazepine [CBZ] 200–1,200 mg/day and oxcarbazepine [OXC] 600–1,800 mg/day are the two medicines typically prescribed as initial treatment for TN. The initial response rate to medical treatment is 80%, but drops to below 50% over time. Surgery is an option when other treatments have failed or when there are serious risks connected with continuing medical care^[5].

Medically intractable cases of TN can be treated surgically through procedures including peripheral nerve section, radiosurgery with a Gamma Knife, or percutaneous methods such as glycerol rhizolysis, radiofrequency thermo-coagulation [RFT], or balloon compression^[6,7].

Percutaneous methods continue to be a viable and safe choice for many individuals, even if microvascular decompression is considered the gold standard of treatment^[6,7].

Pulsed radiofrequency [PRF] and thermo-coagulation radiofrequency [TRF] are also viable options for treating TN, with TRF demonstrating superior efficacy. There were more difficulties with TRF than with PRF, but they all resolved quickly and left no lasting effects. Patients treated with PRF had a considerably lower incidence of pain alleviation than those treated with TRF. In addition, PRF-treated individuals were more likely to experience persistent pain. As a result, TRF might be the best treatment for TN^[8]. So, we used to do TRF for our patients and it is the topic of our study.

PATIENTS AND METHODS

Twenty-five total cases were considered in this study with idiopathic and classic TN treated with Gaserian Ganglion radiofrequency thermo-coagulation. 16 females [64%] and 9 males [36%], with main age of 48 years old. We excluded cases of TN owing to multiple sclerosis or other space-occupying lesions.

All cases were treated with C-arm guided percutaneous trans foramen ovale Gaserian ganglion RF thermocoagulation using local anesthesia and reversed light sedation between July 2019 and December 2021 and follow up was done for at least 12 months postoperatively.

In the cases under study, we did the following:

History taking: Name, age, gender, occupation, and symptoms such as pain intensity [visual analog scale], location of pain, and other neurologic symptoms are all part of the patient history. The patient's symptoms, as well as the illness's start, duration, and prognosis, were all taken into account.

Examination: General and complete neurological examination was done to exclude secondary causes.

Investigations: Routine laboratory investigations, and Magnetic Resonance Imaging [MRI], trigeminal nerve protocol, was done for all cases to exclude secondary causes and to search for vascular loop.

Informed Consent: All participants or their immediate family members provided written informed permission.

Operative procedures

The percutaneous method was carried out according to the original 1974 description by **sweet *et al.*** [9] The patient is in a relaxed supine position, with their head slightly extended, for this treatment. Continuous hemodynamic monitoring entails recording of electrocardiogram, pulse oximetry, and blood pressure.

The c-arm is introduced in a postero-anterior fashion and rotated caudally to produce a submental view. In many cases, this perspective alone is sufficient to picture the foramen ovale. Foramen ovale visibility may be enhanced by tilting the patient 5-10 degrees to the ipsilateral [affected] side [figure 1].

Needle insertion site is around 2–3 cm from the patient's mouth corner. We had great success with "bringing the foramen ovale to the entry point" by rotating the c-arm in a caudo-cranial direction, which provided a fantastic "tunnel

view." A 1% lidocaine solution is applied to the area of skin that will receive a needle.

The ipsilateral pupil is targeted with the needle in an aseptic procedure. To prevent the needle from entering the patient's mouth, we use the standard procedure of having the patient hold one finger in their mouth. If the needle enters the oral cavity, it is immediately replaced to prevent the spread of infection.

When inserting the needle into the foramen ovale, up to 0.75 mg/kg of propofol is given to the patient to put them to sleep. To determine how far the needle has penetrated into Meckel's cavity after passing through the foramen ovale, the c-arm is turned to the side. After aligning the external auditory canal bilaterally, the needle's eventual destination is just beyond the angle produced by the petrosal ridge of the temporal bone and the clivus [figure 2].

After the patient is awake, the propofol is turned off and 50 hz sensory stimulation is administered. Inducing paresthesia with sensory stimulation between 0.1 and 0.3 v in the affected painful area confirmed the electrode's final position [10].

The typical RF rhizolysis conditions were 75 degrees Celsius [70-85 degrees Fahrenheit] and 60 seconds [45-60 seconds] [11].

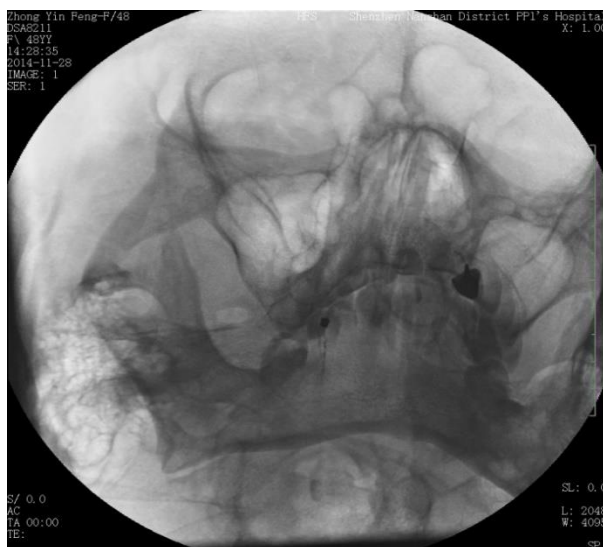


Figure [1]. AP fluoroscopy submental view with the needle inserted in the left foramen ovale, and the rt foramen ovale can be seen

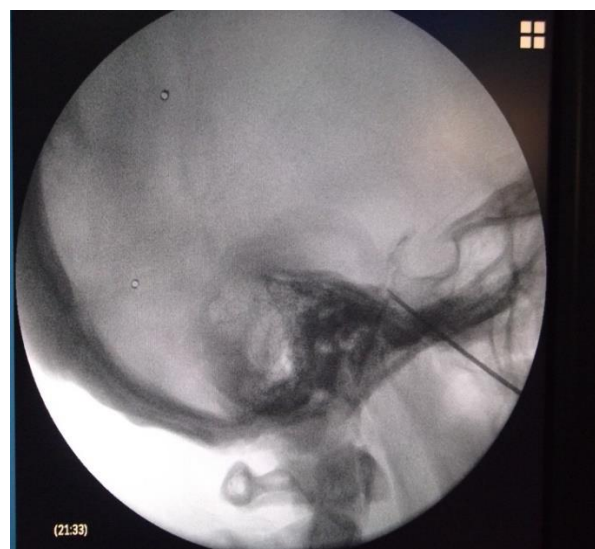


Figure [2]: Lateral Fluoroscopy showing petroclival angle with aligned external auditory canal and the needle tip is stopped at the petroclival angle

Follow up: After 6 and 12 months, patients were evaluated again to see whether or not they had experienced a recurrence of their initial symptoms, as well as to rule out the possibility of any complications.

Statistical analysis: Data were analyzed using Statistical Program for Social Science [SPSS] version 24. Quantitative data were expressed as mean \pm SD. Qualitative data were expressed as frequency and percentage. Mean [average]: the central value of a discrete set of numbers, specifically the sum of values divided by the number of values. Standard deviation [SD]: is the measure of dispersion of a set of values. A low SD indicates that the values tend to be close to the mean of the set, while a high SD indicate that the values are spread out over a wider range. Mann Whitney U test [MW]: when comparing between two means [for abnormally distributed data]. Chi-square test: was used when comparing between non-parametric data. P-value $<$ 0.05 was considered significant.

RESULTS

Regarding age, the range of patients evaluated was between 30 and 70 years old, with the average age of all of the patients being 47.7 years old with a standard deviation of 10.6 years. In terms of gender distribution, there were 16 females [representing 64%] and 9 men [representing 36%] among the patients who were studied [table 1].

As regard affected side, there were 14 cases [56%] with left side affected and 11 cases [44%] with right side affected in the studied patients. As regard distribution, V1 was affected in only 1 patient [4%], V2 was affected in 8

cases [32%] & V3 was affected in all studied patients [100%] [table 2].

According to age the previous intervention in all studied cases. There were 5 patients [20%] subjected to previous intervention in the studied cases. 4 cases were subjected to RF and 1 patient subjected to MVD [table 3].

As regard immediate post-operative evaluation, all patients [100%] shows significant improvement as regard comparison of pre and postoperative VAS, As can be seen in table [4], there is a statistically significant [$p < 0.001$] reduction in VAS scores after surgery. [mean = 0.24 ± 0.5 , Range = 0 -2] when matched with pre-operative VAS [mean = 9.8 ± 0.5 , Range = 8 -10].

Evaluation of recurrence after 6 months and 1 year of follow up show recurrence in 2 patients, [8%] after 6 months and 5 patients, [20%] after 1 year. and these results shows no statistical significance [table 5]

All patients were complaining of postoperative hypoesthesia in the side of the lesion in the first 2 weeks but the majority of them improved after 2 months and only 2 patients, [8%] still complaining of ipsilateral hypoesthesia after 2 months [table 6].

As regard postoperative complications, there were 3 patients [12%] with mild facial swelling that subsided over 1 to 2 weeks, and 3 patients [12%] with grade 4 masticatory weakness that improved over 1 month, while there were no patients recorded with anesthesia dolorosa, corneal affection, CSF leak, meningitis or vascular injury [table 7].

Table [1]: Description of demographic data in all studied cases

Studied patients [n = 25]			
Sex [No., %]	Male	9	36%
	Female	16	64%
Age [years]	Mean \pm SD	47.7 \pm 10.6	
	Min - Max	30 – 70	

Table [2]: Description of distribution in all studied cases

Studied patients [N0. = 25]			
Side	Right	11	44%
	Left	14	56%
Distribution	V1	1	4%
	V2	8	32%
	V3	25	100%

Table [3]: Description of prior intervention for all individuals under study

Studied patients [N0. = 25]			
Previous intervention	No	20	80%
	Yes	5	20%
Type of Interventions	RF	4	80%
	MVD	1	20%

Table [4]: Comparison of pre-operative and post-operative VAS

		Pre-Op [No. = 25]	Post-Op [No. = 25]	P-value
VAS	Mean \pm SD	9.8 \pm 0.5	0.24 \pm 0.5	< 0.001
	Range	8 - 10	0 - 2	

Table [5]: Comparison of recurrence after 6 months and 1-year post-operative

		6 months post-op [n = 25]		1-year post-op [n = 25]		P-value
Recurrence	No	23	92%	20	80%	0.221
	Yes	2	8%	5	20%	

Table [6]: Comparison of 2 weeks and 2 months post-operative hypoesthesia

		2 weeks [n = 25]		2 months [n = 25]		P-value
Hypoesthesia	No	0	0%	23	92%	< 0.001
	Yes	25	100%	2	8%	

Table [7]: Description of post-operative complications

Studied patients [n = 25]			
Complications	Anesthesia dolorosa	0	0%
	Masticatory weakness	3	12%
	Facial swelling	3	12%
	Corneal affection	0	0%
	CSF leak	0	0%
	Meningitis	0	0%
	Vascular injury	0	0%

DISCUSSION

In 1913, Réthi pioneered radiofrequency lesioning by attempting to electrocoagulate the rootlets of the trigeminal nerve and the gasserian ganglion. Nonetheless, Sweet was the first to utilize thermocoagulation on the trigeminal rootlets, and it was proved to be successful for pain alleviation, in 1975 [7,9].

In this study, we worked on 25 case 64% of them were females and 36% were males [male to female ratio 2:3] with main age 47 years old [range 30 – 70 yrs. old]. In the work of Wang *et al.* [12], a Systematic Reviews and Meta-analyses was done 54 studies were included. A total of 13,410 cases. Xue *et al.* [13], stated that 40 patients were treated with trans foramen ovale thermocoagulation RF. Fouad [6], worked on 312 case but also included 1ry and 2ry TN and the number of men to women was roughly 2 to 3.

In this study, the initial pain relief was 100% and VAS decreased from 9.8 to 0.24. In the work of Wang *et al.* [12], the initial pain relief was 95.31% [ranged from 77.8 to 100%]. Xue *et al.* [13] stated that initial pain relief was 90%. In the work of Fouad [6], the initial pain relief was 100%.

In this study, the recurrence rate after 6 months of follow up was 8% [2 cases] and after 1 year was 20% [5 cases]. In the work of Wang *et al.* [12] At 6 months, the recurrence rate varied from 0% to 26%, and at 12 months, it was between 4.5 and 67%. Xue *et al.* [13] stated that the recurrence rate after 1 year was 17.5%. In the work of Fouad [6], the recurrence rate after 1 year was 13.5%.

In this study, all patients developed post RF hypoesthesia in the distribution of the targeted trigeminal nerve branch during the first 2 weeks but the majority of them improved after 2 months and only 2 patients, [8%] still

complaining of ipsilateral hypoesthesia after 2 months. **Xue et al.** ^[13] stated that post op. facial hypoesthesia was 100%. In the work of **Fouad** ^[6], 100% of the patients had post op. facial hypoesthesia.


In this study, As regard the incidence rate of various postoperative complications, There were 3 patients [12%] with mild facial swelling that subsided over 1 to 2 weeks, and 3 patients [12%] with grade 4 masticatory weakness that improved over 1 month, while there were no patients recorded with anesthesia dolorosa, corneal affection, CSF leak, meningitis or vascular injury. **Xue et al.** ^[13] stated that masticatory weakness showed in 77.5%, facial swelling in 37.5 and corneal affection in 55% but other possible complications not mentioned. In the work of **Fouad** ^[6], masticatory weakness showed in 1.6 %, corneal involvement in 1%.

Conclusion: Patients with TN who have not responded to medical treatment, or those can't tolerate medications, may find relief from their suffering with a minimally invasive procedure called radiofrequency thermocoagulation of the Gasserian ganglion. Inaccurate cannulation increases the risk of complications and should be avoided. What's more, the complications that did arise were not irreversible and steadily diminished over time.

Financial and non-financial relations and activities of interest: None

REFERENCES

1. Di Stefano G, Truini A, Cruccu G. Current and Innovative Pharmacological Options to Treat Typical and Atypical Trigeminal Neuralgia. *Drugs*. 2018 Sep;78[14]:1433-1442. doi: 10.1007/s40265-018-0964-9.
2. Cruccu G. Trigeminal Neuralgia. *Continuum [Minneapolis, Minn]*. 2017 Apr;23[2, Selected Topics in Outpatient Neurology]:396-420. doi: 10.1212/CON.0000000000000451.
3. Zakrzewska JM, Wu J, Mon-Williams M, Phillips N, Pavitt SH. Evaluating the impact of trigeminal neuralgia. *Pain*. 2017 Jun;158[6]:1166-1174. doi: 10.1097/j.pain.0000000000000853.
4. Bendtsen L, Zakrzewska JM, Heinskou TB, Hodaie M, Leal PRL, Nurmikko T, et al. Advances in diagnosis, classification, pathophysiology, and management of trigeminal neuralgia. *Lancet Neurol*. 2020 Sep;19[9]:784-796. doi: 10.1016/S1474-4422[20]30233-7.
5. Gunduz HB, Cevik OM, Asilturk M, Gunes M, Uysal ML, Sofuoglu OE, Emel E. Percutaneous Radiofrequency Thermocoagulation in Trigeminal Neuralgia: Analysis of Early and Late Outcomes of 156 Cases and 209 Interventions. *J Korean Neurosurg Soc*. 2021 Sep;64[5]:827-836. doi: 10.3340/jkns.2020.0333.
6. Fouad W. Management of trigeminal neuralgia by radiofrequency thermocoagulation. *Alexandria J Med*. 2011 Mar 1;47[1]:79-86. doi: 10.1016/j.ajme.2011.02.001.
7. Cheng JS, Lim DA, Chang EF, Barbaro NM. A review of percutaneous treatments for trigeminal neuralgia. *Neurosurgery*. 2014 Mar;10 Suppl 1:25-33; discussion 33. doi: 10.1227/NEU.000000000-00001687.
8. Guo J, Dong X, Zhao X. Treatment of trigeminal neuralgia by radiofrequency of the Gasserian ganglion. *Rev Neurosci*. 2016 Oct 1;27[7]:739-743. doi: 10.1515/revneuro-2015-0065.
9. Sweet WG. Proceedings: Analgesia dolorosa after differential retrogasserian thermal or mechanical rhizotomy: tactics employed to decrease its influence. *J Neurol Neurosurg Psychiatry*. 1975 Apr;38[4]:407. doi: 10.1136/jnnp.38.4.407-a.
10. Chua NH, Halim W, Beems T, Vissers KC. Pulsed radiofrequency treatment for trigeminal neuralgia. *Anesth Pain Med*. 2012 Spring;1[4]:257-61. doi: 10.5812/aapm.3493.
11. Massager N, Pouleau HB, Jodaïtis A, Morelli D. Application of morphological characteristics of radiofrequency lesions to individual parameters of thermal rhizolysis for trigeminal neuralgia. *Eur J Pain*. 2022 Jul;26[6]:1292-1303. doi: 10.1002/ejp.1950.
12. Wang Z, Wang Z, Li K, Su X, Du C, Tian Y. Radiofrequency thermocoagulation for the treatment of trigeminal neuralgia. *Exp Ther Med*. 2022 Jan;23[1]:17. doi: 10.3892/etm.2021.10939.
13. Xue TQ, Zhang QX, Bian H, Zhou PC, Liu C, Niu SF, et al. Radiofrequency Thermocoagulation Through Foramen Rotundum Versus Foramen Ovale for the Treatment of V2 Trigeminal Neuralgia. *Pain Physician*. 2019 Nov;22[6]:E609-E614. PMID: 31775414.



International Journal

<https://ijma.journals.ekb.eg/>

Print ISSN: 2636-4174

Online ISSN: 2682-3780

of Medical Arts