

## FINDINGS, IDENTIFICATIONS AND ETIOLOGY OF VERTICAL ROOT FRACTURES

Abdullah Mahmoud Riyahi\* 

### ABSTRACT

**Aim:** Vertical root fractures (VRF) present a diagnostic challenge for clinicians. The failure to identify clinical and radiographic findings related to VRF would result in inappropriate management of the involved teeth.

**Cases Description:** Two Cases of VRFs were investigated. Different tools and strategies were applied to obtain an accurate diagnosis of VRF and relate it to its possible etiologies.

**Conclusion:** Due to the limited options available for management of VRFs when diagnosed, prevention of both the causative and predisposing factors are the key in such scenarios.

**Clinical significance:** Dental practitioners and endodontics should be aware of clinical signs and symptoms, proper radiographical analysis and prevention of VRFs.

**KEY WORDS:** Vertical Root Fracture, Diagnosis, Etiology of fractures & Occlusal forces.

### INTRODUCTION

Vertical root fractures (VRFs), a type of longitudinal tooth fracture, poses a diagnostic challenge to clinicians <sup>(1)</sup>. VRF is defined as a fracture that is either complete or incomplete, starting in the root of the tooth structure and propagating coronally, usually in a bucco-lingual direction <sup>(2)</sup>. However, another definition by Chang is a fracture confined in the root that is directed longitudinally <sup>(3)</sup>. While Von Arx found the majority

of VRFs ran in a direction from cervical to apical area <sup>(4)</sup>.

The two main causes of VRF are placement of posts and condensation forces during obturation. Other causes that have been considered, but which have not been evidentially demonstrated, include wedging of restorations, forces related to occlusion, corrosion, expansion of metallic posts and retrograde fillings <sup>(2,5,6)</sup>. Some reports have found VRFs in non-endodontically treated teeth <sup>(7)</sup>.

\* Associate Professor, (Corresponding author) Department of Restorative Dental Science, Division of Endodontics, College of Dentistry, King Saud University, P.O. Box 60169, Riyadh 11545, Kingdom of Saudi Arabia

VRFs can be difficult to diagnose. Clinical findings may include the following: percussion tenderness, pain on biting, and swelling<sup>(8)</sup>. Characteristic traits of VRFs include sinus tract, narrow and deep pocket, pain to palpation/percussion and halo shaped radiolucency<sup>(9)</sup>.

One of the predisposing factors for VRF is the parafunctional habits. For prevention and management of VRFs, it is important to detect the existence of those parafunctional habits in the patient and to analyze occlusal schemes<sup>(10)</sup>.

In some cases, the segments are separated which can be seen radiographically<sup>(11)</sup>. VRF can be detected on CBCT<sup>(12)</sup>. However, a systematic review concluded that in root canal filled teeth, the use of CBCT is still not a good instrument for detection of VRF in comparison with direct visualization<sup>(13)</sup>. Using CBCT many fracture lines in endodontically treated teeth couldn't be detected while wider fracture could be better detected<sup>(14)</sup>.

When the findings obtained from clinical and radiological are inconclusive, the diagnosis of VRF can be confirmed through exploratory surgery. The use of magnification and methylene blue die also assists in the diagnosis of VRF<sup>(15)</sup>.

This study aimed to present cases that were accurately diagnosed, using different techniques to assist the clinician in examination and management of such situations. Moreover, this study showed that occlusal forces can be a predisposing factor in VRF. The two cases reported were endodontically treated.

### Case 1

A 56-year-old male patient complained of "puffy" gums around tooth #34 and some discomfort when he chewed on it but reported no pain. His medical history was noncontributory. He was not taking any medications and he had no known allergies. He was a non-smoker and was classified as ASA I. His dental history included multiple restorations and root canal treatment, with no previous complications during local anesthesia injections or extraction. The patient reported a tooth clenching habit. Intraorally,

there was soft localized swelling associated with tooth #34 buccally and lingually (Fig. 1). Moreover, his teeth showed signs of occlusal wear.

Upon clinical examination of tooth #34, the tooth had slight tenderness to percussion, mobility grade 1, 11-mm probing-depth mid-buccally and 12-mm probing-depth mid-lingually. A radiograph of tooth #34 showed occlusal amalgam, excessive removal of the tooth structure, particularly in the coronal third of the root, poor obturation, and asymmetrical periapical radiolucency (mesially).

After discussing treatment options with the patient, he chose exploratory surgery. Under magnification and transillumination using an operating microscope, a diagnostic triangular full mucoperiosteal flap was reflected. A VRF was observed visually and was then further revealed using methylene blue dye. The tooth had a hopeless prognosis and was therefore extracted.

### Case 2

A 54-year-old male patient complained of having pain and swelling on tooth #34. The patient first felt some discomfort upon chewing on that tooth 4 months earlier. However, he reported that swelling and pain began 1 month before attendance. For the last 2 weeks, the patient had used amoxicillin. His medical history was noncontributory, and he was classified as ASA I. Intra-orally, buccal swelling was present (Fig. 2) and there were generalized signs of occlusal wear.

Clinical examination of tooth #34 revealed mild tenderness to percussion, palpation, and the bite test. The isolated probing depth was 11 mm mid-buccally.

Peri-apical radiography revealed previous root canal treatment on teeth #34 and #35. Tooth #34 had a porcelain-fused-to-metal crown. There was a pear-shaped periradicular radiolucency and black lines in the apical third (indicative of VRF) related to tooth #34. The patient chose not to undergo exploratory surgery. The tooth had a hopeless prognosis and was extracted.

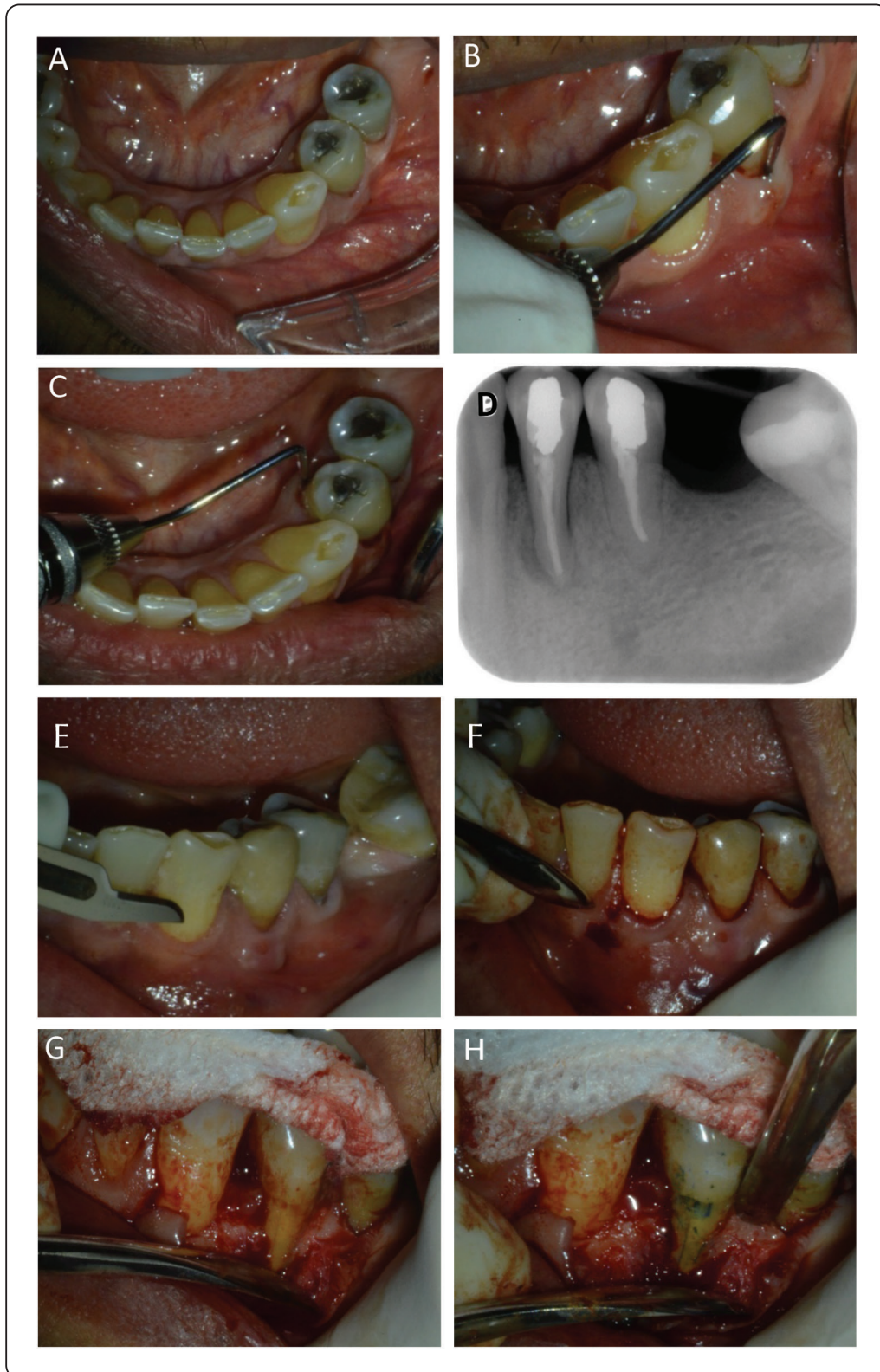


Fig. (1) (A) The patient's teeth showed signs of occlusal wear. (B,C) Deep probing reaching to the root apex buccally and lingually. (D) Peri-apical radiograph showing asymmetrical periapical radiolucency related to tooth #34. (E,F) Exploratory surgery, including flap reflection. (G,H) The vertical root fracture was seen and was then further revealed using methylene blue die.

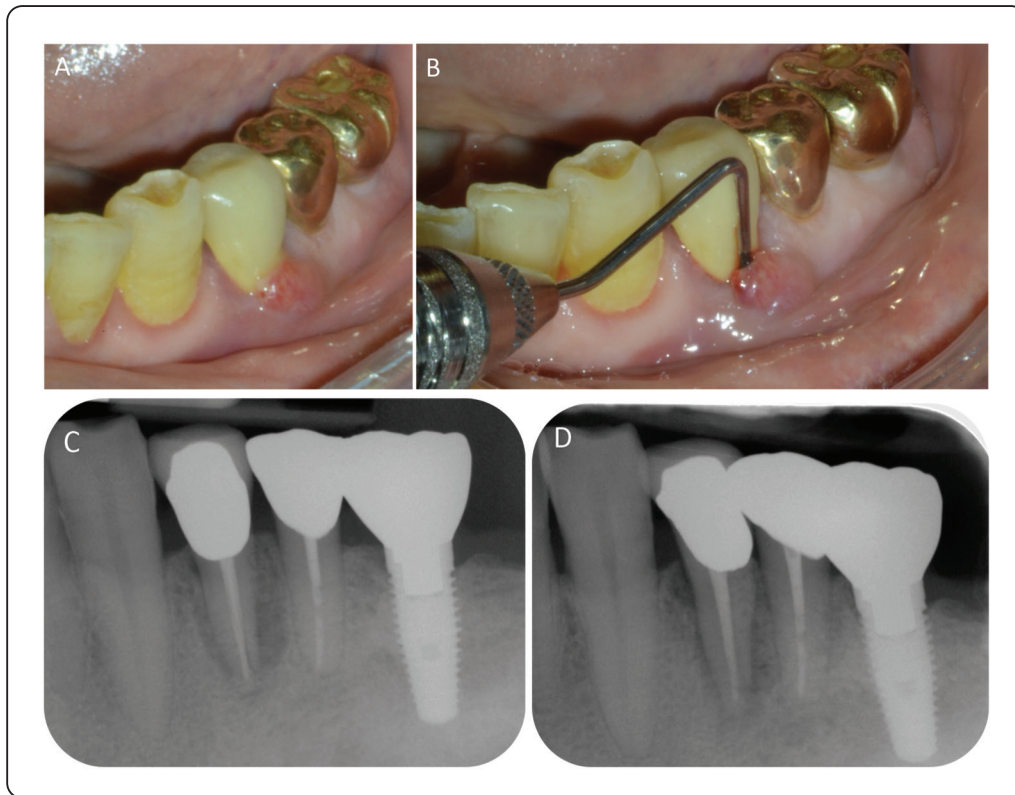

Fig. (2) (A) Clinical image showing buccal swelling related to tooth #34. (B) Signs of occlusal wear. Periodontal probing revealed a deep pocket mid-buccally, reaching the root apex. (C) Periapical radiograph showing a pear-shaped periradicular radiolucency related to tooth #34. This radiograph also shows black lines in the apical third (indicating vertical root fracture) of the same tooth. (D) A radiograph from different angle showing the same black line in the apical third of tooth #34.

## DISCUSSION

In the clinical cases of VRF presented above, there was a history of either discomfort or pain on chewing. In both cases, the tooth in question was a lower premolar that had undergone root canal treatment. Swelling was observed on buccal and/or lingual surfaces. In both cases, the tooth of interest was tender to percussion and palpation. Furthermore, both cases had deep isolated pocked almost reaching the apex on buccal and/or lingual surfaces. The radiographic presentation of the lesion in both cases had a unique pattern (J-shape or Pearshape) that usually accompanies VRF. In the first case, the fracture was observed clinically after flap reflection, with the use of magnification and methylene blue die. In the second case, the fracture line was observed radiographically in two different angles.

In the literature, other longitudinal tooth fractures, such as cracks—which are considered as a different entity, with particular clinical findings and treatment<sup>(16-18)</sup>—are more strongly linked to generalized occlusal forces. Cracks are seen in patients who might have prominent muscles of mastication and show signs of occlusal wear resulting from these heavy forces<sup>(19)</sup>

However, another study reported that vertical split of the roots is associated with force of occlusion and specific stress for a long time<sup>(20)</sup>. Another study suggested that VRF is associated with tooth abrasion and malocclusion.<sup>(21)</sup>

In this study, both cases had generalized wear signs on the teeth (Figs. 1, 2). Although local factors related to the tooth are important for diagnosis and prevention of VRF, general occlusal forces cannot

be ignored as one of the etiologies. In this two-case series, an association between VRF and generalized tooth wear has been shown. In these two cases the teeth were endodontically treated. Attrition was also reported as a common feature in the VRF cases of non-endodontically treated teeth<sup>(15)</sup> in a relatively recent literature review. Innovative modalities have been suggested in the literature for treatment of VRF, but they still need validation. Therefore, the main treatment remains resection of the fractured root in case of multirouted teeth or tooth extraction<sup>(10)</sup>. Since there is still no satisfactory treatment to date, prevention of this condition is critical. To prevent VRFs, knowing all the causative factors is key to success. This study suggests considering occlusal forces as a factor that need to be addressed for prevention.

Magnification using an operating microscope and methylene blue help to detect tooth cracks early<sup>(22)</sup>. Methylene blue is also used for detection of VRF (4). In case 1, the use of operating microscope and methylene blue die assisted to visualize the VRF as shown in Fig. 1.

Additionally, it is worth mentioning that AI assistance may be helpful in the diagnosis of VRF. One study reported promising results using artificial intelligence and panoramic images for detection of VRF<sup>(23)</sup>. Another study used CBCT and deep learning to identify VRF<sup>(24)</sup>. The future can show more studies to evaluate the results in that direction using new and updated artificial intelligence systems and their reliability.

## CONCLUSION

VRFs present diagnostic and management Challenges. This study discussed diagnosis of VRF via application of different tools including magnification, radiography and flap reflection when needed. Generalized occlusal forces and tooth wear, along with local tooth-related factors, should be considered for appropriate diagnosis and management of VRF. Occlusal analysis should be considered early for prevention. Finally, due to the

poor prognosis of VRF, prevention could be a key in addressing such conditions.

### Conflict of interest:

The author denies any conflicts of interest.

### Data Availability:

The data used to support the findings of this study are included within the article.

### Funding:

No special fund was provided for this research.

## REFERENCES

1. Pitts DL, Natkin E. Diagnosis and treatment of vertical root fractures. *J Endod* 1983; 9: 338–346.
2. Rivera EM, Walton RE. Longitudinal tooth fractures: findings that contribute to complex endodontic diagnoses. *Endod Topics* 2007; 16: 82–111.
3. Chang E, Lam E, Shah P, Azarpazhooh A. Cone-beam computed tomography for detecting vertical root fractures in endodontically treated teeth: a systematic review. *Journal of endodontics*. 2016 Feb 1;42(2):177-85.
4. Von Arx T, Bosshardt D. Vertical root fractures of endodontically treated posterior teeth. *Swiss Dent J*. 2017;127(1):14-23.
5. Tamse A. Vertical root fractures in endodontically treated teeth: diagnostic signs and clinical management. *Endod Topics* 2006; 13: 84–94.
6. Tamse A, Fuss Z, Lustig J, Kaplavi J. An evaluation of endodontically treated vertically fractured teeth. *J Endod* 1999; 25: 506–508.
7. Chan CP, Lin CP, Tseng SC, Jeng JH. Vertical root fracture in endodontically versus nonendodontically treated teeth: a survey of 315 cases in Chinese patients. *Oral Surg Oral Med Oral Pathol Oral Radiol Endod* 1999; 87: 504–507.
8. Fayad MI, Ashkenaz PJ, Johnson BR. Different representations of vertical root fractures detected by cone-beam volumetric tomography: a case series report. *J Endod* 2012; 38: 1435–42.
9. PradeepKumar AR, Shemesh H, Jothilatha S, Vijayabharathi R, Jayalakshmi S, Kishen A. Diagnosis of vertical root fractures in restored endodontically treated teeth: a time-dependent retrospective cohort study. *Journal of Endodontics*. 2016 Aug 1;42(8):1175-80.

10. Patel S, Bhuvra B, Bose R. Present status and future directions: vertical root fractures in root filled teeth. *International Endodontic Journal*. 2022 May;55:804-26.
11. Tamse A. Iatrogenic vertical root fractures in endodontically treated teeth. *Dental Traumatology*. 1988 Oct;4(5):190-6.
12. Caetano AP, Sousa TO, Oliveira MR, Evangelista K, Bueno JM, Silva MA. Accuracy of three cone-beam CT devices and two software systems in the detection of vertical root fractures. *Dentomaxillofacial Radiology*. 2021 Mar 1;50(3):20200334.
13. PradeepKumar AR, Shemesh H, Nivedhitha MS, Hashir MM, Arockiam S, Maheswari TN, Natanasabapathy V. Diagnosis of vertical root fractures by cone-beam computed tomography in root-filled teeth with confirmation by direct visualization: A systematic review and meta-analysis. *Journal of endodontics*. 2021 Aug 1;47(8):1198-214.
14. Gulibire A, Cao Y, Gao A, Wang C, Wang T, Xie X, Liang J, Li W, Lin Z. Assessment of true vertical root fracture line in endodontically treated teeth using a new subtraction software—A Micro-CT and CBCT study. *Australian Endodontic Journal*. 2021 Aug;47(2):290-7.
15. Liao WC, Chen CH, Pan YH, Chang MC, Jeng JH. Vertical root fracture in non-endodontically and endodontically treated teeth: current understanding and future challenge. *Journal of personalized medicine*. 2021 Dec 16;11(12):1375.
16. Hiatt WH. Incomplete crown-root fracture in pulpalperi-odontal disease. *J Periodontol* 1973; 44: 369–379.
17. Cameron CE. The cracked tooth syndrome: additional findings. *J Am Dent Assoc* 1976; 93: 971–975.
18. Lynch CD, McConnell RJ. The cracked tooth syndrome. *Journal-Canadian Dental Association*. 2002 Sep 1;68(8):470-5.
19. Rivera EM. Longitudinal tooth cracks and fracture: an update and review. *Endod Topics* 2015; 33: 14–42.
20. Zeng Y, Wang J, Zhou S. Occlusal contact force and stress analysis of molars with vertical root split. *Zhonghua kou Qiang yi xue za zhi= Zhonghua Kouqiang Yixue Zazhi= Chinese Journal of Stomatology*. 2000 Mar 1;35(2):142-3.
21. Dai LX, Tong WL, Guo JL. The role of occlusal factors in the occurrence of vertical root fracture. *Shanghai kou Qiang yi xue= Shanghai Journal of Stomatology*. 2013 Feb 1;22(1):68-71.
22. Van As GA. Evaluation of Enamel and Dentinal Cracks Using Methylene Blue Dye and the Operating Microscope. *Inside Dentistry*. 2007 Jul;3(7).
23. Fukuda M, Inamoto K, Shibata N, Ariji Y, Yanashita Y, Kutsuna S, Nakata K, Katsumata A, Fujita H, Ariji E. Evaluation of an artificial intelligence system for detecting vertical root fracture on panoramic radiography. *Oral Radiology*. 2020 Oct;36:337-43.
24. Yang P, Guo X, Mu C, Qi S, Li G. Detection of vertical root fractures by cone-beam computed tomography based on deep learning. *Dentomaxillofacial Radiology*. 2023 Feb;52(3):20220345