



Updated Survey for Mycotic Keratitis in Tanta University Ophthalmology Hospital and Antifungal Activity of Some Wild Egyptian Plant Extracts Against the Isolated Fungi.

S. Amer¹, M. El-Shourbagy², Kh. Saad-Allah¹, E. El-Mowafy¹ and A. El-Badry^{1,*}

¹Microbiology and Botany Department, Faculty of Science, Tanta University.

²Ophthalmology Department, Faculty of Medicine, Tanta University.

*Corresponding author: anwer.elbadry@science.tanta.edu.eg

ABSTRACT

Two weekly visits to the ocular microbiology lab, Ophthalmology Hospital, Tanta University, were conducted to collect patient data and fungal samples from clinically diagnosed mycotic keratitis cases. It was observable that fungal corneal infections were more common during summer season (48 cases), then spring (26 cases), 2022. This type was more abundant among male patients of age ranged between 20 - 50 years (43 cases out of 100 total mycotic ulcers); in habiting rural houses (78 cases); represented mostly among students and indoor workers (45 cases), that were closely related to commercial contact lenses usage (37 cases). Lab investigation showed more frequency of *Aspergillus flavus* (58 cases), followed by *Aspergillus niger* (22 cases) among the isolated 100 mycotic ulcers. Eight Egyptian wild plants were collected from Halayeb and Shalateen region; their extracts were tested for antifungal activity, whereas the most effective plant extracts against *A. flavus* recorded MIC values of 12.5 mg/ml for *Senna occidentalis*, followed by 25 mg/ml for *Pulicaria undulata*, then 50 mg/ml for *Aerva Jovanica*. The highest antifungal effect of *Senna occidentalis* as illustrated by TEM, showing complete rupture of cell wall, cell membrane, elongation, deformation of cell shape, cytoplasmic agglutination, disintegration of nuclear membrane, shrinking of cytoplasm and leakage of intracellular component outside the damage cell boundaries.

Key Words:

Keratitis, fungi, plant extract, *Aspergillus flavus*, *Senna occidentalis*.

1. INTRODUCTION

Corneal fungal infections are often ulcerative, suppurative lesions; making a challenge to the ophthalmologist because of forming severe stromal inflammation; restricted treatment by the available antifungal agents; and the extent of their corneal tissue penetration [1].

Worldwide variation is observed for the spread of mycotic keratitis. About 11 cases per 100,000 inhabitants had fungal infection in USA, while reaching 799 cases per 100,000 Nepal inhabitants as a developing country [2].

Mycotic keratitis reported from tropical areas may account for more than 50% of all world ocular mycoses, caused by filamentous fungi (like *Aspergillus* and *Fusarium*); and yeast-like fungi (such as *Candida*) [3].

The spores of *Aspergillus*, *Fusarium*, *Bipolaris*, *Curvularia* and *Candida* spp. are implicated in prior ocular surface disease or surgeries and steroid or antibiotic therapies. These are the common isolates cultured from the infected eyes [4].

The presenting complaints of mycotic keratitis are sensation against foreign body, pain of eye, redness, discharge, photophobia, dimness of vision and hypopyon as a characteristic feature [5].

Natamycin is the common initial choice, as it is more effective than the voriconazole for filamentous fungi, like *Aspergillus* and *Fusarium*. Chlorhexidine is used against yeast infections, such as *Candida*. The main principle for using topical corticosteroids is to delay re-epithelialisation, prevent recurrent infection and decrease the risk of perforation [4].

Cataract and the increase in intraocular pressure (IOP) are common complications of prolonged corticosteroid usage. Also, corticosteroids promote fungal growth by suppressing ocular immune mechanisms and inhibiting phagocytosis; so topical steroid should be avoided during fungal infection treatment [6].

Emergence of multi-drug-resistant new fungal species and absence of effective antifungal agents are major public health threats [7]. In the history of humanity, plants have served as the basis for many traditional treatments and are still employed as sources for many modern medications. According to the World Health Organization (WHO), over three-quarters of populations in more than 60% of the resource-limited societies cannot secure approved drugs and depend mostly on medicinal plants for their primary health care [8]. Due to their availability, affordability, safety, potential efficacy, and environmental friendliness, traditional herbal medicines have recently attracted increased attention. These phytochemicals include large number of compounds like phenols, flavonoids, tannins, alkaloids, essential oils, polysaccharides, terpenoids, lignans, glycosides, so they contain chemical molecules that combine to provide a variety of bioactivities [9].

The present survey aimed to update the relationship between human and infective fungi, causing mycotic keratitis, complications, risk factors, virulent enzymes; and how to deal with them by trying new natural remedies.

2. MATERIALS AND METHODS

2.1 Clinical diagnosis of different corneal ulcers:

A survey was conducted on patients clinically diagnosed possessing corneal ulcers of different types. That was achieved by arranging regular twice weekly visits to Ocular Microbiology lab., Ophthalmology Hospital, Tanta University, (from 9 am to 1 pm) from January 2022 to December 2022. Then patients with mycotic keratitis were assigned for more detailed studies. Symptoms of corneal fungal infections:

- Initially, foreign body sensation and slow onset of increasing pain [10].
- Thick area of keratitis with thick sticky hypopyon [11].
- Stromal infiltrates with feathery edges and area of epithelial defect [12].
- Coagulative necrosis with the loss of keratocytes and disruption of collagen lamellae due to secretion of fungal enzymes as phospholipase, collagenase and proteases. That leads to puncture of Descemet's membrane, resulting in passage of fungi to the anterior chamber [13].

Also, many complications could be observed accompanying active mycotic keratitis, such as endophthalmitis, perforation, ring abscess, corneal melting, gutter, facet, thinning, and corneal opacity. All infected eyes were photographed, and clinically described to summarize clinical complications accompanying fungal keratitis; and patient data were collected.

2.2 Collection, purification and identification of keratitis fungi:

Samples were taken from patients diagnosed clinically to have mycotic keratitis by flame-sterilized platinum "Kummra" spatula (Alcon-Couvreur, Belgium) for hard tissues, or by autoclaved cotton swab for soft ulcers (to avoid perforation). Conjunctiva, and eyelids were avoided in corneal scraping; anaesthesia were used as topical external eye drops (Boxinate eye drops by Alex. Pharma. Co., tested for non-antimicrobial activity). Aseptic conditions were applied by alcohol washing around the infected eyes, samples were picked up in the closed hospital laboratory, then cultured as C-streaks to distinguish the desired microbial growth of corneal sample origin on the plate surface from other contaminants [14]. The protocol of sampling and patient dealing was approved by the Research Ethics Committee, Faculty of Medicine, Tanta University, with approval code of 34895/9/21.

Each sample was cultured on Sabouraud's dextrose agar (SDA) medium (30 gm dextrose, 10 gm peptone, 20 gm agar, in 1 L dist. water with 0.05 % chloramphenicol to avoid bacterial contamination) in triplicates. All plates were incubated for 4 to 21 days at 27°C. Fungal colonies were purified, examined and identified morphologically [15–17].

2.3 Detection of pathogenicity tools of isolated fungi:

All isolated fungi from corneal ulcers during the present survey were tested for collagenase and proteases as different extracellular enzyme activities, that were expected to be effective to establish corneal ulcers.

A. Qualitative collagenase assay:

Production of extracellular collagenase enzyme was induced by growing each of the collected fungal isolates on a collagen- dependent liquid nutrition medium, composed of 0.5 mg/ml native bovine collagen (by EVA cosmetics lab. Cairo, Egypt), 0.36 mM CaCl₂, and 25 mM Tris-HCl in dist. H₂O, pH=7.5 for one week at 37°C in a shaking incubator. Cultures were centrifuged, and supernatants (with crude enzyme extract) were tested for collagenase activity according to Barrett et al. [18] as follows:

Native bovine collagen substrate (25mg) was dissolved in 5ml Tris-HCl buffer (pH=7.5), and pre-incubated at 37°C for 15 minutes, then mixed with 0.1ml crude enzyme suspension of each fungal isolate (liquid culture filtrate), and incubated for five hours at 37°C. Reaction was stopped in all tubes by transferring 0.2ml of each reaction mixture into a tube with 1ml of ninhydrin [dissolved in 0.25% acetone], heated to preboiling point in water bath for 20 minutes. Positive result of collagenase activity (secretion of collagenase, and collagen breakage) was detected by purple colour formed due to reaction of ninhydrin with the resultant amino acids, and peptides.

B. Proteases assay:

Production of extracellular proteases was tested on casein substrate for all fungi isolated from corneal ulcers, following the modified procedure of Paterson and Bridge [19]. One gram of agar was dissolved in 60 ml of 50 mM Tris-HCl, 10mM CaCl₂ at pH=8 in hot water bath, cooled to 65°C, 50 mg of casein (Sigma) substrate powder were dissolved in 40ml of buffer (pH=8), mixed with the prepared agar solution, heated at 90°C with stirring for 10 minutes, autoclaved, and poured in sterile plates avoiding air bubbles, being sure that the gel thickness was uniform.

A well of 1mm diameter was punched on the center of each plate using tip of sterilized cork borer and kept in a humidified chamber. On the other hand, the growth of each fungal isolate was harvested in 5ml of sterile saline; five microliters of each isolate spore suspension were pipetted in the central well of each plate and incubated at 25°C for 16 hours. The reaction was stopped by covering agar with filter papers soaked in 5% acetic acid, this could enhance contrast of the cleared zones resulting from proteolysis (Pz value), which was calculated as a percentage ratio of diameter of colony to diameter of colony + cleared zone in each plate.

C. Quantification of collagenase activity of fungal isolates:

All isolated fungi were tested for collagenase production as carried out by Keil et al. [20] as follows: Liquid medium was prepared, containing 0.25% yeast extract, 0.3% glucose, 1% gelatine and 1% native bovine collagen, then divided into 100ml fractions in flasks (250 ml), and autoclaved. Then three replica for each fungal isolate (about 10⁶ cells/ml spore suspension of an overnight fresh culture) were inoculated into the sterile flasks of the prepared collagen- dependent liquid medium. All were shaken for 4 days at 37°C.

Fungal growth was centrifuged for 20 minutes at 3000 rpm; and mycelial mat was separated from the culture filtrate, tested for collagenase production, and no intracellular collagenase activity was observed.

Then two parameters were measured in the supernatant of each fungus individually; firstly, the concentration of L-leucine produced from collagen degradation. Secondly, the concentration of total proteins in each fungal culture filtrate. Collagen degradation product (L-leucine) was measured by adding 5ml of 0.05 M Tris-HCl buffer (pH=7.5) to 0.1 ml of fungal supernatant, incubated for 5 hours at 37°C; then 0.2ml of each mixture were diluted with 1 ml ninhydrin-acetone solution (Sigma), boiled for 20 minutes in water bath, diluted with 5ml of 50% propanol, cooled for 15 minutes, absorbance was measured for each tested mixture at $\lambda=600\text{nm}$ [20].

A standard curve was prepared by reading the absorbance of known concentrations of ninhydrin-stained L-leucine (Sigma) at $\lambda=600\text{nm}$. Then concentrations of L-leucine in the tested mixtures were concluded from that curve. According to Keil et al. [20], Unit of collagenase enzyme is the amount of enzyme, producing 1 μmol of L-leucine during 1 hour. Collagenase activity was quantitatively calculated for each fungus by dividing L-leucine concentration in micromoles on total protein concentration in milligrams, which were previously recorded in its supernatant as follows:

Enzyme activity (enzyme unit/mg protein) = μmol . L-leucine /mg total proteins.

The second parameter was the total protein concentration in the supernatant of each fungal culture, measured according to Bradford [21] as follows: 0.1 ml of each supernatant was added to 5 ml of dye reagent (100 mg Coomassie brilliant blue G-250 dye in 50 ml of 95% ethanol +100 ml of 85% phosphoric acid, diluted to 1 liter dist. water and filtered). Sample mixtures were shaken for 5 minutes, absorbance was measured at $\lambda=595\text{ nm}$. Total protein concentrations in the tested supernatants were concluded from a previously scaled standard curve plotted for the absorbance of known concentrations of pure stained bovine serum albumin solution, as a standard protein.

2.4 Collection, identification and extraction of wild plants:

Eight wild plants were collected from Halayeb and Shalateen reserved region during a field trip in Spring, 2022. All plants were examined, photographed, identified and dried. The procedure described by Kasim et al. [22] with some modifications was followed to prepare the different extracts of the dried plants. A weight of 50 g of each dried plant powder was well mixed with 600 ml of each type of solvent individually (cold water, hot water at 60°C, ethanol and methanol); then incubated for 24 h. in dark at 120 rpm. Each extract was filtered, evaporated till dryness and redissolved in 1 L dist. water, then stored at 4°C for further work.

2.5 Survey for antifungal activity of the collected plant extracts:

A. Preliminary survey for antifungal activity of the selected plant extracts:

Antifungal activity of the stored plant extracts was conducted by Cut plug method according to Pridham et al. [23] as follows: Fresh spore suspension of each collected fungus (0.5 ml of about 106 cells/ml) was mixed separately with 9.5 ml of melting sterile Sabouraud's dextrose agar at 45°C, poured on sterile Petri dishes, solidified at room temperature. Regular 0.8 mm wells were made in the inoculated plates by a sterile cork borer. Each well was filled with 20 μL of each tested extract. Three replica were made for each test; and all plates were incubated at 27°C for 3 days. Then the average inhibition zone diameters were recorded for all plates.

B. Estimation of MIC for the most efficient antifungal plant extracts against the most dominant fungal isolate:

Concentrations of 6.25, 12.5, 25, 50 and 100 mg/ml were prepared in distilled water for each plant extract by individually half-fold dilution; negative control was considered as zero concentration. A Fresh pure spore suspension of the selected fungus (0.5 ml of about 106 cells/ml) was added to each extract concentration (9.5 ml), then incubated for 3 days at 27°C, then growth turbidity (indicated by light absorbance) was measured at 620 nm by spectrophotometer (Riele 5010, Germany), results were represented graphically, and MIC of each tested extract was estimated [24].

C. Examination of ultrastructure of fungal growth under the effect of the most potent plant extract by transmission electron microscope (TEM):

The effect of the selected plant extracts could be studied on the ultrastructure of fungal cells by preparing the tested fungus on Sabouraud's dextrose liquid medium with a cell suspension of 5x106 cells/ml, that was mixed with the most potent plant extract of its previously estimated MIC. The mixture was incubated at 27°C overnight with shaking at 60 rpm. Then the mixture was twice centrifuged for 20 min. at 3000 rpm and washed with sterile saline solution to collect the cell pellet [25]. The collected cell pellet was fixed by soaking in glutaraldehyde (1 ml of 2.5%, buffered in 0.1 M phosphate buffer saline (PBS) of pH=7.4, to fix cell proteins and stop all cellular metabolic reactions), then cooled at 4°C for 2

hrs. Each sample pellet was washed with 1% osmic acid for 30 min. (to fix lipid cell content), then washed 3 times with PBS (10 min. for each time), dehydrated in 30, 50, 70, 90%, and absolute alcohol gradually for 30 min. for each concentration, then infiltrated for 1 h with acetone.

Samples were soaked in araldite 502 resin to build a plastic mold (to fix all cell contents completely), cut into semi-thin sections by ultra-cut microtome (LEICA ultracut UCT, Japan), stained with 1% toleudine blue, examined for good sample preparation, then ultra-thin sections were prepared, stained with uranyl acetate and counter stained with lead citrate [26], examined at 6000X using the transmission electron microscope (JEOL-JEM-100SX, Japan) with beam current = 60 μ A, and high voltage of 80 KV; good representative photographs were saved digitally for each test.

3. RESULTS

During the year of survey (2022), it was observable that the ulcerative keratitis is a common case among patients coming to out-patient clinic of Ophthalmology Hospital, Tanta University, as 675 cases were recording in the present study, including traumatic (388 cases), bacterial (152 cases), viral (21 cases), Acanthamoeba (14 cases) and mycotic ulcers (100 cases) as revealed in Figure (1).

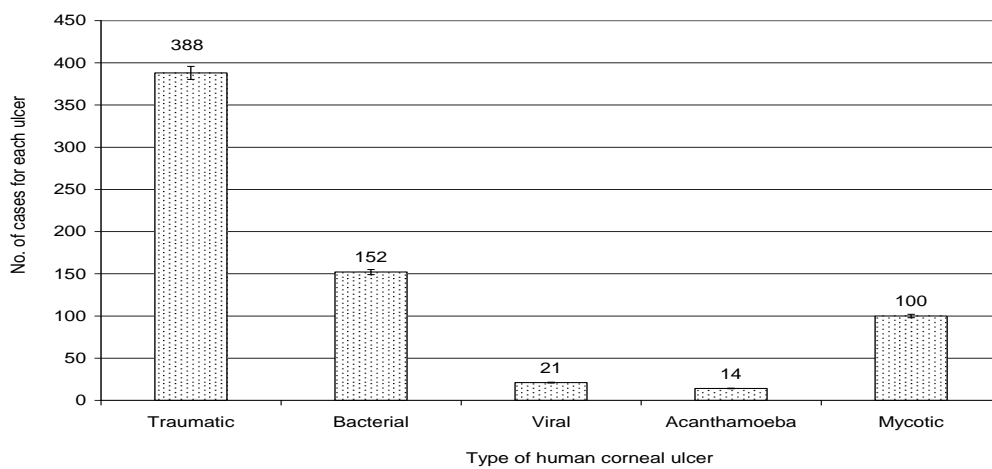


Figure (1): Total incidence of the investigated corneal ulcers during the present survey (2022).

The highest frequency of traumatic ulcer was recorded in January 2022 (42 cases); followed by bacterial ulcer (22 cases) in May 2022, then fungal ulcer was commonly investigated in August 2022 (18 cases). Figure (2) showed that the lowest existence was recorded for both viral and Acanthamoeba ulcer (4 and 3 cases) for each one.

Seasonal variation is a great factor affecting the spread of different types of infectious corneal ulcer. It was clear that spring season recorded the highest frequency of corneal ulcers with total of 198 cases; followed by summer season with total 174 cases, including the highest rate of fungal infection with 48 cases as recorded in Figure (3).

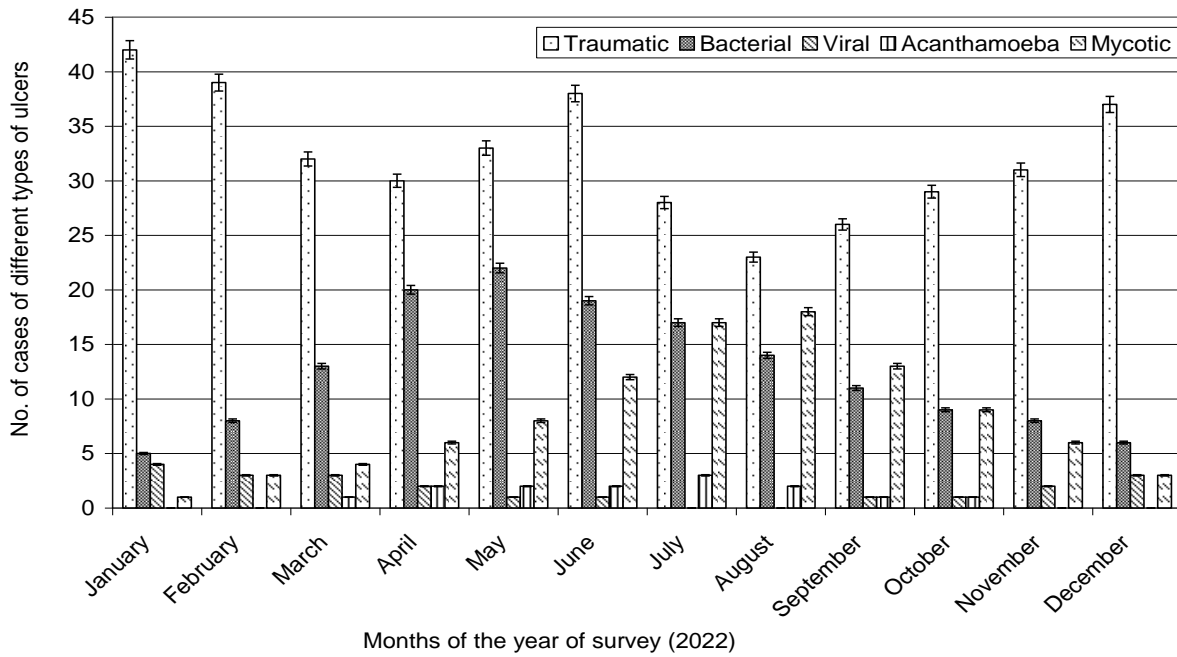


Figure (2): frequency of the investigated corneal ulcers during the present survey (Jan.-Dec., 2022).

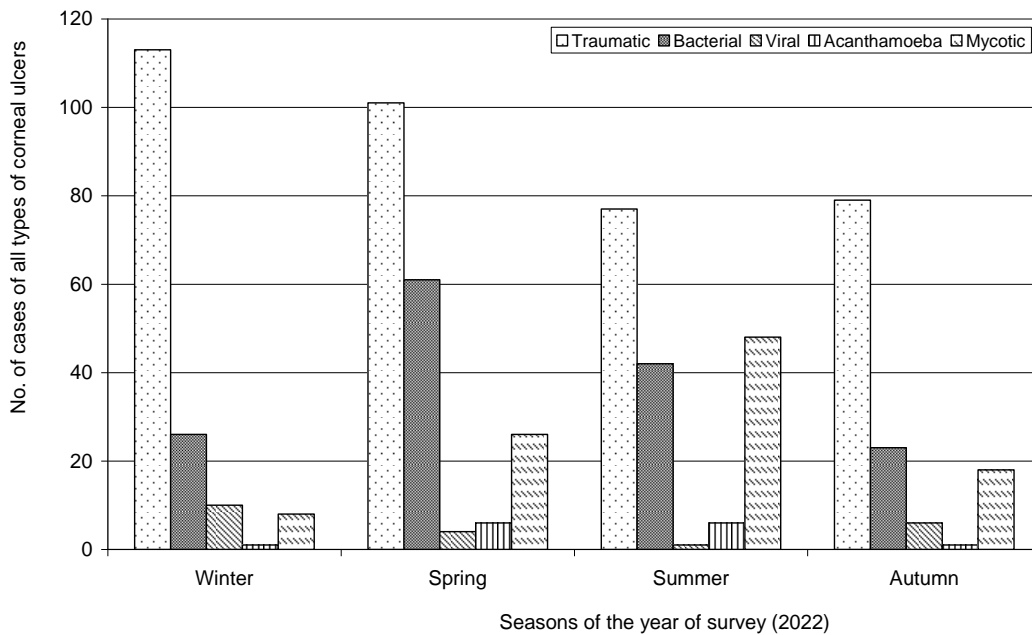


Figure (3): Seasonal variation of the investigated corneal ulcers during the present survey (2022).

Eyes infected with isolated fungi, represent the severity of mycotic keratitis and their complications, were illustrated in Photo (1), that ranged among faint corneal scarring, vascularized corneal opacity, active keratitis with hypopyon, corneal melting, thinning with corneal ulcer, peripheral keratitis with perforation, dendritic central keratitis and endophthalmitis.

On studying the patient’s condition, data were collected and tabulated to reveal the effective factors on the spread of mycotic corneal ulcers. Figure (4) showed that fungal keratitis was more common among patients aging from 20 – 50 years (43 cases out of total 100 cases), followed by (38 cases) of patients

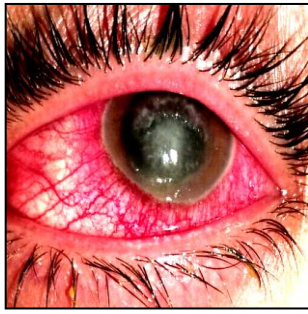aging more than 50 years, while the lowest frequency of mycotic ulcer was recorded for patients aging less than 20 years (19 cases).

As an observable effect of occupation carrier males were more exposed to mycotic ulcer (57 cases) than females (43 cases) as represented in Figure (5). Also, types of houses can greatly affect the spread of mycotic infection as 78 cases were isolated from rural houses compared with only 22 cases inhabiting urban houses as observed in Figure (6).

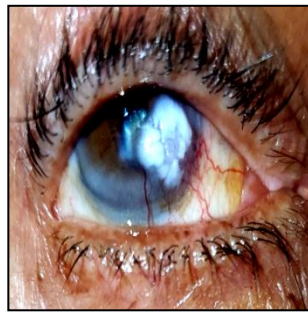
Surrounding condition can affect the fungal spreading of fungal spores and other contaminant among different categories of indoor and outdoor workers. Figure (7) showed that students and indoors workers were mostly exposed to fungal infection (45 cases); followed by farmers (28 cases); then houses wives (21 cases); while the lowest rate of fungal infection was recorded handy professional (6 cases).

From a detailed study of the medical history of mycotic keratitis patients; Figure (8) showed a closed relationship between occupational carrier and different health habits of patients; as this type of infection was more common among users of contact lenses (37 cases) followed by antibiotic and steroid users (34 cases); who included housewives, students and indoor workers. The lowest rate of fungal infection was observed as a post – surgery contamination (4 cases).

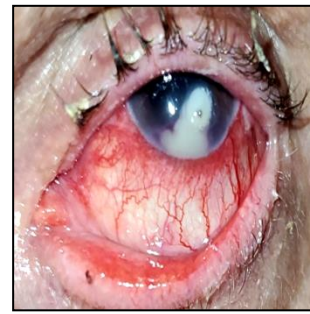All cases which were clinically diagnosed as mycotic ulcer, were confirmed for fungal growth by culturing and morphological identification of the collected isolates, which were recorded in Table (1), that represent the incidence of each isolate among different cases. *Aspergillus flavus* Link was the most common causative agent of the mycotic keratitis as it was isolated from (58 cases) out of total 100 investigated mycotic ulcer; followed by *Aspergillus niger* Tieghem in (22 cases); the *Candida albicans* Berkhout in 17 cases; while the lowest incident fungus was *Mucor fuscus* Bainier only in 3 cases.



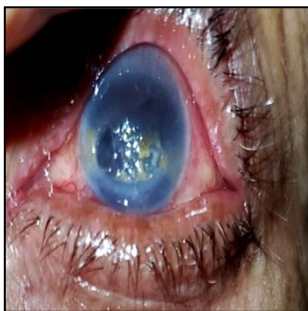Faint corneal scarring.



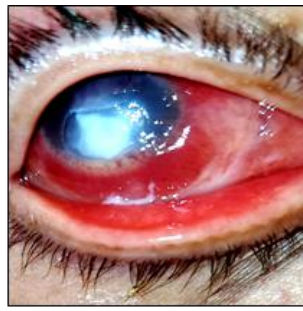
Vascularized corneal opacity.



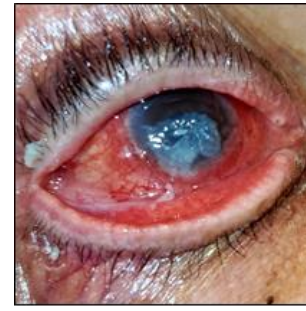Active keratitis with hypopyon.



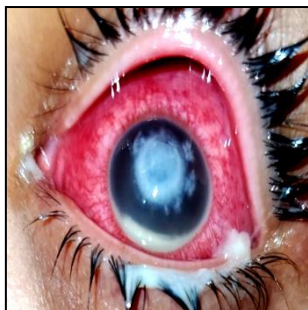
Corneal melting with hypopyon.



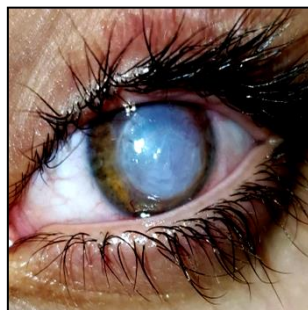Corneal ulcer with thinning.



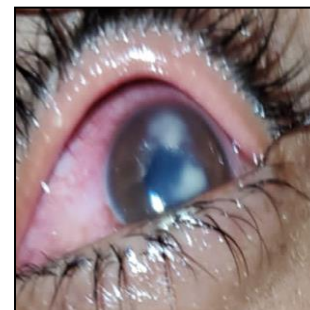
Peripheral keratitis with perforation.



Dendritic central keratitis with hypopyon.



Endophthalmitis.



Double lesion mycotic keratitis

Photo (1): Representative symptoms and complications of mycotic corneal infections during the year of survey (2022).

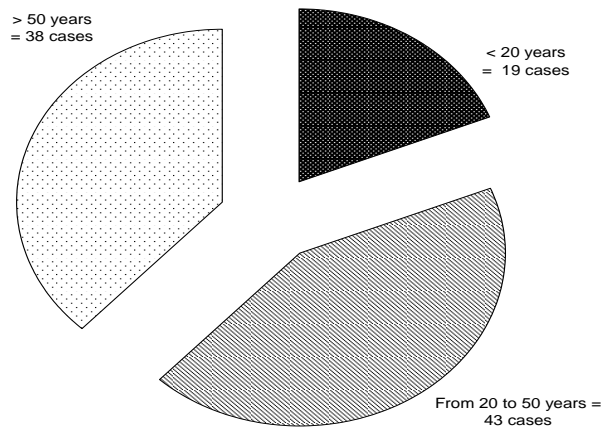


Figure (4): Relation between age categories and incidence of mycotic keratitis.

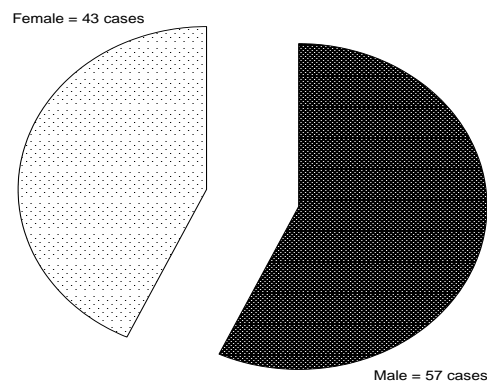


Figure (5): Relation between gender categories and incidence of mycotic keratitis.

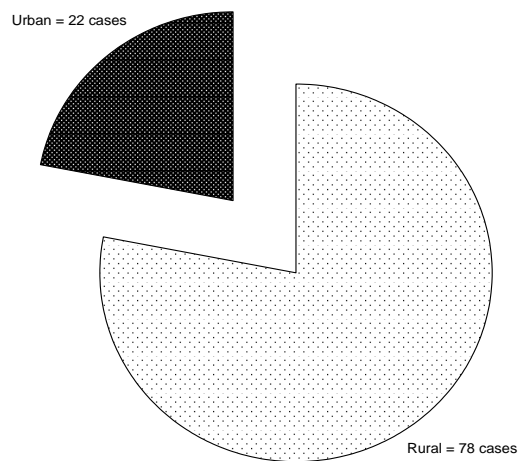


Figure (6): Relation between different house types and incidence of mycotic keratitis.

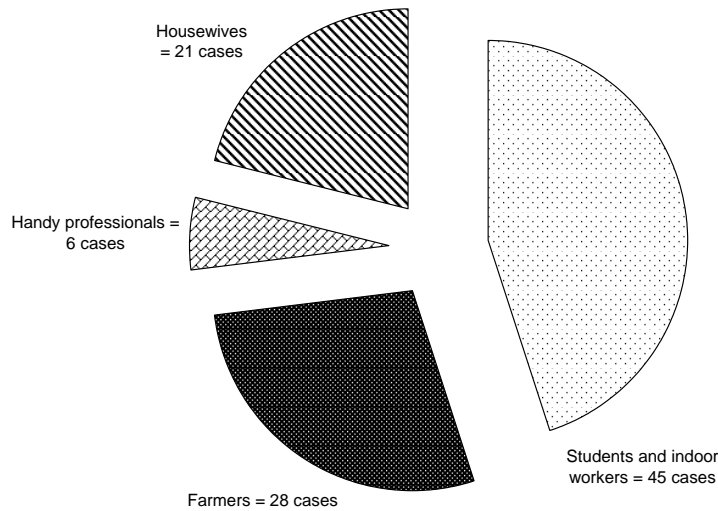


Figure (7): Relation between different categories of occupational career and incidence of mycotic keratitis.

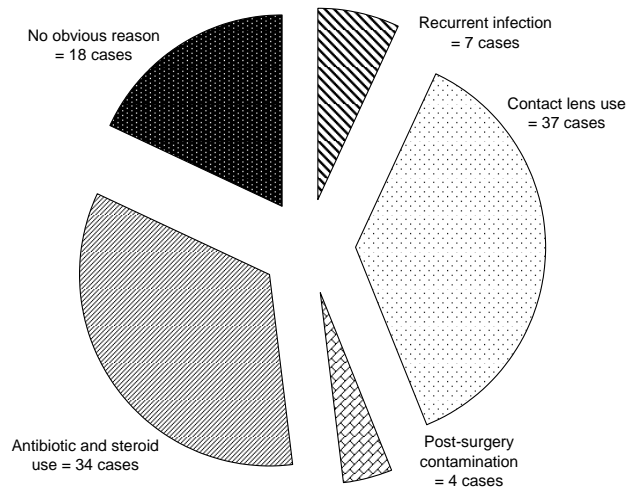


Figure (8): Relation between medical history of patient and incidence of mycotic keratitis.

Spread of fungi in corneal infections depends on their offensive forces, so hydrolytic activity of the collected isolates was tested in the form of casienase and collagenase that was known by their ability to invade corneal tissues. Table (2) and Photo (2) revealed high activity of both (casienase and collagenase) for *Aspergillus flavus*, as it was the most dominant corneal invader; followed by moderate activity of both enzymes for *Aspergillus niger*. On the other hand, *Candida albicans* and *Mucor fuscus* showed low collagenase activity and no casienase activity.

Table (1): Frequency of the isolated fungi among the investigated corneal ulcer patients:

Isolate name	No. of cases (% incidence)
<i>Mucor fuscus</i> (Bainier, 1967)	3
<i>Candida albicans</i> (Berkhout, 1923)	17
<i>Aspergillus niger</i> (Tieghem, 1877)	22
<i>Aspergillus flavus</i> (Link, 1809)	58

Table (2): qualitative detection of enzyme activity of the isolated fungi as an offensive force to invade human cornea:

Isolate name	Proteases activity	Collagenase activity
<i>Mucor fuscus</i> (Bainier, 1967)	-	+
<i>Candida albicans</i> (Berkhout, 1923)	-	+
<i>Aspergillus niger</i> (Tieghem, 1877)	+	++
<i>Aspergillus flavus</i> (Link, 1809)	++	+++

Screening of enzymatic activity of the isolated fungi was confirmed by quantitative assay for both tested enzymes; as the highest activity of collagenase (0.034 u/mg) and for casienase activity (78% pz) were recorded for *Aspergillus flavus* as shown in Figures (9 and 10); followed by *Aspergillus niger* with 0.21 u/mg of collagenase and 33% pz of casienase activity.

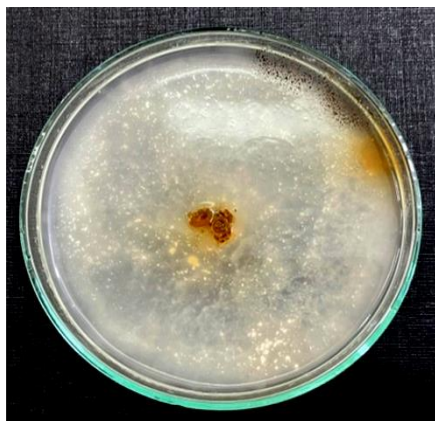
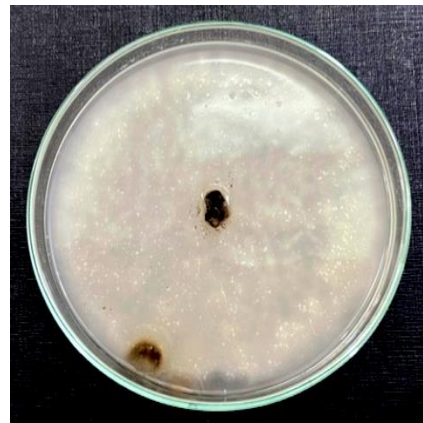**+ve production of casienase.****-ve production of casienase**

Photo (2): Representative plates of qualitative screening for casienase production by the isolated fungi from keratitis patients.

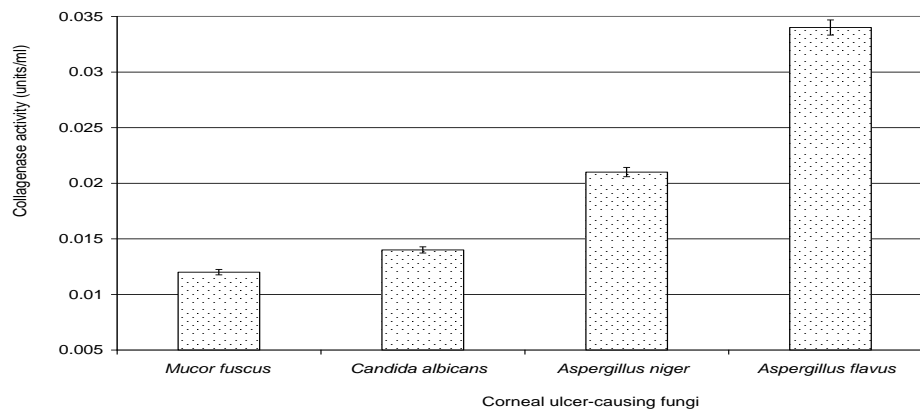


Figure (9): Quantitative estimation of collagenase enzyme activity of the isolated fungi from corneal ulcers.

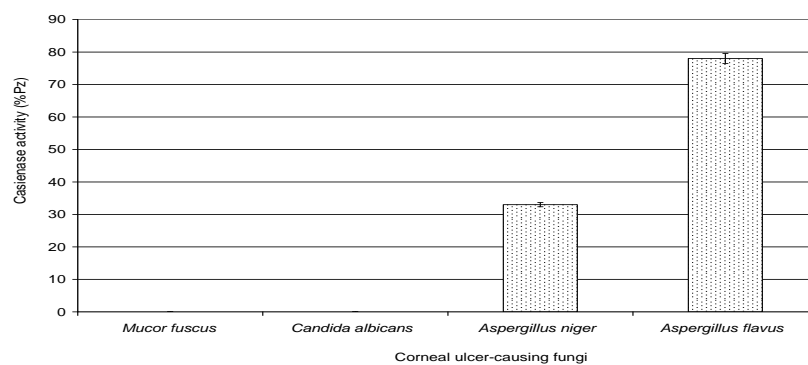


Figure (10): Quantitative estimation of casienase enzyme activity of the isolated fungi from corneal ulcers.









As a trial to search for new natural remedy to treat the investigated corneal ulcer-causing fungi; some wild plants were collected during a field trip to the southeast Egyptian coast at Halayeb and Shalateen region; that was photographed, identified and represented in Table (3), namely: *Cotula cinerea* L., *Senna alexandrina* Mill., *Senna occidentalis* (L.) Link, *Pulicaria undulata* Gaertn., *Senna italica* Mill., *Heliotropium europaeum* L., *Aerva javanica* (Burm) Schult. and *Cleome droserifolia* L.

Ingredients of the collected plants were extracted with different solvents and tested for their antifungal action against the different identified fungi separately. Table (4) showed that the ethanolic extract was the most effective to produce antifungal ingredients. of *Senna occidentalis* had the highest effect among the tested plants on the linear growth *Mucor fuscus* (diameter of inhibition zone = 13 mm. Other ethanolic extracts of *Senna alexandrina* and *Pulicaria undulata* recorded moderate inhibition of 11 and 8 mm against *Mucor fuscus*. Also, only ethanolic extract of the selected plants recorded mild inhibitory action against *Candida albicans* as *Senna occidentalis* gave diameter of inhibition zone =10 mm; while other plant ethanolic extracts gave equal inhibition zone diameter of 8 mm.

Other confirmatory antifungal test against *Aspergillus niger* for the selected plants investigated similar mild activity of ethanolic extract, as the diameter of inhibition zone by *Heliotropium europaeum* measured 10 mm; and a diameter of 8 mm was recorded for each of *Senna alexandrina*, *Senna occidentalis*, *Senna italica* and *Aerva javanica*. *Aspergillus flavus* was the most common fungal isolate of the present work, that was successfully inhibited by ethanolic extract of *Senna occidentalis* diameter of inhibition zone =13 mm; followed by *Pulicaria undulata* (11 mm) and *Aerva javanica* (10 mm); then

other plant ethanolic extracts gave moderate inhibition zones of diameters = 8, 9 and 9 mm for *Senna alexandrina*, *Heliotropium europaeum* and *Cleome droserifolia*, respectively (Table 4).

Table (3): List of collected wild plants from Egyptian Halayeb and Shalateen region:

Latin name:	<i>Cotula cinerea</i> L.		Latin name:	<i>Senna alexandrina</i> Mill.	
Arabic name:	الكوتولا الرمادية		Arabic name:	السينامكى	
Family:	Asteraceae		Family:	Fabaceae	
Used part:	Aerial parts		Used part:	Leaves	
Latin name:	<i>Senna occidentalis</i> (L.) Link		Latin name:	<i>Pulicaria undulata</i> Gaertn	
Arabic name:	الكلكول		Arabic name:	العرفج	
Family:	Fabaceae		Family:	Asteraceae	
Used part:	Leaves		Used part:	Aerial parts	
Latin name:	<i>Senna italica</i> Mill.		Latin name:	<i>Heliotropium europaeum</i> L.	
Arabic name:	عشرق		Arabic name:	عقربانة	
Family:	Fabaceae		Family:	Boraginaceae	
Used part:	Leaves		Used part:	Aerial parts	
Latin name:	<i>Aerva javanica</i> (Burm) Schult		Latin name:	<i>Cleome droserifolia</i> L.	
Arabic name:	شجرة الغزال		Arabic name:	ذفرة ندية الأوراق	
Family:	Amaranthaceae		Family:	Cleomaceae	
Used part:	Aerial parts		Used part:	Leaves	

More detailed investigation of the antifungal activity of the most effective plant extract was adopted to confirm their action and to determine the suitable concentration of the selected plant extract to achieve the highest inhibitory effect on fungal growth, the lowest side effects on the infected host tissues by using the lowest amount of the selected antifungal agent.

Firstly, minimum inhibitory concentration (MIC) determined the activity of the most effective ethanolic plant extracts (Fig. 11). As the ethanolic extract of *Senna occidentalis* recorded MIC at 12.5 mg/ml against *Aspergillus flavus*, followed by 25 mg/ml for ethanolic extract of *Pulicaria undulata*. The lowest activity was indicated by MIC of 50 mg/ml for the ethanolic extract of *Aerva javanica*.

It was observed that ethanolic extract of *Senna occidentalis* had the greatest inhibitory effect on the linear growth of *Aspergillus flavus* as the most common fungal isolate, represented among the investigated corneal ulcer in the present work with the lowest MIC value (12.5 mg/ml). This finding could be explained by the detailed study of ultra structure of treated fungal cells under transmission electron microscope (TEM), that was illustrated in Photo (3).

Table (4): Screening for the antifungal activity of different plant extracts against some representative isolates from the investigated mycotic corneal ulcers:

Plant ethanolic extract	Diameter of inhibition zone (mm) against fungal isolates			
	<i>Mucor fuscus</i>	<i>Candida albicans</i>	<i>Aspergillus niger</i>	<i>Aspergillus flavus</i>
<i>Cotula cinerea</i>	0.0	8	0.0	0.0
<i>Senna alexandrina</i>	11	0.0	8	8
<i>Senna occidentalis</i>	13	10	8	13
<i>Pulicaria undulata</i>	8	8	0.0	11
<i>Senna italica</i>	0.0	8	8	0.0
<i>Heliotropium europaeum</i>	0.0	8	10	9
<i>Aerva javanica</i>	0.0	8	8	10
<i>Cleome droserifolia</i>	0.0	0.0	0.0	9

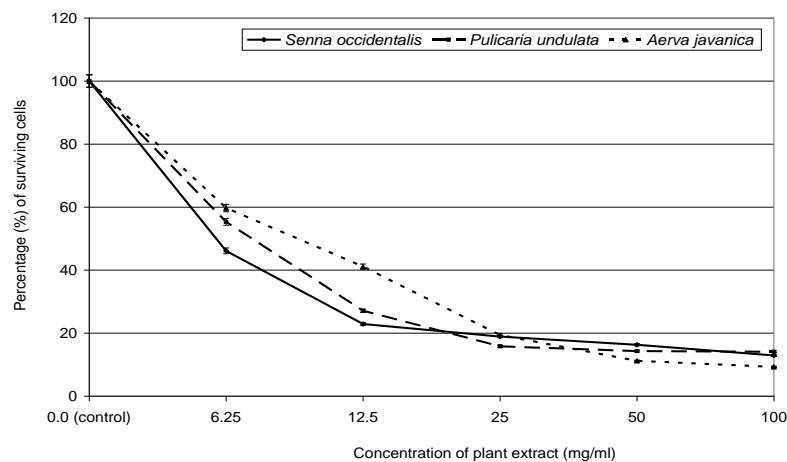
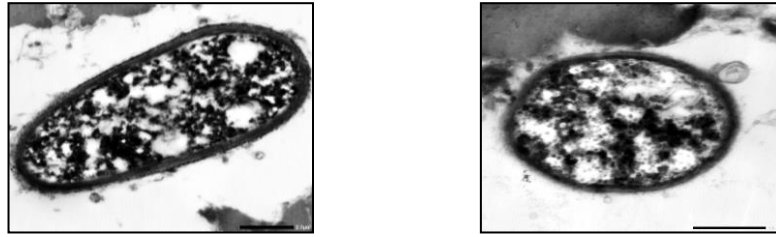


Figure (11): Determination of the MIC of the most efficient plant extract against *Aspergillus flavus*.

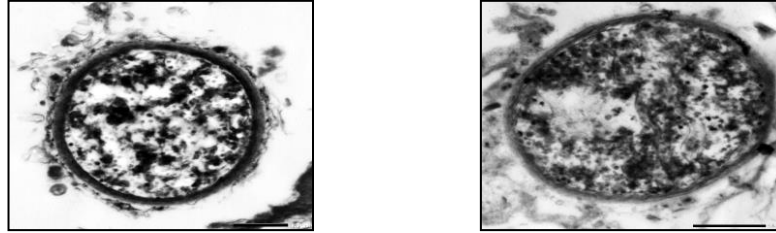
Photo (3-a) showed contact nucleus, cytoplasmic and cell wall structures of the non-treated cells of *Aspergillus flavus*. As comparative investigation, fluconazole with a commercial concentration (150 mg/ml) showed mild protein denaturation and low appearance of coagulates within cytoplasm of treated fungal cells and non-observable effects on cell boundaries as illustrated in Photo (3-b).

As a trial to arise the antifungal activity of fluconazole, a combined action with *Senna occidentalis* ethanolic extract was investigated in Photo (3-c), showing increased cytoplasmic agglutination; observable rupture of cell wall, shrinking and vacuolation.

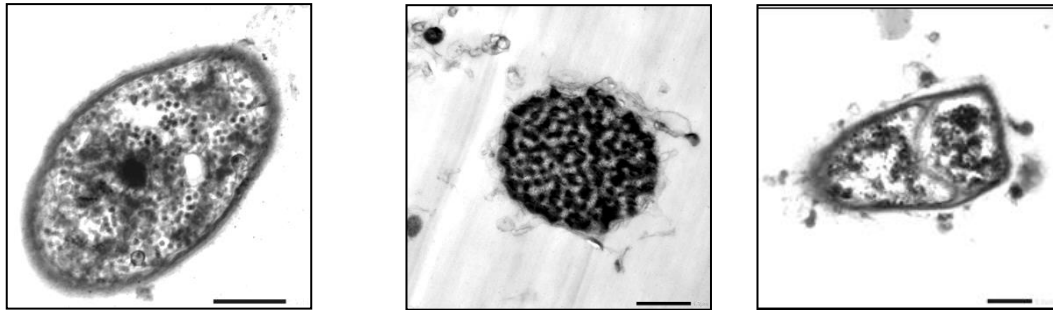
Great and variable effects were noticed on the fungal cells treated with MIC of ethanolic extract of *Senna occidentalis*; as Photo (3-d) illustrated complete rupture of cell wall, cell membrane, elongation and deformation of cell shape; more condensed cytoplasmic agglutination, disintegration of nuclear membrane, shrinking of cytoplasm and leakage of intracellular component outside the damage cell boundaries.



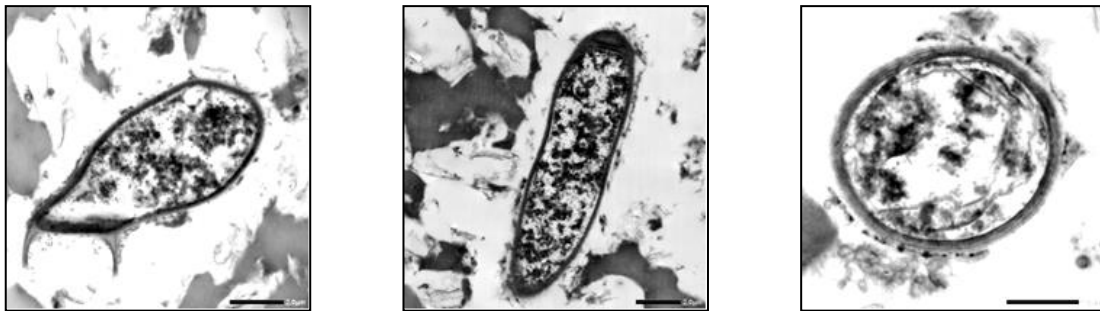a) -ve control: intact cells of non-treated growth of *Aspergillus flavus*.



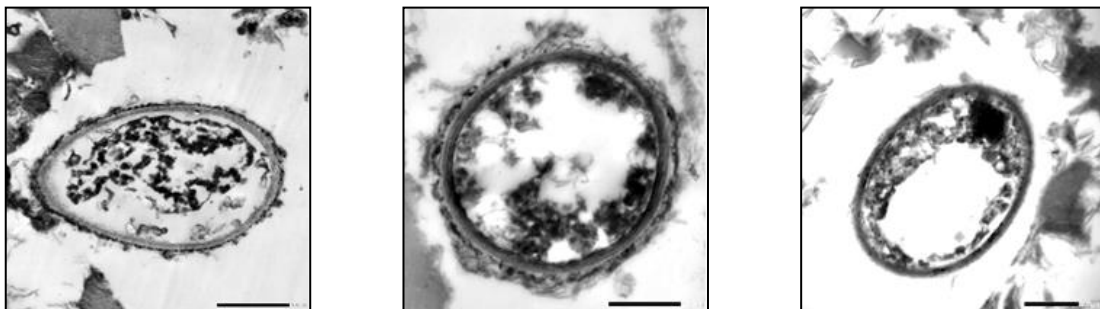
b) +ve control: effect of fluconazole (150 mg/ml) on growth of *Aspergillus flavus*.



c) Effect of combined treatment of *Senna occidentalis* ethanolic extract with MIC and fluconazole commercial concentration (150 mg/ml) on growth of *Aspergillus flavus*.



d) Effect of MIC of *Senna occidentalis* ethanolic extract on growth of *Aspergillus flavus*.



e) Effect of double MIC of *Senna occidentalis* ethanolic extract on growth of *Aspergillus flavus*.

Photo (3): Antifungal effects of *Senna occidentalis* ethanolic extract on the cellular ultrastructure of *Aspergillus flavus* by TEM examination (6000X); compared with control and fluconazole-treated fungal cells.

For more confirmation of the effect of higher dose, the double MIC of *Senna occidentalis* ethanolic extract that was applied on *Aspergillus flavus* growth, showing great destructive effects that elucidate the antifungal activity of the selected plant extract with higher dose to insure the reach of the effective amounts of active ingredients to the target fungal cells within the host tissues. That was clearly illustrated in Photo (3-e), showing higher rate of cytoplasmic shrinkage, leakage of almost cell components, larger vacuolation, complete nucleus disintegration and complete agglutination of intracellular protein, leading to complete stopping of cellular metabolic activities.

4. DISCUSSION

Ulcerative keratitis is a common case among patients coming to out-patient clinic of Ophthalmology Hospital, Tanta University, during the year of survey (2022). Seasonal variation is a great factor affecting the spread of different types of infectious corneal ulcer. It was clear that spring season recorded the highest frequency of corneal ulcers in the present survey; followed by summer season. Kate and Basu [27] recorded a similar survey in the United Kingdom, with estimates for mycotic keratitis ranged from 20 to 30 patients per million annually. Another study in Ethiopia by Wuletaw et al. [28] revealed that trauma was the most relevant risk factor associated with corneal ulcers, whereas their primary causative agents were fungi.

Eyes infected with isolated fungi, represent the severity of mycotic keratitis and their complications, that ranged from faint corneal scarring, active keratitis with hypopyon, corneal melting, perforation, to severe endophthalmitis. This type was more abundant among male patients of age ranged between 20 - 50 years; inhabiting rural houses; represented mostly among students and indoor workers, that were closely related to commercial contact lenses usage. Whereas *Aspergillus flavus* was more frequent, followed by *Aspergillus niger* among mycotic ulcers of the present survey. Several studies recorded that members of *Aspergillus* are wide spread fungi, inhabiting indoor air, dust, soils and plant residues; such as *A. parasiticus* and *A. flavus* [29]. Medeiros and Santhiago [30] stated that females were generally more affected by fungal infections, with more complications accompanying the prolonged course of eye invasion. That may be related to continuous steroid doses and use of contaminated contact lenses. Blindness (<3/60) was presented in 90% of the fungi-infected eyes in middle Africa [28]. They also reported that the commonest fungal and bacterial isolates were *Aspergillus* species and *S. aureus*. Timlin et al. [31] referred signs of mycotic infection in peripheral and central cornea, that were susceptible to ulceration, inflammation, neural sensitivity in the peripheral more than the central cornea. The thickening of the peripheral cornea and epithelium deformation may be tightly adherent to the corneal basement membrane and stroma in the infected cases.

Some Egyptian wild plants were evaluated for their antifungal activity; the most effective plant extract against *A. flavus* was *Senna occidentalis* (with MIC = 12.5 mg/ml), followed by *Pulicaria undulata* (25 mg/ml), then *Aerva Jovanica* (50 mg/ml). These effects were confirmed by TEM examination of *Senna occidentalis* treatment on *Aspergillus flavus*, showing complete rupture of cell wall, cell, nuclear membranes, deformation of cell shape, cytoplasmic agglutination, and leakage of intracellular components. El-Desouky [32] reported a promising antifungal activity of some wild Egyptian edible plant, as *Sonchus oleraceus*, *Cichorium pumilum* and *Portulaca oleracea* recorded MIC of 1.5, 2.5 and 5 mg/ml against *Aspergillus flavus*, respectively. An Asian study confirmed the antifungal activity of *Senna occidentalis* extract with concentration of 3% against the soil borne fungus *Macrophomina phaseolina* [33]. Another recent study on the response of mycotic keratitis against natural and synthetic agents revealed high efficiency of plant extracts to heal fungal infections of human eyes caused by *Fusarium* sp. due to their multi-effect of their mixed ingredients as anti-inflammatory and antimicrobial actions, which was lacking for fluconazole and other synthetic agents with only antifungal action, expected fungal resistant and host side effects [1].

5. CONCLUSION

It was observable that fungal corneal infections were more common during summer season (48 cases), then spring (26 cases), 2022. This type was more abundant among male patients of age ranged between 20 - 50 years (43 cases out of 100 total mycotic ulcers); in habiting rural houses (78 cases); represented mostly among students and indoor workers (45 cases), that were closely related to commercial contact lenses usage (37 cases). *Aspergillus flavus* was more frequent (58 cases), followed by *Aspergillus niger* (22 cases) among the isolated 100 mycotic ulcers. The most effective plant extracts against *A. flavus* recorded MIC values of 12.5 mg/ml for *Senna occidentalis*, followed by 25 mg/ml for *Pulicaria undulata*, then 50 mg/ml for *Aerva Jovanica*. TEM showed the effect of *Senna occidentalis* on *Aspergillus flavus*, with complete rupture of cell wall, cell membrane, elongation, deformation of cell shape, cytoplasmic agglutination, disintegration of nuclear membrane, shrinking of cytoplasm and leakage of intracellular component outside the damage cell boundaries.

6. RECOMMENDATION

The promising antifungal activity of *Senna occidentalis* ethanolic extract against the most common fungal isolate among mycotic keratitis cases, *Aspergillus flavus*, encouraged researchers to do more detailed studies on the safety of this extract usage on the experimental animal eye tissues and other systemic physiological functions; as a preliminary step for achieving further drug licencing requirements.

Conflict of interest: There is no conflict of interest.

Data availability: Raw data were generated at Faculty of Science, Tanta University, Egypt. Derived data supporting the findings of this study are available from the corresponding author Prof. Dr.: Anwer S.M. El-Badry upon request.

Authors contribution:

Saida M. Amer: General supervision, sharing in the research point choice.

M. Sameh El-Shourbagy: Supervision of dealing with patient as a medical supervisor according to the rules of the Research Ethics Committee.

Khalil M. Saad-Allah: Collection of wild plant and supervision of plant extraction and characterization.

Eman El-Mowafy: Ph. D. student, performing all practical work, sharing in writing the article.

Anwer S.M. El-Badry: Sharing in point choice, supervision of microbiology work, main writing of article, result presentation and discussion.

7. REFERENCES

- [1] P. Reginatto, G. de J. Agostinetto, R. do N. Fuentefria, D. R. Marinho, M. D. Pizzol, and A. M. Fuentefria, "Eye fungal infections: a mini review," *Arch. Microbiol.*, vol. 205, no. 6, p. e236, 2023, doi: 10.1007/s00203-023-03536-6.
- [2] C. B. Estopinal and M. D. Ewald, "Geographic disparities in the etiology of bacterial and fungal keratitis in the United States of America," *Semin. Ophthalmol.*, vol. 31, no. 4, pp. 345–352, 2016, doi: 10.3109/08820538.2016.1154173.
- [3] L. Kredics *et al.*, "Filamentous fungal infections of the cornea: A global overview of epidemiology and drug sensitivity," *Mycoses*, vol. 58, no. 4, pp. 243–260, 2015, doi: 10.1111/myc.12306.
- [4] N. Sharma *et al.*, "Fungal keratitis: A review of clinical presentations, treatment strategies and outcomes," *Ocul. Surf.*, vol. 24, pp. 22–30, 2022, doi: <https://doi.org/10.1016/j.jtos.2021.12.001>.

- [5] S. Verma *et al.*, “Current spectrum of oculomycosis in North India: A 5-year retrospective evaluation of clinical and microbiological profile,” *Indian J. Med. Microbiol.*, vol. 34, no. 1, pp. 72–75, 2016, doi: <https://doi.org/10.4103/0255-0857.174104>.
- [6] E. J. Holland, M. Fingeret, and F. S. Mah, “Use of topical steroids in conjunctivitis: a review of the evidence,” *Cornea*, vol. 38, no. 8, pp. 1062–1067, 2019.
- [7] R. Dangarembizi, S. Wasserman, and J. C. Hoving, “Emerging and re-emerging fungal threats in Africa,” *Parasite Immunol.*, vol. 45, no. 2, p. e12953, 2023, doi: <https://doi.org/10.1111/pim.12953>.
- [8] R. Jadon and S. Dixit, “Phytochemical extraction and antimicrobial activity of some medicinal plants on different microbial strains Photochemical extraction and antimicrobial activity of some medicinal plants on different microbial strains,” *J. Med. Plants Stud.*, vol. 2, no. 3, pp. 58–63, 2014, [Online]. Available: www.plantsjournal.comwww.plantsjournal.com
- [9] R. Al-Tohamy *et al.*, “Phytochemical analysis and assessment of antioxidant and antimicrobial activities of some medicinal plant species from Egyptian flora,” *J. Appl. Biomed.*, vol. 16, no. 4, pp. 289–300, 2018.
- [10] M. S. Osato, N. M. Robinson, K. R. Wilhelmus, and D. B. Jones, “*In vitro* evaluation of antimicrobial compounds for cysticidal activity against *Acanthamoeba*,” *Rev. Infect. Dis.*, vol. 13, no. 5, pp. 431–435, 1991, doi: 10.1093/clind/13.Supplement_5.S431.
- [11] J. Chander and A. Sharma, “Prevalence of fungal corneal ulcers in Northern India,” *Infection*, vol. 22, no. 3, pp. 207–209, 1994, doi: 10.1007/BF01716706.
- [12] P. A. Thomas, “Mycotic keratitis — an underestimated mycosis,” *J. Med. Vet. Mycol.*, vol. 32, no. 4, pp. 235–256, 1994, doi: 10.1080/02681219480000321.
- [13] J. Herbert and B. Michael, “Bacterial and fungal keratitis,” *Med. Clin. North Am.*, vol. 3, pp. 454–58, 1990.
- [14] C. Margo and J. Brinser, *Microbiologic diagnosis: Mycology: Laboratory diagnosis in ophthalmology*. McMillan Press, New York, USA, 1987.
- [15] A. Moubasher, *Soil fungi in Qatar and other Arab countries*. Doha, Qatar: Qatar University Press, 1993.
- [16] M. A. Klich, *Identification of common Aspergillus species*. CBS, 2002.
- [17] R. A. Samson, J. Houbraeken, U. Thrane, J. C. Frisvad, and B. Andersen, *Food and indoor fungi*. Utrecht, Netherlands: CBS-KNAW-Fungal Biodiversity Center, 2010.
- [18] A. J. Barrett, C. G. Knight, M. A. Brown, and U. Tisljar, “A continuous fluorimetric assay for clostridial collagenase and Pz-peptidase activity,” *Biochem. J.*, vol. 260, no. 1, pp. 259–263, May 1989, doi: 10.1042/bj2600259.
- [19] R. R. M. Paterson and P. D. Bridge, *Biochemical techniques for filamentous fungi*. CAB International, 1994.
- [20] B. Keil, A.-M. Gilles, A. Lecroisey, N. Hurion, and N.-T. Tong, “Specificity of collagenase from *Achromobacter iophagus*,” *FEBS Lett.*, vol. 56, pp. 292–297, 1975.
- [21] M. M. Bradford, “A rapid and sensitive method for the quantitation of microgram quantities of protein utilizing the principle of protein-dye binding,” *Anal. Biochem.*, vol. 72, no. 1–2, pp. 248–254, 1976, doi: 10.1016/0003-2697(76)90527-3.
- [22] W. A. Kasim, K. M. Saad-Allah, and M. Hamouda, “Seed priming with extracts of two seaweeds alleviates the physiological and molecular impacts of salinity stress on radish (*Raphanus sativus*),” *Int. J. Agric. Biol.*, vol. 18, no. 3, p. 653–660, 2016, doi: 10.17957/IJAB/15.0152.
- [23] T. Pridham *et al.*, “Antibiotics against plant diseases: A laboratory and green house survey,” *Phytopathology*, vol. 46, pp. 568–575, 1956.
- [24] S. Shadomy, “Laboratory studies with antifungal agents: susceptibility tests and bioassays,” in *Manual of clinical microbiology*, 4th ed., L. A. B. W, H. H, and S. S, Eds. Boston, MA, USA: American Society for Microbiology, 1985, pp. 991–999.

- [25] R. M. E. Richards and R. H. Cavill, "Electron Microscope Study of Effect of Benzalkonium Chloride and Edetate Disodium on Cell Envelope of *Pseudomonas aeruginosa*," *J. Pharm. Sci.*, vol. 65, no. 1, pp. 76–80, 1976, doi: <https://doi.org/10.1002/jps.2600650115>.
- [26] M. Von Ardenne and D. Beischer, "Untersuchung von Metalloxyd-Rauchen mit dem Universal-Elektronenmikroskop," *Zeitschrift fur Elektrochemie und Angew. Phys. Chemie*, vol. 46, no. 4, pp. 270–277, 1940.
- [27] A. Kate and S. Basu, "Systemic Immunosuppression in Cornea and Ocular Surface Disorders: A Ready Reckoner for Ophthalmologists," *Semin. Ophthalmol.*, vol. 37, no. 3, pp. 330–344, 2022, doi: 10.1080/08820538.2021.1966059.
- [28] T. Wuletaw, M. Geta, A. Bitew, W. Mulugeta, and B. Gelaw, "Clinical and Microbiological Profile of Bacterial and Fungal Suspected Corneal Ulcer at University of Gondar Tertiary Eye Care and Training Centre, Northwest Ethiopia," *J. Ophthalmol.*, vol. 2021, p. e3940151, 2021, doi: 10.1155/2021/3940151.
- [29] P. Kumar, D. K. Mahato, M. Kamle, T. K. Mohanta, and S. G. Kang, "Aflatoxins: A global concern for food safety, human health and their management," *Front. Microbiol.*, vol. 7, no. JAN, p. e2170, 2017, doi: 10.3389/fmicb.2016.02170.
- [30] C. S. Medeiros and M. R. Santhiago, "Corneal nerves anatomy, function, injury and regeneration," *Exp. Eye Res.*, vol. 200, p. e108243, 2020, doi: <https://doi.org/10.1016/j.exer.2020.108243>.
- [31] H. M. Timlin, H. N. Hall, B. Foot, and P. Koay, "Corneal perforation from peripheral ulcerative keratopathy in patients with rheumatoid arthritis: epidemiological findings of the British Ophthalmological Surveillance Unit," *Br. J. Ophthalmol.*, vol. 102, no. 9, pp. 1298–1302, 2018, doi: 10.1136/bjophthalmol-2017-310671.
- [32] T. A. El-Desouky, "Evaluation of effectiveness aqueous extract for some leaves of wild edible plants in Egypt as anti-fungal and anti-toxigenic," *Heliyon*, vol. 7, no. 2, p. e06209, 2021, doi: 10.1016/j.heliyon.2021.e06209.
- [33] A. Javaid, H. Qudsia, I. H. Khan, A. Anwar, and M. F. H. Ferdosi, "Antifungal activity of *Senna occidentalis* root extract against *Macrophomina phaseolina* and its GC-MS analysis," *Pakistan J. Weed Sci. Res.*, vol. 28, no. 1, pp. 115–122, 2022.