

## Research Article

# Towards a Synergistic Grading System for Mucoepidermoid Carcinoma

Fatemeh Elham and Esam Mandour

## Abstract

**Background** Mucoepidermoid carcinoma (MEC) is a diverse salivary gland malignancy with varied prognostic outcomes. Different grading systems have been proposed, each with its complexities and merits.

**Objective** This study seeks to harness the precision of MEC assessment by synergistically consolidating established grading systems.

**Method** We evaluated primary MEC cases (2016-2022) using four prominent grading systems: modified Healey, AFIP, Brandwein, and Katabi. An algorithm was devised to integrate these systems and derive average scores harmoniously. The impact on overall survival, disease-free measures, and recurrence was investigated.

**Results** The integrated grading algorithm yielded a holistic perspective, enhancing the prognostic significance of MEC grading. Brandwein's high-grade designation emerged as a potent predictor of aggressive behavior. Our approach unveiled nuanced relationships between morphological features and outcomes, offering an avenue for targeted therapeutic decisions.

**Advances in Knowledge** In assessing MEC, this study offers a novel approach—a unified grading system that draws strength from multiple established paradigms. By orchestrating this synergistic approach, clinicians and pathologists can navigate the complexity of MEC with enhanced precision, aiding in prognosis determination and informed therapeutic interventions.

**Keywords:** Mucoepidermoid carcinoma, Grading, Survival, AFIP, Salivary gland tumors

1. Department of Pathology, Islamic Azad University of Ardabil, Iran Email: [f.elham@iauar.dabil.ac.ir](mailto:f.elham@iauar.dabil.ac.ir)

2. Department of Pathology, Badr University in Cairo (BUC), Badr City | 1829, Egypt Email: [essam.mohammed@buc.edu.eg](mailto:essam.mohammed@buc.edu.eg)

DOI: 10.21608/aced.2023.232002.1022

## Introduction

The grading of mucoepidermoid carcinoma (MEC) using the Brandwein[1], AFIP[2], Katabi[3], and modified Healey systems exhibits inconsistencies and limitations in accurately predicting the behavior and prognosis of MECs. The Brandwein high grade category is the most reliable predictor of aggressive behavior. A simplified binary grading system based on the Brandwein system was proposed to enhance clarity and better align grading with the potential clinical implications of MEC behavior [4]. This approach was not well received because the historical familiarity and resistance to change among pathologists and clinicians worked against the adoption of a 3-grade system. Established systems often become ingrained in surgical pathology, and reluctance to transition to a new grading system might emerge, especially if its validity and effectiveness have not been widely demonstrated.

Ultimately, several grading systems for MEC failed to gain popularity[5–8]; however, a 3-grade system with a clear distinction between low, intermediate and high-grade tumors can capture the essential differences in tumor behavior and prognosis. This type of system aims to provide a balanced framework that is often sufficient, to allow clinicians to differentiate between tumors with a higher risk of recurrence or adverse outcomes and those with a more favorable prognosis[9]. Presenting measures for multiple grading systems is now a solicited approach when grading MEC given that no definitive consensus has been reached regarding which system might be superior[10].

We examined the grading of 52 mucoepidermoid carcinomas (MECs) using a straightforward algorithm that combines both the Brandwein and AFIP grading systems, by calculating the mean of the two scores and propose the corresponding grade. Besides, we analyzed the correlation between the algorithm's output and overall survival, disease-free survival, disease-specific survival measurement, and recurrence rates.

## Method

### *Cases selection*

Following Katabi et al. [3], we examined 52 primary mucoepidermoid carcinoma (MEC) cases from the diagnostic surgical pathology database from 2016 to 2022. Our inclusion criteria encompassed resection specimens from major and minor salivary glands, while MEC cases originating outside the head and neck were excluded. Retrieving diagnostic hematoxylin and eosin (H&E) slides and formalin-fixed paraffin-embedded (FFPE) blocks from the surgical pathology archives, the grading features were charted along with the clinical data and overall survival.

### *Molecular labeling*

Regarding the assessment of *MAML2* Rearrangement, we selected FFPE cases with available tissue blocks that were rich in tumor material. We conducted fluorescence in situ hybridization (FISH) targeting the *MAML2* gene to investigate so. This procedure

involved utilizing dual-color break-apart probes designed for the *MAML2* gene. The 5' *MAML2* gene fragment was tagged with ZyGreen, while the 3' *MAML2* gene fragment was labeled with ZyOrange. This FISH kit was sourced from Zytovision, a company based in Bremerhaven, Germany. The steps for this procedure included deparaffinization using CitriSolv performed three times for 10 minutes each, followed by dehydration with 100% ethanol twice for 5 minutes each. Subsequently, the tissue sections underwent treatment with 0.2N Hydrochloric acid for 30 minutes at room temperature, followed by Sodium Thiocyanate treatment for 30 minutes at 80°C. The digestion of tissue sections was carried out using a protease solution provided by Sigma-Aldrich.

### *Grading MECs*

MECs were assigned a grade, referencing four well-established grading systems: (a) the modified Healey system by Batsakis and Luna; (b) the AFIP system[2]; (c) the system introduced by Brandwein et al.[1]; and (d) the system developed by Katabi et al.[3]. We also calculated the mean score from the Brandwein and AFIP systems. Additionally, we documented the grade initially determined by the diagnosing pathologist for correlation.

### *Algorithm assessment*

The algorithm calculates scores for the AFIP and Brandwein grading systems and an average score. The grades are determined based on predefined score ranges. The algorithm retrieves input values related to various histological features of MEC, such as cystic/solid component ratio, perineural invasion, necrosis, mitoses, anaplasia, lymphovascular invasion, aggressive pattern of invasion, and bony invasion. It then calculates scores for both the AFIP and Brandwein systems using conditional statements and adds them to the corresponding variables. The calculated scores are used to determine grades according to predefined score ranges, and the average score is calculated as the mean of the AFIP and Brandwein scores. Finally, the algorithm displays the individual input values, the calculated scores and grades for both systems, and the average score and average grade, as follows.

```

FUNCTION calculateGrades():
  DECLARE afipScore, brandweinScore = 0
  FOR each criterion:
    IF meetsAFIPCriterion(criterion) THEN afipScore += afipScoreFor(criterion)
    IF     meetsBrandweinCriterion(criterion)     THEN     brandweinScore     +=
brandweinScoreFor(criterion)
  DISPLAY results(afipScore, brandweinScore)
FUNCTION meetsAFIPCriterion(criterion) and meetsBrandweinCriterion(criterion):
  RETURN result
FUNCTION afipScoreFor and brandweinScoreFor:
  RETURN score

```

```
FUNCTION results(afipScore, brandweinScore):
  DECLARE afipGrade = calculateGradeFromScore(afipScore)
  DECLARE brandweinGrade = calculateGradeFromScore(brandweinScore)
  DECLARE averageScore = (afipScore + brandweinScore) / 2
  DECLARE averageGrade = calculateGradeFromScore(averageScore)
  RETURN afipScore, afipGrade, brandweinScore, brandweinGrade, averageScore,
  averageGrade)
FUNCTION calculateGradeFromScore(score):
  FUNCTION formattedResults(afipScore, afipGrade, brandweinScore, brandweinGrade,
  averageScore, averageGrade):
    RETURN "AFIP Score:", afipScore, "AFIP Grade:", afipGrade, "Brandwein Score:",
    brandweinScore, "Brandwein Grade:", brandweinGrade, "Average Score:", averageScore,
    "Average Grade:", averageGrade.
```

### *Statistical analysis*

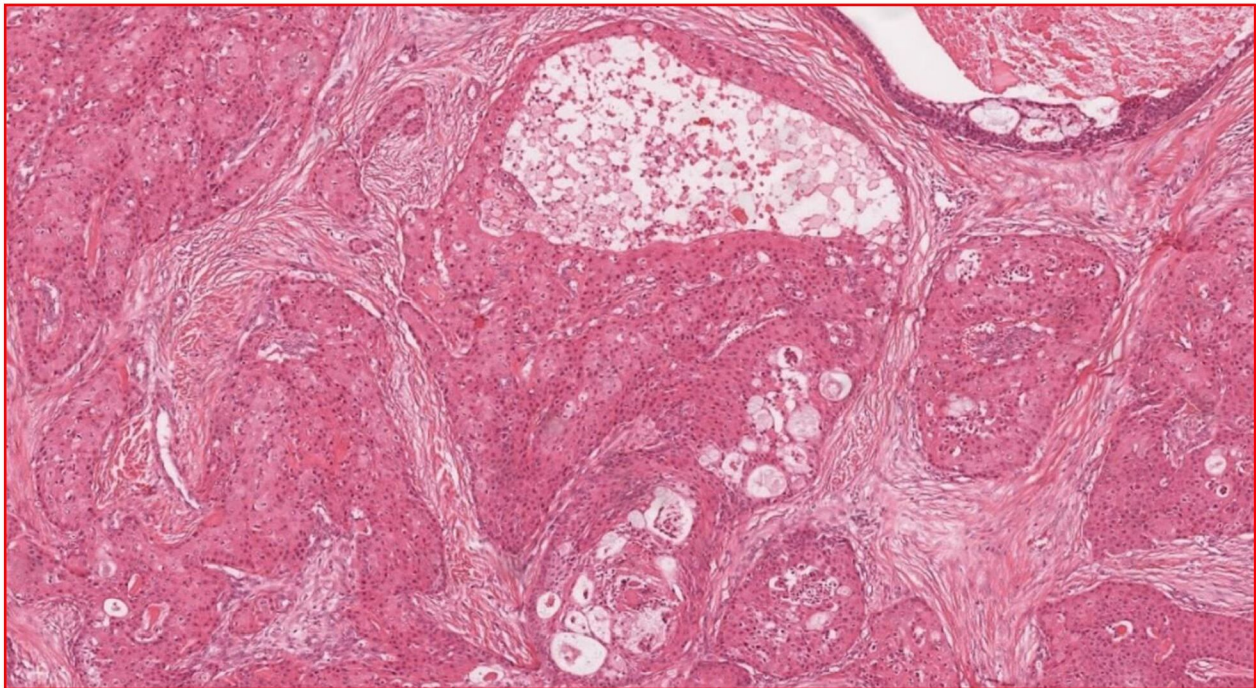
The Kaplan-Meier analyses were employed to compute overall survival (OS), time to first metastases, and disease-free survival (DFS). The clinical impact of the variables under investigation was evaluated using the Wilcoxon test, log-rank test, and Cox regression hazard model, which also included the calculation of hazard ratios (HR). Multivariate analysis was conducted as well. The C & RTs (classification and regression tree) method was used to calculate outcomes for OS and DFS. All survival graphs were generated using R. Statistical significance was established at a 5% significance level.

### **Results**

The analysis methodically examines tumors, considering distinct attributes and criteria to determine their nature and severity. The tumors are categorized by evaluating cystic/solid component ratio, perineural invasion, necrosis, mitoses, anaplasia, angiolymphatic invasion, aggressive pattern of invasion, and bony invasion. The grading and scoring for the examined cases are shown in the [Supplementary Material](#).

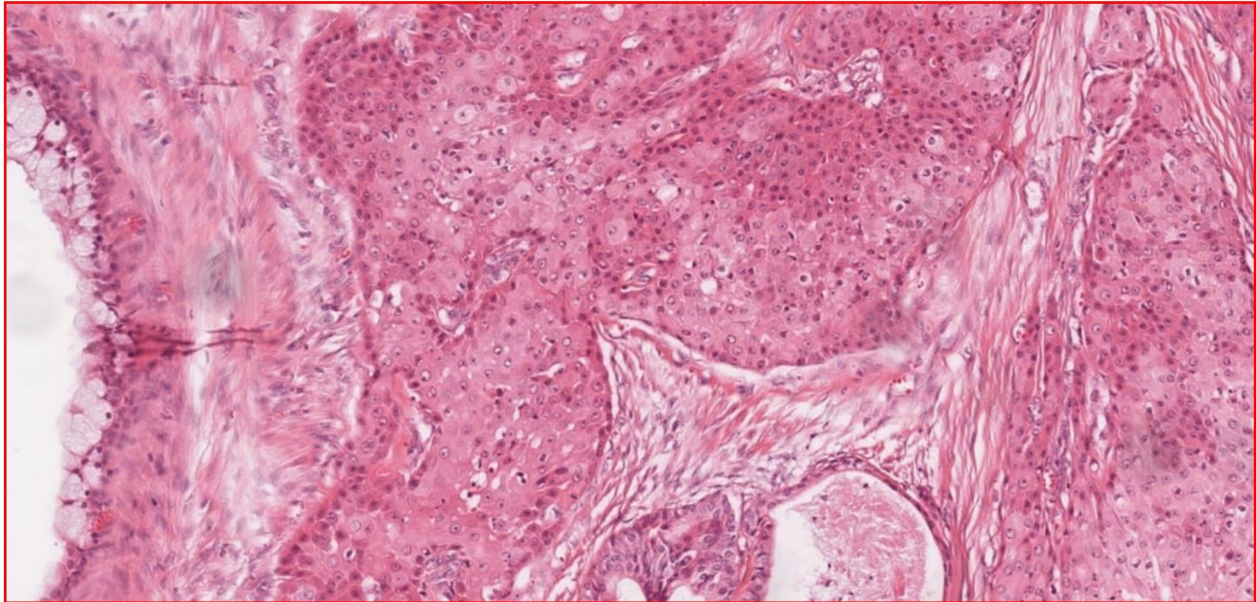
MECs exhibited a prevailing inclination toward a solid structural composition in three cases. While perineural invasion was apparent, no necrosis was found. The tumors demonstrated abnormal mitotic activity. Anaplasia was evident within the tumor cells, in contrast to the absence of angiolymphatic invasion. Concurrently, an evident pattern of aggressive infiltration was observed within the surrounding tissue but devoid of any concurrent indications of bony invasion. Applying the AFIP assessment, the assigned score was 9 and the grade was high. In tandem, the Brandwein Score was 10, corresponding to a Brandwein Grade classified as high. Upon meticulous calculation of the average outcomes, the average score was 9.5, accompanied by a corresponding grade aligned with the high-grade classification. These cases showed consistency between all measurements.

In four cases demonstrating the following attributes, the cystic/solid component ratio was solid, and no perineural invasion was noted. Necrosis was present, while mitoses were minimal. Tumor cells exhibited no anaplastic features and no evidence of angiolymphatic invasion or an aggressive pattern of invasion. However, neoplastic cells invaded the blood and lymphatic vessels and infiltrated the surrounding adipose tissue. Additionally, invasion into bone tissue was evident. The AFIP results revealed an AFIP score of 3, classifying the tumour as low-grade according to the AFIP criteria. By contrast, the Brandwein score was 6, resulting in a high-grade classification based on Brandwein's criteria. The average score was 4.5, corresponding to an intermediate-grade categorization (Figure 1).



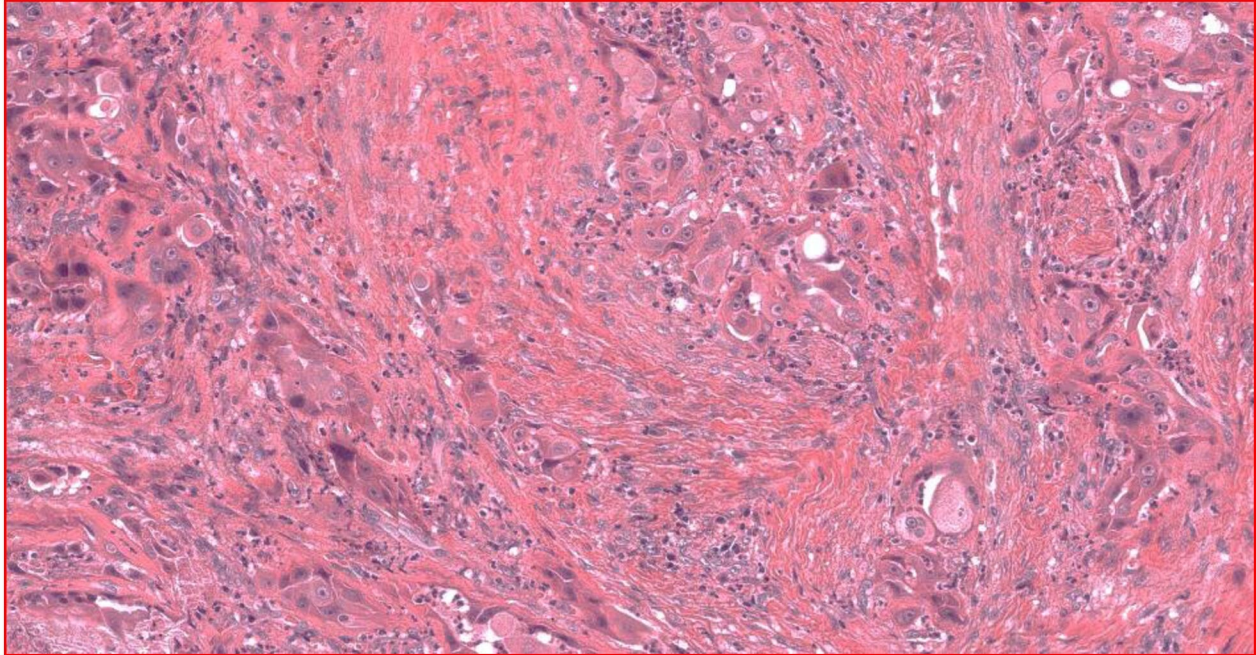
**Figure 1.** MEC reclassified as intermediate-grade

In five MECs, the cases displayed a predominantly solid structure, with an absence of invasion around nerves and no presence of necrosis. However, abnormal mitotic activity within the tumour was notably high. The tumor cells exhibited normal morphology, with no anaplastic features. A few neoplastic cells had invaded the blood and lymphatic vessels and infiltrated the surrounding adipose tissue, but no invasion into bone tissue was evident. The tumour was categorised as low-grade according to the AFIP criteria, but as high-grade according to Brandwein's criteria. The tumor fell into the intermediate-grade category on average (Figure 2).



**Figure 2.** MEC reclassified as intermediate-grade

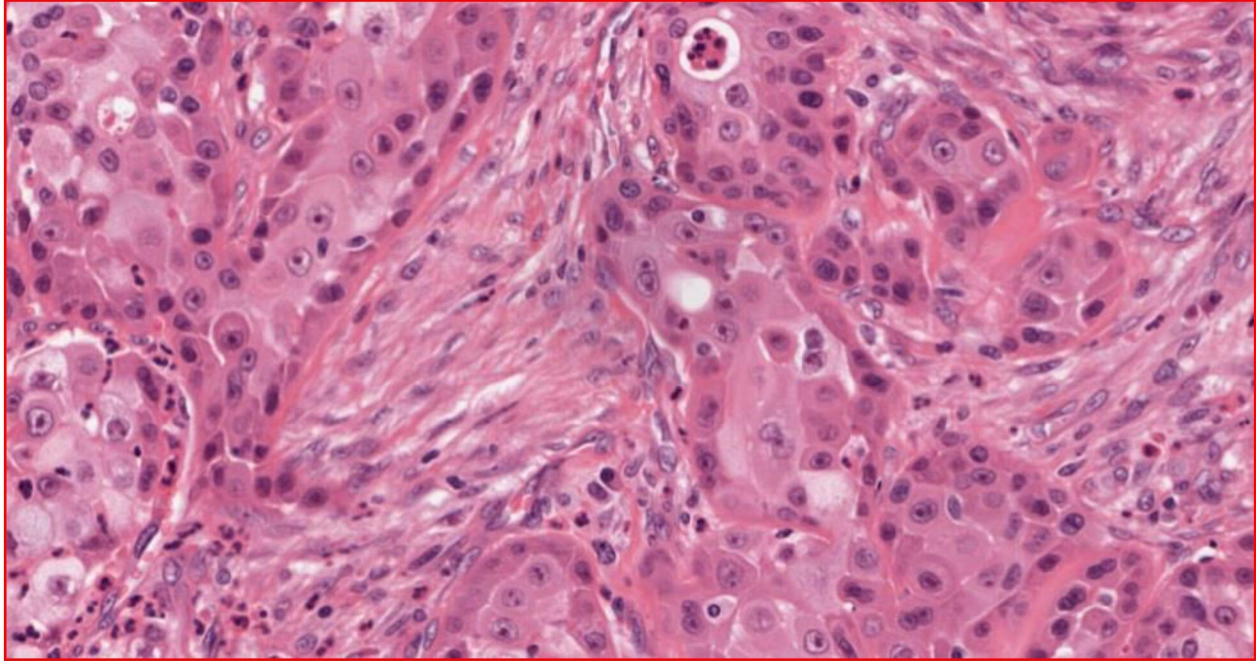
In two cases, the tumors demonstrated a prevalent inclination towards a solid structural composition. While perineural invasion was evident, the absence of necrosis was particularly notable. Anaplasia was manifested within the tumor cells, in contrast to the apparent lack of angiolymphatic invasion. Simultaneously, a discernible pattern of aggressive infiltration, conspicuously lacking bony invasion, emerged within the surrounding tissue. From the AFIP assessment, the assigned score and grade stood at high and low, respectively. Concurrently, the computed results aligned with the Brandwein evaluation (Brandwein Score: 11, Brandwein Grade: High-grade). After calculating the aggregate results, the average score was 7, accompanied by an average grading corresponding to the high-grade MEC classification ([Figure 3](#)).



**Figure 3.** Examples for MEC classified as high-grade

The cystic/solid component ratio signified a pronouncedly solid structure. Perineural invasion was observed, while necrosis was conspicuously absent. The tumor exhibited remarkable mitotic activity. Anaplasia was not discernible within the tumor cells. Lymphovascular invasion was present, accompanied by an aggressive pattern of infiltration that manifested within the surrounding tissue. Bony invasion was evident. In terms of AFIP assessment, the grade fell within the Intermediate-grade range. The Brandwein Score was reported as 14, corresponding to a Brandwein Grade of High-grade. Upon computation of the aggregate results, the average score attained a value of 9.50, paralleled by an average grade aligned with the high-grade classification (Figure 4). All other cases were classified as low-grade MECs.

The mean time to metastasis occurrence was 80.4 months, with a standard deviation of 0.2 months. Furthermore, a differentiation was made between intermediate- and high-grade tumours versus low-grade tumors. The aim of this distinction was to dissect the potential impact of tumor grade on nodal metastatic behavior. We computed the average OS duration as 73 months, with a standard deviation of 0.23 months. Furthermore, hazard ratio (HR) analysis was strategically employed to elucidate the impact of grade 3 tumors on survival outcomes. High-grade MEC exhibited a 2.31 times higher risk of negative outcomes compared to other grades, emphasizing the significance of tumor grade in influencing survival trajectories. The hazard ratio for worse OS increased significantly, quantified at HR 3.03 ( $P < 0.0001$ ).



**Figure 4.** Examples for MEC classified as high-grade

This finding accentuates the importance of disease staging in prognosticating patient survival. Additionally, the influence of the pT stage on mortality risk revealed a four times higher likelihood of mortality ( $P < 0.0001$ ). The age of patients emerged as a pertinent determinant. Those above 55 years exhibited a notably elevated hazard ratio of 16.787 ( $P < 0.0002$ ), indicating a heightened risk profile. The impact of gender on survival was not found to be significant ( $P = 0.23$ ). Females demonstrated comparatively lower survival rates. Prominently, female patients were 3.21 times higher risk of disease-related mortality than their male counterparts. The influence of tumoral site, specifically minor versus major salivary gland sites, was examined, revealing no statistical significance ( $P = 0.323$ ).

Mirroring OS in its significance led to the computation of an average DFS of 72 months, accompanied by a standard deviation of  $\pm 0.46$  months. This temporal insight into the duration of disease remission provides a crucial perspective on the disease trajectory. The focus on high-grade tumors within the context of disease-related death risk unearthed a striking observation. High-grade tumors were associated with a noteworthy 3.73 times higher risk of disease-related death compared to other grades ( $P < 0.0001$ ). The investigation extended to pT stage and its association with increased mortality risk. Each step increase in pT stage was tied to a significant 5 times higher mortality risk ( $P < 0.0001$ ). Expanding the purview of gender's impact, the study established that gender was not a significant factor influencing disease-free survival ( $P = 0.374$ ). Additionally, within the realm of low-grade mucoepidermoid carcinoma, the analysis yielded a remarkable finding—patients faced a notably reduced risk of recurrence or death, marked at 12.4 times lower compared to other grades ( $P = 0.0497$ , CI = 1.003-2.236). The results of the statistical analysis are shown in [Table 1](#).



Table 1. Results of survival analysis

Parameter	Description
<b>Metastasis and Tumor Grade:</b>	
Mean Time until Metastasis	96 months (SD = 0.23 month)
Tumor Grade and Distant Metastasis	Distant metastasis risk was not high
Intermediate- and high-grade vs low-grade	Shorter time to distant metastases (log-rank test $P < 0.0001$ )
Regression Hazard Model	Estimated risk: 4.5 ( $P < 0.0001$ )
<b>Overall Survival (OS) and Risk Factors:</b>	
Average OS	86 months (SD = $\pm 0.55$ month)
HR Analysis for High-grade MEC	2.31 times higher risk ( $P < 0.0001$ )
Worse OS	HR 3.03 ( $P < 0.0001$ ) for worse OS with higher stage
Increasing pT Stage and Mortality Risk	4 times higher risk ( $P < 0.0001$ )
> 55 years Risk Group	HR = 16.787 ( $P < 0.0002$ )
Gender Impact on Survival	Not significant ( $P = 0.23$ )
Males vs. Females in 5- and 10-Year OS	Lower for females
Female Disease Mortality Risk	3.21 times higher than males
Minor vs. major SG site Influence on OS	Not significant ( $P = 0.323$ )
<b>Disease-Free Survival (DFS) and Risk Factors:</b>	
Average DFS	survival: 72 months (SD = $\pm 0.46$ month)
High-grade Disease-Related Death	3.73 times higher risk than other grades ( $P < 0.0001$ )
Increased pT Stage	5 times higher risk ( $P < 0.0001$ )
Gender Impact on DFS	Not significant ( $P = 0.374$ )
Recurrence/Death in Low-Grade MEC	12.4 times lower risk than other grades ( $P = 0.0497$ , CI = 1.003-2.236)
High-grade Disease-Related Death	3.73 times higher risk than other grades ( $P < 0.0001$ )
<b>Multivariate Analysis and Prognostic Factors:</b>	
Stratification into Grades	Significant for both OS and DFS
Prognostic Factors for OS	pT stage, and grading
Ranking in Regression Tree for OS	pT stage more significant than grading system
Multivariate Analysis Predictors for DFS	Specific stage
Ranking in Regression Tree for DFS	pT stage more significant than grading system

A multivariate analysis using the Cox model was executed. This sophisticated analysis not only reaffirmed the significance of key variables but also illuminated their interplay. Stratification into different grade categories was meticulously conducted, revealing their profound impact on both OS and DFS. By pinpointing these distinct categories, the study unveiled a refined understanding of survival dynamics based on tumor grade. Furthermore, the multivariate analysis identified potent prognostic factors for OS, including pT stage, location, and score. To contextualize these findings, a regression tree analysis effectively ranked these factors in terms of their influence on OS outcomes. Similarly, predictors for DFS were unearthed using multivariate analysis, providing a holistic perspective on survival determinants. The resulting ranking in the regression tree for DFS underscored the pivotal role of pT stage and grade in influencing disease-free survival.

## Discussion

Introducing a new grading system or taxonomy requires rigorous validation[11] and a concerted effort to educate surgical pathologists on its nuances and implications. The preference for the AFIP system, despite the Brandwein system's better predictive value[4], can be strongly influenced by institutional practices, textbook endorsement, and regional trends, especially in Europe and the USA. Defining the grade upon which surgical and post-surgical decisions shall be made is a responsibility better thrown at institutions.

Although computing measures for all grading systems is transparent[12–15], it is not purposeful in terms of grading of MECs, leaving it all for clinical staging. Therefore, there is a need to provide one representative measure and stand by its value, although several attempts have failed [15,16]. A new grading system was proposed for secretory carcinoma (SC) based on analyzing 215 cases[17]. It adds a subclassification for abrupt high-grade transformation and customizes the parameters to the histologic features of SC. MEC differs from SC morphologically in a way that does not accept consolidating their grading systems. We believe that algorithmically integrating the two quantitative systems to compute the average values is more convenient for pathologists should they try to test their cases using the automatic grader here. However, there is a call for incorporating IHC markers and genetic alterations as prognosticators in grading MEC[18–22]. However, there is no consensus on this approach.

## Conclusion

The results from both the AFIP and Brandwein criteria further refine these categorizations. The AFIP score and grade and the Brandwein Score and Grade provide additional layers of assessment. These assessments lead to conclusions about the tumors' grades, differentiating between high-grade, low-grade, and intermediate-grade classifications. The limitation of this study is excluded non-salivary type MECs (including sinonasal MECs, thyroid MEC and thymic MECs). These tumors may reveal distinct molecular profiles and specific morphologic features.

**Notes:** None

**Acknowledgements:** None

**Funding resources:** None

**Conflict of interest:** The authors declare no conflict of interest.

## References

- [1] Brandwein MS, Ivanov K, Wallace DI, Hille JJ, Wang B, Fahmy A, et al. Mucoepidermoid carcinoma: A clinicopathologic study of 80 patients with special reference to histological grading. *Am J Surg Pathol* 2001;25:835–45. <https://doi.org/10.1097/00000478-200107000-00001>.
- [2] Goode RK, Auclair PL, Ellis GL. Mucoepidermoid carcinoma of the major salivary glands: Clinical and histopathologic analysis of 234 cases with evaluation of grading criteria. *Cancer* 1998;82:1217–24. [https://doi.org/10.1002/\(SICI\)1097-0142\(19980401\)82:7<1217::AID-CNCR2>3.0.CO;2-C](https://doi.org/10.1002/(SICI)1097-0142(19980401)82:7<1217::AID-CNCR2>3.0.CO;2-C).
- [3] Katabi N, Ghossein R, Ali S, Dogan S, Klimstra D, Ganly I. Prognostic features in mucoepidermoid carcinoma of major salivary glands with emphasis on tumour histologic grading. *Histopathology* 2014;65:793–804. <https://doi.org/10.1111/his.12488>.
- [4] Cipriani NA, Lusardi JJ, Mcelherne J, Pearson AT, Olivas AD, Fitzpatrick C, et al. Mucoepidermoid Carcinoma: A Comparison of Histologic Grading Systems and Relationship to MAML2 Rearrangement and Prognosis. *Am J Surg Pathol* 2019;43:885–97. <https://doi.org/10.1097/PAS.0000000000001252>.
- [5] Koblin I, Koch H. On the nature of mucoepidermoid tumours of major and minor salivary glands. *J Maxillofac Surg* 1974;2:19–25. [https://doi.org/10.1016/S0301-0503\(74\)80008-1](https://doi.org/10.1016/S0301-0503(74)80008-1).
- [6] Auclair PL, Goode RK, Ellis GL. Mucoepidermoid carcinoma of intraoral salivary glands evaluation and application of grading criteria in 143 cases. *Cancer* 1992;69:2021–30. [https://doi.org/10.1002/1097-0142\(19920415\)69:8<2021::AID-CNCR2820690803>3.0.CO;2-7](https://doi.org/10.1002/1097-0142(19920415)69:8<2021::AID-CNCR2820690803>3.0.CO;2-7).
- [7] Batsakis JG. Staging of salivary gland neoplasms: Role of histopathologic and molecular factors. *Am J Surg* 1994;168. [https://doi.org/10.1016/S0002-9610\(05\)80081-9](https://doi.org/10.1016/S0002-9610(05)80081-9).
- [8] Hicks MJ, El-Naggar AK, Flaitz CM, Luna MA, Batsakis JG. Histocytologic grading of mucoepidermoid carcinoma of major salivary glands in prognosis and survival: A clinicopathologic and flow cytometric investigation. *Head Neck* 1995;17:89–95. <https://doi.org/10.1002/hed.2880170203>.
- [9] Luo X-D, Han H. Prognostic analysis and nomogram establishment in patients with mucoepidermoid carcinoma of the tongue: a population-based study using the SEER database. *Eur Arch Oto-Rhino-Laryngology* 2022;279:1489–98. <https://doi.org/10.1007/s00405-021-06919-x>.
- [10] Bishop JA, Thompson LDR, Siegele B, Gagan J, Mansour M, Chernock RD, et al. Mucoepidermoid carcinoma may be devoid of squamoid cells by immunohistochemistry: expanding the histologic and immunohistochemical spectrum of MAML2- rearranged salivary gland tumours. *Histopathology* 2023. <https://doi.org/10.1111/his.14817>.
- [11] Bai S, Clubwala R, Adler E, Sarta C, Schiff B, Smith R V, et al. Salivary Mucoepidermoid Carcinoma: A Multi-Institutional Review of 76 Patients. *Head Neck Pathol* 2013;7:105–12. <https://doi.org/10.1007/s12105-012-0405-0>.
- [12] Lloyd S, Yu JB, Ross DA, Wilson LD, Decker RH. A Prognostic Index for Predicting Lymph Node Metastasis in Minor Salivary Gland Cancer. *Int J Radiat Oncol Biol Phys* 2010;76:169–75. <https://doi.org/10.1016/j.ijrobp.2009.01.021>.
- [13] Chan RC-L, Chan JY-W. Head and neck mucoepidermoid carcinoma: A curious association with second primary malignancy. *Otolaryngol - Head Neck Surg (United States)* 2014;151:797–801. <https://doi.org/10.1177/0194599814551131>.
- [14] Spellman J, Calzada G. Mucoepidermoid Carcinoma: A 23-Year Experience with Emphasis on Low-Grade Tumors with Close/Positive Margins. *Otolaryngol - Head Neck Surg (United States)* 2018;158:889–95. <https://doi.org/10.1177/0194599817751072>.
- [15] Grasl S, Janik S, Faisal M, Grasl MC, Pammer J, Weinreb I, et al. Influence of Grading on Management and Outcome in Mucoepidermoid Carcinoma of the Parotid – A Multi-institutional Analysis. *Laryngoscope* 2022. <https://doi.org/10.1002/lary.30135>.
- [16] Johnson DN, Onenerk M, Krane JF, Rossi ED, Baloch Z, Barkan G, et al. Cytologic grading of primary malignant salivary gland tumors: A blinded review by an international panel. *Cancer*

- Cytopathol 2020;128:392–402. <https://doi.org/10.1002/cncy.22271>.
- [17] Baněčková M, Thompson L, Hycza M, Vaněček T, Agaimy A, Laco J, et al. Salivary Gland Secretory Carcinoma: Clinicopathologic and Genetic Characteristics of 215 Cases and Proposal for a Grading System. *Am J Surg Pathol* 2023;47:661–77. <https://doi.org/10.1097/PAS.0000000000002043>.
- [18] Ellis MA, Graboyes EM, Day TA, Neskey DM. Prognostic factors and occult nodal disease in mucoepidermoid carcinoma of the oral cavity and oropharynx: An analysis of the National Cancer Database. *Oral Oncol* 2017;72:174–8. <https://doi.org/10.1016/j.oraloncology.2017.07.025>.
- [19] Ghosh-Laskar S, Murthy V, Wadasadawala T, Agarwal J, Budrukkar A, Patil N, et al. Mucoepidermoid carcinoma of the parotid gland: Factors affecting outcome. *Head Neck* 2011;33:497–503. <https://doi.org/10.1002/hed.21477>.
- [20] Nance MA, Seethala RR, Wang Y, Chiosea SI, Myers EN, Johnson JT, et al. Treatment and survival outcomes based on histologic grading in patients with head and neck mucoepidermoid carcinoma. *Cancer* 2008;113:2082–9. <https://doi.org/10.1002/cncr.23825>.
- [21] Janjua OS, Qureshi SM, Khan TS, Alamgir W. Bcl-2 protein expression in mucoepidermoid carcinoma of salivary glands: A single institution experience. *Hematol Oncol Stem Cell Ther* 2012;5:96–100. <https://doi.org/10.5144/1658-3876.2012.96>.
- [22] Shang X, Fang Q, Liu F, Wu J, Luo R, Qi J. Deep Parotid Lymph Node Metastasis Is Associated With Recurrence in High-Grade Mucoepidermoid Carcinoma of the Parotid Gland. *J Oral Maxillofac Surg* 2019;77:1505–9. <https://doi.org/10.1016/j.joms.2019.01.031>.