



Official Journal Issued by
Faculty of
Veterinary Medicine

Benha Veterinary Medical Journal

Journal homepage: <https://bvmj.journals.ekb.eg/>



Since 1990

Original Paper

Cellular Changes in the Thymus Gland induced by Hyperthyroidism and Melatonin Administration

Sara Habk1*, Mohamed Azab1, Randa Ismail1, Abeer Nafeaa1, Saad Shousha1,2

¹ Department of Physiology, Faculty of Veterinary Medicine, Benha University, Egypt

² Department of Biomedical Sciences, College of Veterinary Medicine, King Faisal University, Al-Ahsa 31982, Saudi Arabia

ARTICLE INFO

Keywords

Hyperthyroidism;
Melatonin;
Thyroid;
Thymus;
Bax expression.

Received 03/08/2023

Accepted 25/08/2023

Available On-Line

01/10/2023

ABSTRACT

The current research aimed to evaluate the effects of L-thyroxine-induced hyperthyroidism and melatonin administration on the histopathology of the thyroid and thymus glands and Bax immunoreactivity. The rats were divided into four groups, comprising ten rats each. Rats were given the following treatments for four weeks: Group I served as the control group; Group II received melatonin; Group III received L-thyroxine; and Group IV received both L-thyroxine and melatonin. The serum levels of total T3 (tT3) and total T4 (tT4) were assessed, as well as histological examinations of the thyroid and thymus and analysis of Bax immunoeexpression in both organs. The obtained results showed that in rats with hyperthyroidism, melatonin administration caused a noticeably lower level of thyroid hormones. According to the histopathological examination, hyperthyroidism induced various deteriorating changes in the thyroid and thymus glands, while melatonin therapy reduced these adverse effects. The immunohistochemical analysis demonstrated that hyperthyroid rats displayed a substantial elevation in Bax expression in the thyroid and thymus glands. However, melatonin treatment in hyperthyroid rats resulted in a marked reduction in Bax expression. Thus, it could be concluded that hyperthyroidism induced a range of degenerative changes and markedly elevated Bax expression in thyroid and thymus tissues. However, melatonin intervention ameliorated these negative effects.

1. INTRODUCTION

The correlation between the endocrine and immune systems has garnered increased interest in recent years. The bidirectional interplay between the endocrine and immune systems promotes appropriate host responses during homeostasis and infection. This communication is viable given that cytokine receptors are expressed by the endocrine organs and hormone receptors are expressed by immune cells (Webber et al., 2022). The thymus is a central lymphoid organ, where lymphoid progenitor cells, derived from bone marrow, are stimulated to differentiate into proficient T cells that express an array of T cell receptor (TCR) repertoire selectively chosen to enable the recognition of alien antigens while evading self-reactivity and autoimmunity (Han and Zúñiga-Pflücker, 2021). Numerous hormones of the hypothalamic-pituitary axis regulate the development, involution, and endocrine function of the thymus and the creation of the T lymphocyte repertoire. Also, hormones of peripheral endocrine organs, such as thyroid hormones, regulate the thymus activities (Dąbrowski et al., 2011). Thyroid hormones (TH) play a critical role in regulating essential cellular processes including differentiation,

proliferation, apoptosis, and metabolism (Krashin et al., 2019). Hence, any disturbance in the balance of these hormones can be harmful to tissues. Hyperthyroidism is a condition characterized by excessive levels of thyroid hormone circulating throughout the body. Hyperthyroidism promotes a hypermetabolic state primarily associated with activated mitochondrial respiration, which is known to foster reactive oxygen species (ROS) generation, leading to oxidative stress (Di Meo and Venditti, 2020). Elevated levels of ROS within cells cause damage to nucleic acids, proteins, lipids, membranes, and organelles, thereby potentially triggering the initiation of cellular death processes such as apoptosis (Redza-Dutordoir and Averill-Bates, 2016). Hyperthyroidism has been shown to induce oxidative damage and apoptosis in many tissues, such as the brain (Rao et al., 2016), heart (Mishra et al., 2019), and liver (Yang et al., 2020).

Melatonin, a neurohormone, is primarily synthesized by the pineal gland. Melatonin serves as an integral player in a wide variety of critical physiological processes that include circadian and seasonal rhythms, neuroendocrine, reproductive, cardiovascular, immunoregulation, and

* Correspondence to: sara.habk@fvtm.bu.edu.eg

oncostatic activities (López-Muñoz et al., 2016). In recent decades, extensive research has provided evidence of the significant antioxidant and antiapoptotic capacity of melatonin. In addition to its adeptness at scavenging numerous free radicals, melatonin also augments the activity of several antioxidant enzymes (Ferlazzo et al., 2020). Several studies have demonstrated that the anti-apoptotic effect of melatonin encompasses the down-regulation of Bax, a promoter of apoptosis, or the up-regulation of Bcl-2, an antiapoptotic protein (Singh and Haldar, 2016; Keskin-Aktan et al., 2022). Additionally, melatonin decreases the production of reactive oxygen species (ROS), thereby improving the damage and apoptosis caused by free radicals (Hacışevki and Baba, 2018). The objective of the current investigation was to assess the impact of L-thyroxine-induced hyperthyroidism on the histopathology of the thyroid and thymus glands, as well as the expression of Bax, and to determine the consequences of melatonin administration.

2. MATERIAL AND METHODS

2.1. Experimental animals

Forty male Sprague Dawley albino rats averaging 6 weeks old and weighing 100-120 g were purchased from Vacsera, Egypt. The rats were kept in a controlled setting with a consistent temperature of 25 ± 2 °C, a relative humidity range of 50 to 55%, and a 12-hour cycle of alternating light and darkness. They were granted unrestricted access to food and water. The animals were provided with one week for acclimatization prior to the experiment. The Institutional Animal Care and Use Committee of Benha University has granted approval for all animal treatments, with approval number BUFVTM16-03-23.

2.2. Chemicals

L-thyroxine (T4, Sigma T2376) was purchased from Sigma-Aldrich, Germany. Reconstitution of T4 was accomplished by dissolving 50 mg in 1 mL of a 4M ammonia solution in methanol (779423, Sigma-Aldrich, Switzerland) according to the manufacturer's recommendations. T4 stock solution was stored at -80 °C. T4 stock aliquots were diluted to provide final concentrations at exposure time. Melatonin was obtained from Nerhadou International company (Egypt). Daily preparations of melatonin were made, dissolved in 100% ethanol (50 mg/ml) and diluted in saline solution. The final ethanol concentration was less than 1% (Sirichoat et al., 2019).

2.3. Experimental design

The rats were divided into four groups, 10 rats in each, and received the following treatments:

Group I (Control): Rats were treated with intraperitoneal (IP) injections of saline daily for 28 days.

Group II (Melatonin): Rats were treated with IP injections of melatonin (10 mg/kg) daily for 28 days, according to Luo et al. (2020).

Group III (Hyperthyroid): Hyperthyroidism was induced in rats by daily IP injections with L-thyroxine (250 µg/kg) daily for 28 days, according to Ayala et al. (2019).

Group IV (Hyperthyroid + Melatonin): Rats were treated as group III and received IP injection of melatonin (10 mg/kg) daily for 28 days.

2.4. Blood and tissue samples

At the experiment's end, rats were anesthetized with isoflurane. Blood specimens were collected from the retro-orbital venous plexus without an anticoagulant and maintained at room temperature to facilitate serum separation. The serum was preserved at a temperature of -20 °C until its utilization in biochemical analysis. Following blood collection, the animals were euthanized through cervical dislocation. The thyroid and thymus were dissected and immersed in 10% neutral buffered formalin for histopathological and immunohistochemical processing.

2.5. Measurement of thyroid hormones

The evaluation of serum total T3 and T4 levels was conducted by means of electro-chemiluminescent immunoassay (ECLIA) tests utilizing a Cobas® analyzer (Elecsys, E170, Roche Diagnostics, Germany), as previously outlined by Yu et al. (2018).

2.6. Histological examination

The technique for histological preparation was carried out in accordance with Suvarna et al., (2019). In brief, the thyroid and thymus tissues were sliced to a thickness of 3-4 mm and fixed in 10% neutral buffered formalin. Following this, they were subjected to dehydration using graded concentrations of ethanol, clearing in xylene, and ultimately embedded in paraffin. The paraffin blocks underwent sectioning via a microtome, with a thickness ranging from 4 to 6µm, and were subsequently stained with Hematoxylin and Eosin. H&E-stained sections were examined with the aid of a Leica microscope (CH9435 Heerbrugg) from Leica Microsystems, Switzerland.

2.7. Immunohistochemistry analysis of Bax expression

Immunohistochemistry was applied to paraffin tissue sections and fixed to positively charged slides utilizing the avidin-biotin-peroxidase complex (ABC) method. Sections were incubated with Mouse Anti-Bax Monoclonal Antibody, Clone 1C1 (Elabscience cat no. E-AB-22212, Dil:1:100). Subsequently, the chemicals involved in the ABC (Vectastain ABC-HRP kit, Vector laboratories) were introduced. Marker expression was detected via peroxidase and stained with diaminobenzidine (DAB, Sigma-Aldrich) to discriminate antigen-antibody complexes. Negative controls were incorporated by utilizing non-immune serum instead of primary or secondary antibodies. Sections of immuno-stained tissue were examined and captured using a Leica microscope (Leica Microsystems Ltd., CH9435 Heerbrugg, Switzerland). The area percentage of Bax-stained sections was determined using Leica QWin 500 image analyzer computer system (Leica Ltd., England)

which consists of Leica microscope coupled to a video camera and Leica QWin 500 software. The area percent of Bax immunoreactivity is expressed as mean \pm S.E.M.

2.8. Statistical Analysis

The statistical analyses were performed via SPSS Statistics (Version 26, IBM, USA). The significance of intergroup variations was conducted through one-way ANOVA followed by a post hoc Duncan test. The results are presented as means \pm S.E.M., and statistical significance is indicated by a $P < 0.05$.

3. RESULTS

3.1. Serum thyroid hormone levels

The findings indicated that the hyperthyroid rats exhibited a significant ($p < 0.05$) increase in tT3 and tT4 levels compared to the controls. The hyperthyroid rats treated with melatonin displayed a marked reduction in tT3 and tT4 levels compared with the hyperthyroid rats. However, it was noted that there was no statistically significant variance between the melatonin-treated and control rats (Fig. 1.).

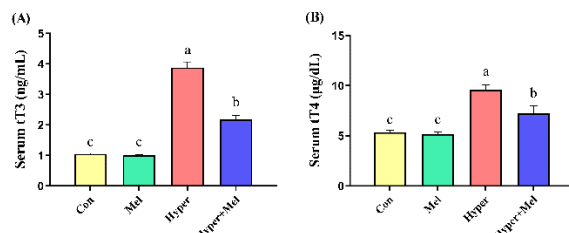


Fig. 1. Influence of hyperthyroidism and melatonin on serum levels of tT3 (A) and tT4 (B). Values are expressed as mean \pm S.E.M. Values within the same column carrying different letters are significantly different at ($p < 0.05$).

3.2. Histopathological observations of the thyroid gland

Thyroid gland histopathology from control or melatonin-treated rats (Fig. 2A and 2B, respectively) revealed normal thyroid follicles featuring simple cuboidal follicular epithelial cells with eosinophilic cytoplasm and hyperchromatic round nuclei. These cells surround a central lumen repleted with pink colloids. Parafollicular C cells were seen as polygonal clusters closest to thyroid follicles. In hyperthyroid rats (Fig. 2C), the thyroid follicles had large and small pleomorphic features and were presented with a degraded architecture accompanied by a desquamated epithelium. Obvious scanty colloid quantities are detected in most follicles. The follicular and parafollicular cells were marked with polygonal apoptotic shapes in high numbers. Moreover, congested blood vessels plus interstitial edema leading to dispersion between thyroid follicles were seen. In hyperthyroid rats administered melatonin (Fig. 2D), there was a noticeable improvement in tissue architecture marked by regular thyroid follicles with intact follicular cells. Colloids appeared mostly in a homogenous shape and a few vacuolated ones. Blood vessels remain congested.

3.3. Histopathological observations of the thymus gland

Control and melatonin-treated rats (Fig. 3A and 3B, respectively) exhibited a standard cortex histological structure with an intense accumulation of deep basophilic T lymphocytes. The thymic medulla has a standard appearance through a high number of epithelial reticular cells. Hyperthyroid rats (Fig. 3C) exhibited serious degenerative

changes evidenced by subcapsular hemorrhage, decreased cellularity in the cortex area, and apoptotic lymphocytes with acidophilic cytoplasm, as well as dispersed necrotic changes in the medullary region. Moreover, epithelial reticular cells existed with hypertrophy. Hyperthyroid rats administered melatonin (Fig. 3D) showed an obvious increase in cortex cellularity, except in a few areas still with few cells and a high acidophilic appearance. An increase in epithelial reticular cells is also evident. Additionally, subcapsular hemorrhage was still perceived.

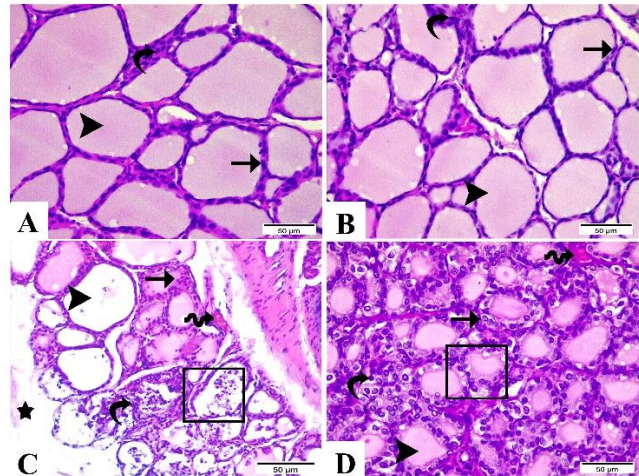


Fig. 2. Histological sections of the thyroid gland (Hematoxylin & Eosin 400x, Scale Bar 50 μ m). A: Control group and B: Melatonin group show normal follicles lined with simple cuboidal follicular cells (arrow) with pink colloid (arrowhead). Parafollicular C cells are represented as clusters of a polygonal shape (curvy arrow). C: Hyperthyroid group, shows deteriorated follicle structure with cuboidal epithelium (cube) and scanty colloid. Further, congested blood vessels (wave arrow) and interstitial edema (star) were observed. D: Hyperthyroid + Melatonin group, shows most thyroid follicles with a regular structure (cube) and intact follicular cells (arrow).

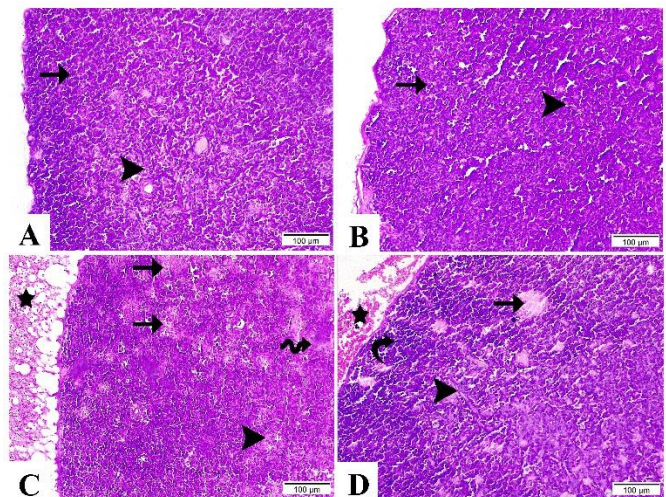


Fig. 3. Histological sections of the thymus gland (Hematoxylin & Eosin 200x, Scale Bar 100 μ m). A: Control group and B: Melatonin group demonstrate standard cortex structure with deep basophilic T lymphocytes (arrow). The medulla comprises a high number of epithelial reticular cells (arrowhead). C: Hyperthyroid group shows degenerative changes evidenced by subcapsular hemorrhage (star), apoptotic lymphocytes with acidophilic cytoplasm (arrows), and dispersed necrotic changes in the medullary region (wave arrow). D: Hyperthyroid + Melatonin group highlights an obvious increase in cortex cellularity (curvy arrow) and growth in epithelial reticular cells (arrowhead).

3.4. Bax expression in the thyroid gland

Thyroid glands from control and melatonin-administered rats (Fig. 4A and 4B, respectively) showed few positive cytoplasmic and nuclear Bax expressions along the follicular

epithelial cells. The hyperthyroid rats (Fig. 4C) displayed high positive cytoplasmic and nuclear Bax reactivity that was significantly different ($P < 0.05$) from that of the control melatonin-administered rats. A remarkable decrease in cytoplasmic and nuclear Bax expression was exhibited in the hyperthyroid rats treated with melatonin (Fig. 4D) compared with hyperthyroid rats.

3.5. Bax expression in the thymus gland

The thymus glands from the control and melatonin-administered rats (Fig. 5A and 5B, respectively) expressed few positive nuclear Bax reactivity, with no significant difference ($P < 0.05$) between them. Rats with hyperthyroidism (Fig. 5C) denoted high positive nuclear Bax reactivity with significant differences compared with control and melatonin-administered rats. A substantial decrease in nuclear Bax expression was observed in hyperthyroid rats treated with melatonin (Fig. 5D) compared with hyperthyroid rats.

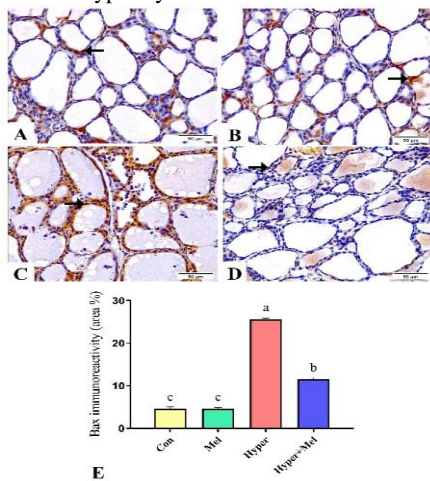


Fig. 4. Bax expression in the thyroid gland (400x & Scale Bar 50µm). A: Control group and B: Melatonin group exhibit few positive cytoplasmic and nuclear Bax expressions along the follicular epithelial cells (arrow). C: Hyperthyroid group shows high levels of cytoplasmic and nuclear Bax reactivity. D: Hyperthyroid + Melatonin group displays moderate positive cytoplasmic and nuclear Bax reactivity. E: Immunohistochemical scoring of the Bax positive area. Values are expressed as mean ± S.E.M. Values with different letters are significantly different at ($p < 0.05$).

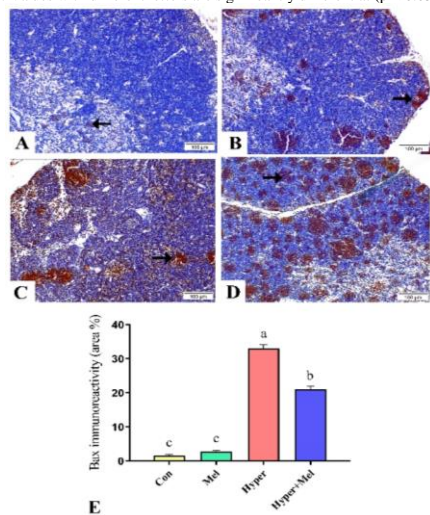


Fig. 5. Bax expression in the thymus gland (200x & Scale Bar 100µm). A: Control group, and B: Melatonin group show little positive Bax reactivity (arrow). C: Hyperthyroid group denotes high positive nuclear Bax reactivity. D: Hyperthyroid + Melatonin group highlights moderate positive nuclear Bax reactivity. E: Immunohistochemical scoring of the Bax positive area. Values are expressed as mean ± S.E.M. Values with different letters are significantly different at ($p < 0.05$).

4. DISCUSSION

Research evidence suggests that interactions exist between the endocrine system and thymus gland activity. The impact of the endocrine axis on thymus physiology appears to be mediated by the direct action of pituitary hormones or via peripheral hormones, both of which elicit their effects on the thymus epithelial cells and immature thymocytes (Reggiani et al., 2014). Hence, the present research evaluated the impact of hyperthyroidism and melatonin on the histopathology of the thyroid and thymus glands, as well as Bax expression within them. In the current study, induction of hyperthyroidism in rats was effectively achieved, as indicated by the marked elevation in serum levels of tT3 and tT4 in hyperthyroid rats compared to controls. These observations are consistent with previous findings (Panda et al., 2019; Ghosh et al., 2022). The coadministration of melatonin to hyperthyroid rats resulted in an interesting decrease in thyroid hormone levels, suggesting a potential suppression of thyroid hormone synthesis and/or release at the glandular level. These findings are consistent with earlier research, which showed that melatonin exerts an inhibitory effect on thyroid hormones (Verma et al., 2019; Ghosh et al., 2022). The potential mechanism through which melatonin inhibits thyroid hormone levels in hyperthyroid conditions may implicate the regulation of the pituitary-thyroid axis. Melatonin could hinder the secretion of thyroid-stimulating hormone (TSH) from the pituitary gland and reduce the protein expression of TSH receptors within the thyroid gland (Laskar and Singh, 2020).

In the present investigation, the histopathological alterations observed in the thyroid gland corroborated the biochemical findings. The histopathological changes induced by hyperthyroidism in the thyroid glands revealed various degenerative alterations marked by deteriorated thyroid follicles with desquamated epithelium and scanty colloid quantities. These results are consistent with the findings reported by Panda et al. (2019). Melatonin coadministration to hyperthyroid rats significantly improved the architecture of the thyroid tissue, as shown by the presence of the majority of thyroid follicles with a regular structure and homogenous colloids. The present observations concerning melatonin are somewhat similar to those from earlier studies, which suggested that melatonin has a protective effect against thyroid gland injury (Arıcigil et al., 2017). The histopathological analysis conducted on the thymus gland revealed that hyperthyroidism caused significant degenerative modifications, notably apoptotic lymphocytes and dispersed necrotic changes in the medullary area. However, melatonin coadministration elicited an increase in cortical cellularity and epithelial reticular cell number. These findings were validated through immunohistochemical analysis of Bax expression, which indicated that hyperthyroidism elevated Bax expression and, consequently, apoptosis, whereas melatonin treatment in hyperthyroid rats mitigated this effect.

Apoptosis is the programmed death of cells activated by intrinsic or extrinsic pathways. The intrinsic pathway is stimulated by intracellular signals produced by cellular stress and by proteins released from the intermembrane space of mitochondria. The extrinsic pathway is evoked through the coupling of extracellular ligands to death

receptors at the surface of target cells. Proteins from the Bcl-2 family, like Bax, play a pivotal role in regulating apoptosis pathways mediated by mitochondria (Pourahmad and Rezaei, 2021). Upon cellular stimulation towards apoptosis, the Bax protein triggers a cascade reaction leading to cytochrome C release from the mitochondria, which promotes subsequent activation of caspase proteins, culminating in programmed cell death (Bertheloot et al., 2021). In this study, based on the obtained results of Bax immunohistochemistry, it was observed that both control and melatonin-administered rats exhibited a few positive Bax immunoreactions within the thyroid and thymus glands. Hyperthyroidism engendered a substantial elevation in Bax expression. These results are supported by previous studies that revealed that hyperthyroidism induced Bax expression and cell apoptosis in many tissues like the brain (Rao et al., 2016), liver (Yang et al., 2020), and heart (Wu et al., 2017). Thyroid hormones have a substantial effect on ROS production and oxidative stress processes at the cellular level, attributed to their crucial role in cellular metabolism and oxygen consumption. Hyperthyroidism elicits an upsurge in the generation of ROS, thereby initiating alterations in the antioxidant defense mechanisms of diverse tissues, culminating in a state of oxidative stress (Macvanin et al., 2023). Hyperthyroidism-induced oxidative stress has the potential to trigger apoptosis through mitochondrial DNA damage, inhibition of the mitochondrial respiratory chain transition, and elevation of mitochondrial membrane permeability. The augmented hyperpolarization of the mitochondrial membrane after exposure to ROS generated by hyperthyroidism was the instigator of the decline in the potential of the mitochondrial membrane, translocation of Bax to the mitochondria, and release of cytochrome C (Cui et al., 2012). Our findings also indicated that melatonin effectively ameliorated the heightened expression of Bax, brought on by hyperthyroidism, in both thyroid and thymus tissues. These results are consistent with Rao et al. (2016) findings, which indicated that melatonin treatment decreased the expression of Bax in the hippocampal region of the brain during a hyperthyroid state. There is a growing body of evidence indicating that the protective effects of melatonin against apoptosis are mainly mediated by the intrinsic pathway. Melatonin treatment resulted in a decrease in apoptotic rate, maintenance of mitochondrial membrane potential, reduction of cytochrome C release from mitochondria, downregulation of Bax and caspase-3 levels, and upregulation of Bcl-2 (Liu et al., 2012).

5. CONCLUSIONS

In conclusion, hyperthyroidism caused a variety of degenerative modifications and a significant increase in the expression of the Bax protein in the tissues of the thyroid and thymus. Melatonin treatment, however, significantly improved these deleterious effects.

Acknowledgement

The authors express their gratitude to Nerhadou International Company for graciously providing a sample of melatonin as a gift.

6. REFERENCES

1. Arıcıgil, M., Dündar, M.A., Yücel, A., Eryılmaz, M.A., Aktan, M., Alan, M.A., Fındık, S. and Kılınc, İ., 2017. Melatonin prevents possible radiotherapy-induced thyroid injury. *International Journal of Radiation Biology*, 93(12), 1350-1356.
2. Ayala, C., Pennacchio, G.E., Soaje, M., Bittencourt, J.C., Celis, M.E., Jahn, G.A., Valdez, S.R. and Seltzer, A.M., 2019. Differential effects of hypo- and hyperthyroidism on remodeling of contacts between neurons expressing the neuropeptide EI and tyrosine hydroxylase in hypothalamic areas of the male rat. *Peptides*, 113, 1-10.
3. Bertheloot, D., Latz, E. and Franklin, B.S., 2021. Necroptosis, pyroptosis and apoptosis: an intricate game of cell death. *Cellular & molecular immunology*, 18(5), 1106-1121.
4. Cui, H., Kong, Y. and Zhang, H., 2012. Oxidative stress, mitochondrial dysfunction, and aging. *Journal of signal transduction*, 2012, 1-13.
5. Dąbrowski, M.P., Dąbrowski, M.I. and Stankiewicz, W., 2011. Review paper The thymus in neuro-endocrine-immune network. *Central European journal of immunology*, 36(3), 188-192.
6. Di Meo, S. and Venditti, P., 2020. Evolution of the knowledge of free radicals and other oxidants. *Oxidative Medicine and Cellular Longevity*, 2020, 1-32.
7. Ferlazzo, N., Andolina, G., Cannata, A., Costanzo, M.G., Rizzo, V., Currò, M., Ientile, R. and Caccamo, D., 2020. Is melatonin the cornucopia of the 21st century?. *Antioxidants*, 9(11), 1-29.
8. Ghosh, H., Rai, S., Manzar, M.D., Pandi-Perumal, S.R., Brown, G.M., Reiter, R.J. and Cardinali, D.P., 2022. Differential expression and interaction of melatonin and thyroid hormone receptors with estrogen receptor α improve ovarian functions in letrozole-induced rat polycystic ovary syndrome. *Life Sciences*, 295, 1-9.
9. Hacışevki, A. and Baba, B., 2018. An overview of melatonin as an antioxidant molecule: a biochemical approach. *Melatonin molecular biology, clinical and pharmaceutical approaches*, 5, 59-85.
10. Han, J. and Zúñiga-Pflücker, J.C., 2021. A 2020 view of thymus stromal cells in T cell development. *The Journal of Immunology*, 206(2), 249-256.
11. Keskin-Aktan, A., Akbulut, K.G., Abdi, S. and Akbulut, H., 2022. SIRT2 and FOXO3a expressions in the cerebral cortex and hippocampus of young and aged male rats: antioxidant and anti-apoptotic effects of melatonin. *Biologia Futura*, 73, 71-85.
12. Krashin, E., Piekietko-Witkowska, A., Ellis, M. and Ashur-Fabian, O., 2019. Thyroid hormones and cancer: a comprehensive review of preclinical and clinical studies. *Frontiers in endocrinology*, 10, 1-23.
13. Laskar, P. and Singh, S.S., 2020. Receptor Mediated Effect of Melatonin in Pituitary Regulated Thyroid Secretions of Hyperthyroid Mice. *Journal of Health Science Research*, 5(2), 77-83.
14. Liu, Y., Zhang, L., Zhang, H., Liu, B., Wu, Z., Zhao, W. and Wang, Z., 2012. Exogenous melatonin modulates apoptosis in the mouse brain induced by high-LET carbon ion irradiation. *Journal of Pineal Research*, 52(1), 47-56.
15. López-Muñoz, F., Srinivasan, V., De Berardis, D., Álamo, C. and Kato, T.A. eds., 2016. *Melatonin, neuroprotective agents and antidepressant therapy*. Springer, 65-75.
16. Luo, J., Zhang, Z., Sun, H., Song, J., Chen, X., Huang, J., Lin, X. and Zhou, R., 2020. Effect of melatonin on T/B cell activation and immune regulation in pinealectomy mice. *Life sciences*, 242, 1-11.
17. Macvanin, M.T., Gluovic, Z., Zafirovic, S., Gao, X., Essack, M. and Isenovic, E.R., 2023. The protective role of nutritional

- antioxidants against oxidative stress in thyroid disorders. *Frontiers in Endocrinology*, 13, 1-19.
18. Mishra, P., Paital, B., Jena, S., Swain, S.S., Kumar, S., Yadav, M.K., Chainy, G.B. and Samanta, L., 2019. Possible activation of NRF2 by Vitamin E/Curcumin against altered thyroid hormone induced oxidative stress via NFκB/AKT/mTOR/KEAP1 signalling in rat heart. *Scientific reports*, 9(1), 1-16.
 19. Panda, S., Sharma, R. and Kar, A., 2019. Chavibetol corrects thyrotoxicosis through alterations in thyroid peroxidase. *Naunyn-Schmiedeberg's Archives of Pharmacology*, 392, 541-550.
 20. Pourahmad, J. and Rezaei, M. eds., 2021. Mitochondrial metabolism: an approach to disease management. Academic Press, 49-60.
 21. Rao, G., Verma, R., Mukherjee, A., Haldar, C. and Agrawal, N.K., 2016. Melatonin alleviates hyperthyroidism induced oxidative stress and neuronal cell death in hippocampus of aged female golden hamster, *Mesocricetus auratus*. *Experimental Gerontology*, 82, 125-130.
 22. Redza-Dutordoir, M. and Averill-Bates, D.A., 2016. Activation of apoptosis signalling pathways by reactive oxygen species. *Biochimica et Biophysica Acta (BBA)-Molecular Cell Research*, 1863(12), 2977-2992.
 23. Reggiani, P. C., Schwerdt, J. I., Console, G. M., Roggero, E. A., Dardenne, M. and Goya, R. G., 2014. Physiology and therapeutic potential of the thymic peptide thymulin. *Current Pharmaceutical Design*, 20 (29), 4690-4696.
 24. Singh, A.K. and Haldar, C., 2016. Melatonin modulates glucocorticoid receptor mediated inhibition of antioxidant response and apoptosis in peripheral blood mononuclear cells. *Molecular and Cellular Endocrinology*, 436, 59-67.
 25. Sirichoat, A., Krutsri, S., Suwannakot, K., Aranarochana, A., Chaisawang, P., Pannangrong, W., Wigmore, P. and Welbat, J.U., 2019. Melatonin protects against methotrexate-induced memory deficit and hippocampal neurogenesis impairment in a rat model. *Biochemical Pharmacology*, 163, 225-233.
 26. Suvarna, K.S., Layton, C. and Bancroft, J.D., 2019. Bancroft's theory and practice of histological techniques eighth edition. Elsevier health sciences, 120:131.
 27. Verma, V.K., Haldar, C. and Pal, S., 2019. Oxidative Damage and Apoptosis Induction by L-thyroxine in the Spleen of a Tropical Bird *Perdicula asiatica*: Rescue by Melatonin. *Journal of Endocrinology and Reproduction*, 23(1), 37-43.
 28. Webber, T., Ronacher, K., Conradie-Smit, M. and Kleynhans, L., 2022. Interplay between the immune and endocrine systems in the lung: implications for TB susceptibility. *Frontiers in immunology*, 13, 1-16.
 29. Wu, J.B., Zhou, Y., Liang, C.L., Zhang, X.J., Lai, J.M., Ye, S.F., Ouyang, H., Lin, J. and Zhou, J.Y., 2017. Cycloviobuxinum D alleviates cardiac hypertrophy in hyperthyroid rats by preventing apoptosis of cardiac cells and inhibiting the p38 mitogen-activated protein kinase signaling pathway. *Chinese journal of integrative medicine*, 23, 770-778.
 30. Yang, Q., Liu, W., Sun, D., Wang, C., Li, Y., Bi, X., Gu, P., Feng, H., Wu, F., Hou, L. and Hou, C., 2020. Yinning Tablet, a hospitalized preparation of Chinese herbal formula for hyperthyroidism, ameliorates thyroid hormone-induced liver injury in rats: Regulation of mitochondria-mediated apoptotic signals. *Journal of Ethnopharmacology*, 252, 1-11.
 31. Yu, Z., Han, Y., Shen, R., Huang, K., Xu, Y.Y., Wang, Q.N., Zhou, S.S., Xu, D.X. and Tao, F.B., 2018. Gestational di-(2-ethylhexyl) phthalate exposure causes fetal intrauterine growth restriction through disturbing placental thyroid hormone receptor signaling. *Toxicology Letters*, 294, 1-10.