

## Significance of Dicer1 in Adrenocortical Adenoma and Carcinoma (Immunohistochemical Study)

Heba M. Rashad, Aya A. Abdel Monem, Mohebat H. Goda, Taghreed A. Abdel Aziz

### Abstract:

**Background:** Adrenocortical tumors (ACTs) are detected in 5–7% of the general population. Dysregulation of micro-ribonucleic acid (microRNA) biogenesis machinery- is involved in a variety of human cancers. Dicer1 is an essential component of microRNA machinery. **Aim:** To evaluate the diagnostic and prognostic significance of Dicer1 in adrenocortical adenoma (ACA) and carcinoma (ACC), then correlate the results with clinico-pathological data. **Material and Methods:** Forty adrenocortical lesions were included in this retrospective study, included (20) ACA and (20) ACC. Clinicopathological characteristics of examined cases were correlated with the IHC expression of Dicer1. **Results:** Dicer1 IHC expression was more frequent in ACC (65%) than in ACA (25%), ( $P = 0.04$ ). But among ACC, a weak Dicer1 expression was significantly more frequent in advanced ACCs. There was a significant statistical inverse relation between Dicer1 expression in studied ACC cases according to tumor size, weight, Weiss score, lymph node metastasis, lympho-vascular invasion and ENSAT stage ( $P < 0.05$ ). Other clinico-pathological variables such as age, sex, tumor site, tumor grade, and distant metastasis showed no significant statistical difference ( $P > 0.05$ ). Dicer1 showed 76% sensitivity and 67% specificity for differentiating ACA from ACC. **Conclusion:** Reduced Dicer1 expression with tumor progression in ACC may play a role in the tumorigenesis and further decline in Dicer1 expression may be associated with poor prognosis in ACC.

**Keywords:** Adrenocortical adenoma, Adrenocortical carcinoma, Dicer1.

Pathology Department, Faculty of Medicine Benha University, Egypt.

Corresponding to:

Dr. Aya A. Abdel Monem.

Pathology Department, Faculty of Medicine Benha University, Egypt.

Email:

aya.abdelaziz.naser@gmail.com

Received:

Accepted:

---

## Introduction

According to 2017 WHO classification of tumors of the adrenal cortex; it is classified as adrenocortical adenoma, adrenocortical carcinoma, sex cord stromal tumors, adenomatoid tumor, mesenchymal and stromal tumors (myelolipoma and schwannoma), hematological tumors, and secondary tumors <sup>(1)</sup>.

Adrenal cortical adenoma accounts for a large proportion of incidentally discovered adrenal tumors (so-called adrenal incidentalomas) <sup>(2,3)</sup>. The true incidence of ACA is unknown; however, the incidence seems to have sharply increased recently, possibly because of increasing use of CT abdominal imaging <sup>(4)</sup>. In Egypt, benign tumors were constituting 9.01% of all suprarenal lesions and ACA constitutes 40.48% <sup>(5)</sup>.

Adrenal cortical carcinoma is the most common primary cancer in the adrenal gland <sup>(6)</sup>. It is the second most common malignant tumor of the endocrine organ after anaplastic thyroid carcinoma <sup>(7)</sup>. The annual Incidence of ACC is stable, at 0.5-2 cases per 1 million population <sup>(4,8)</sup>. In Egypt, primary malignant suprarenal tumors represented 0.67% of all malignancy at NCI and ACC represented 11.15 % <sup>(5)</sup>.

Adrenal cortical adenomas are benign tumors without the biological potential to invade and metastasize <sup>(4)</sup>. Adrenocortical carcinoma has a poor prognosis with a high recurrence rate. Tumor stage at diagnosis and the completeness of surgical excision are the most relevant prognostic factors <sup>(9)</sup>.

Dicer1 enzyme and its cofactor, transactivation response (TAR) RNA-binding protein (TRBP) are key components of the miRNA processing machinery <sup>(10)</sup>. Dicer1, an RNase III endoribonuclease, cleaves double-stranded RNA and pre-miRNA into short double stranded RNA fragments called small interfering RNA and miRNA respectively. It was demonstrated that escaping miRNA

control in cancer cells due to Dicer downregulation may allow the phenotypic emergence of more aggressive genetic variants <sup>(11)</sup>.

Dysregulation of miRNA production is related to a prooncogenic effect, as observed in several tumor types. The overexpression of one miRNA may inhibit the protein translation of a cancer suppressor gene, while the downregulation of another miRNA may increase the protein level of an oncogene <sup>(12)</sup>.

The aim of this work is to evaluate the diagnostic, and prognostic significance of Dicer1 in ACA and ACC then correlate the results with clinico-pathological data.

---

## Material and Methods:

This is a retrospective study performed upon selected formalin-fixed, paraffin-embedded biopsy specimens from 40 different cases of adrenocortical lesions designated as: 20 cases of ACA and 20 cases of ACC. All cases were of adrenalectomy specimens. Six cases of apparently normal adjacent adrenal tissue were taken as a control. The cases were collected from Pathology Department, Early Cancer Detection Unit, Faculty of Medicine, Benha University and Mansoura University, Egypt, during the period from January 2011 to December 2020.

Inclusion criteria: Cases with available clinicopathological data regarding age, sex, laterality, tumor size, grade, lymph node status, distant metastasis, and stage.

Exclusion criteria: Cases with no available paraffin blocks or clinicopathological data were excluded from the current study.

The Ethics Committee of Faculty of Medicine, Benha University, Egypt approved this study code {M.S.28.9.2020}.

## Histopathological Analysis:

Formalin fixed /Paraffin embedded blocks were cut at 5  $\mu$ m thickness and stained using hematoxylin and eosin stain. Two observers reviewed the microscopic

sections from all the cases. The Weiss criteria was used to classify adenomas and carcinomas (Weiss score  $\geq 3$  indicates a diagnosis of ACC) <sup>(13)</sup>. The grading system uses the cut-off of 20 mitoses per 10 mm<sup>2</sup> to distinguish low- and high-grade ACC. Low-grade ACC has a mitotic activity  $\leq 20$  mitoses per 10 mm<sup>2</sup>, whereas high-grade ACC shows  $> 20$  mitoses per 10 mm<sup>2</sup> <sup>(14)</sup>. Lymph node status was evaluated and ENSAT staging system was applied to the ACC cases according to AJCC, 8th edition <sup>(15)</sup>.

#### **Dicer1 Immunohistochemical Study:**

Slides were immune stained according to manufacturer's instructions with Dicer1 rabbit polyclonal antibody (Chongqing biopsies co., Cat No YPA1120, China) at a dilution of 1:50, at room temperature, overnight. Immunodetection was carried out using a standard labeled streptavidin-biotin system (Genemed, CA 94080, USA, South San Francisco). Antigen retrieval was done by using 10 mmol/L citrate monohydrate buffer (pH 6.0) and heating for 15 minutes in the microwave. The chromogen diaminobenzene (DAB, Envision TM Flex /HRP-Dako, REF K 8000) used was freshly prepared. The counter stain was Mayer's hematoxylin. Normal gastric tissue used as a positive control <sup>(16)</sup>. For negative control, primary antibody was omitted (Phosphate- buffered Saline).

#### **Immunohistochemical interpretation:**

Positivity for Dicer1 was detected as cytoplasmic brownish staining without nuclear staining in tumor cells <sup>(17)</sup>. Immunoreactivity was assessed by evaluating the extent and intensity of the stained cells, as regard for the extent of staining, percentage of positive cells was scored as: 0= no positive cells, 1= 1–25% of positive cells, 2= 26–50% positive cells, 3= 51- 75% positive cells, 4= 76 -100% positive cells. Intensity of staining was scored as: 0= no staining, 1= weakly positive, 2= moderately positive (modest granular staining) and 3= strongly positive (diffuse and homogenous staining) <sup>(16, 17)</sup>.

A semiquantitative score was then calculated by sum of the staining intensity with the proportion score with a final score ranging from 0 to 7. The median score was a priori chosen as cut-off point for separating tumors with low and high staining <sup>(16)</sup>. The median score for Dicer1 immunoreactivity was 0 (range, from 0 to 5) for ACA and 2.5 (range, from 0 to 6) for ACC. Cases were divided into low or high Dicer1 expression according to the median score: for ACC cases,  $> 2.5$  is considered high Dicer1 expression and  $< 2.5$  is considered low Dicer1 expression. For ACA, cases with score 0 are considered negative and cases with score  $> 0$  are considered positive.

#### **Statistical analysis:**

The data were gathered, tabulated, and statistically analyzed using the computer program SPSS (Statistical package for social science) version 26 (SPSS Inc., Chicago, IL, USA). P value was statistically significant when  $< 0.05$  and highly significant when  $\leq 0.01$ . Receiver-operating characteristic (ROC) curve was used to estimate sensitivity and specificity of Dicer1 in differentiating ACA from ACC.

---

## **Results:**

### **Clinicopathological results:**

This study was carried out upon 40 cases of ACTs. The age of studied ACA cases ranged from 23 to 67 years with mean age  $48.60 \pm 13.04$  years, and the age of ACC cases ranged from 37 to 85 years with mean age  $57.60 \pm 11.63$  years. The mean size of ACA cases was  $4.70 \pm 1.82$  cm (range 3-11cm), and the mean size of ACC cases was  $13.90 \pm 3.39$  cm (range 6-20 cm). The clinicopathological variables are listed in Table (1&2).

### **Immunohistochemical results:**

Dicer1 was detected as brownish cytoplasmic staining. Apparently normal adrenal tissue showed negative Dicer1 expression. In ACA, 15 cases (75%) showed low Dicer1 expression, and 5 cases (25%) showed high Dicer1

expression. In ACC, 10 cases (50%) showed low Dicer1 expression, and 10 cases (50%) showed high Dicer1 expression. A statistically significant

relation was found between Dicer1 expression and histopathologic types of studied cases (P =0.04), (Figure 1).

**Table (1):** Patients' clinicopathological data in studied ACA and ACC cases.

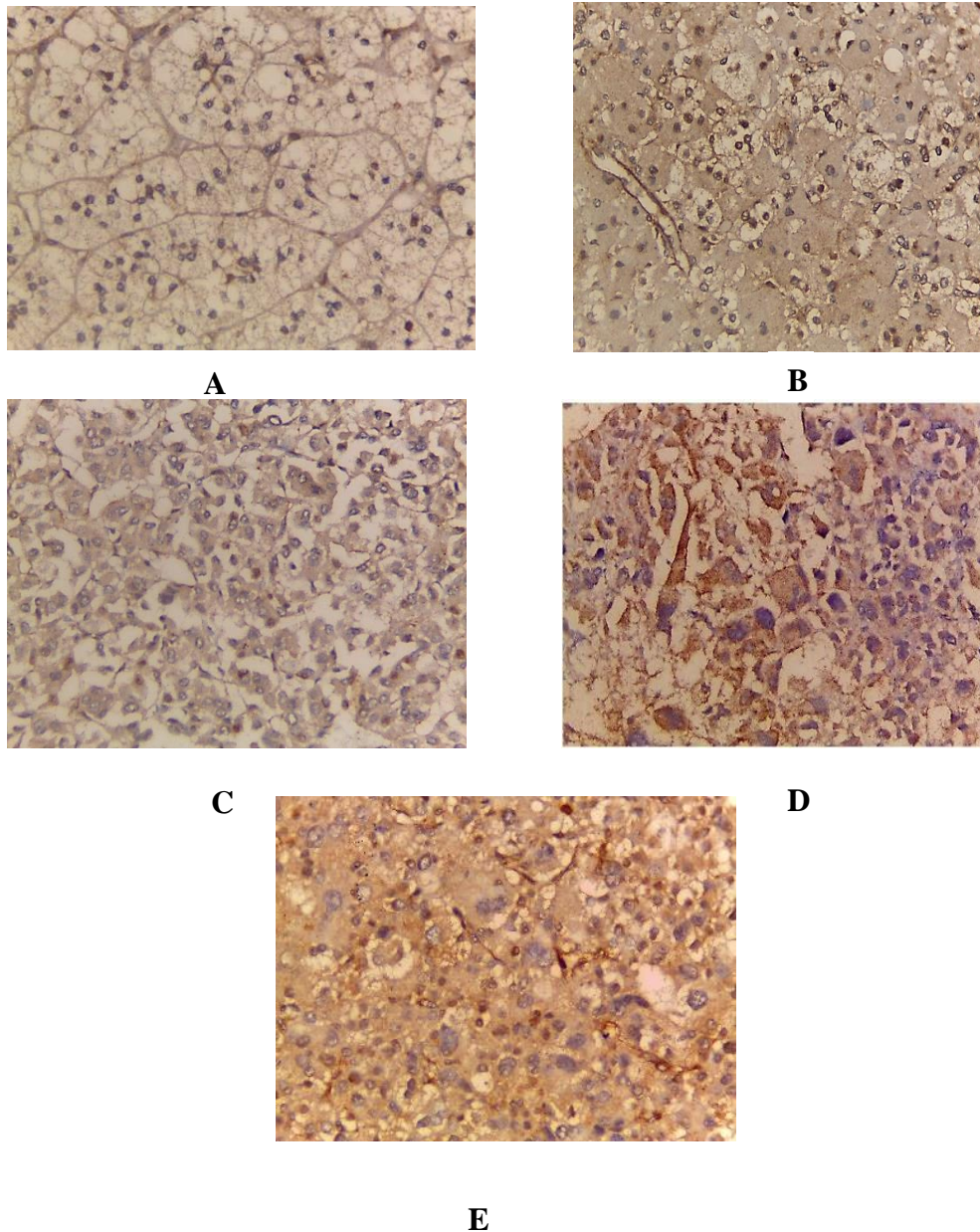
Parameter		ACA	ACC	P
Mean age		48.6	57.6	<b>0.03*</b>
Gender	<b>Male</b>	7 (35%)	13 (65%)	<b>0.1</b>
	<b>Female</b>	12 (60%)	8 (40%)	
Hormonal level	<b>Non-functioning</b>	7 (35%)	13 (65%)	<b>0.2</b>
	<b>Cushing</b>	11 (55%)	6 (30%)	
	<b>Virilizing</b>	2 (10%)	1 (5%)	
Mean tumor size		4.7	13.9	<b>&lt;0.001**</b>
Mean tumor weight		30.55	399.4	<b>&lt;0.001**</b>
Site distribution	<b>Right</b>	12 (60%)	11 (55%)	<b>0.7</b>
	<b>Left</b>	8 (40%)	9 (45%)	

ACA: adrenocortical adenoma; ACC: adrenocortical carcinoma; \* significant; \*\* highly significant

**Table (2):** Clinico-pathological features of studied ACC cases (N=20).

Clinico-pathological feature		Frequency	Percentage
<b>Grade</b>	Low	11	55%
	High	9	45%
<b>Mitotic count</b>	≥5	18	90%
	<5	2	10%
<b>Atypical mitosis</b>	Present	15	75%
	Absent	5	25%
<b>Capsular invasion</b>	Present	8	40%
	Absent	12	60%
<b>Lympho-vascular invasion</b>	Present	8	40%
	Absent	12	60%
<b>Nuclear grade</b>	High	9	45%
	Low	11	55%
<b>Diffuse architecture pattern</b>	Present	14	70%
	Absent	6	30%
<b>Clear cell distribution</b>	<25%	17	85%
	>25%	3	15%
<b>Median Weiss score</b>	<5	5	25%
	≥5	15	75%
<b>Tumor extent (T)</b>	T2	12	60%
	T3	2	10%
	T4	6	30%
<b>Lymph node metastasis (N)</b>	N0	15	75%
	N1	5	25%
<b>Distant metastasis (M)</b>	M0	16	80%
	M1	4	20%
	II	11	55%
<b>Stage</b>	III	5	25%
	IV	4	20%

N: number.



**Figure (1):** **A**-Adrenocortical adenoma showing weak positive cytoplasmic Dicer1 expression, score 2 (IHC, x400). **B**-Adrenocortical adenoma showing positive moderate granular cytoplasmic Dicer1 expression, score 4 (IHC, x400). **C**-Adrenocortical carcinoma showing weak cytoplasmic Dicer1 expression, score 4 (IHC, x400). **D**-Adrenocortical carcinoma showing moderate focal cytoplasmic Dicer1 expression, score 4 (IHC, x400). **E**-Adrenocortical carcinoma showing intense diffuse cytoplasmic Dicer1 expression, score 6 (IHC, x400).

Statistical analysis was performed on the relation between Dicer1 expression in studied cases and clinico-pathological variables. A significant statistical inverse relation was found between Dicer1 expression in studied ACC cases and tumor size, weight, Weiss score, ( $P = 0.03$ ,  $0.04$  and  $0.02$  respectively). Also, a

significant statistical inverse relation to lymph node metastasis, lympho-vascular invasion and ENSAT stage ( $P = 0.03$ ,  $<0.001$  and  $0.04$  respectively)- was found. Other clinico-pathological variables revealed no significant statistical difference between ACA and ACC cases ( $P > 0.05$ ), (Table 3).

The diagnostic accuracy of Dicer1 expression for differentiating between ACA and ACC was determined by using ROC Curve. The curve shows the specificity (true negative fraction) and sensitivity (true positive fraction) of the

test. The area under the curve indicates the test's accuracy (AUC) (Figure 2). Sensitivity and specificity of Dicer1 in differentiating ACA from ACC were 65% and 75% respectively (Table 4).

**Table (3):** Relation between Dicer1 and different clinicopathological variables of studied ACC cases.

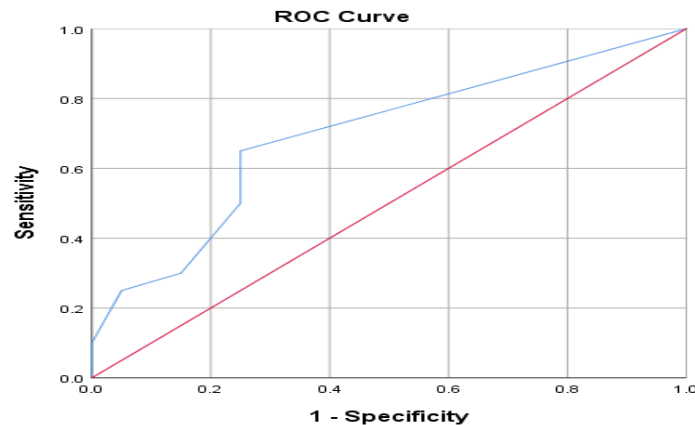
Clinico-pathological feature	Total	Dicer1 expression		P	
		Low N %	High N %		
<b>Mean Size</b>	≥14	13	9 69.3%	4 30.7%	0.03*
	<14	7	1 14.3%	6 85.7%	
<b>Median Weight</b>	≥400	11	8 72.7%	3 27.3%	0.04*
	<400	9	6 22.2%	7 77.8%	
<b>Grade</b>	Low	11	3 27.3%	8 72.7%	0.07
	High	9	7 77.7%	2 22.3%	
<b>Mitotic count</b>	≥5	18	1 55.5%	8 44.5%	0.5
	<5	2	0 0	2 100%	
<b>Atypical mitosis</b>	Present	15	8 53.4%	7 46.6%	0.6
	Absent	5	2 40%	3 60%	
<b>Capsular invasion</b>	Present	8	6 75%	2 25%	0.2
	Absent	12	4 33.4%	8 66.6%	
<b>Lympho-vascular Invasion</b>	Present	8	8 100%	0 0	<0.001**
	Absent	12	2 16.6%	1 83.4%	
<b>Nuclear grade</b>	High	9	6 66.6%	3 33.4%	0.2
	Low	11	4 36.4%	7 63.6%	
<b>Diffuse architecture pattern</b>	Present	14	6 42.8%	8 57.2%	0.3
	Absent	6	4 66.6%	2 33.4%	
<b>Clear cell distribution</b>	<25%	17	9 52.9%	8 47.1%	0.5
	>25%	3	1 33.4%	2 66.6%	
<b>Median Weiss score</b>	<5	5	0 0	5 100%	0.02*
	≥5	15	1 66.6%	0 33.4%	
<b>Tumor extent (T)</b>	T2	12	4 33.4%	8 66.6%	0.1
	T3	2	1 50%	1 50%	
	T4	6	5 83.4%	1 16.6%	
<b>Lymph node metastasis (N)</b>	N0	15	5 33.4%	1 66.6%	0.03*
	N1	5	5 100%	0 0	
<b>Distant metastasis (M)</b>	M0	16	6 37.5%	1 62.5%	0.09
	M1	4	4 100%	0 0	
	II	11	3 27.3%	8 72.7%	
<b>Stage</b>	III	5	3 60%	2 40%	0.04*
	IV	4	4 100%	0 0	

\* Significant; \*\* highly significant

**Table (4):** The sensitivity, specificity, accuracy rate, positive predictive value, and negative predictive value of Dicer1.

Sensitivity	Specificity	PPV	NPV	AUC
65%	75%	72.2%	68.2%	0.7

AUC, Area under the curve; PPV, Positive predictive value; NPN, Negative predictive value.

**Figure (2):** ROC curve for Dicer 1 expression as diagnostic tool for adrenocortical carcinoma, the area under the curve represents an optimal statistic for comparing the sensitivity and specificity of Dicer1 for differentiating between ACA and ACC.

## Discussion:

Adrenal cortical adenoma accounts for a large proportion of incidentally discovered ACTs (called adrenal incidentalomas) (2,3). Adrenal cortical carcinoma is the most common primary cancer in the adrenal gland (6).

The miRNA machinery regulates the expression of multiple tumor suppressor genes and oncogenes (18). The deregulation of miRNA processing enzymes and their cofactors has been demonstrated in several types of cancers, suggesting a pivotal role of miRNA processing disruption in tumor progression (19). The Dicer endoribonuclease protein creates miRNAs (20).

In the current study, Dicer1 expression was higher in ACCs when compared to ACA. 65% of ACC cases showed positive cytoplasmic expression and 25% of ACA cases showed positive expression, with a statistically significant difference ( $P$

$=0.04$ ), while normal adrenal gland showed negative Dicer1 expression.

Our findings were compatible with previous study reported that Dicer1 was significantly over-expressed in ACC when compared with ACA and normal adrenal (21), also, to the study reported that Dicer1 gene overexpression was more frequent in ACCs (60%) than in ACA (23%;  $P = 0.006$ ) (16, 22). These findings suggest that Dicer1 may have a role in progression from adenoma to carcinoma.

MiR-103/miR-107 family have been shown to regulate the expression of Dicer1. MiR-103 expression was not significantly different between ACA and ACCs. Regarding miR-107, its expression was significantly higher in carcinomas than in adenomas. Then that miR-107 overexpression might explain Dicer1 expression in ACC (16).

High Dicer1 expression was found in esophageal carcinomas (23) and prostate



cancer <sup>(24)</sup>. Also, reported in cutaneous melanomas <sup>(17, 25)</sup> and colorectal cancer <sup>(26)</sup>. On the contrary down regulation of Dicer1 was found in advanced lung adenocarcinoma <sup>(27)</sup>, breast cancer <sup>(28)</sup> and hepatocellular carcinoma <sup>(29)</sup>.

Several mechanisms contribute to Dicer1 dysregulation in human cancers, including genomic alterations, epigenetic modifications, and alternative promoter usage <sup>(30)</sup>. Variation of Dicer1 expression level among different tumor types suggests that deregulation of miRNA-processing factors can be dependent on cellular context, to degree of aggressiveness of the given cancer and imply their possible dual role as tumor suppressors or oncogenes in human cancers <sup>(31)</sup>.

There was a statistically significant inverse relation between Dicer1 expression and tumor size ( $P = 0.03$ ), tumor weight ( $P = 0.03$ ) and Weiss score ( $P = 0.02$ ). These results were concomitant with the results of the previous study, in which a weak Dicer1 expression in ACC was significantly associated with larger tumor size and higher Weiss score <sup>(16)</sup>. These results suggest that weak Dicer1 expression may be associated with aggressive behavior and poor prognosis.

In this study, there was a significant statistical inverse relation between IHC expression of Dicer1 and lymph node metastasis ( $P = 0.03$ ) and lympho-vascular invasion ( $P < 0.001$ ). Previous studies agreed with those finding <sup>(16)</sup>, who found that weak Dicer1 expression is a predictor of lymph node invasion and metastasis. In agreement with our results, a weak Dicer1 expression has been associated with poor outcome in several malignancies. In breast cancer, lower mRNA Dicer1 expression was observed in cases with lymph node metastases and metastatic bone derivatives and overexpression of Dicer1 reduced the cell migration and invasion <sup>(28, 32)</sup>. In gastric cancer, a low Dicer1 staining was a predictor of local lymph node invasion <sup>(33)</sup>. In clear cell renal cell carcinoma (ccRCC),

negative Dicer1 expression was associated with increased lymph node and distant metastases <sup>(34)</sup>. In bladder cancer, inhibition of Dicer1 expression enhanced the mesenchymal phenotype and promoted cell invasion <sup>(35)</sup>. Loss of Dicer1 expression enhanced the migratory and invasive abilities and stemness of endometrial carcinoma <sup>(36)</sup>.

This relation could be explained by Dicer1 protein, and some Dicer-dependent microRNAs are keys to inhibit the expression and function of hypoxia inducible factor-1 $\alpha$  (HIF- $\alpha$ ) subunits resulting in up-regulation of HIF- $\alpha$  downstream target genes, especially matrix metalloproteinase (MMPs)- the most common enzymes in remodeling extracellular matrix components for metastasis and vascular endothelial growth factor (VEGFA)- the most important triggered factor in stimulating angiogenesis. Dicer1 significantly suppressed the protein expressions of MMP-2 and VEGFA, which may well explain migration, invasion, and angiogenesis results <sup>(34)</sup>.

This work in addition revealed a significant statistical inverse relation between the ENSAT stage of ACC and IHC expression of Dicer1 ( $P = 0.04$ ), agreeing with de Sousa et al. <sup>(16)</sup> who reported that low expression of Dicer1 in ACC was significantly associated with more advanced tumor stage. In the same line, previous studies in other cancers, <sup>(27, 37)</sup> reported that Dicer1 was up-regulated in atypical adenomatous hyperplasia and bronchoalveolar carcinoma and down-regulated in areas of invasion and in advanced stages adenocarcinoma. These data suggest that a transient up regulation of Dicer1 in the earliest stages of ACC, while down regulation occurs in advanced stages of ACC. In ovarian cancer <sup>(38)</sup>, ccRCC <sup>(39)</sup>, cancer cervix <sup>(40)</sup>, thyroid cancer <sup>(41)</sup> and breast cancer <sup>(32)</sup> - low Dicer1 protein expression was associated with advanced tumor stage.



On the contrary, Dicer1 is up regulated in prostate cancer <sup>(24)</sup>, cutaneous melanomas <sup>(17)</sup> and bladder carcinoma <sup>(42)</sup>. It is significantly related to advanced-stage, grade disease, and lymph node status.

These controversy in the expression due to the deregulation of Dicer1 is involved in several types of cancer- are attributed to tissue-specific differences/to degree of aggressiveness of the given cancer <sup>(31)</sup> and that it may function as either an oncogene or a tumor suppressor gene in a tissue-specific manner <sup>(39)</sup>.

This work revealed a non-statistically significant relation between Dicer1 expression, distant metastasis and tumor grade ( $P > 0.05$ ), which was in contrast with the results of previous studies on Dicer1 in other cancers reported that Dicer1 expression was reduced in ccRCC with distant metastasis <sup>(39)</sup>, cancer cervix associated with metastatic relapse <sup>(40)</sup> and hepatocellular carcinoma with distant metastasis <sup>(43)</sup>.

Dicer1 expression has an inextricable relationship with cell migratory/invasive abilities and leads to a poor prognosis in cancer patients <sup>(32)</sup>.

From this work, Dicer1 may be a prognostic factor, as it associates with aggressive clinicopathological features and poor clinical outcome and pointing to a role for Dicer1 down regulation in tumor progression.

Using ROC curve analysis, the sensitivity and specificity of Dicer1 were 65% and 75% respectively. A previous study compatible with our results reported that classifications of ACC based on Dicer1 expression levels resulted in a much lower sensitivity and specificity (76% and 67% respectively) <sup>(21)</sup>.

## Conclusions:

Reduced Dicer1 expression with tumor progression in ACC may play a role in tumorigenesis and further decline may be associated with a poor prognosis in ACC.

Additionally, Dicer1 is not a useful marker to distinguish ACA from ACC.

**Conflicts of interest:** No conflicts of interest.

## References:

1. Lam, A. K. Y. Update on adrenal tumours in 2017 World Health Organization (WHO) of endocrine tumours. *Endocrine pathology* 2017, 28, 213-227.
2. Berland, L. L., Silverman, S. G., Gore, R. M., Mayo-Smith, W. W., Megibow, A. J., Yee, J., et al. Managing incidental findings on abdominal CT: white paper of the ACR incidental findings committee. *Journal of the American College of Radiology* 2010, 7(10), 754-773.
3. Mínguez Ojeda, C., Gómez Dos Santos, V., Álvaro Lorca, J., Ruz-Caracuel, I., Pian, H., Sanjuanbenito Dehesa, A., et al. Tumour size in adrenal tumours: its importance in the indication of adrenalectomy and in surgical outcomes—a single-centre experience. *Journal of Endocrinological Investigation* 2022, 45(10), 1999-2006.
4. Giordano TJ, Chrousos GP, Kawashima A, Koch C.A Sasano H. A. and Young W.F. Adrenal cortical adenoma. In: Lloyd RV, Osamura RY, Kloppel G, Rosai J, eds. WHO Classification of Endocrine Organs. Lyon, France: IARC Press; 2017, pp.169-172.
5. Mokhtar N, Salama A, Badawy O, Khorshed E, Mohamed G, Ibrahim M, et al. Cancer pathology registry 2000-2011. Cairo, Egypt: National Cancer Institute Cairo University. Back to cited text. 2016(18).
6. Chandrasekar, T., Goldberg, H., Klaassen, Z., Wallis, C. J., Woon, D. T., Herrera-Caceres, J. O., et al. *The who, when, and why of primary adrenal malignancies: Insights into the epidemiology of a rare clinical entity.* *Cancer* 2019, 125(7), 1050-1059.
7. Lam, A. K. Y. Adrenocortical carcinoma: Updates of clinical and pathological features after renewed world health organisation classification and pathology staging. *Biomedicines* 2021, 9(2), 175.
8. Altieri, B., Ronchi, C. L., Kroiss, M., and Fassnacht, M. Next-generation therapies for adrenocortical carcinoma. *Best Practice & Research Clinical Endocrinology & Metabolism* 2020, 34(3), 101434.
9. Nakamura, Y., Yamazaki, Y., Felizola, S. J., Ise, K., Morimoto, R., Satoh, F., et al. Adrenocortical carcinoma: review of the pathologic features, production of adrenal steroids, and molecular pathogenesis. *Endocrinology and Metabolism Clinics* 2015, 44(2), 399-410.

10. Bartel, D. P. MicroRNAs: target recognition and regulatory functions. *Cell* 2009, 136(2), 215-233.
11. Martello, G., Rosato, A., Ferrari, F., Manfrin, A., Cordenonsi, M., Dupont, S., et al. A MicroRNA targeting dicer for metastasis control. *Cell* 2010, 141(7), 1195-1207.
12. Kian, R., Moradi, S., and Ghorbian, S. Role of components of microRNA machinery in carcinogenesis. *Experimental oncology*. 2018 40, 1, 2-9
13. Lau, S. K., and Weiss, L. M. The Weiss system for evaluating adrenocortical neoplasms: 25 years later. *Human pathology* 2009, 40(6), 757-768.
14. Mete, O., Erickson, L. A., Juhlin, C. C., de Krijger, R. R., Sasano, H., Volante, M., et al. Overview of the 2022 WHO classification of adrenal cortical tumors. *Endocrine pathology* 2022, 33(1), 155-196.
15. Amin MB, EdgeS, Greene F, Byrd DR, Brookland RK, Washington MK, et al. AJCC Cancer Staging Manual, 8th edn. American Joint Committee on Cancer 2017 (Vol. 1024).
16. de Sousa GR, Ribeiro TC, Faria AM, Mariani BM, Lerario AM, Zerbini MC, et al. Low DICER1 expression is associated with poor clinical outcome in adrenocortical carcinoma. *Oncotarget*. 2015 Sep 8;6(26).
17. Ma Z, Swede H, Cassarino D, Fleming E, Fire A, and Dadras SS. Up-regulated Dicer expression in patients with cutaneous melanoma. *PLoS One*. 2011;6(6). e20494.
18. Liu J, Yang T, Huang Z, Chen H, and Bai Y. Transcriptional regulation of nuclear miRNAs in tumorigenesis (Review). *Int J Mol Med*. 2022 Jul;50(1):92.
19. Bahubeshi A, Tischkowitz M, and Foulkes WD. miRNA processing and human cancer: DICER1 cuts the mustard. *Sci Transl Med*. 2011 Nov 30;3(111):111ps46.
20. Foulkes WD, Priest JR, and Duchaine TF. DICER1: mutations, microRNAs and mechanisms. *Nat Rev Cancer*. 2014 Oct;14(10):662-72.
21. Caramuta S, Lee L, Ozata DM, Akçakaya P, Xie H, Höög A, et al. Clinical and functional impact of TARBP2 over-expression in adrenocortical carcinoma. *Endocr Relat Cancer*. 2013 Jul 4;20(4):551-64.
22. Decmann A, Perge P, Turai PI, Patócs A, and Igaz P. Non-Coding RNAs in Adrenocortical Cancer: From Pathogenesis to Diagnosis. *Cancers (Basel)*. 2020 Feb 17;12(2):461.
23. Sugito N, Ishiguro H, Kuwabara Y, Kimura M, Mitsui A, Kurehara H, et al. RNASEN regulates cell proliferation and affects survival in esophageal cancer patients. *Clin Cancer Res*. 2006 Dec 15;12(24):7322-8.
24. Chiosea S, Jelezcova E, Chandran U, Acquafondata M, McHale T, Sobol RW, et al. Up-regulation of dicer, a component of the MicroRNA machinery, in prostate adenocarcinoma. *Am J Pathol*. 2006 Nov;169(5):1812-20.
25. Sand M, Gambichler T, Sand D, Altmeyer P, Stuecker M, and Bechara FG. Immunohistochemical expression patterns of the microRNA-processing enzyme Dicer in cutaneous malignant melanomas, benign melanocytic nevi and dysplastic melanocytic nevi. *Eur J Dermatol*. 2011 Jan-Feb;21(1):18-21.
26. Faber C, Horst D, Hlubek F, and Kirchner T. Overexpression of Dicer predicts poor survival in colorectal cancer. *Eur J Cancer*. 2011 Jun;47(9):1414-9.
27. Chiosea S, Jelezcova E, Chandran U, Luo J, Mantha G, Sobol RW, et al. Overexpression of Dicer in precursor lesions of lung adenocarcinoma. *Cancer Res*. 2007 Mar 1;67(5):2345-50.
28. Grelier G, Voirin N, Ay AS, Cox DG, Chabaud S, Treilleux I, et al. Prognostic value of Dicer expression in human breast cancers and association with the mesenchymal phenotype. *Br J Cancer*. 2009 Aug 18;101(4):673-83.
29. Wu JF, Shen W, Liu NZ, Zeng GL, Yang M, Zuo GQ, et al. Down-regulation of Dicer in hepatocellular carcinoma. *Med Oncol*. 2011 Sep;28(3):804-9.
30. Wu D, Tao J, Xu B, Li P, Lu Q, and Zhang W. Down regulation of Dicer, a component of the microRNA machinery, in bladder cancer. *Mol Med Rep*. 2012 Mar;5(3):695-9.
31. Yang R, Xu J, Hua X, Tian Z, Xie Q, Li J, et al. Overexpressed miR-200a promotes bladder cancer invasion through direct regulating Dicer/miR-16/JNK2/MMP-2 axis. *Oncogene*. 2020 Feb;39(9):1983-1996.
32. Hsu TW, Chen HA, Liao PH, Su YH, Chiu CF, Huang CY, et al. Dicer-mediated miR-200b expression contributes to cell migratory/invasive abilities and cancer stem cells properties of breast cancer cells. *Aging (Albany NY)*. 2022 Aug 8;14(16):6520-6536.
33. Zhang J, Zhang XH, Wang CX, Liu B, Fan XS, Wen JJ, et al. Dysregulation of microRNA biosynthesis enzyme Dicer plays an important role in gastric cancer progression. *Int J Clin Exp Pathol*. 2014 Mar 15;7(4):1702-7. PMID: 24817967; PMCID: PMC4014251.
34. Chen YS, Meng F, Li HL, Liu QH, Hou PF, Bai J, et al. Dicer suppresses MMP-2-mediated invasion and VEGFA-induced angiogenesis and serves as a promising

- prognostic biomarker in human clear cell renal cell carcinoma. *Oncotarget*. 2016 Dec 20;7(51):84299-84313.
35. Lombard AP, Lim RM, Nakagawa RM, Vidallo KD, Libertini SJ, Platero AJ, et al. Dicer ablation promotes a mesenchymal and invasive phenotype in bladder cancer cells. *Oncol Rep*. 2015 Sep;34(3):1526-32.
  36. Wang XJ, Jiang FZ, Tong H, Ke JQ, Li YR, Zhang HL, et al. Dicer1 dysfunction promotes stemness and aggression in endometrial carcinoma. *Tumour Biol*. 2017 Apr;39(4):1010428317695967.
  37. Szczyrek M, Kuźnar-Kamińska B, Grenda A, Krawczyk P, Sawicki M, Głogowski M, et al. Diagnostic value of plasma expression of microRNAs complementary to Drosha and Dicer in lung cancer patients. *Eur Rev Med Pharmacol Sci*. 2019 May;23(9):3857-3866.
  38. Merritt, W. M., Lin, Y. G., Han, L. Y., Kamat, A. A., Spannuth, W. A., Schmandt, R., et al. Dicer, Drosha, and outcomes in patients with ovarian cancer. *New England Journal of Medicine* 2008, 359(25), 2641-2650.
  39. Ma X, Fan Y, Gao Y, Zhang Y, Huang Q, Ai Q, et al. Dicer is down-regulated in clear cell renal cell carcinoma and in vitro Dicer knockdown enhances malignant phenotype transformation. *Urol Oncol*. 2014 Jan;32(1):46.e9-17.
  40. He L, Wang HY, Zhang L, Huang L, Li JD, Xiong Y, et al. Prognostic significance of low DICER expression regulated by miR-130a in cervical cancer. *Cell Death Dis*. 2014 May 1;5(5):e1205.
  41. Ramírez-Moya J, Wert-Lamas L, Riesco-Eizaguirre G, and Santisteban P. Impaired microRNA processing by DICER1 downregulation endows thyroid cancer with increased aggressiveness. *Oncogene*. 2019 Jul;38(27):5486-5499.
  42. Zhang Z, Zhang G, Kong C, Bi J, Gong D, Yu X., et al. EIF2C, Dicer, and Drosha are up-regulated along tumor progression and associated with poor prognosis in bladder carcinoma. *Tumour Biol*. 2015 Jul;36(7):5071-9.
  43. Zhang LI, Wang C, Liu S, Zhao Y, Liu C, and Guo Z. Prognostic significance of Dicer expression in hepatocellular carcinoma. *Oncol Lett*. 2016 Jun;11(6):3961-3966.

**To cite this article:** Heba M. Rashad, Aya A. Abdel Monem, Mohebat H. Goda, Taghreed A. Abdel Aziz. Significance of Dicer1 in Adrenocortical Adenoma and Carcinoma (Immunohistochemical Study). *BMFJ* XXX, DOI: 10.21608/bmfj.2023.228490.1875.