

Original Article

Three-layered approach utilizing pedicled buccal fat pad in surgical closure of chronic oroantral fistula: A case series study.

Ahmed Yousef 1, Nada Noureldin 2, Hesham S. Abdelmoneim 1, Walaa Kadry 1*

1.Department of Oral & Maxillofacial Surgery, Faculty of Dentistry, Cairo University.

2.Department of Oral & Maxillofacial Pathology, Faculty of Dentistry, Cairo University.

*Email: walaakadry@dentistry.cu.edu.eg

Submitted: 11-04-2023

Accepted: 31-07-202

Abstract

The objective of this study was to assess the efficacy of utilizing pedicled buccal pad of fat (BPF) through three-layered approach for closure of large, chronic oroantral fistula (OAF). OAF as an inadvertent sequelae of posterior Maxillary surgery or trauma, represents a significant problem to patients and clinicians. This complication may be caused by impacted tooth odontectomy, enucleation of large Maxillary cyst or tumor of following jaw infection. It's usually followed by Maxillary sinusitis that have to be managed before closure of this pathological communication. Pedicled BPF is a readily available, abundant type of flap with no donor site morbidity and good blood supply. Patients & methods: BPF was utilized as an intermediate layer in a three-layered approach to manage the soft tissue component of the OAF. Assessment included the clinical soft tissue healing, pathological assessment of specimen of the fistulous tract and recurrence of the fistula if any; which was monitored one week and three months postoperatively. Results: The study population included five patients. Healing went uneventful in all cases without dehiscence, vestibular depth compromise or recurrence of OAF. Conclusion: Within the limitations of the current study, it seems that the pedicled BPF technique is simple, easy, versatile one. It represents a promising alternative to different local and regional flaps for closure of OAF with successful results. A study with larger sample size is recommended by the authors.

Keywords: oroantral fistula, buccal pad of fat, buccal mucosa

1. Introduction

Oroantral fistula (OAF) is a pathological communication between the Maxillary antrum and the oral cavity. It occurs as an inadvertent sequelae of posterior Maxillary surgery or trauma and represents a significant problem to patients and clinicians. This complication may result from impacted tooth odontectomy, enucleation of large Maxillary cyst or tumor, following infection, implant failure, radiotherapy or as a complication of Caldwell-Luc operation. Azzouzzi et al. 2022

Oroantral communication (OAC) that went undiagnosed or improperly management, would get epithelialized within 24 to 72 hours forming a permanent epithelial tract (fistula) that will eventually allow bacterial passage to the sinus with subsequent sinusitis in most of the cases. Abdel-Aziz et al, 2018

Various flaps for closure of OAF have been described in literature. Starting with local, regional and distal tissue flaps and ending with autografts and their alloplastic or allogenic alternatives, have been reported in literature. Ossama H. et al, 2012, Cláudio Marcantonio et al., 2015 and A Senthil Kumar et al., 2022 Each technique has its own advantages and disadvantages.

The selection of the appropriate technique for closure of OAF depends on the site, size, the cause of the fistula, patient's age & medical condition and the operator skill. Manuel S et al., 2015 The size of OAF is a critical factor. The defects can be classified as small (up to 1 cm), medium (1-4 cm) or large (more than 4 cm) defects. Local flaps could be sufficient for closure of small and medium size defects, where in large defects, pedicled flaps could be more advantageous for optimizing healing and

decreasing the risk of recurrence of OAF. Peter Egyedi, 1977

Candamourty R et al., 2012 reported that defects less than 5 mm heal spontaneously while defects more than 5 mm require surgical intervention. The intervention comprises different options like the buccal (advancement, pad fat, transposition or myo-mucosal), pedicled palatal rotation (mucosal, submucosal or island) or tongue flap. The selection from the various options further depends on the site of the fistula which could be buccal, occlusal or palatal to the alveolus. Azzouzzi et al., 2022 Moreover, defects that follow radiotherapy favors a pedicled flap to ensure sufficient vascularization and improved healing to the compromised defect bed. Candamourty R et al. 2012

Besides the various soft tissue flaps, different autogenous, alloplastic grafts and membranes have been utilized Peter Egyedi, 1977, Manuel S et al., 2015 and Sharma et al., 2019. Buccal pad of fat has raised attention in recent years. BPF is abundant, lobulated, easily accessible adipose tissue located between buccinator muscle and mandibular ramus. Bither S et al, 2013 and Abdelaziz M et al., 2018 It extends to infratemporal fossa superiorly, retromolar area inferiorly and anteriorly till the point where the Stenson's duct Pierces the buccinator muscle. BPF is also readily attainable under local anesthesia Peter Egyedi, 1977 and Bither S et al., 2013

Added to the abundant blood supply of BPF flap and decreased donor site morbidity, BPF flap is a source of mesenchymal stem cells with multilineage potential. Farre-Guasch E et al., 2010 and Trevor LV et al, 2020 The derived stem cells further stimulate angiogenesis making BPF a versatile option for regenerative therapies.

Farre-Guasch E et al., 2010 Moreover, it readily epithelializes within 2 weeks without the need to be covered with additional soft tissue layer or skin graft. Stajčić Z, 1992

BPF has been increasingly utilized for repair of various defects including OAF due to its numerous advantages. Utilization of BPF flap in OAF repair was first described by Egyedi, 1977. Later in many researches, BPF was utilized either as a sole flap technique (Stajčić Z, 1992, Hanazawa Y et al., 1995 and Hakobyan k et al., 2018), strengthened with additional overlying buccal mucosal flap (Benjamin et al., 2009, Candamourty R et al., 2012 and Hakobyan K et al., 2018) or with a bone graft underneath. Sharma SP, 2019

Closure of OAF is necessary for eradication of infection, sinus floor reconstruction and allowing future prosthetic rehabilitation. To address these concerns, pedicled BPF was utilized as an added tissue layer. Reviewing literature, BPF was utilized for closure of OAF, (Peter Egyedi, 1977 and Stajčić Z, 1992 and following tumor excision (Samman N et al., 1993, Rapidis AD et al., 2000 and Dean A et al., 2001) and for management of palatal and dentoalveolar defects, Levi B et al, 2009

Authors believe that this technique may decrease the risk of recurrence of oroantral fistula. Moreover, the technique is simple and requires minimal time, dissection and operator skill to harvest it. The only three-layered approach that was mentioned in literature has included press fit chin graft, BPF and buccal flap. Peter Egyedi, 1977 and Sharma SP, 2019 The aim of the current study is to report the results of utilization of BPF in closure of chronic oroantral fistula with underlying maxillary sinus floor defect for different reasons.

2. Patients and methods

Five patients (3 males and 2 females) with chronic oroantral fistula were retrieved from the outpatient clinic of the oral and maxillofacial surgery department of faculty of oral and dental medicine, Cairo University. All patients were evaluated in terms of the etiology of the maxillary defect, clinical presentation and radiographic sinus assessment to be included in the current study. Patients with uncontrolled medical condition or with a history of previous repair of oroantral fistula were excluded from the study. Informed consent was obtained from all patients. The present study was approved by the institutional ethical committee that follows the Declaration of Helsinki guidelines.

Medical status was reviewed including any symptoms suggestive for OAF. The size of OAF was examined as well as the presence of any associated lesions. Preoperative radiography was ordered to exclude any antral pathology or presence of remaining roots which had been left behind.

2.1. Surgical outline

The surgery in all patients included: 1. Marking the soft tissue surrounding the fistula and its inversion in the sinus for reconstructing the sinus floor (1st layer); 2. Elevation of buccal mucosal flap, preparing the oral (3rd) layer; 3. Exposure and utilization of the pedicled BPF as an intermediate (second) layer.

Surgical technique

2.1.1. Sinus floor reconstruction (inner layer)

Following administration of local anesthesia (2% lidocaine with 1/ 200 000 epinephrine), the 2mm of alveolar mucosa was marked all around the fistulous tract, incised, elevated and sutured to reconstruct the sinus floor and representing the first layer of closure (**Figure 1**). Prior to suturing,

biopsies from the five patients were obtained from multiple sites of the pathological sinus tract and submitted for histopathological examination.

2.1.2. BPF harvesting (intermediate layer)

A buccal trapezoidal flap was then elevated. To expose the buccal pad of fat, 5 mm vertical incision (posterior to the zygomatic buttress) at the level of upper second molar followed by blunt dissection was performed on the periosteal surface of the buccal flap.

A curved hemostat was introduced closed through the incision in a disto- cranial direction opposite to the Maxillary second molar, wide open and withdrawn, to expose the BPF. That was repeated on demand with gentle pedicle traction to expose sufficient amount of BPF necessary for covering the bony defect without tension (**Figure 1**). The proximal part of BPF was handled carefully to avoid compromising its blood supply. The pedicled buccal pad of fat was then sutured to the palatal mucosa (4-0 vicryl suture) creating a second layer of closure.

2.1.3. Oral layer soft tissue closure (outermost layer)

Horizontal incisions were performed on the periosteal surface of the buccal flap to be advanced over the BPF layer with the least tension and to avoid compromising the depth of buccal vestibule significantly. It was then sutured to the palatal mucosa with interrupted sutures creating the 3rd layer.

2.2. Postoperative Care

All patients were instructed to avoid nasal blowing or any maneuver that might build up negative antral pressure for two weeks. They are also instructed to avoid smoking for at least 3

months, run on soft diet on the operated side and to follow strict oral hygiene measures.

Postoperative systemic antibiotic (**Amoxicillin 500 mg with Clavunic acid 125 mg**), decongestant and analgesics were prescribed for one week. The patients were followed up clinically up to three months. They were recalled weekly for the first month and then monthly for 3 months to check for any signs of infection or dehiscence.

3. Results

All patients were suffering from chronic large oroantral fistula. One of them had complaints related to sinus infection and pain. Mean age of patients was 40.6 years. The defects were unilateral with three of them located buccal to the alveolar ridge and two of them in the ridge. Most defects are located in the premolar region. The average defect size was recorded at its greatest dimension. Variable size bone defects were revealed on computed tomography that has been requested from the patients (Table 1).

3.1. Histological Results:

Histopathological Examination of H&E-stained sections revealed chronically inflamed granulation tissue covered by respiratory ciliated, pseudostratified epithelium. Parts of the sinus lining showed polyp formation. Other parts next to the oral cavity showed stratified squamous epithelial lining. The connective tissue showed dilated blood vessels with marked chronic inflammatory cell infiltrate. However, no signs of fungal infection or malignancy were detected for any of the five patients.

3.2. Clinical results:

Healing went uneventful in all patients. In one case exposure of BPF occurred and

epithelialization was revealed on the follow up visits. On 1st week, the exposed BPF was yellowish pink in color which turned whitish on the second week owing to granulation tissue

maturation. Complete mucosal epithelialization was revealed on the next visits and on three months without recurrence of OAF. Mild shallowing of the upper vestibule was noticed.

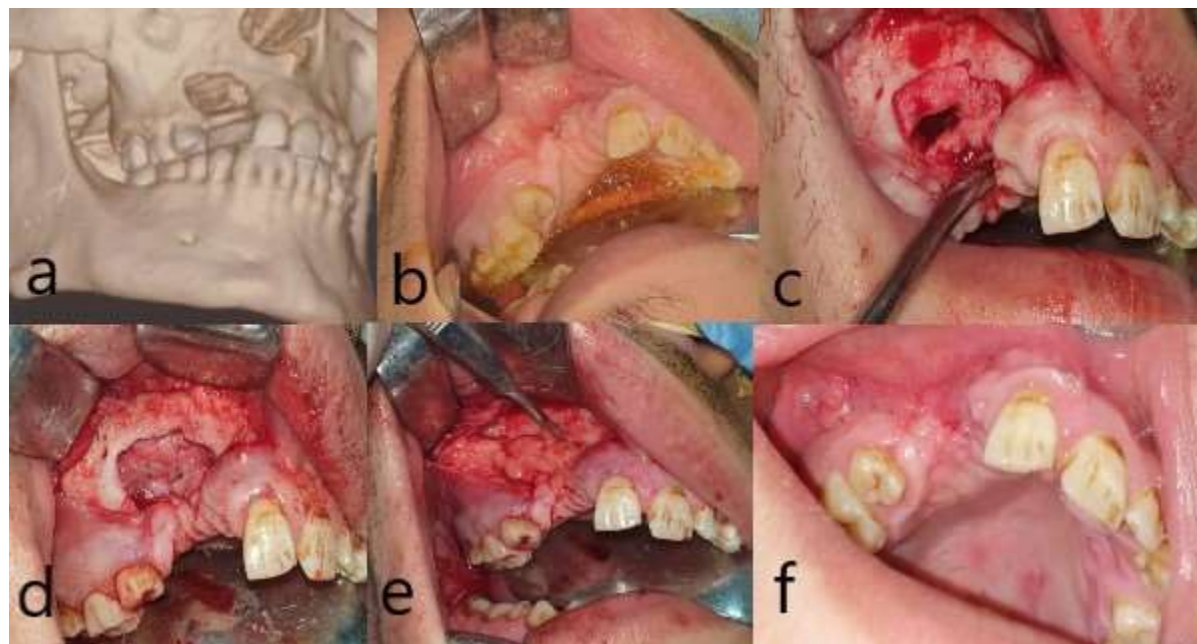


Figure 1: Preoperative CT showing the defect size (a), Preoperative photograph showing the fistula, arrow (b), Reflection of the buccal flap and elevation of 2mm of alveolar mucosa all around the fistulous tract, incised (c), Suturing and reconstruction of the sinus floor (the first layer) (d), Traction of BPF to cover the defect (second layer) (e), Reposition of the buccal advancement flap over BPF (3rd layer) (f).

Table 1: Demographic data of the included patients

Patient	1	2	3	4	5
Number					
Age (years)	43	32	47	36	45
Sex	M	M	F	M	F
Site	Lt	Rt	Rt	Rt	Lt
Size of soft tissue defect (cm)	0.5x 1	0.3x 0.6	Pin point	1x 1.4	0.6 x 1.1
Size of bony defect (cm)	0.8x 1.3	1.4x 1.8	2.5x 2.0	1.2x 2.0	1.7 x 1.4

Cause of the defect	Traumatic extraction	Traumatic extraction	Traumatic odontectomy of impacted maxillary canine	Implant failure	Traumatic extraction
Postop. dehiscence	No	No	No	No	No

4. Discussion

Long term closure of chronic OAF without the possibility of future Fistulation is a challenging technique for a Maxillofacial surgeon. It necessitates consideration of various factors like the size of the defect, eradication of infection, scaring due to previous surgeries as well as operator skill. **Gheisari R. et al, 2019**

The BPF volume is abundant enough to cover a large defect area around 10 cm² but during harvesting, the periosteal incision shouldn't exceed 5 mm to avoid protrusion of the whole BPF body, hence obstructing the surgical field with difficulty of reinsertion of the excess volume. **Staicic Z et al., 1992**

Vascularized tissue like pedicled buccal pad of fat has shown to be useful for management of posterior Maxillary defects for different reasons. (Levi B et al, 2009, **Bither S et al, 2013** and **Park J et al ,2019**. BPF is a highly vascularized, versatile flap that requires minimal skill to harvest and a potential source of undifferentiated mesenchymal stem cells. It's readily available in abundant volume, readily accessible to the surgical site because of its favorable anatomical location, thus decreasing the operative time and overall cost. Utilization of BPF is a simple technique which results in minimal donor site morbidity and unaltered vestibular depth. The possibility to be performed under local anesthesia is an added advantage. **Candamentory R et al., 2012** and **Azzouzzi A et al., 2022** Therefore, addition of an intermediate layer of vascularized tissue via utilization of BPF serves to fill the

defect and enhance the vascularity to the area, with subsequent reduction of the risk of recurrent fistulation through reduction of wound contracture **Levi B et al, 2009**

On the other hand, few problems may be encountered with BPF harvesting. Shrinkage or perforation could result from dissection to tease out the BPF through the incision. In this situation the coverage of large oroantral defect with BPF alone may get compromised. **Candamentory R et al., 2012** Moreover, the size of BPF is large in children but variable in adults so augmenting the BPF with the buccal advancement flap may compensate for insufficient volume of BPF in some patients. **Candamentory R et al., 2012**

Unlike other reports, most of the fistulas in the current study resulted from traumatic surgical extraction, with subsequent significant bone loss. The yielded sinus infection was minimal and managed thoroughly prior surgery, if any to guarantee the health of tissues surrounding the fistula to be everted to reconstruct the sinus floor. Later a combination flap of BPF and buccal advancement flap was utilized.

Reviewing literature, it was recommended to fully cover BPF with split thickness skin graft Peter **Egyedi 1977**, so a combination flap (buccal advancement & BPF) was utilized by the authors. However, recent literature supports that BPF readily epithelializes when exposed to the oral cavity

Authors believe that maxillofacial surgeons would benefit from utilization of this simple, readily accessible and easily harvested

vascularized flap in management of chronic, large size oroantral defects. **Levi B** et al, 2009 Despite the buccal advancement flap may be the first choice, its utilization is challenging in large defects with the risk of postoperative dehiscence. An interpositional buccal pad of fat add firmness to the final closure which is enhanced by the rich blood supply that diminish the risk of postoperative dehiscence. The BPF can also epithelialize within 2- 3 weeks without complications. **Staicic Z**, 1992 However, the vestibular depth compromise remains but it can be managed later with pre-prosthetic surgery before dental rehabilitation **Staicic Z** 1992

In another study, OAF was managed with BPF flap and endoscopic drainage of the maxillary sinus through the middle meatus. **Abdelaziz et al.**, 2018 Closure of OAF was attained with BPF alone in different studies **Hanazawa Y** et al, 1995 while in others' closure was attained with BPF combined with buccal mucosal flap **MK Jain et al**, 2012 In another study, the mucosal flap was further supported with titanium mesh till complete healing before its removal. **Pedro H et al.**, 2015 and **Nishikubo S** et al 2021, utilized BPF together with nasolabial flap for closure of palatal defects following maxillectomy.

The only study provided three- layered closure of OAF had utilized a press fit Chin graft, BPF and buccal advancement flap **Sharma** 2019, while in the present study the three-layered approach comprised reconstructed sinus floor, BPF and buccal advancement flap which was not mentioned earlier in literature. The main consideration in the present study was to attain sepsis free sinus membrane and tension free closure of the overlying mucosa. Owing to the numerous forementioned advantages of BPF, it was utilized as interpositional graft in the current study.

5. Conclusion

BPF is a convenient solution for management of chronic large oroantral defects with minimal Fistulation recurrence postoperative and without donor site morbidity. Authors recommend more studies in the future with larger sample size.

Conflict of interest:

Authors declare no conflicts of interest

Funding

This research didn't receive any specific grants from funding agencies in the public, commercial, or not-for-profit sectors.

Ethics:

The study protocol was approved by the ethical committee of Faculty of Dentistry- Cairo university on 31 January, 2023, approval number 25-1-23

6. References

Abdel-Aziz M, Fawaz M, Kamel M, Kamel A, Aljeraiis T. (2018) 'Closure of Oroantral Fistula with Buccal Fat Pad Flap and Endoscopic Drainage of the Maxillary Sinus', *J Craniofac Surg*, doi: 10.1097/SCS.0000000000004709.

A Senthil Kumar, C Prasad, Davidson Rajiah, P Kamalakannan, S Praveen Kumar. (2022) 'Closure of Oroantral Communication with Gelfoam and Collagen Membrane after Periapical Cyst Enucleation, A Case Report', *Journal of Clinical and Diagnostic Research*, DOI: 10.7860/JCDR/2022/50228.16926

Azzouzi A, Hallab L, Chbicheb S. (2022) 'Diagnosis and Management of Oro-antral fistula: Case series and review', *Int J Surg Case Rep*, doi: 10.1016/j.ijscr.2022.107436.

Bither S, Halli R, Kini Y. (2013) 'Buccal fat pad in intraoral defect reconstruction', *J Maxillofac Oral Surg.*, doi: 10.1007/s12663-010-0166-9.

- Candamourty R, Jain MK, Sankar K, Babu MR. (2012) 'Double-layered closure of oroantral fistula using buccal fat pad and buccal advancement flap', *J Nat Sci Biol Med*, doi: 10.4103/0976-9668.101930.
- Cláudio Marcantonio, Michelle Palmieri, Daniel Villela Gorga, Magali de Oliveira Pereira, Lélis Gustavo Nícoli, Waldyr Antônio Jorge. (2015) 'Use of a palatal pedicle flap for closure of an oroantral fistula', *RGO, Rev Gaúch Odontol*, Porto Alegre, <http://dx.doi.org/10.1590/1981-863720150003000202954>
- ean A, Alamillos F, García-López A, Sánchez J, Peñalba M. (2001) 'The buccal fat pad flap in oral reconstruction', *Head Neck*, doi: 10.1002/hed.1048.
- Farré-Guasch E, Martí-Pagè C, Hernández-Alfaro F, Klein-Nulend J, Casals N. (2010) 'Buccal fat pad, an oral access source of human adipose stem cells with potential for osteochondral tissue engineering: an in vitro study', *Tissue Eng Part C Methods*, doi: 10.1089/ten.TEC.2009.0487.
- Gheisari R., Hosein Zadeh H., Tavanafar S. (2019) 'Oro-Antral Fistula Repair with Different Surgical Methods: a Retrospective Analysis of 147 Cases', *J Dent Shiraz Univ Med Sci*, DOI: 10.30476/DENTJODS.2019.44920
- Hakobyan K, Poghosyan Y, Kasyan A. (2018) 'The use of buccal fat pad in surgical treatment of 'Krokodil' drug-related osteonecrosis of maxilla', *J Craniomaxillofac Surg.*, doi: 10.1016/j.jcms.2018.03.007.
- Hanazawa Y, Itoh K, Mabashi T, Sato K. (1995) 'Closure of oroantral communications using a pedicled buccal fat pad graft', *J Oral Maxillofac Surg.*, doi: 10.1016/0278-2391(95)90329-1.
- Levi B, Kasten SJ, Buchman SR. (2009). 'Utilization of the buccal fat pad flap for congenital cleft palate repair', *Plast Reconstr Surg.*, doi: 10.1097/PRS.0b013e318199f80f.
- Manuel S, Kumar S, Nair PR. (2015) 'The Versatility in the Use of Buccal Fat Pad in the Closure of Oro-antral Fistulas', *J Maxillofac Oral Surg.*, doi: 10.1007/s12663-014-0669-x.
- M.K. Jain, C. Ramesh, K. Sankar, K.T, Lokesh Babu. (2012) 'Pedicled buccal fat pad in the management of oroantral fistula: a clinical study of 15 cases', *International Journal of Oral and Maxillofacial Surgery*, <https://doi.org/10.1016/j.ijom.2012.02.014>.
- Nishikubo S, Matsuda H, Watanabe S, Tamura H, Tonogi M. (2021) 'Reconstruction of maxillary palatal defects after partial maxillectomy using a pedicled buccal fat pad and a nasolabial flap', *Clin Case Rep.*, doi: 10.1002/ccr3.4442.
- Ossama Hassan, Tamer Shoukry, Alaa Abdel Raouf, Hassan Wahba, (2012) 'Combined palatal and buccal flaps in oroantral fistula repair', *Egyptian Journal of Ear, Nose, Throat and Allied Sciences*, <https://doi.org/10.1016/j.ejenta.2012.06.002>
- Park J, Chun BD, Kim UK, Choi NR, Choi HS, Hwang DS. (2019) 'Versatility of the pedicled buccal fat pad flap for the management of oroantral fistula: a retrospective study of 25 cases' *Maxillofac Plast Reconstr Surg.*, doi: 10.1186/s40902-019-0229-x.
- Pedro Henrique de Souza Lopes, Diogo de Oliveira Sampaio, Bruno Luiz de Souza Menezes, Daniel Ferreira do Nascimento, Belmino Carlos Amaral Torres. (2015) 'Combined palatal flap and titanium mesh for oroantral fistula closure' *Ann Maxillofac Surg*, doi: 10.4103/2231-0746.161090

Peter Egyedi, (1977) 'Utilization of the buccal fat pad for closure of oro-antral and/or oro-nasal of Maxillofacial Surgery, [https://doi.org/10.1016/S0301-0503\(77\)80117-3](https://doi.org/10.1016/S0301-0503(77)80117-3).

Rapidis AD, Alexandridis CA, Eleftheriadis E, Angelopoulos AP. (2000) 'The use of the buccal fat pad for reconstruction of oral defects: review of the literature and report of 15 cases', *J Oral Maxillofac Surg.*, doi: 10.1016/s0278-2391(00)90330-6.

Samman N, Cheung LK, Tideman H. (1993) 'The buccal fat pad in oral reconstruction. *Int J Oral Maxillofac Surg.*', doi: 10.1016/s0901-5027(05)80346-7.

Sharma SP. (2019) 'Three-Layered Closure of Persistent Oroantral Fistula Using Chin Graft, Buccal Fat Pad, and Buccal Advancement Flap: A Case Report with Review of Literature. *Case Rep Dent.*', doi: 10.1155/2019/8450749.

Stajčić Z. (1992) 'The buccal fat pad in the closure of oro-antral communications: a study of 56 cases', *J Craniomaxillofac Surg.*, doi: 10.1016/s1010-5182(05)80314-2.

Trevor LV, Riches-Suman K, Mahajan AL, Thornton MJ. (2020) 'Adipose Tissue: A Source of Stem Cells with Potential for Regenerative Therapies for Wound Healing'. *J Clin Med.*, doi: 10.3390/jcm9072161.