



Study Vitamin D3 Effect on Polycystic Ovarian Induction by Letrozole of Rat



Abd alrazaq E. Abd alrazaq* and Fadwa Kh. Tawfeeq

Department of Physiology, Biochemistry and Pharmacology, College of Veterinary Medicine, University of Mosul, Mosul, Iraq

The goal of this study was to investigate the impact of letrozole-induced Polycystic ovary (PCOS) on rat ovarian physiology and determine the most probable positive effects of vitamin D3. Twenty-four female albino rats were divided into four groups: control, letrozole, vit D3, (letrozole and vit D3) various dosages administered orally for 21 days. The results showed that letrozole significantly increased body and ovarian weights compared to the control group, whereas, vitamin D3 treatment with letrozole showed a significant decrease in body weight compared to the letrozole group, but there were no significant change in ovarian weight compared to the letrozole group. Letrozole treatment showed the highest number of cystic follicles compared to the control group, the group of vit D3 treatment with letrozole showed significant decrease in the number of cystic follicles compared to the letrozole group. In the letrozole and vitamin D3 group there was an improvement in the GSH, MDA, LH, FSH, AMH, estrogen, progesterone and testosterone levels. This study concluded that letrozole had adverse effects on body and ovarian weights which leading to an increase in their weight. In addition, the use of vit D3 at these dose and duration of the treatment had minimal effects on mitigating or reversing the adverse effects of letrozole.

Keywords: Polycystic ovary, Letrozole, Vitamin D3, Rats.

Introduction

Polycystic ovary syndrome (PCOS) is the most prevalent endocrine condition affecting females of reproductive age, also known as hyperandrogenic anovulation (HA) [1,2]. PCOS is a complicated psychological, metabolic, and reproductive disorder that is occasionally linked to insulin resistance and is characterized by either hyperandrogenism or abnormal gonadotropin production [3]. This syndrome is accompanied by hormonal disruption, including decreased progesterone levels and increased levels of testosterone and luteinizing hormone [4]. Cystic follicles are the most frequent reason for infertility in cattle [5]. Because of the increased calving to conception and calving intervals,

this disease can result in severe economic losses for the dairy industry [6]. According to some research, increasing milk yield in dairy cattle may increase the risk of developing ovarian cysts [7]. Nutrition, feeding management, and housing type are all connected with the likelihood of developing ovarian cysts in dairy cows [8]. Letrozole It is the third generation of a non-steroidal aromatase inhibitor that induces a PCOS model [9]. It inhibits testosterone and androstenedione conversion to estradiol and estrone, respectively, causing PCOS by creating hormonal imbalance, circulating hyperandrogenism, and intra-ovarian androgen excess, resulting in polycystic ovary. [10]. Letrozole induction has been linked to hyperglycemia, which may contribute to insulin resistance and hyperlipidemia, leading to

*Corresponding author: Abd alrazaq, E. Abd alrazaq, E-mail: refae1995@gmail.com. Tel.: 009647733230565

(Received 31/08/2023, accepted 19/10/2023)

DOI: 10.21608/EJVS.2023.233155.1594

©2024 National Information and Documentation Center (NIDOC)

metabolic syndrome [11,12]. Vitamin D3, also known as cholecalciferol, is an endogenous fat-soluble steroid that is either biosynthesized in human skin by sunshine or absorbed from food and health supplements [13]. Multiple metabolic events are required for the creation of vitamin D3 and its subsequent conversion to active or inactive metabolites, UV-B radiation from sunlight changes epidermal 7-dehydrocholesterol (provitamin D3) to vitamin D3, which is subsequently taken to the liver by plasma proteins and transformed into calcifediol or 25-hydroxyvitamin D3 via a hydroxylation process in mammals [14,15]. Vitamin D3 is essential for calcium and phosphorus metabolism, Its primary activities include intestinal calcium absorption and renal calcium reabsorption, as well as a direct influence on chondrocyte and osteoblast differentiation and bone production [16]. Vitamin D may influence glucose metabolism by improving insulin production and release, increasing insulin receptor expression, or suppressing proinflammatory cytokines that may contribute to the development of insulin resistance [17]. Vitamin D3 plays a role in the occurrence of infertility due to the presence of vitamin receptors in many tissues [18] Vitamin D3 receptors were found in the ovaries, uterus, and placenta of female reproductive organs. According to some studies, females who have weak vitamin D3 receptors develop infertility with reduced folliculogenesis[19]

Experimental

Material

Letrozole (Accord, United Kingdom) was given orally using a gavage needle at 3mg/kg body weight [20]. vitamin D3 (FDC Nutrition United States) was given orally by gavage needle at 1000 IU/Kg body weight [21]. which had all been dissolved in 5% Carboxymethyl cellulose (CMC).

Animals

Female albino rats (n=24) weighing 150-257g and 3 months old were kept in a plastic cages under regulated environmental conditions with a 12 h light/dark cycle and a temperature of 30 ± 3 °C. Ad libitum rodent food and tap water were given.

Estrus cycle

The estrous cycles were identified by taking vaginal smears every day between 8:00 AM and 9:00 AM for 21 days. Vaginal secretion was collected with a sterile cotton swab soaked in normal saline (NaCl

0.9%) by inserting 0.5 cm into the rat vagina, rotating for 2-3 revolutions against the vaginal wall, withdrawing, and rolling on a clean glass slide [22]. The smears were air-dried and examined under a light microscope (magnifications 10x and 40x). The estrous cycle stages were established by classifying vaginal smears based on their cytological appearance [23]. A proestrus smear was dominated by nucleated epithelial cells, but an estrous smear was dominated by anucleated cornified cells, a metestrus smear had the same percentage of leukocytes, cornified, and nucleated epithelial cells as a diestrus smear, with a predominance of leukocytes[21].

Experimental Design

The experimental animals were divided into four groups (n=6 each) and dosed orally with a gavage needle for 21 days as : follow control group (CMC), letrozole group (3mg/kg body weight), vitamin D3 group (1000IU/kg body weight), group letrozole +vitamin D3 (3mg/kg +1000IU/kg body weight). Rats were weighed on the first day, then every three days for dose calibration and at end of therapy the body weight was listed and the ovaries were dissected and weighed in comparison to the body weight. On the day after the last dosage, all rats were thoroughly sedated with intraperitoneal injections of xylazine (interchemie, Holland) (5 mg/kg/b.w.) and ketamine (dutch farm, Holland) (50 mg/kg/b.w.) to collect the ovaries. Six ovaries were removed from each experimental group by scissors and forceps then fixed in formalin 10% after passing them through a succession of ethyl alcohol concentrations (70, 95, 100)% to remove water (dehydration), and then xylol for clarifying before being embedded in paraffin. The blocks were sectioned at 5 micrometer and stained with hematoxylin-eosin (H&E), The ovarian sections were examined using a light microscope (Novel, China) and a camera (Omax, China) for picturing the ovarian sections. For each ovary (n=12/group), serial slices were examined. Using the Image J/Fiji 1.46 application, two perpendicular diameters were measured for each cyst that showed in each region. All hormones were measured by (ELISA) Enzyme-linked immunosorbent assay kit (ELK Biotechnology, P.R.C) according to the user manual

Statistical analysis

JMP Pro16.1 software (2021 SAS Institute Inc., North Carolina, USA) was used for descriptive and

inferential statistics. The mean and standard error were descriptive statistics. The results were examined using analysis of variance (ANOVA) to assess the effect of the treatments on the animals and ovarian weights. Duncan's multiple range test was used to identify differences between treatment groups. The chi-square test was performed to evaluate if there was a significant difference between the treatments in terms of the number of cystic follicles. $P \leq 0.05$ was used to determine significance.

Results and Discussion

When compared to the control group, treatment with letrozole alone resulted in a significant ($P \leq 0.05$) increase in body weight. When vitamin D3 is combined with letrozole, there was a significant decrease in body weight compared to the letrozole group. As shown in fig. 1 .

When compared to the control group, letrozole alone resulted in a significant increase in relative ovarian weight. whereas the addition of vitamin D3 to letrozole did not show any significant differences in ovarian weight when compared to letrozole alone.as shown in fig.2 .

When compared to the control group, letrozole alone resulted in a significant increase in LH level ,When vit D3 is combined with letrozole, there is a significant decrease compared to the letrozole group in LH level as shown in fig. 3.

When compared to the control group, letrozole alone resulted in a significant increase in FSH level . whereas the addition of vitamin D3 to letrozole there is a significant decrease in FSH level compared to the letrozole group as shown in fig.4.

When compared to the control group, letrozole alone resulted in a significant decrease in progesterone level ,When vit D3 is combined with letrozole, there is a significant increase compared to the letrozole group in progesterone level as shown in fig. 5.

When compared to the control group, letrozole alone resulted in a significant decrease in estrogen level. whereas the addition of vitamin D3 to letrozole there is a significant increase in estrogen level when compared to letrozole alone.as shown in fig.6 .

When compared to the control group, letrozole alone resulted in a significant decrease in AMH level

,When vit D3 is combined with letrozole, there is a significant increase compared to the letrozole group in AMH level as shown in fig.7 .

When compared to the control group, letrozole alone resulted in a significant increase in testosterone level. whereas the addition of vitamin D3 to letrozole there is a significant decrease in testosterone level when compared to letrozole alone.as shown in fig.8 .

When compared to the control group, letrozole alone resulted in a significant decrease in GSH level ,When vit D3 is combined with letrozole, there is a significant increase compared to the letrozole group in GSH level as shown in fig.9 .

When compared to the control group, letrozole alone resulted in a significant increase in MDA level. whereas the addition of vitamin D3 to letrozole there is a significant decrease MDA level when compared to letrozole alone.as shown in fig.10 .

When compared to the control group, letrozole alone resulted in a significant increase in cystic follicle number ,When as D3 is combined with letrozole, there is a significant decrease in cystic follicle number compared to the letrozole group as shown in fig.11 .

Discussion

Letrozole is a third-generation non-steroidal aromatase inhibitor [9]. The studies found that giving female rats consecutive doses of letrozole disrupted their estrous cycle [22] Furthermore, letrozole use causes a disruption in the secretion of hormones from the pituitary gland and the ovaries, resulting in polycystic ovary syndrome due to hypersecretion of androgens in the blood and ovaries [10]. The results of our current study showed a significant increase in the body weight of females treated with letrozole, and this result corresponds with the results of Jahan et al. [23] who noticed a significant increase in the body weight of rats treated with letrozole at a dose of 1 mg / kg orally for a period of 21 days , and agree with the results of some authors [20] Those who recorded a significant increase in the weight of female rats treated with letrozole at a dose of 3 mg / kg orally for a period of 21 days, Perhaps the reason for the high body weight in our current study is that the letrozole treatment caused high blood glucose, which contributes to the development of insulin resistance [11,12]. In the group treated with letrozole, there was

a significant increase in the ovarian weight, and this result corresponds with Mohamed and Fathy, 2021 [20]. Those who observed a significant increase in ovarian weight after administering letrozole 3 mg/kg orally for 21 days, and agree with Ibrahim et al. [24] those who noticed a significant increase in the ovarian weights when using letrozole at a dose of 1 mg / kg orally for a period of 21 days, the results not agree with Kafali et al., who reported non-significant increase in ovarian weight after taking Letrozole at a dosage of 1 mg/kg orally for 21 days. Perhaps the greater weight of the ovaries in our study is related to letrozole's anabolic effects [24]. Letrozole treatment resulted in a significant decrease in glutathione levels, which is consistent with previous research [25]. This result corresponds with a significant increase in lipid peroxidation (malondialdehyde) [22]. The reduction in glutathione and increased malondialdehyde in our current study might be due to an increase in the production of reactive oxygen species caused by letrozole and the development of oxidative stress [20]. The results of the present research also showed a significant increase in the level of luteinizing hormone in the letrozole-treated group, which is similar to previous study [26]. Those who showed a significant increase in luteinizing hormone levels. Perhaps this is because letrozole prevents testosterone from being converted into estradiol, resulting in a reduction in estrogen levels [25]. Thus, a deficiency causes a negative effect on hormone production, resulting in an increased level of luteinizing hormone and an increase in the ratio of luteinizing hormone to follicle-stimulating hormone [27]. The results of the present research showed a significant decrease in progesterone levels in the group treated with letrozole and the results corresponded with previous results [25] Those who reported a significant decrease in progesterone levels in the group treated with letrozole at a dosage of 1 mg/kg orally for 21 days. Because progesterone is one of the hormones produced by the ovaries, it is possible that the cyst in the ovaries is the cause of this decrease [28]. In addition the present study showed a significant decrease in estrogen levels in the group treated with letrozole and the results corresponded with previous work [29] Who observed a decrease in estrogen hormone levels in the group treated with letrozole at a dosage of 5 mg/kg orally for two days. Perhaps this is because letrozole prevents testosterone from being converted into estradiol, resulting in a reduction in estrogen levels

[25]. The results of this study showed a significant increase in testosterone levels in the group treated with letrozole, and the results corresponded with previous results Chandrashekhar (2020) Those who observed an important increase in testosterone levels in the group treated with letrozole at a dosage of 1 mg/kg orally Perhaps this is because letrozole prevents testosterone from being converted into estradiol, resulting in a reduction in estrogen levels [25]. The results of the present study showed a significant increase in the level of anti-Mullerian hormone in the group treated with letrozole, which corresponded to the results of previous research [30], those who observed a significant rise in the level of anti-Mullerian hormone in the group treated with letrozole at a dosage of 1 mg/kg orally for 21 days. It is possible that the increases in anti-Mullerian hormone levels in our present study is due to an increase in androgens in the small antral follicles (Du [30]. The current study also found a significant increase in the number of follicular cysts in the group that received letrozole, The study agreed with Mvondo et al. [31] It is possible that the formation of ovarian cysts is caused by an imbalance in hormonal levels. The non-significant differences in body weight of D3 treated group compared to control group which is similar to the results of Behmanesh et al.[32], who noticed that there was no significant difference in body weight in the D3-treated group compared to the control group, and the reason could be that vit D3 reduce insulin resistance by stimulating the expression of insulin receptor in the body and one of vit D3 deficiency signs is insulin resistance . Beside that no significant changes in D3 group ovarian weight may be due to the role of vit D3 in decreasing insulin resistance by increasing insulin receptor expression in ovarian tissue [32],The non-significant change in glutathione(GSH) and malodialdehyde (MDA) level in D3 treated group compared to control group and GSH significant increase accompanied with MDA significant decrease in the letrozole+vit D3 group compared to letrozole group reflect the fact that of antioxidant effects of vit D3 protecting the body from oxidant effects [21]. With vit D3 treatment no significant changes in the levels of AMH, LH, FSH, progesterone, estrogen and testosterone compared with control (without ovarian cysts) ,the results agreed with Behmanesh et al., [32].and the reason could be that vit D3 have no negative effects on body tissues ,therefore maintaining physiological processes within the

normal condition, as in the control group. The significant reduction in body weight and the non significant changes in ovarian weight with animals treatment by letrozole and vit D3 compared to letrozole group supported by the results of Behmanesh et al.[32]. Who found that vitD3 treatment decreasing body weight with no changes in ovarian weight compared with PCOS group ,this may be due to vit D3 increasing insulin sensitivity by stimulating insulin receptor expression in peripheral tissues and reducing sugar level so lowering insulin resistance. The significant decrease in LH level with letrozole and vit D3 group compared with letrozole group alone similar to results of results El-bahaie et al. [26] who found an arithmetic decrease in treatment of letrozole and vit D3 together and the reason could be caused by vit D3 action in insulin resistance reduction because excess insulin can lead to follicular formation disorder by stimulating androgens secretion from the theca cells this cause increasing blood testosterone level and PCOS occurrence. The reduction in FSH level in the doubled treatment group matches the results by El-bahaie et al. [26] , and the reason is unknown till now ,in addition to that the reason of significant increase in progesterone level may be due to the crucial role of vit D3 in production of progesterone in the ovary [32].while the significant increase in estrogen level which is similar to the results of El-bahaie et al. [26], possibly caused by vit D3 improvement to aromatase activity during corpus luteum development in rather with PCOS and vit D3 effect in decreasing insulin resistance could be the cause of significant decrease in testosterone level in the letrozole and vit D3 group compared to letrozole group alone with unknown reason for the mathematical decrease in AMH level in the letrozole and vit D3 group compared to the letrozole group alone. Histopathology results in our present study showed a significant decrease in the number of ovarian cysts in the letrozole plus D3 group compared to the letrozole alone group. It is possible that the reason is the effect of vitamin D3 and its effective role in reducing insulin resistance, which causes an increase in the production of androgens and testosterone and thus the occurrence of polycystic ovaries, but vitamin D3 reduced the polycystic condition, which was reflected in the decrease in the number of cysts.

Conclusions

Letrozole had an adverse effect on body weight and ovarian weight, resulting in a increase in both weights. In addition, the use of vit D3 shown an decreasing in body weight and MDA level and increasing GSH level by lowering the adverse effects of letrozole. In addition, as compared to the letrozole group, vitamin D3 reduced the number of ovarian cysts.

Acknowledgment

We would like to thank the college of veterinary medicine for providing the lab facilities

Conflicts of interest

The author of this manuscript stated there is no conflict of interest regarding the writing process or data analysis.

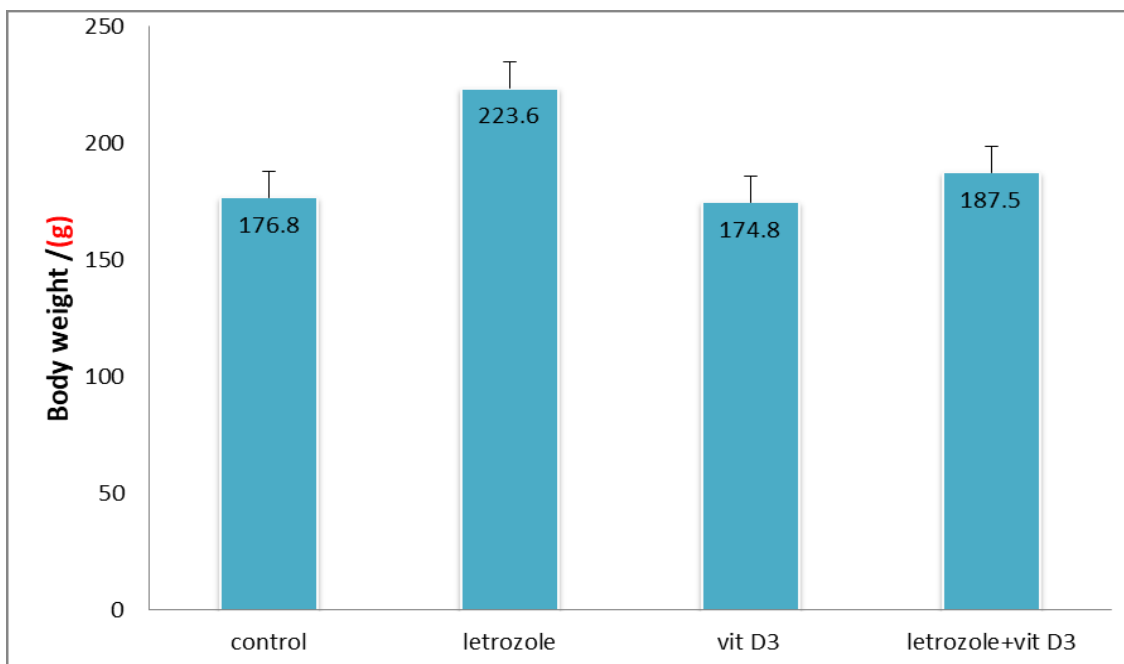


Fig. 1. The effect of treatment with letrozole, vit D3, letrozole and vit D3 on animal weights (mean \pm standard error). Similar letters indicate no significant differences between groups at ($P \geq 0.05$), while different letters indicate a significant differences between groups at ($P \leq 0.05$).

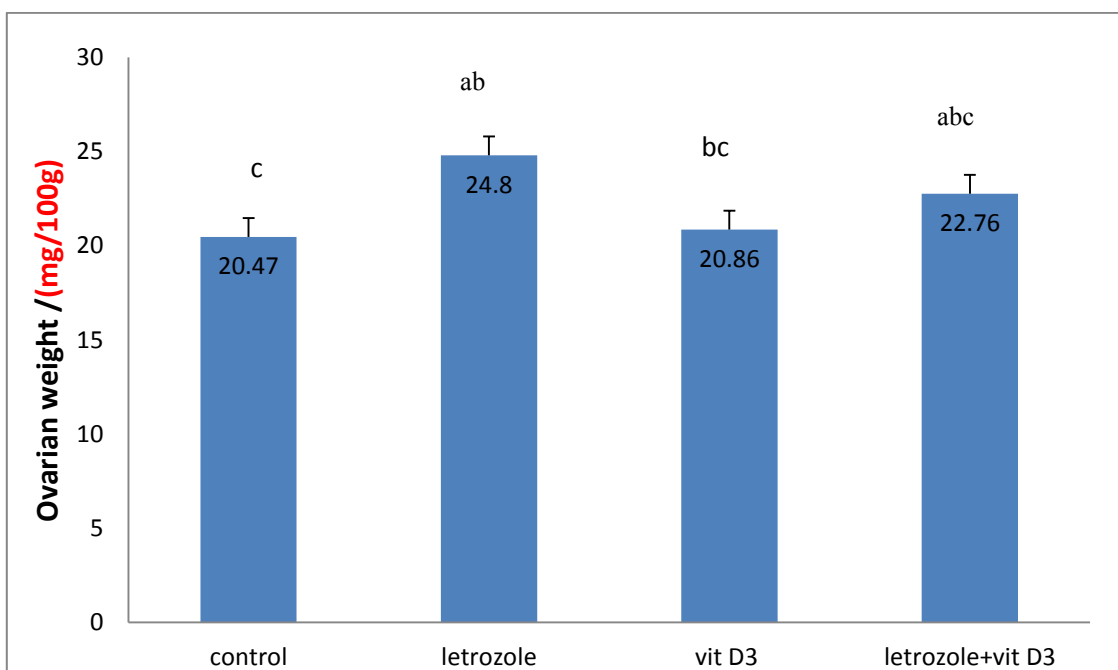


Fig. 2. The effect of treatment with letrozole, vit D3, letrozole and vit D3 on ovarian weights (mean \pm standard error). Similar letters indicate no significant differences between groups at ($P \geq 0.05$), while different letters indicate a significant difference between groups at ($P \leq 0.05$).

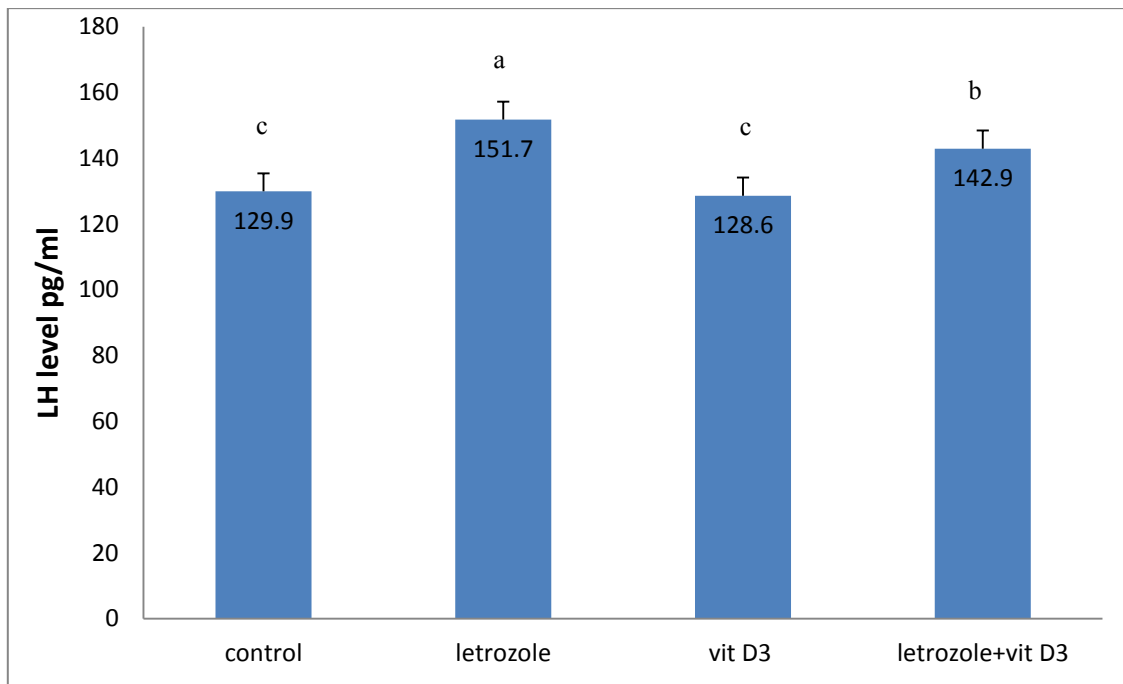


Fig. 3. The effect of treatment with letrozole, vit D3, letrozole and vit D3 on Luteinizing hormone (LH) level (mean \pm standard error). Similar letters indicate no significant differences between groups at ($P > 0.05$), while different letters indicate a significant differences between groups at ($P < 0.05$).

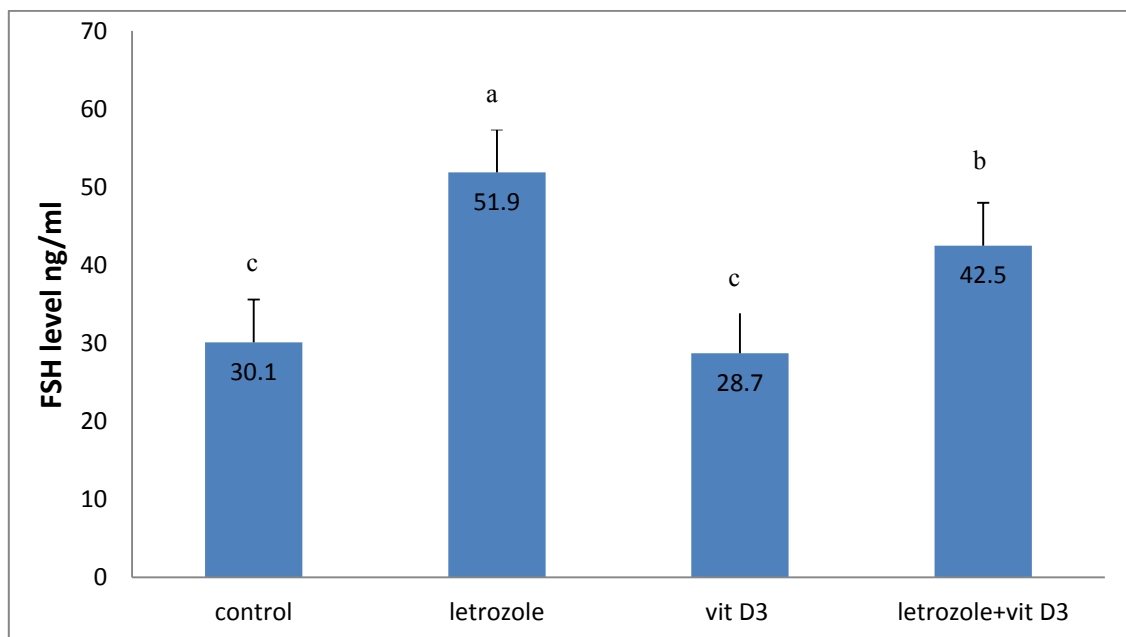


Fig. 4. The effect of treatment with letrozole, vit D3, letrozole and vit D3 on Follicle stimulating hormone (FSH) level (mean \pm standard error). Similar letters indicate no significant differences between groups at ($P \geq 0.05$), while different letters indicate a significant differences between groups at ($P \leq 0.05$).

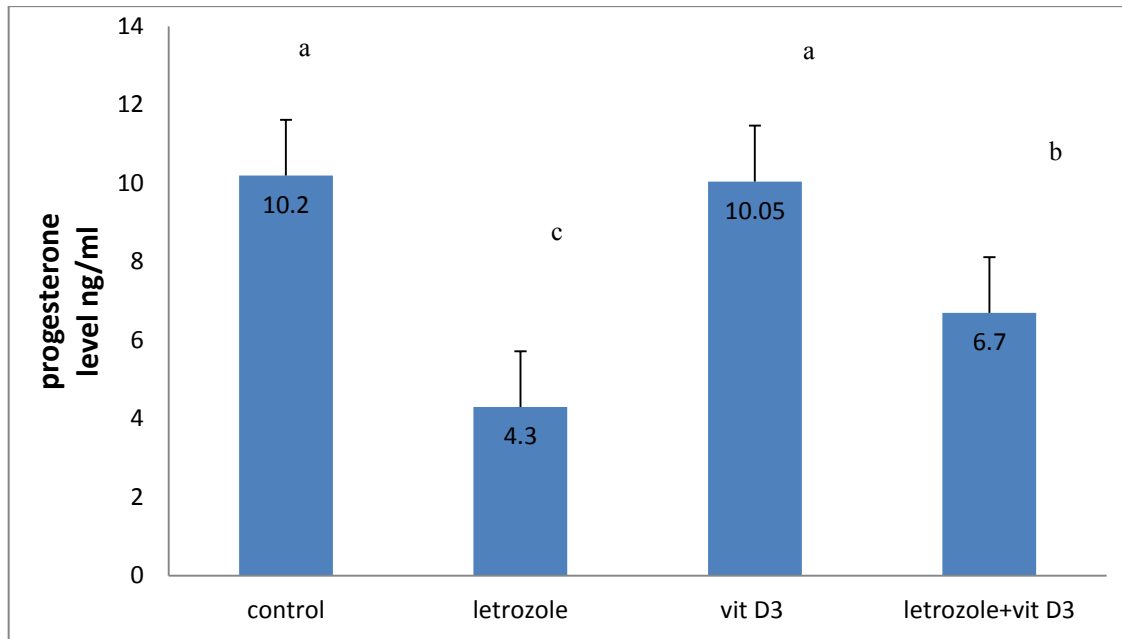


Fig. 5. The effect of treatment with letrozole, vit D3, letrozole and vit D3 on progesterone level (mean \pm standard error). Similar letters indicate no significant differences between groups at ($P \geq 0.05$), while different letters indicate a significant differences between groups at ($P \leq 0.05$).

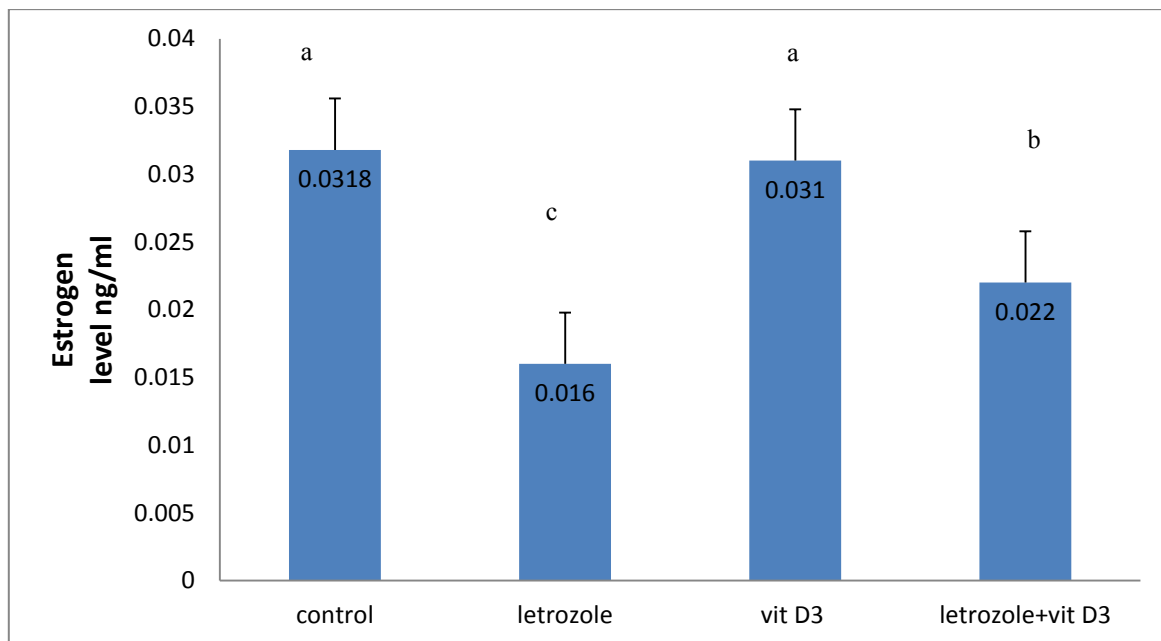


Fig. 6. The effect of treatment with letrozole, vit D3, letrozole and vit D3 on progesterone level (mean \pm standard error). Similar letters indicate no significant differences between groups at ($P \geq 0.05$), while different letters indicate a significant differences between groups at ($P \leq 0.05$).

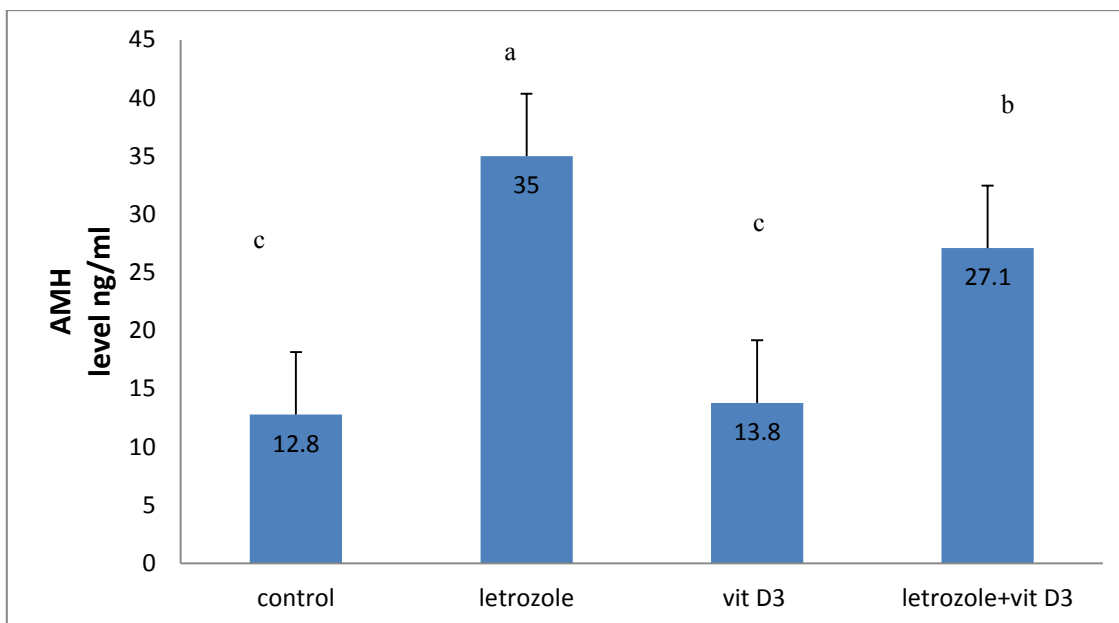


Fig. 7. The effect of treatment with letrozole, vit D3, letrozole and vit D3 on Anti-müllerian hormone (AMH) level (mean \pm standard error). Similar letters indicate no significant differences between groups at ($P \geq 0.05$), while different letters indicate a significant differences between groups at ($P \leq 0.05$).as shown in fig.8 .

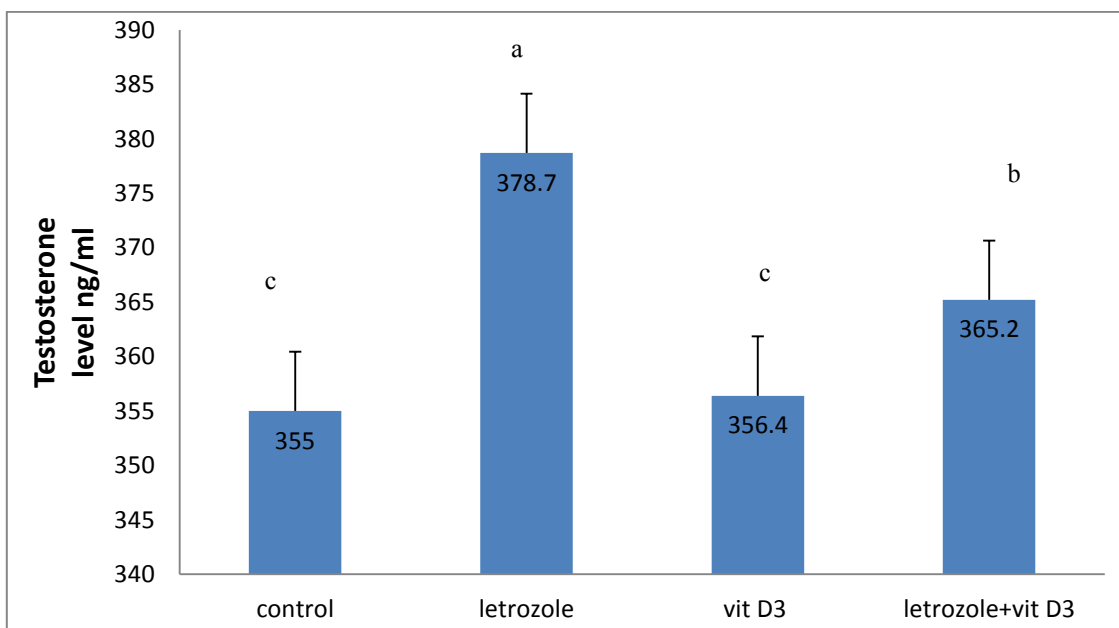


Fig. 8. The effect of treatment with letrozole, vit D3, letrozole and vit D3 on testosterone level (mean \pm standard error). Similar letters indicate no significant differences between groups at ($P \geq 0.05$), while different letters indicate a significant differences between groups at ($P \leq 0.05$).

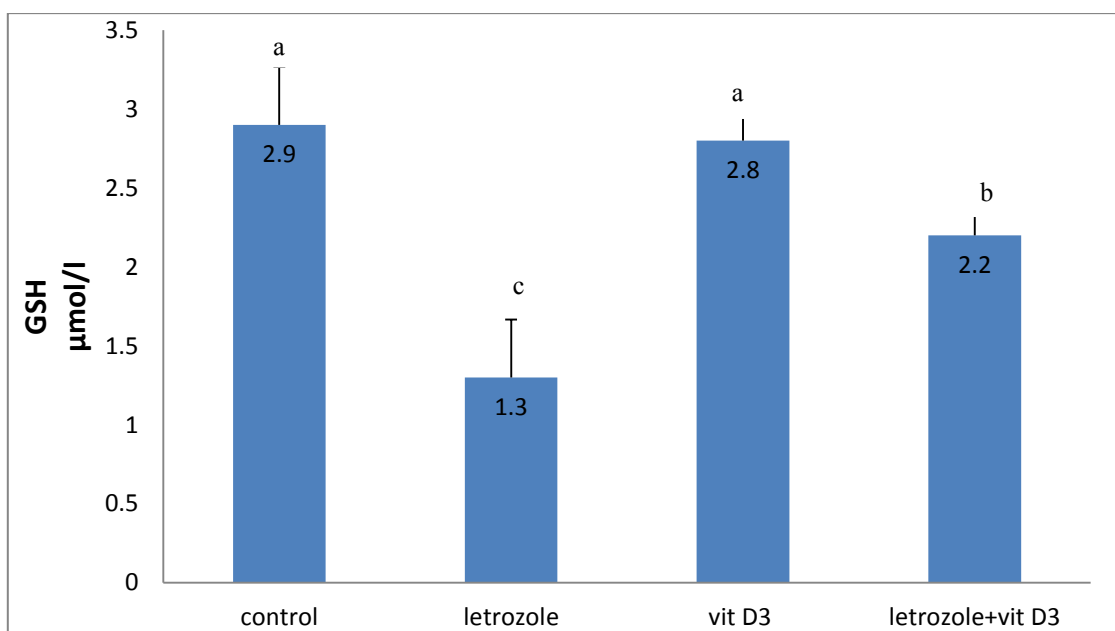


Fig. 9. The effect of treatment with letrozole, vit D3, letrozole and vit D3 on GSH level (mean \pm standard error). Similar letters indicate no significant differences between groups at ($P \geq 0.05$), while different letters indicate a significant differences between groups at ($P \leq 0.05$).

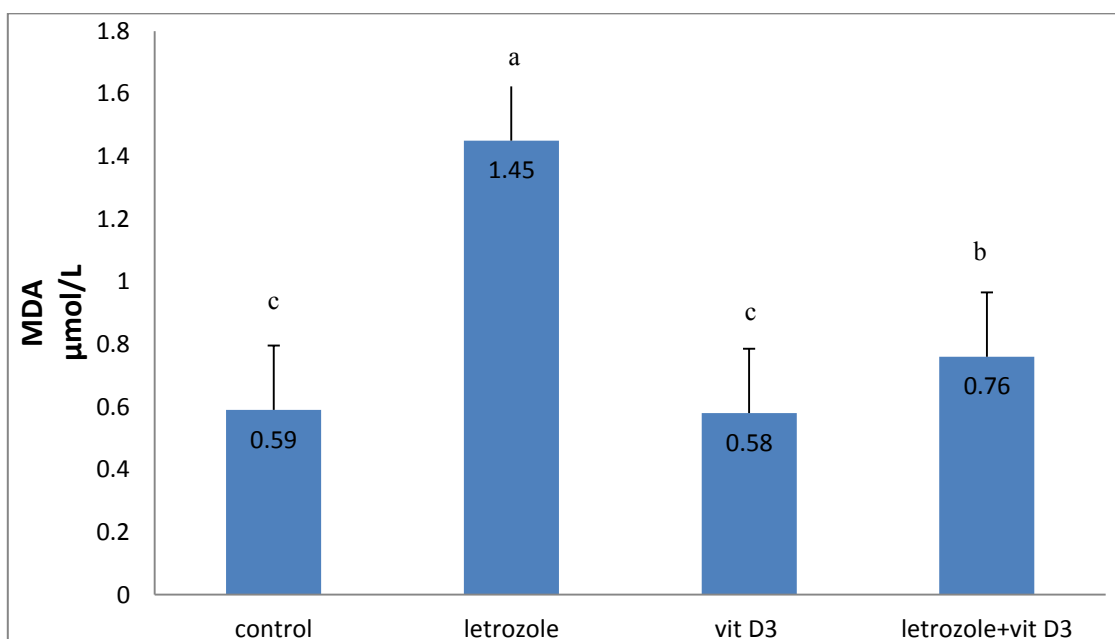


Fig. 10. The effect of treatment with letrozole, vit D3, letrozole and vit D3 on MDA level (mean \pm standard error). Similar letters indicate no significant differences between groups at ($P \geq 0.05$), while different letters indicate a significant differences between groups at ($P \leq 0.05$).

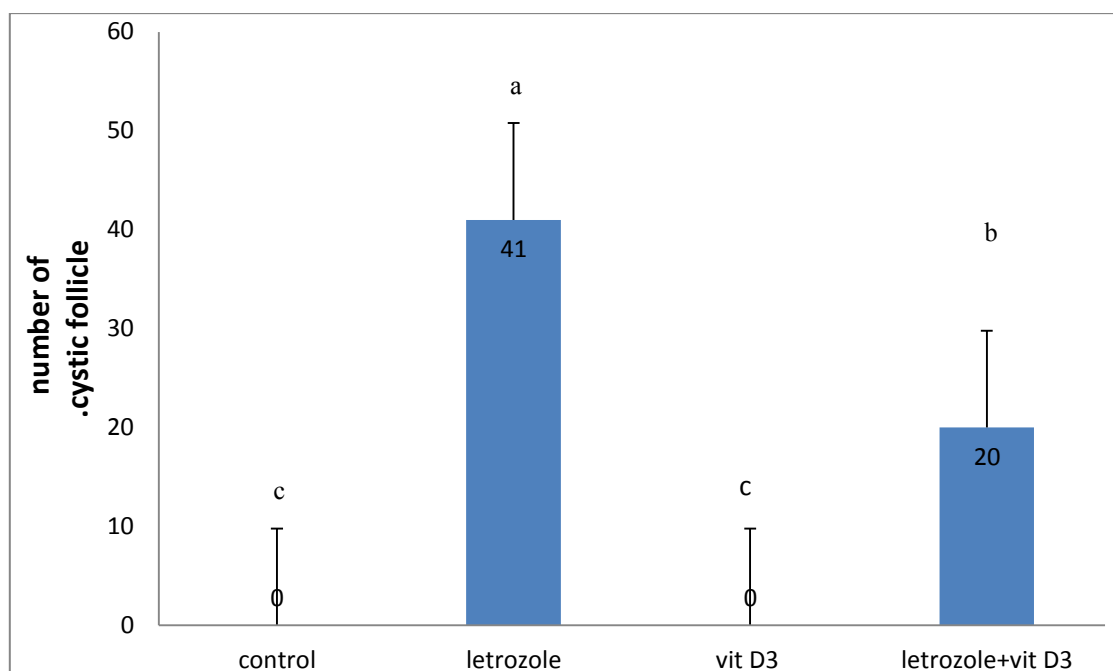


Fig. 11. The effect of treatment with letrozole, vit D3, letrozole and vit D3 on number of cystic follicles (mean \pm standard error). Similar letters indicate no significant differences between groups at ($P \geq 0.05$), while different letters indicate a significant differences between groups at ($P \leq 0.05$).

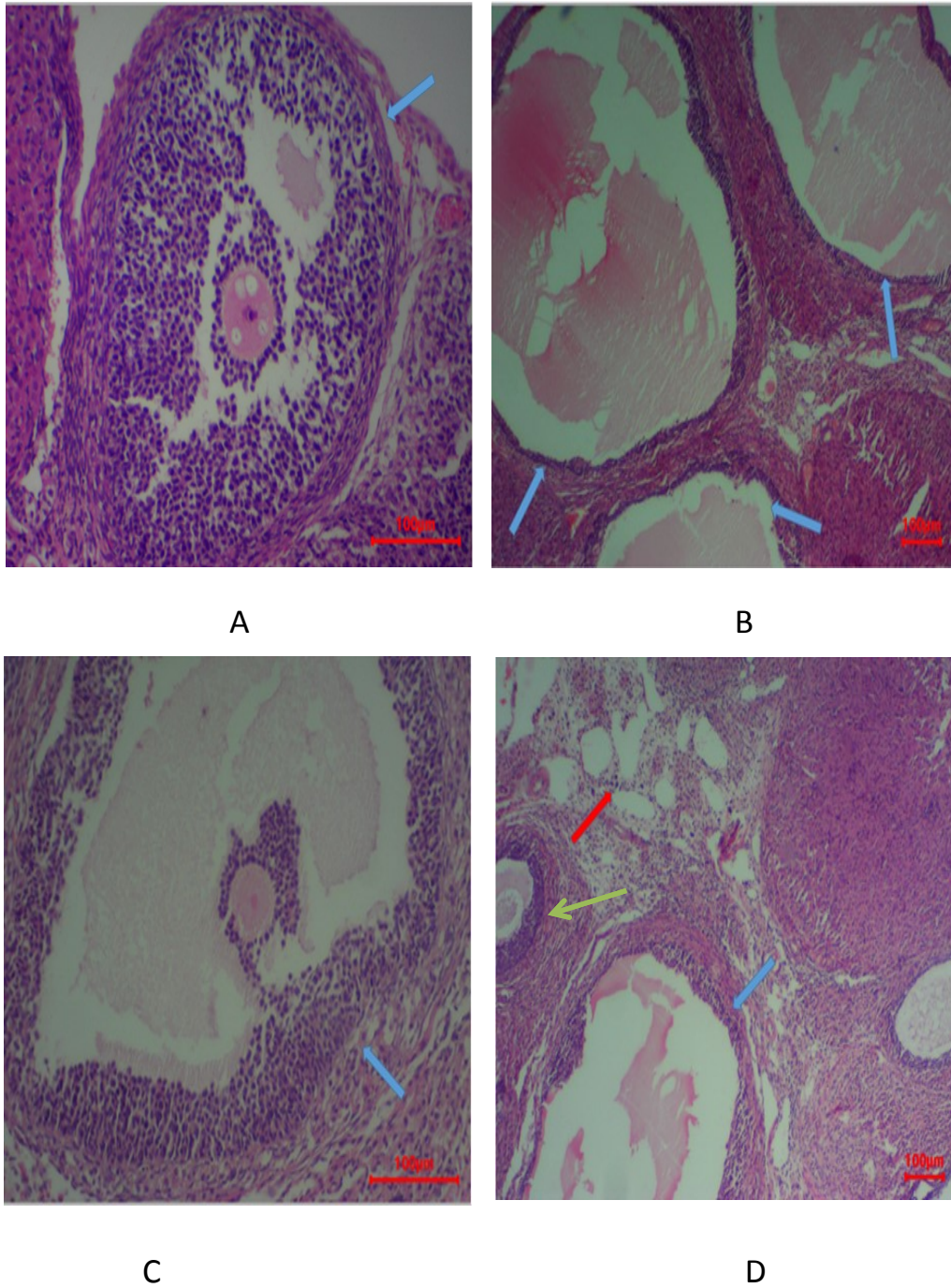


Fig.12. (A) ovaries from the control group showed normal mature follicle (H&E, X100). (B) ovaries from letrozole group showed multiple cystic follicles (H&E, X40).(C) ovaries from the vit D3 group showed normal mature follicle (H&E, X100).(D) ovaries from the letrozole +vit D3 group showed two type of cystic follicle and normal mature follicle

References

- Johnstone, E.B., Mitchell, P.R., Rebecca, N.D., Barbara, S.R., Carolyne, A.A., Renee, R.P. and Marcelle, I.C. The polycystic ovary post-Rotterdam: a common, age-dependent finding in ovulatory women without metabolic significance. *The Journal of Clinical Endocrinology & Metabolism*, **95**(11), 4965-4972 (2010).
- Teede, H.J., Marie L.M., Michael, F.C., Anuja, D.H., Lisa, M.T. and Robert, J.N. Recommendations from the international evidence-based guideline for the assessment and management of polycystic ovary syndrome. *Human Reproduction*, **33** (9), 1602-1618 (2018).
- Teede, H.A. and Lisa, M. Polycystic ovary syndrome: a complex condition with psychological, reproductive and metabolic manifestations that impacts on health across the lifespan. *BMC Medicine*, **8**(1), 1-10(2010).
- Valkenburg, O.R., Regine, S.T., Huberdina, P.S., Geesje, M.D., Bart, C.F., Egbertine, H.W. and Joop, S.L. A more atherogenic serum lipoprotein profile is present in women with polycystic ovary syndrome: a case-control study. *The Journal of Clinical Endocrinology & Metabolism*, **93**, (2), 470-476 (2008).
- Garverick, H.A. Ovarian follicular cysts in dairy cows. *Journal of Dairy Science*, **80**(5), 995-1004(1997).
- Peter, A.T. An update on cystic ovarian degeneration in cattle. *Reproduction in Domestic Animals*, **39**(1), 1-7(2004).
- Braw, T.R. and Roth, Z. Ovarian cysts in high-yielding dairy cows. *Theriogenology*, **72**(5), 690-698(2009).
- Simensen, E., Olav, Ø., Knut, E.B., Camilla, K.L. and Geir, N. Housing system and herd size interactions in Norwegian dairy herds; associations with performance and disease incidence. *Acta Veterinaria Scandinavica*, **52**, 1-9(2010).
- Fisher, C.R., Kathy, H.G., Albert F.P. and Evan, R.S. Characterization of mice deficient in aromatase (ArKO) because of targeted disruption of the cyp19 gene. *Proceedings of the National Academy of Sciences*, **95**(12), 6965-6970(1998).
- Kafali, H., Mehmet, I., Ilyas, O. and Nurettin, D. Letrozole-induced polycystic ovaries in the rat: a new model for cystic ovarian disease. *Archives of Medical Research*, **35**(2), 103-108(2004).
- Desai, B.N., Radha, H.M. and Laxmipriya P.N. Aloe barbadensis Mill. formulation restores lipid profile to normal in a letrozole-induced polycystic ovarian syndrome rat model. *Pharmacognosy Research*, **4**(2), 109(2012).
- Maharjan, R.P. and Laxmipriya, N. Effect of Aloe barbadensis Mill. formulation on Letrozole induced polycystic ovarian syndrome rat model. *Journal of Ayurveda and Integrative Medicine*, **1**(4), 273(2010).
- Deeb, K.K., Donald, L.T. and Candace, S.J. Vitamin D signalling pathways in cancer: potential for anticancer therapeutics. *Nature Reviews Cancer*, **7**(9), 684-700(2007).
- Bikle, D.D. Vitamin D metabolism, mechanism of action, and clinical applications. *Chemistry & Biology*, **21**(3), 319-329 (2014).
- Schuster, I. Cytochromes P450 are essential players in the vitamin D signaling system. *Biochimica et Biophysica Acta (BBA)-Proteins and Proteomics*, **1814**(1), 186-199(2011).
- Lieben, L., Geert, C. and Ritsuko, M. Calcemic actions of vitamin D: effects on the intestine, kidney and bone. *Best Practice & Research Clinical Endocrinology & Metabolism*, **25** (4), 561-572(2011).
- Teegarden, D. and Shawn, S.D. Vitamin D: emerging new roles in insulin sensitivity. *Nutrition Research Reviews*, **22**(1), 82-92(2009).
- Yoshizawa, T., Yuki, H., Yoshikatsu, U., Shu, T., Keisuke, S., Yuko, Y. and Toru, K. Mice lacking the vitamin D receptor exhibit impaired bone formation, uterine hypoplasia and growth retardation after weaning. *Nature Genetics*, **16**(4), 391-396(1997).
- Irani, M., Howard, M., David, B. and Zahe, M. Vitamin D increases serum levels of the soluble receptor for advanced glycation end products in women with PCOS. *The Journal of Clinical Endocrinology & Metabolism*, **99**, (5), E886-E890 (2014).
- Mohamed, A.M. and Shaymaa, F.M. The possible effect of flaxseed extract on letrozole-induced polycystic ovary rat model: Correlative histological and functional study. *Al-Azhar Medical Journal*, **50** (4), 3051-3096(2021).
- Helal, B.A., Ghada, M.I., Salma, E.N. and Abeer, A.A. Effect of vitamin D on experimental model of polycystic ovary syndrome in female rats. *Life Sciences*, **283**, 119558(2021).
- Chandrashekhar, R., Bakshi, V., Jagruthi J., Nelavelli L.B. and Bhavani, B. Protective and therapeutic effect of protocatechuic acid in assessment of letrozole-induced polycystic ovary syndrome in rats. *Asian Pacific Journal of Reproduction*, **9**(5), 230-238(2020).
- Jahan, S., Faryal, M., Suhail, R., Anam, M., Qurat U.A., Hizb, U., Tayyaba, A., Ghazala. S. and Ali, A. Ameliorative effects of rutin against metabolic, biochemical and hormonal disturbances in polycystic ovary syndrome in rats. *Journal of Ovarian Research*, **9**, 1-9(2016).
- Ibrahim, Y.F., Mohammed, A., Walaa, Y.A., Nisreen, D.T., Khaled, T., AbdelRahman, H. and Haitham A.B. Diacerein ameliorates letrozole-induced polycystic ovarian syndrome in rats. *Biomedicine & Pharmacotherapy*, **149**, 112870 (2022).
- Reddy, P.S, Nazia, B., Sumith, M. and Vasudha, B. Beneficial effect of Curcumin in Letrozole induced polycystic ovary syndrome. *Asian Pacific Journal of Reproduction*, **5**(2), 116-122(2016).

26. El-Bahaie, E.M. and Moursi, S. F.S. Reversal of Haemostatic Changes in Letrozole-Induced PCOS Rat Model with Vitamin D Supplementation. *The Medical Journal of Cairo University*, **87**, 1753-1767(2019).
27. Bednarska, S. and Agnieszka, S. The pathogenesis and treatment of polycystic ovary syndrome: What's new?. *Advances in Clinical and Experimental Medicine*, **26**(2), 359-367 (2017).
28. Pineda, M.H. Female reproductive system. *McDonald's Veterinary Endocrinology and Reproduction* Ed. 5: 283-340 (2003).
29. Kilic, O.T., Mustafa, K. and Sems, A. Comparison of the effects of letrozole and clomiphene citrate on ovarian follicles, endometrium, and hormone levels in the rat. *Fertility and Sterility*, **80**(6), 1330-1332(2003).
30. Du, D.F., Xue, L.L., Fang, F. and Mei, R.D. Expression of anti-Müllerian hormone in letrozole rat model of polycystic ovary syndrome. *Gynecological Endocrinology*, **30**(12), 885-889(2014).
31. Mvondo, M.A., Flavie I.M., Charline F.A. and Dieudonné, M. The leaf aqueous extract of *Myrianthus arboreus* P. Beauv.(Cecropiaceae) improved letrozole-induced polycystic ovarian syndrome associated conditions and infertility in female Wistar rats. *BMC Complementary Medicine and Therapies*, **20**, 1-13(2020).
32. Behmanesh, N., Ali, A., Hojjatollah, N.C. and Alireza, A. Effects of vitamin D supplementation on follicular development, gonadotropins and sex hormone concentrations, and insulin resistance in induced polycystic ovary syndrome. *Turkish journal of Obstetrics and Gynecology*, **16**(3), 143(2019).
33. Abdul-Wahab, F.K. and Nada, N.A. Effects of vitamin D3 on methotrexate-induced jejunum damage in rats. *J. Pharm. Sci.*, **29**(1), 260-267(2020).

تأثير فيتامين D3 على فسلجة مبايض الجرذان المستحدث فيها تكيس المبايض

عبدالرزاق عماد عبدالرزاق و فدوى خالد توفيق

فرع الفسلجة والكيمياء الحياتية والأدوية - كلية الطب البيطري - جامعة الموصل - الموصل - العراق.

كان هدف هذا البحث دراسة التغيرات الفسيولوجية في مبايض الجرذان التي تم استحداث متلازمة تكيس المبايض فيها بواسطة اللتروزول وتفصي التأثير الايجابي لفيتامين D3 على هذه المتلازمة . تم استخدام اربع وعشرون انثى من الجرذان البيض قسمت الى اربعة مجاميع (مجموعة السيطرة ، مجموعة اللتروزول ،مجموعة فيتامين D3 ومجموعة اللتروزول وفيتامين D3 معاً) .تم اعطاء الجرع عن طريق الفم ولمدة 21 يوماً. اظهرت نتائج الدراسة الحالية ارتفاعاً معنوياً في وزن الجسم والمبايض في المجموعة المعاملة باللتروزول مقارنة مع مجموعة السيطرة بينما كانت المجموعة المعاملة باللتروزول وفيتامين D3 معاً انخفاضاً معنوياً في وزن الجسم مقارنة مع مجموعة اللتروزول بينما لم يكن هناك تغير ملحوظ في وزن المبايض . اظهرت المجموعة المعاملة باللتروزول الكبر عدد من الاكياس المبيضية مقارنة مع مجموعة السيطرة . في حين ان المجموعة المعاملة باللتروزول وفيتامين D3 اظهرت انخفاضاً ملحوظاً في الاكياس المبيضية مقارنة مع مجموعة اللتروزول لوحده ، وكان هناك ايضاً تحسناً ملحوظاً في كل من مستوى الكلوتاتيون ،المالوندايالديهيد ، الهرمون اللوتيني، الهرمون المحفز للجريبات، الهرمون المضاد للمولر، الاستروجين ، البروجستيرون والتستوستيرون .استنتجت هذه الدراسة ان اللتروزول لديه تأثيرات سلبية تؤدي الى زيادة في وزن الجسم والمبايض وان استخدام فيتامين D3 له تأثير بسيط في تخفيف ومعالجة الاعراض السلبية لللتروزول

الكلمات الدالة : متلازمة تكيس المبايض ،اللتروزول، فيتامين D3 ، جرذان