

THE PROTECTIVE ROLE OF ERDOSTEINE AND EXOGENOUS REDUCED NICOTINAMIDE ADENINE DINUCLEOTIDE ON ACUTE ALUMINIUM PHOSPHIDE INDUCED HEPATOTOXICITY IN ADULT ALBINO RATS

Wafaa S. A. Elbadawy^a, Eslam S. Metwally^a, Maha M. Mokhtar^a, Nagah E.M. Ali^a

^a Forensic Medicine and Clinical Toxicology Department, Faculty of Medicine, Benha University, Benha 13518, Egypt

Corresponding Author: Maha M. Mokhtar

Email: maha.mahmoud@fmed.bu.edu.eg

ABSTRACT

Background: Aluminum phosphide (ALP) is a fumigant used recently for suicide; Liver failure is the common reason for death. Aim of the work The current work was done to assess the effects of erdosteine and exogenous (NADPH) against (ALP) acute hepatotoxicity. Serum levels of hepatic enzymes (ALT, AST) and oxidative stress parameters (MDA, CAT, and GSH) in liver tissue were measured. **Materials and Methods:** 54 male adult albino rats were divided into 7 groups (each 6 rats); 4 control groups (negative, solvent, erdosteine, NADPH), then 3 test groups; AIP group (12 mg/kg orally), AIP (12 mg/kg orally) + erdosteine (150 mg/kg orally) group, AIP (12 mg/kg orally) + NADPH (16 mg/kg intravenously) group. Blood samples were collected after 8 hours, the abdominal cavity was incised to remove the liver for histopathological examination and to measure the oxidative stress parameters in liver tissue. **Results:** Poisoning with AIP can cause elevation of serum (ALT, AST) with a marked increase in (MDA) and a decrease in catalase enzyme level and GSH. Combined administration of erdosteine with AIP improved serum levels of ALT and AST and improved the levels of CAT and GSH, besides decreasing the MDA level. Combined administration of NADPH with AIP markedly decreased the serum levels of ALT and AST, a marked decrease in MDA level, and a marked increase in the CAT and GSH levels. Histopathological examination of liver tissues confirmed the results. **Conclusion:** The administration of erdosteine and exogenous NADPH may be helpful in improving ALP hepatotoxicity.

Keywords: Aluminium phosphide, Erdosteine, NADPH, hepatotoxicity.

1. INTRODUCTION

Aluminium phosphide (AIP) is a well-known pesticide that is used worldwide to protect food grains from insects and rodents, as it's cheap and highly effective (*Singh et al., 2014*).

Each AIP tablet contains only 56% AIP and 44% inert ingredients (usually aluminium carbonate or carbamate) that prevent the decomposition of the tablet. On exposure to moisture, each 3 gm tablet releases 1 gm of phosphine, leaving a nontoxic greyish residue of aluminium hydroxide behind (*Moghadamnia, 2012*).

Recently, AIP poisoning has become a leading problem in Egypt as the incidence of toxicity is increasing (*Hasabo, 2015*). It

possesses a high mortality rate, usually due to multi-organ failure, even when they are in the intensive care unit as there is no available antidote (*Farzaneh et al., 2018*).

Most deaths occur within the first 12–24 hours after exposure due to cardiac dysrhythmia (*Sciuto et al., 2016*). Patients who pass death from cardiac failure die commonly later from acute hepatic failure (*Nath et al., 2011*).

The mitochondrion is the main target organelle affected by AIP toxicity in the cell, so inhibiting its activity is considered the key to AIP toxic effects (*Solgi et al., 2015*). Phosphine is the active pesticide component of AIP, it initiates a nucleophilic attack that causes a reduction of the vital enzymes such as catalase and peroxidase which are

metalloenzymes, decreasing their activity in scavenging peroxide radicals (*Anand et al., 2011*).

Phosphine also causes a reduction of the ferric ion to the ferrous ion in the cytochrome C oxidase. In the presence of hydrogen peroxide (H_2O_2), ferrous ion generates the reactive hydroxyl free radical (OH^\cdot), which is an important reactant in the Fenton reaction and initiator of lipid peroxidation besides the formation of highly unstable superoxide anions ($O_2^{\cdot-}$) (*Sciuto et al., 2016*).

Additionally, the position of the cytochrome C oxidase enzyme in the electron transport chain protects the cell from the potentially dangerous electrons by transferring them to the final electron acceptor, the molecular oxygen, to generate water. So, its inhibition results in the production of uncontrolled amounts of reactive oxygen species (*Nath et al., 2011*).

Overproduction of peroxide radicals with consumption of the mitochondrial antioxidant defense as catalase enzyme and reduced glutathione results in lipid peroxidation, protein denaturation of the cell membrane, and DNA damage with activation of apoptotic pathways and subsequent cell death eventually (*Mehrpour et al., 2012; Solgi, 2015; Karimani et al., 2018*).

Erdosteine is a thiol-based drug that is used as a mucolytic in the management of chronic pulmonary diseases (*Cazzola et al., 2019*). So, it has been widely used recently in experimental research for its antioxidant activity, including studies done on hepatotoxicity (*Moretti, 2007*).

Reduced nicotinamide adenine dinucleotide phosphate (NADPH) is a fundamental molecule in cellular redox homeostasis, it potentiates cellular defense against oxidative stress (*Ogasawara et al., 2009*). In the liver, NADPH holds a key position in the detoxification processes and metabolism of drugs, toxins, and some sex hormones. This action is mediated by the cytochrome p450 enzyme (*Zhu et al., 2019*).

So, the present study aimed to assess the possible protective role of erdosteine and

exogenous NADPH on AIP-induced hepatic injury in adult albino rats.

2. MATERIALS AND METHODS

I-Chemicals:

AIP was obtained from a local shop in Benha city, in the form of 3 gm tablets (56% concentration, Excel Crop Care Ltd., India). Erdosteine capsules (Mucotec, 300mg) were obtained from Global Nabi Pharmaceuticals Company, Egypt). NADPH Tetrasodium salt white powder, with a purity of 97%, was obtained from Sigma Chemical Company. Other chemicals used were of the highest analytical grade.

II- Route of administration:

Both AIP and erdosteine were given orally by gavage tube, while NADPH was given intravenously in the tail vein using an insulin syringe.

III-Animals:

Adult Male albino rats (200–250 g) were used. All animal procedures were done according to the Ethics Committee of Scientific Research, Faculty of Medicine, Benha University (code: MS-9-4-2020). The current experiment was done in the animal bread house of the faculty of veterinary medicine, Benha University.

IV- Study design:

Fifty-four rats were divided into seven groups, as follows:

- **Group I** (negative control group- 6 rats): rats were left without intervention to measure the basic parameters while having free access to food and distilled water.
- **Group II** (solvent control groups- 18 rats);
Subgroup IIa (normal saline control group- 6 rats) received a single oral dose of normal saline by gavage tube.
Subgroup IIb (modified saline control group- 6 rats) was treated with a single intravenous dose of (1 ml of modified saline solution) with PH:8 (normal saline +10% NaOH) (*Zhu et al., 2019*).
Subgroup IIc (corn oil control group- 6 rats) received a single oral dose of (1 cc of

corn oil) by a gavage tube (Ahmadi et al., 2018).

- **Group III** (erdosteine-treated control group- 6 rats) received a single dose of erdosteine 150 mg/kg dissolved in normal saline 0.9% orally by gavage tube (Demiralay et al., 2006).
- **Group IV** (NADPH treated control group- 6 rats): received a single intravenous dose of NADPH 16 mg/kg dissolved in 1ml of modified saline with pH: 8 (Zhu et al., 2019).
- **Group V** (AIP treated group- 6 rats) received a single acute dose of AIP 12 mg/kg orally by gavage tube (determined according to the pilot study done before the current experiment). The tablets were freshly powdered and suspended in corn oil.
- **Group VI** (AIP + erdosteine treated group- 6 rats) received a single dose of AIP 12 mg/kg orally by gavage tube, followed by a single dose of erdosteine 150 mg/kg orally, 1h after the AIP dose.
- **Group VII** (AIP + NADPH treated group- 6 rats) received a single dose of AIP 12 mg/kg orally by gavage tube, followed by a single dose of NADPH 16 mg/kg, dissolved in 1 ml of modified saline with pH: 8, IV, 1 hour after AIP administration. All studied groups were exposed to fasting after AIP ingestion. The duration of the study was 24 hours.

The mortality started to appear in the AIP group after 8 hours and live rats in the same group were in a morbid state. So, live rats from the AIP group and rats from all other groups were sacrificed by neck dislocation to take samples.

V- Collection of samples:

Blood samples (4-5 ml) were collected from the retro-orbital plexus. The liver of each rat was removed by opening the abdominal cavity then cleaned and divided into two parts; one part was placed in 10% formalin for histopathological examination and the 2nd part was frozen at -80°C immediately for biochemical measurement of oxidative stress parameters.

VI- Studied parameters:

a- Biochemical analysis of serum hepatic enzymes:

Collected blood samples were centrifuged at 3000 rpm for 10 min at 4°C, the clear non-hemolyzed supernatant serum was quickly removed and used for estimation of serum ALT and AST enzymes. The examined parameters were analyzed in the central lab of the Faculty of Veterinary Medicine, Benha University.

ALT and AST levels were calculated spectrophotometrically using the commercial test of (ALT, AST), biosystem lab (Biosystems S.A. company), Spain.

b- Estimation of oxidative stress parameters in liver tissue

Liver tissue preparation:

The liver tissue of each animal was taken and rapidly frozen at -80°C until analyzed. Then, the liver tissue was homogenized in phosphate-buffered saline (1ml for 250 mg of each liver) by a glass homogenizer then centrifuged by cooling centrifugal at 5000 rpm for 15 minutes at 4°C, using a high-speed cooling centrifuge (Type 3-30K, Sigma, Osterode-am-Harz, Germany). After that, the supernatant was recentrifuged till obtaining clear supernatant that was kept at -20°C till analysis.

Malondialdehyde (MDA) level in liver tissue (nmol/gm) was determined according to the protocol of the rat MDA ELISA Kit (CUSABIO BIOTECH CO., Ltd., China). Determination of catalase (CAT) enzyme level (ng/ml) in liver tissue was done using rat Catalase ELISA kit. Cat No. MBS2600683 (MyBioSource, Inc., Southern California, San Diego, USA). Determination of reduced glutathione level (nmol/gm) in liver tissue: Kits: Rat Glutathione (GSH) ELISA Kit. Catalog No. CSB-E12144r (CUSABIO BIOTECH CO., Ltd., China). The concentration of MDA, CAT, and GSH in the samples were determined by

comparing the optical density of the samples to the standard curve.

c- Histopathological examination of the heart:

Histopathological examination of collected liver samples was done at the Pathology Department, Faculty of Medicine, Benha University, using Haematoxylin and Eosin (H&E) and examined by a light microscope (OLYMPUS, Japan).

VII- Statistical analysis:

The data were analyzed using the SPSS program, (Spss Inc, Chicago, ILL Company) version 26. Descriptive statistics were calculated in the form of mean and standard deviation (SD) for quantitative data. The significance of the difference between the studied groups was tested using one of the following tests: the ANOVA test (analysis of variance), to compare the mean of more than two groups, and the Post hoc test (Least significant difference, LSD) for intergroup comparisons.

3. RESULTS

Mortality was observed only in AIP group (2 rats) before scarification and other rats in the same group were in morbid state, rats in other groups were still in good condition before scarification.

As regards the control groups (negative control), (solvent control), (erdosteine control), and (NADPH control), they showed non-significant differences ($p > 0.05$) as regards serum levels of ALT, AST, and oxidative stress parameters. So, the mean of all control groups was chosen as a representative group for the four control groups to be compared with the results of the remaining groups.

I- Serum liver enzymes:

There was a highly significant ($p < 0.001$) increase in ALT level in the AIP group when compared with the control group. Test group VI (AIP+ erdosteine) showed a reduction in ALT level, while test group VII (AIP+ NADPH) showed a marked reduction in ALT level when compared with group V (AIP treated group). No significant difference was found between test group VI and test group VII, (**Table 1**).

In the same way, there was a more significant ($p < 0.001$) increase in AST level in the AIP group when compared with the control group. Test group VI (AIP +erdosteine) caused a reduction in AST level, while test group VII (AIP+ NADPH) showed a marked reduction in AST level when compared with group V (AIP treated group). No significant difference was found between test group VI and test group VII, (**Table 2**).

Table (1): Comparison between the studied groups regarding serum ALT level (U/L):

ALT	Mean	± SD	Range	ANOVA	P-value
Control group	32.47	2.69	26-38	118.87	<0.001**
Group V (AIP)	127.40 ^a	34.399	94-165		
Group VI (AIP +erdosteine)	78.00 ^{ab}	12.182	61-92		
Group VII (AIP+ NADPH)	65.17 ^{abd}	12.189	51-87		

** : highly significant. **a** highly significant difference when compared with the control group at $p < 0.001$. **b** highly significant difference when compared with the AIP group (V) at $p < 0.001$. **d** indicates a non-significant difference when compared with group VI (AIP+ erdosteine), $p > 0.05$.

Table (2): Comparison between the studied groups regarding serum AST level (U/L):

AST	Mean	± SD	Range	ANOVA	P-value
Control group	80.72	3.61	72-89	321.95	<0.001**
Group V (AIP)	416.20 ^a	40.795	380-480		
Group VI (AIP +erdosteine)	255.33 ^{ab}	64.248	202-362		
Group VII (AIP+ NADPH)	237.50 ^{abd}	30.651	189-265		

** : highly significant. **a** highly significant difference when compared with the control group at $p < 0.001$. **b** highly significant difference when compared with the AIP group (V) at $p < 0.001$. **d** indicates a non-significant difference when compared with group VI (AIP+ erdosteine), $p > 0.05$.

II- Oxidative stress parameters:

There was a more significant ($p < 0.001$) increase in MDA level in the AIP group when compared with the control group. Administration of (AIP+ erdosteine) caused a reduction in MDA level, while test group VII (AIP+ NADPH) showed a marked reduction in MDA level when compared with group V and group VI, (Table 3).

There was a more significant ($p < 0.001$) reduction in CAT level in the AIP group when compared with the control group. Administration of (AIP +erdosteine) caused a

rise in CAT level, while test group VII (AIP+ NADPH) showed a marked increase in CAT level as compared to group V and group VI, (Table 4).

There was a more significant ($p < 0.001$) reduction in GSH level in the AIP group when compared with the control group. Administration of (AIP +erdosteine) caused a rise in GSH level, while test group VII (AIP+ NADPH) showed a marked increase in GSH level when compared with test group V and test group VI, (Table 5).

Table (3): Comparison between the studied groups regarding MDA level (nmol/gm) in hepatic tissue:

MDA	Mean	± SD	Range	ANOVA	P-value
Control group	0.533	0.09	0.402-0.691	137.20	<0.001**
Group V (AIP)	14.16 ^a	4.93	9.23-20.13		
Group VI (AIP+ erdosteine)	5.45 ^{ab}	0.62	4.77-6.21		
Group VII (AIP+ NADPH)	2.18 ^{abc}	0.919	0.919-3.77		

** : highly significant. **a** highly significant difference when compared with the control group at $p < 0.001$. **b** highly significant difference when compared with the AIP group (V) at $p < 0.001$. **c** highly significant difference when compared with AIP +erdosteine group at $p < 0.001$.

Table (4): Comparison between the studied groups regarding catalase (CAT) level (ng/ml) in hepatic tissue:

Catalase	Mean	± SD	Range	ANOVA	P-value
Control group	10.83	0.33	10.12- 11.64	732.32	<0.001**
Group V (AIP)	1.62 ^a	0.85	0.599-2.76		
Group VI (AIP +erdosteine)	4.20 ^{ab}	0.54	3.5-5.16		
Group VII (AIP+ NADPH)	7.08 ^{abc}	0.92	5.56-7.82		

** : highly significant. **a** highly significant difference when compared with the control group at $p < 0.001$. **b** highly significant difference when compared with the AIP group (V) at $p < 0.001$. **c** highly significant difference when compared with AIP +erdosteine group at $p < 0.001$.

Table (5): Comparison between the studied groups regarding GSH level (nmol/gm) in hepatic tissue:

GSH	Mean	± SD	Range	ANOVA	P-value
Control group	200.78	12.03	180-216	222.29	<0.001**
Group V (AIP)	66.20 ^a	21.253	39-87		
Group VI (AIP +erdosteine)	114.00 ^{ab}	11.367	101-129		
Group VII (AIP+ NADPH)	147.50 ^{abc}	10.330	132-162		

** : highly significant. **a** highly significant difference when compared with the control group at $p < 0.001$. **b** highly significant difference when compared with the AIP group (V) at $p < 0.001$. **c** highly significant difference when compared with AIP +erdosteine group at $p < 0.001$.

III- Histopathological results:

In control groups (negative control, solvent control, erdosteine control, NADPH control), examination of sections from liver tissue by light microscope showed almost the same structures with no marked histopathological changes. The negative control group was representative of other control groups, as shown in (Figure 1).

In group V (AIP treated group), liver sections showed inflammatory hepatic tissues, severe hydropic degeneration of hepatocytes, severe dilatation of the blood sinusoids, and congestion of the central vein, as shown in (Figures 2,3).

In group VI (AIP + erdosteine treated group), liver sections showed less pathological changes as compared to the AIP group but failed to have the same picture observed in the normal control group. There was a mild hydropic degeneration in hepatocytes, dilated congested blood sinusoids and central vein, as shown in (Figure 4).

In group VII (AIP + NADPH treated group), liver sections showed a better histopathological picture of liver morphology than that of the AIP & erdosteine treated group. It showed apparent normal hepatic architecture, as shown in (Figure 5).

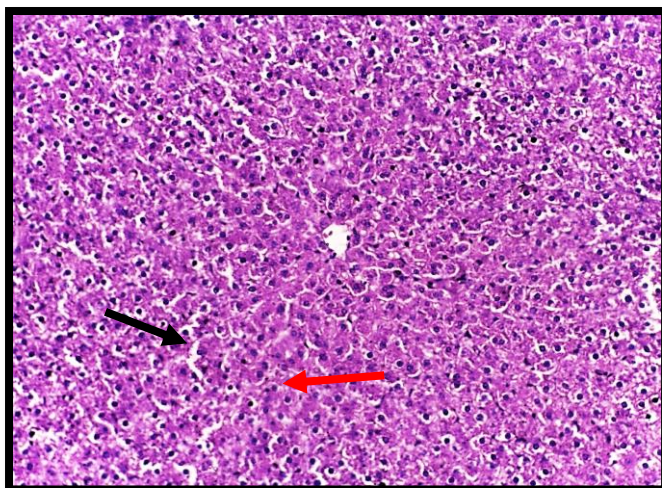


Fig. (1): A photomicrograph of a section from a rat's liver of the negative control group showed normal hepatic plates radiating from a thin-walled central vein separated by normal-sized blood sinusoids (black arrow), polyhedral hepatocytes contained rounded vesicular nuclei (red arrow) and eosinophilic cytoplasm (H&E, x 200).

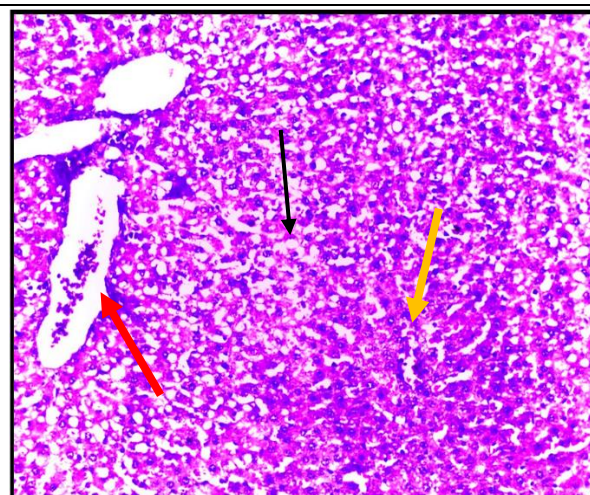


Fig. (2): A photomicrograph of a section from a rat's liver of AIP treated group showed dilated and distorted central vein (red arrow), vacuolated hepatocytes with hydropic degeneration (black arrow), dilated congested blood sinusoids with perivascular inflammatory cells (yellow arrow) (H&E, x 200).

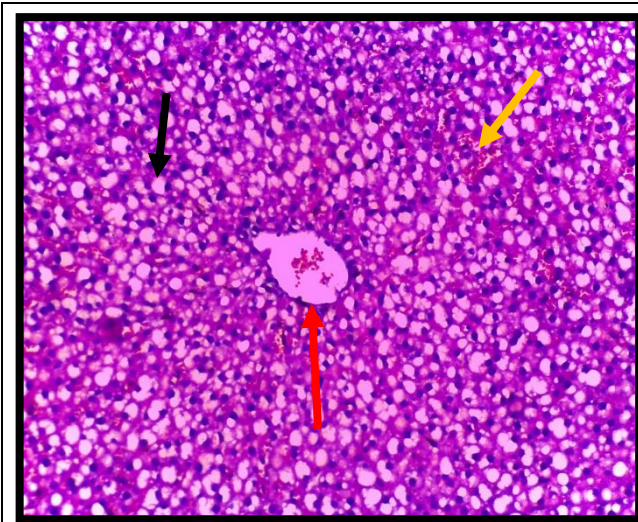


Fig. (3): A photomicrograph of a section from a rat's liver of AIP treated group showed dilated and distorted central vein (red arrow), severe hydropic degeneration of hepatocytes (black arrow) with many dilated congested blood sinusoids (yellow arrow) (H&E, x 200).

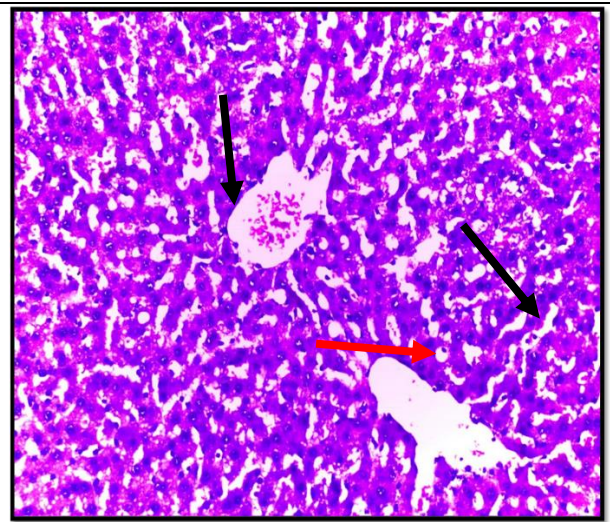


Fig. (4): A photomicrograph of a section from a rat's liver of AIP and erdosteine-treated group showed mild hydropic degeneration of hepatocyte (red arrow), central vein and blood sinusoids still dilated (black arrow) (H&E, x 200).

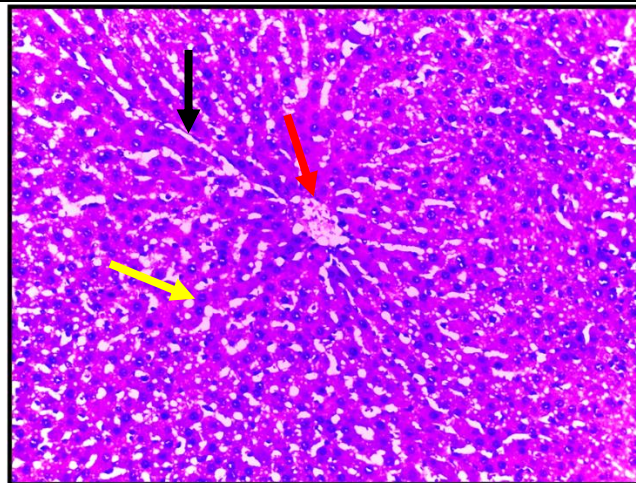


Fig. (5): A photomicrograph of a section from a rat's liver of the AIP and NADPH treated group showed a nearly normal-sized central vein (red arrow) with slightly dilated blood sinusoids (black arrow) and normal hepatocytes with eosinophilic cytoplasm and rounded vesicular nuclei (yellow arrow) almost similar to control group (H&E, x 200).

4. DISCUSSION

The liver is considered a major target organ for phosphine poisoning in the human body. So, the current study investigated the levels of serum (ALT) and (AST), being the fundamental biomarkers of the liver, that are released into circulation after hepatic injury (*El shehaby et al., 2021*).

In the present study, phosphine had markedly increased the mean values of both ALT and AST levels in the AIP-treated group

when compared with control groups, indicating liver tissue damage.

These results are in agreement with *Aminjan et al. (2019)*, *Sweilum et al. (2017)*, and *Anand et al. (2012)*. *Shadnia et al. (2005)* also reported markedly increased ALT and AST levels in human serum after AIP toxicity. According to *Mehrpour et al. (2012)*, a transient elevation of ALT and AST may occur in acute AIP poisoning.

Some human studies, such as *Anand et al. (2013)*, also reported the non-significant increase in ALT and AST levels in AIP

poisoning and explained that by the delay in the development of hepatotoxicity 72 hours after AIP toxicity if survival occurs.

In the current study, test group VI (AIP + erdosteine) showed a less significant decrease in the mean values of ALT and AST when compared with the AIP-treated group, but still higher than the control group.

This result was in agreement with the following studies that showed the positive effect of erdosteine in decreasing the serum levels of ALT and AST in many liver disorders and toxicity, such as ischemia-reperfusion injury in the liver of rats (*Barlas et al., 2017*), acetaminophen-induced liver damage (*Saritas et al. 2012*), in naphthalene induced liver damage (*Sehirli and Sener, 2010*).

In the present study, (the AIP + NADPH group) showed a more significant decrease in the mean values of liver enzymes ALT and AST when compared with the AIP group and (AIP + erdosteine) group.

Adzavon et al. (2022) and Xun et al. (2021) agreed with this result, as they reported that molecular hydrogen supply could increase the reduced NADPH level in the hepatocytes and improve liver metabolism with an observed decrease in serum ALT and AST levels.

In this research, AIP administration significantly increased the mean value of MDA level in liver tissue homogenate when compared with the control group and that result was in line with previous reports such as *Ranjbar et al. (2020), Salimi et al. (2017), Anand et al. (2012), Dua et al. (2010) and Quistad et al. (2000). Emam et al. (2021)* also found increased MDA levels in the serum of patients with AIP poisoning.

Administration of erdosteine with AIP in this study had reduced the mean value of MDA level in rats poisoned with AIP when compared with the AIP group.

This result was confirmed by the following studies, which showed the ability of erdosteine to decrease MDA level in liver tissue homogenate, such as; ischemia-reperfusion injury of the rat liver (*Barlas et al., 2017*), naphthalene hepatotoxicity in rats

(*Sehirli and Sener, 2010*), doxorubicin-induced hepatotoxicity in rats (*Yagmurca et al., 2007*).

This decrease in MDA level may be due to the antioxidant activity of erdosteine which helped in cell membrane protection by scavenging the free radicals (*Nacar et al., 2015*).

In the present work, (AIP + NADPH group) showed a more significant decrease in the mean value of MDA level when compared with the AIP group and (AIP + erdosteine group), but its mean value was still higher than the control group.

This result was in line with *Han et al. (2018)* who found that MDA level increases in liver tissue after NADPH deficiency. *Adzavon et al. (2022) and Fukuda et al. (2007)* also mentioned the ability of hydrogen gas to decrease liver MDA by increasing the NADPH/NADP ratio.

The result can be explained by the strong relationship between the increase in NADPH and the decrease in MDA formation in liver cells (*Augustin et al., 1997*).

The current study demonstrated a highly significant decrease in the mean value of CAT in liver tissue homogenate in the AIP-treated group.

Ranjbar et al. (2020), Aminjan et al. (2019), and Anand et al. (2012) confirmed this result after phosphine toxicity. The possible mechanism of catalase inhibition by phosphine may be due to its interaction with the metal ion co-factor that is present at the active site of the catalase enzyme (*Nath et al., 2011*).

In the present study, there was a less significant increase in the mean value of catalase enzyme in the (AIP+ erdosteine group). This result was in agreement with the following studies, which reported the increase in catalase enzyme after the use of erdosteine in the following conditions, such as; cyclosporine A-induced hepatotoxicity (*Erarlan et al., 2010*), doxorubicin-induced hepatotoxicity in rats (*Yagmurca et al., 2007*).

The current results showed a more significant increase in the mean value of catalase enzyme activity in the (AIP+ NADPH

group) when compared with the AIP-treated group.

This result was in agreement with *Han et al. (2018)*, who reported a decrease in catalase enzyme level after NADPH decrease in cases of isocitrate dehydrogenase (IDH₂) enzyme deficiency in liver tissue.

The present study showed a highly significant decrease in the mean value of GSH level in liver tissue homogenate in the AIP-treated group, and this result was confirmed by *Aminjan et al. (2019) and Salimi et al. (2017)*.

In the current study, (AIP + erdosteine group) caused a less significant increase in the mean value of GSH level when compared with the AIP group. This result was in agreement with *Sehirli and Sener (2010) and Sener et al. (2007)* who proved the beneficial effect of erdosteine in raising GSH levels in hepatotoxicity caused by naphthalene toxicity and biliary obstruction, respectively.

According to the current results, (the AIP + NADPH group) showed a more significant increase in the mean value of GSH level in comparison to the AIP group and (the AIP + erdosteine group). This beneficial action can be explained by the response of the cells to oxidative stress by increasing the level of reducing agents, including NADPH (*Adzavon et al., 2022*).

Kim et al. (2019) and Han et al. (2018) agreed with this result as they demonstrated the decrease in GSH enzyme level in the case of isocitrate dehydrogenase deficiency (IDH₂) enzyme, which is the major source of mitochondrial NADPH, in liver injury caused by acetaminophen and ischemia-reperfusion injury, respectively.

Also, this result was in agreement with *Augustin et al. (1997)* who confirmed the relation between the increase in NADPH and increased reduced glutathione levels in liver cells.

So, the present study suggested that phosphine could injure the liver tissue by induction of oxidative stress, evident by a significant increase in lipid peroxidation marker (MDA) and decrease in CAT and GSH in liver tissue.

Based on the results of oxidative stress parameters in the present study, erdosteine and NADPH can modulate the production of ROS in liver cells through their ability to protect the respiratory chain and improve the endogenous antioxidant capacity, including CAT and GSH thus decreasing the MDA level. So, they can decrease the oxidative damage caused by AIP toxicity.

The biochemical analysis of liver serum markers and oxidative stress markers in hepatic tissue in the current results was confirmed by the liver histopathological examination, which revealed that AIP caused severe hydropic degeneration of hepatocytes, severe dilatation of the blood sinusoids, and congestion of central vein.

These results were in agreement with *Eric et al. (2021), Elshehaby et al. (2021), Aminjan et al. (2019), Sweilum et al. (2017), and Gheshlaghi et al. (2015)*, who found similar changes in liver histopathology in AIP intoxicated rats.

In the current study, (AIP + erdosteine group) showed fewer pathological changes when compared with the AIP group.

This result was similar to the studies of *Barlas et al. (2017), Nacar et al. (2015), Saritas et al. (2012), Erarslan et al. (2010), Yagmurca et al. (2007), and Sener et al. (2007)* who reported the same protective effects of erdosteine treatment in liver injury induced by many toxins.

In the present study, a better histopathological picture of liver tissue was seen in the (AIP + NADPH-treated group). It showed apparent normal hepatic architecture. This result correlated with *Han et al. (2018)*, who confirmed the protective effect of NADPH on liver tissue.

5. CONCLUSION

1. The results revealed that administration of erdosteine with AIP caused a slight improvement in the AIP-induced hepatotoxicity via decreasing the level of (ALT, and AST) enzymes and MDA levels and improving the antioxidant defense (CAT, GSH) of the liver.

- Treatment by NADPH one hour after AIP toxicity was more protective against AIP-induced cardiotoxicity than treatment by erdosteine. NADPH ameliorated the AIP-induced hepatotoxicity by decreasing the level of (ALT, and AST) enzymes and MDA levels and improving the antioxidant defense (CAT, GSH) of the liver tissue. It showed apparent normal hepatic architecture in histopathological examination. So, NADPH may be a promising treatment for AIP toxicity.

6. RECOMMENDATIONS

- Restriction of AIP sale in Egypt.
- Further studies are needed to investigate the survival time in rats intoxicated with AIP after administration of exogenous NADPH and to investigate the positive effect of exogenous NADPH in the treatment of AIP in humans.

7. ACKNOWLEDGMENT

The authors are grateful to the technical and cooperative staff at the departments of Pathology, Faculty of Medicine, Central Lab of Veterinary Medicine, Benha University for their support during the study.

8. ABBREVIATIONS

AIP: aluminium phosphide
 NADPH: nicotinamide adenine dinucleotide phosphate
 ALT: alanine aminotransferase
 AST: aspartate aminotransferase
 MDA: malondialdehyde
 CAT: catalase
 GSH: reduced glutathione

9. REFERENCES

- Adzavon, Y. M.; Xie, F.; Yi, Y.; et al. (2022):** ‘Long-term and daily use of molecular hydrogen induces reprogramming of liver metabolism in rats by modulating NADP/NADPH redox pathways’, *Sci Rep.*; 12(1), p. 3904.
- Ahmadi, J.; Joukar, S.; Anani, H.; et al. (2018).** ‘Dihydroxyacetone as a definitive treatment for aluminium phosphide poisoning in rats’, *Arh Hig Rada Toksikol.*; 69 (2), p.169-177.
- Aminjan, H. H.; Abtahi, S. R.; Hazrati, E.; et al. (2019).** ‘Targeting of oxidative stress and inflammation through ROS/NF-kappaB pathway in phosphine-induced hepatotoxicity mitigation’, *Life Sci.*; 232, 116607.
- Anand, R.; Binukumar, B. K.; and Gill, K. D. (2011).** ‘Aluminum phosphide poisoning: an unsolved riddle’, *J Appl Toxicol.*; 31(6), p. 499–505.
- Anand, R.; Kumari, P.; Kaushal, A.; et al. (2012).** ‘Effect of acute aluminum phosphide exposure on rats: a biochemical and histological correlation’, *Toxicol Lett.*; 215(1), p. 62–69.
- Anand, R.; Sharma, D. R.; Verma, D.; et al. (2013).** ‘Mitochondrial electron transport chain complexes, catalase and markers of oxidative stress in platelets of patients with severe aluminum phosphide poisoning’, *Hum Exp Toxicol.*; 32(8), p. 807–816.
- Augustin, W.; Wiswedel, I.; Noack, H.; et al. (1997).** ‘Role of endogenous and exogenous antioxidants in the defence against functional damage and lipid peroxidation in rat liver mitochondria’, *Mol Cell Biochem*; 174(1-2), p. 199–205.
- Barlas, A. M.; Kismet, K.; Erel S.; et al. (2017).** ‘Erdosteine ameliorates the harmful effects of ischemia-reperfusion injury on the liver of rats’, *Acta Cir Bras*; 32(10), p. 796-806.
- Cazzola, M.; Calzetta, L.; Page, C.; et al. (2019).** ‘Thiol-Based Drugs in Pulmonary Medicine: Much More than Mucolytics’, *Trends Pharmacol Sci*; 40(7), p. 452–463.
- Demiralay, R.; Gürsan, N.; and Erdem, H. (2006).** ‘Regulation of sepsis-induced apoptosis of pulmonary cells by

posttreatment of erdoseine and N-acetylcysteine', *Toxicology*; 228(2-3), p. 151–161.

- Dua, R.; Sunkaria, A.; Kumar, V.; et al. (2010).** 'Impaired mitochondrial energy metabolism and kinetic properties of cytochrome oxidase following acute aluminium phosphide exposure in rat liver', *Food Chem Toxicol.*; 48(1), p. 53–60.
- El Shehaby, D. M.; Sayed, S. A.; Abd El-Kareem, D. M.; et al. (2021).** 'Trimetazidine with hyperinsulinemia-euglycemia, N-acetyl cysteine, and vitamin C: A new approach concept for management of aluminum phosphide poisoning', *J Biochem Mol Toxicol.*; 36(1), e22931.
- Emam, N.; Ahmed, D.; Mesbah, A.; et al. (2021).** 'Malondialdehyde and Total Antioxidant Capacity as Predictors Biomarkers of Mortality in Acute Aluminium Phosphide Poisoning', *Egy SCTJ*; 9(1), p. 34-46.
- Erarslan, E.; Ekiz, F.; Uz, B.; et al. (2010).** 'Effects of erdoseine on cyclosporine-A-induced hepatotoxicity in rats', *Drug Chem Toxicol.*; 34(1), p. 32–37.
- Eric, E. U.; Boloya, V. E.; and Osuamkpe, A. E. (2021).** 'Aggravation of Aluminum Phosphide Induced Liver Damage and Hematotoxicity in Adult Wistar Rat: The Role of Allium Sativum', *EJBIO*; 2(2), p. 51-59.
- Farzaneh, E.; Ghobadi, H.; Akbarifard, M.; et al. (2018).** 'Prognostic Factors in Acute Aluminium Phosphide Poisoning: A Risk-Prediction Nomogram Approach', *Basic Clin Pharmacol Toxicol.*; 123(3), p. 347–355.
- Fukuda, K.; Asoh, S.; Ishikawa, M.; et al. (2007).** 'Inhalation of hydrogen gas suppresses hepatic injury caused by ischemia/reperfusion through reducing oxidative stress', *Biochem Biophys Res Commun.*; 361(3), p. 670–674.
- Gheshlaghi, F.; Lavasanijou, M. R.; Moghaddam, N. A.; et al. (2015).** 'N-acetylcysteine, Ascorbic Acid, and Methylene Blue for the Treatment of Aluminium Phosphide Poisoning: Still Beneficial?', *Toxicol Int.*; 22(1), p. 40–44.
- Han, S. J.; Choi, H. S.; Kim, J. I.; et al. (2018).** 'IDH2 deficiency increases the liver susceptibility to ischemia-reperfusion injury via increased mitochondrial oxidative injury', *Redox Biol.*; 14, p. 142–153.
- Hasabo, G. (2015).** 'Aluminum Phosphide, A Serious killer in Egypt', *JFTM*; 1(1), p. 6-7.
- Karimani, A.; Mohammadpour, A. H.; Zirak, M. R.; et al. (2018).** 'Antidotes for aluminum phosphide poisoning – An update', *Toxicol Rep.*; 5, p. 1053–1059.
- Kim, H.; Lee, J. H.; and Park, J. W. (2019).** 'IDH2 deficiency exacerbates acetaminophen hepatotoxicity in mice via mitochondrial dysfunction-induced apoptosis', *Biochim Biophys Acta Mol Basis Dis*; 1865(9), p. 2333–2341.
- Koc, A.; Duru, M.; Ciralik, H.; et al. (2005).** 'Protective agent, erdoseine, against cisplatin-induced hepatic oxidant injury in rats', *Mol Cell Biochem.*; 278(1-2), p. 79–84.
- Mehrpour, O.; Jafarzadeh, M.; and Abdollahi, M. (2012).** 'A systematic review of aluminium phosphide poisoning', *Arh Hig Rada Toksikol*; 63 (1), p. 61-73.
- Moghadamnia, A. A. (2012).** 'An update on toxicology of aluminum phosphide', *Daru*; 20(1), p. 25.
- Moretti, M. (2007).** 'Pharmacology and clinical efficacy of erdoseine in chronic obstructive pulmonary disease', *Expert Rev Respir Med*; 1(3), p. 307–316.
- Nacar, A.; Karaboğa, I.; Okuyan, H. M.; et al. (2015).** 'Investigation of the protective effect of erdoseine against cyclosporine-

- induced injury in rat liver with histological and biochemical methods', *Turk J Med Sci*; 45(6), p. 1390–1395.
- Nath, N. S.; Bhattacharya, I.; Tuck, A. G.; et al. (2011).** 'Mechanisms of Phosphine Toxicity', *J Toxicol*; 2011, 494168, p. 1-9.
- Ogasawara, Y.; Funakoshi, M.; and Ishii, K. (2009).** 'Determination of reduced nicotinamide adenine dinucleotide phosphate concentration using high-performance liquid chromatography with fluorescence detection: ratio of the reduced form as a biomarker of oxidative stress', *Biol Pharm Bull*; 32(11), p. 1819–1823.
- Quistad, G. B.; Sparks, S. E.; and Casida, J. E. (2000).** 'Chemical model for phosphine-induced lipid peroxidation', *Pest Manag Sci*; 56, p. 779-783.
- Ranjbar, A.; Gholami, L.; Ghasemi, H.; et al. (2020).** 'Effects of nano-curcumin and curcumin on the oxidant and antioxidant system of the liver mitochondria in aluminum phosphide-induced experimental toxicity', *Nanomed. J*; 7, p. 58-64.
- Salimi, A.; Paezi, M.; Yousefsani, B. S.; et al. (2017).** 'Inhibition of glucose-6-phosphate dehydrogenase protects hepatocytes from aluminum phosphide-induced toxicity', *Pestic Biochem Physiol*; 143, p. 141–146.
- Saritas, A.; Kandis, H.; Baltaci, D.; et al. (2012).** 'N-Acetyl cysteine and erdosteine treatment in acetaminophen-induced liver damage', *Toxicol Ind Health*; 30(7), p. 670–678.
- Sciuto, A. M.; Wong, B. J.; Martens, M. E.; et al. (2016).** 'Phosphine toxicity: a story of disrupted mitochondrial metabolism', *Ann N Y Acad Sci*; 1374(1), p. 41–51.
- Sehirli, A. O. and Sener, G. (2010).** 'Protective effect of erdosteine against naphthalene-induced oxidative stress in rats', *Marmara Pharm J*; 14, p. 67-73.
- Sener, G.; Aksoy, H.; Sehirli, Ö.; et al. (2007).** 'Erdosteine Prevents Colonic Inflammation Through Its Antioxidant and Free Radical Scavenging Activities', *Dig Dis Sci*; 52(9), p. 2122–2132.
- Shadnia, S.; Rahimi, M.; Pajoumand, A.; et al. (2005).** 'Successful treatment of acute aluminium phosphide poisoning: possible benefit of coconut oil', *Hum Exp Toxicol*; 24(4), p. 215–218.
- ++ Y.; Joshi, S.C.; Satyawali, V.; et al. (2014).** 'Acute aluminium phosphide poisoning, what is new?', *Egypt J Intern Med*; 26, p. 99 - 103.
- Solgi, R.; Baghaei, A.; Golaghaei, A.; et al. (2015).** 'Electrophysiological and molecular mechanisms of protection by iron sucrose against phosphine-induced cardiotoxicity: a time course study', *Toxicol Mech Methods*; 25(4), p. 249–257.
- Sweilum, O. A. H.; Kandeel, F. S.; and Noya, D. A. R. (2017).** 'Management of acute aluminum phosphide toxicity in rat model with a novel intervention, a trial of boric acid', *Egypt J. Forensic Sci. Appl. Toxicol*; 17(2), p. 57-72.
- Xun, Z. M.; Zhao, Q. H.; Zhang, Y.; et al. (2020).** 'Effects of long-term hydrogen intervention on the physiological function of rats', *Sci Rep*; 10(1), 18509.
- Yagmurca, M.; Bas, O.; Mollaoglu, H.; et al. (2007).** 'Protective effects of erdosteine on doxorubicin-induced hepatotoxicity in rats', *Arch Med Res*; 38(4), p. 380–385.
- Zhu, J.; Wang, Y. F.; Chai, X. M.; et al. (2019).** 'Exogenous NADPH ameliorates myocardial ischemia-reperfusion injury in rats through activating AMPK/mTOR pathway', *Acta Pharmacol Sin*; 41(4), p. 535–545.

التأثير الوقائي لمادتي الإردوشتاين ونيكوتيناميد أدنين ثنائي نوكليويد الفوسفات المختزل علي سمية الكبد الناتجة عن التسمم الحاد بفوسفيد الألومنيوم في الفئران البيضاء

فوسفيد الألومنيوم هو مبيد حشري صلب يعمل بالتبخير، وقد تم استخدامه بشده في الإنتحار في الأيام الحالية عن طريق البلع، ويعد الفشل الكبدي من أشهر اسباب الوفاة بعد التسمم الحاد بفوسفيد الألومنيوم بأربع وعشرين ساعة. الهدف من الدراسة الحالية هو إستكشاف التأثير الإيجابي لعقار الإردوشتاين ومادة نيكوتيناميد أدنين ثنائي نوكليويد الفوسفات المختزل علي سمية الكبد الناتجة عن التسمم الحاد بفوسفيد الألومنيوم في الجرذان البيضاء البالغة وذلك من خلال فحص مستوي إنزيمات الكبد في الدم وقياس علامات الإجهاد التأكسدي في نسيج الكبد. تم إجراء هذه التجربة علي أربعة وخمسون فأر من الذكور، حيث تم تقسيمهم عشوائيا إلي سبع مجموعات (كل مجموعة بها 6 فئران) كالآتي: المجموعة الضابطة السلبية، مجموعة المواد المذيبة، المجموعة الضابطة الإيجابية للإردوشتاين، المجموعة الضابطة الإيجابية لنيكوتيناميد أدنين ثنائي نوكليويد الفوسفات المختزل، مجموعة فوسفيد الألومنيوم (12 مجم / كجم بالفم مرة واحدة)، مجموعة فوسفيد الألومنيوم 12 مجم / كجم ثم يتبع بعد ساعة بالإردوشتاين 150 مجم / كجم بالفم مرة واحدة، مجموعة فوسفيد الألومنيوم 12 مجم / كجم بالفم مرة واحدة ثم يتبع بعد ساعة ب(نيكوتيناميد أدنين ثنائي نوكليويد الفوسفات المختزل 16 مجم / كجم عن طريق الحقن الوريدي مرة واحدة. بعد مرور ثمان ساعات من بداية التجربة تم أخذ عينات الدم من الضفيرة الدموية الخلفية للعين من أجل فحص وظائف الكبد في الدم وكذلك تم فتح تجويف البطن لإخراج الكبد لفحص علامات الإجهاد التأكسدي والفحص الهستوباثولوجي. أوضحت النتائج أن التسمم بفوسفيد الألومنيوم سبب زيادة في إنزيمات الكبد في الدم وارتفاع معدل (المالونداي ألددهايد) في نسيج الكبد، المصاحب بنقص معدل الإنزيمات والمركبات المضادة للأكسدة (الكثاليز والجلوتاثيون) في نسيج الكبد. إعطاء عقار الإردوشتاين مع فوسفيد الإلومنيوم سبب تحسنا طفيفا في سمية الكبد الناتجة عن فوسفيد الألومنيوم والذي ظهر من خلال خفض معدل وظائف الكبد في الدم وخفض معدل (المالونداي ألددهايد) في نسيج الكبد وزيادة معدل الإنزيمات والمركبات المضادة للأكسدة (الكثاليز والجلوتاثيون) في نسيج الكبد. أما إعطاء مادة نيكوتيناميد أدنين ثنائي نوكليويد الفوسفات المختزل مع فوسفيد الألومنيوم أحدث تحسنا ملحوظا في سمية الكبد الناتجة عن فوسفيد الألومنيوم من خلال خفض مستوي وظائف الكبد في الدم وخفض معدل (المالونداي ألددهايد) في نسيج الكبد وزيادة معدل الإنزيمات والمركبات المضادة للأكسدة (الكثاليز والجلوتاثيون) في نسيج الكبد بشكل ملحوظ، وقد تم تأكيد هذه النتائج بالفحص الهستوباثولوجي لأنسجة الكبد المأخوذة من كل مجموعة. لذلك أثبتت الدراسة الحالية أن مادتي الإردوشتاين ونيكوتيناميد أدنين ثنائي نوكليويد الفوسفات المختزل من الممكن أن تحسن سمية الكبد الناتجة عن فوسفيد الألومنيوم.