

Original Article

The Efficacy of Topical Sesame Oil in Orabase Versus Topical Triamcinolone in Orabase on Oral Lichen Planus and Salivary Level Of Oxidative Stress Biomarker (MDA): Randomized Clinical Trial

Mona Taha Mohammed¹, Noha Adel Azab¹, Olfat Gamil Shaker², Amal Ali Husseine¹

¹Oral Medicine and Periodontology Department, Faculty of Dentistry, Cairo University, Egypt.

²Medical Biochemistry and Molecular Biology, Faculty of Medicine, Cairo University, Egypt.

Submitted: 7-6-2023

Accepted: 10-11-2023

E-mail: mona.taha @dentistry.cu.edu.eg

ABSTRACT

Objectives: To compare the efficacy of topical sesame oil in the formulation of gel and topical triamcinolone acetonide 0.1% in managing the signs and symptoms of OLP. **Patients and Methods:** This randomized, non-blind, controlled trial had thirty four patients who were randomized into two groups to receive either sesame oil oral gel or triamcinolone acetonide 0.1% oral gel thrice daily for 4 weeks. The patients were analyzed for the symptom (burning) using visual analogue scale and sign (erythema and ulceration) using the thongprasome index and salivary MDA by ELISA technique. **Results:** The VAS scores was statistically significant between both groups ($p = 0.003$). The Thongprasome index was statistically significant between both groups ($p < 0.001$); The MDA was statistically insignificant between both groups ($p = 0.838$). Our analyses demonstrated statistically. **Conclusion:** Sesame oil has no detectable effect on improving the clinical picture of OLP. It had an inferior effect to triamcinolone in relieving pain and clinical picture.

Keywords: Triamcinolone acetonide, sesame oil, Thongprasome, VAS

Introduction:

Oral lichen planus (OLP) is a T-cell-mediated chronic inflammatory mucosal disease of unknown etiology (Abbas et al., 2014). It affects about 0.4% to 5% of the world population (Alrashdan et al., 2016). OLP is classified as a potentially malignant disorder by the WHO with a rate of malignant transformation of 1.09% particularly in erythematous and erosive OLP (Alrashdan et al., 2016; Iqbal et al., 2020).

In Egypt, the prevalence of oral lichen planus is reported to be 1.43% with 2.2:1 female to male ratio particularly in the 4th and 6th decade of life. The percentage of the symptomatic forms in Egyptian patients is 59.37% atrophic and 20.3% erosive OLP (Mostafa and Ahmed, 2015). Patients usually complain of symptoms that range from mild discomfort to severe pain causing difficulty in eating, speaking and oral hygiene. Additionally, the premalignant nature of this

disease causes anxiety, stress and cancerphobia for patients. It also affects their quality of life and may even worsen their symptoms (Radwan-Oczko et al., 2017).

The goal of OLP management is not curative but symptomatic relief, acceleration of healing and decrease the chances of malignant transformation (Gupta and Jawanda, 2015). Corticosteroids are the gold standard and the first line of treatment of OLP as they reduce inflammation and pain due to their potent anti-inflammatory and immunomodulatory effects (Gorouhi et al., 2007; Gupta et al., 2017).

The chronic nature of the OLP mandates a prolonged course of treatment. Moreover, the repeated episodes of exacerbation increase the incidence of facing corticosteroids side effects which range from mucosal thinning or secondary candidiasis to more serious systemic side effects as adrenal insufficiency, hypertension and osteoporosis (Al-Maweri et al., 2017). Based on the role of oxidative stress in the pathogenesis of OLP, there are currently trends towards using natural or herbal drugs with anti-inflammatory and antioxidant properties, with or without corticosteroids to overcome the side effects of long term use of steroids (Keshari et al., 2015; Amirchaghmaghi et al., 2016).

Sesame oil was used as a unique natural oil rich in lignans (sesamin, sesamol, and sesamolol) and tocopherols which are responsible for antioxidant and anti-inflammatory activities as they increase the antioxidant enzymes, down-regulate oxidative stress, lipid peroxidation and MDA. Sesamin and sesamolol suppress NF κ B activation (Geetha et al., 2009) via inhibition of I κ B dissociation through decreasing I κ B kinase activity (Harikumar et al., 2010 and Woo et al., 2019).

Based on the antioxidant and anti-inflammatory role of sesame oil, it can be suggested as a suitable therapeutic candidate for OLP treatment. Furthermore, sesame oil has anticancer properties

through lignans and tocopherols' anti-mutagenic ability (Hsu et al., 2013; Monteiro et al., 2014). Sesame oil has been proven in several trials as a safe and cost effective drug. This is besides its ease of application, palatable taste and acceptable mouth feel even in patients who may have nausea (Anilakumar et al., 2011; Dharmavaram et al., 2015; Okada et al., 2015; Bigdeli Shamloo et al., 2015; Khaira et al., 2020).

This study aimed at assessing topical Sesame oil in comparison to Triamcinolone acetonide for the management of oral lichen planus regarding pain relief, clinical improvement and antioxidant effect.

Subjects and Methods

Study Design:

Phase III, parallel two-armed superiority randomized controlled clinical trial. (Trial Registration Number Identifier: NCT03738176)

Study Settings:

The study was conducted at the Department of Oral Medicine and Periodontology, Faculty of Dentistry, Cairo University.

The study duration was from September 2018 till November 2021.

Ethical Approval:

The study was approved by the ethical committee of scientific research – faculty of Dentistry – Cairo University (Registration Number: 19/3/14) and was conducted according to the declaration of Helsinki. The details of the study were explained to all patients, and written informed consent was obtained from the patients before entering into the study. Patients were first assessed for eligibility, then those eligible had the details of the study were explained to them. The patients signed a written Arabic informed consent that had all the pertinent information and complications prior to entering the study.

Sample Size Calculation:

The required sample size for this study was determined according to (Thomas et al., 2017)

using two tailed test , $\alpha=0.05$ and power =0.8 and an effect size of 1.1272141 yielding 14 patients in each group. A 20% increase in sample size to avoid attrition bias gave a total of 17 patients per group.

Participants:

Eligibility Criteria:

Patients were recruited from the Diagnostic Center, Faculty of Dentistry, Cairo University, where attending patients were screened until reaching the target sample. We included medically free patients with Symptomatic (atrophic or erosive) oral lichen planus who had no history of taking corticosteroids or immunosuppressive drugs within 1 month before the study. We excluded patients with lichenoid reaction, or those having other lesions than OLP and pregnant and lactating females.

Intervention :

Sesame oil Preparation:

20% Sesame oil from raw sesame seed-70% NaCMC-10% gelatin -100% distilled water and (Methyl para and propyl paraben as a preservatives). Several trials were carried out to determine the maximum loading capacity of orabase without showing any signs of separation which was 12 mg (20%). Sesame oil used in this study is cold pressed from raw white Egyptian sesame seeds .

Procedure:

Full medical history and intra and extra oral examination, verbal and written consent were obtained from all patients enrolled in the study . Patients were randomly allocated into two groups of 17 :

Group A: Subjects received topical sesame oil in orabase 3 times /day one hour after eating for a month.

Group B: Subjects received topical Kenacort in orabase (0.1% Triamcinolone) 3 times /day one hour after eating for a month (Bristol-Myers Squibb Company).

The patients in both groups were instructed to apply a thin layer of the treatment. The patients were asked not to eat, drink or smoke for 30 minutes after each application. The patients were asked to report immediately if there was any side effect at any time of the study. Patients were also assessed for any possible side effects by researcher at each appointment and their compliance to the drugs .

Outcomes:

Pain Intensity:

Intensity of pain was measured for each patient using visual analogue scale (VAS) which is a 10-cm ruler where each patient reports the degree of pain to a number on this scale where Zero score indicating "no pain" and 10 score indicating "extremely severe pain."

The VAS was measured at baseline and at each follow-up visit (weeks 2 and 4) by the principal investigator.

Clinical Improvement:

Clinical Improvement and reduction in size of the lesion was measured using a periodontal probe and the area of the erosive and atrophic parts was calculated. The lesion was photographed at each visit at a standard distance parallel to the lesion site at a standard angle for documentation. Reduction in clinical sign score was assessed objectively using **Thongprasom score (Thongprasom et al., 1992)**. These measurements were done at baseline and at the end of the second and fourth weeks.

Salivary Malondialdehyde (MDA) Level:

Salivary sample collection:

Whole unstimulated Saliva was collected at baseline and after one month from treatment in the two groups using standard techniques (**Navazesh, 1993**). All the samples were collected at room temperature, which is relatively stable. Samples were collected for 5 min from both the test and control groups where the subject leant

forward and spitted saliva into a graded sampling tube.

Determination of Human Malondialdehyde (MDA) in saliva :

Saliva sample was centrifuged for 10 min at 4000xg. Supernatant was separated and used for determination of MDA level using ELISA Kit Cat No. MBS263626. Provided by My Biosource (USA, NY).

This kit employs the “Double Antibody Sandwich” technique. The principle of Double

Antibody Sandwich is based on the characteristics of a target analyte with more than two possible epitopes which can be identified by both the pre-coated capture antibody and the detection antibody simultaneously.

Sequence Generation and Allocation Concealment :

Random sequence was generated using Microsoft Excel and was implemented by N.A. as was the allocation concealment which was done using the telephone after the primary investigator enrolled the each participant

Blinding:

The principal investigator acted as the outcome assessor and was not blind to the allocated treatment nor was the patient due to the nature of the treatment.

Statistical methods

Data management and statistical analysis were performed using the Statistical Package for Social Sciences (SPSS) version 24. Numerical data were summarized using means and standard deviations or medians and ranges. Data were explored for normality by checking the data distribution and using Kolmogorov-Smirnov and Shapiro-Wilk tests. Categorical data were summarized as percentages. Comparisons

between the two groups with respect to normally distributed numeric variables were done using the t-test. Non normally distributed numeric variables were compared by Mann-Whitney test. Comparisons over time regarding numeric variables were done by repeated measure ANOVA, Friedman test and Wilcoxon test as appropriate. For categorical variables, differences were analyzed with chi square (χ^2) test and Fisher’s exact test when appropriate. All p-values are two-sided. P-values ≤ 0.05 were considered significant.

Results:

From September 2018 till November 2021, 34 patients were included in the study. The flow chart of the patients through the study followed the CONSORT flow diagram is presented in **Figure (1)**.

Comparing median VAS scores over time in each single group was statistically significant for both groups with superiority for group B.

Comparing mean size over time in each single group was statistically insignificant for group A while a significant reduction in lesion size was seen in group B ($p < 0.001$) throughout the three time intervals.

Before treatment, the median and range of the MDA was 3.5(2.4-10.6) for Group A and 3.2(1.2-8.6) for Group B with no statistically significant difference between both groups ($p = 0.357$).

After treatment, the median and range of the MDA was 3.5(1.2-25.9) for Group A and 2.4 (1.2-8.7) for Group B with no statistically significant difference between both groups ($p = 0.838$).

Comparing median MDA over time in each single group was statistically insignificant ($p > 0.05$)

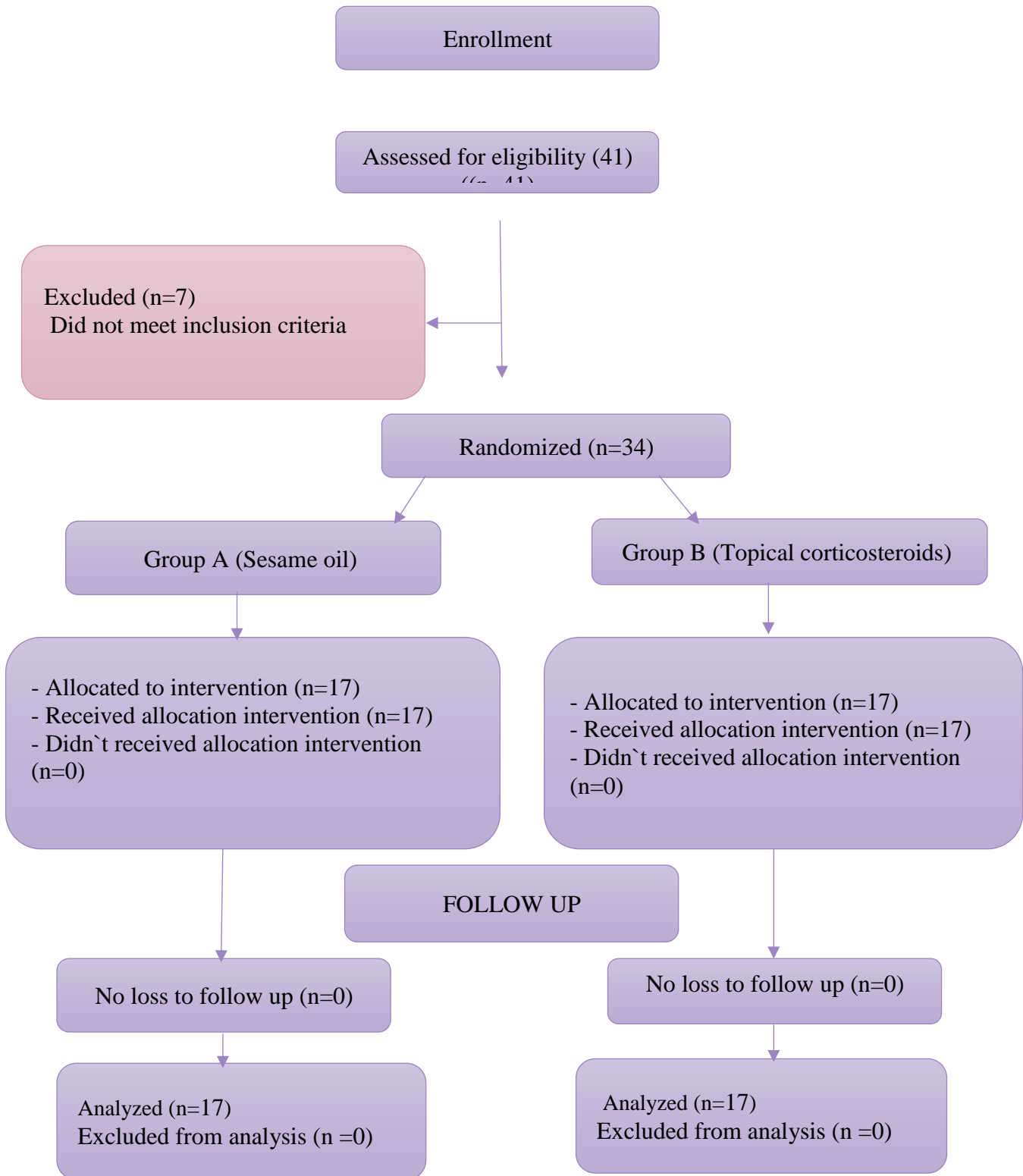


Figure (1): CONSORT Flowchart

Table (1): Clinical characteristics of included patients

Variables	Group	Group A(n=17)		Group B (n=17)		P value
		No	%	No	%	
Age (yrs.)	Mean± SD	11.9±52.7		48.4±9.6		0.21
	Range	34-75		32-66		
Sex	Male (%)	3(17.6)		2(11.8)		1.0
	Female (%)	14 (82.4)		15 (88.2)		
Types of OLP	Erosive	7		8		
	Atrophic	10		9		
Site Distribution	Cutaneous lesion	5		3		
	Buccal mucosa	16		16		
	Tongue	7		6		
	Gingiva	2		1		
	Labial mucosa	3		0		

Table (2): Median and range of VAS score at different time points in the tested groups

	Group A			Group B			P value 1
	Median	Min.	Max.	Median	Min.	Max	
0	7 ^a	5	9	7*	6	9	0.394
Week2	6	4	9	6	5	8	0.454
Week4	5 ^a	0	8	2	0	6	0.003
P value 2	<0.001			<0.001			

P≤0.05 is statically significant; *P*1: for comparison between 2 groups. *P*2: for comparison over time in each group separately, similar lower case letters are statistically significant ,*: all time interval are statistically significant from each other's.

Table (3): Mean and SD of size at different time points in the tested groups

SIZE	Group A		Group B		P value 1
	Mean	SD	Mean	SD	
Week 1	3.2	1.2	3.4*	0.7	0.456
Week 2	2.9	1.2	2.9	0.8	0.833
Week 4	2.8	1.3	1.2	0.9	<0.001
P value 2	0.218		<0.001		

P≤0.05 is statically significant; *P1*: for comparison between 2 groups. *P2*: for comparison over time in each group separately, *: all time intervals are statistically significant

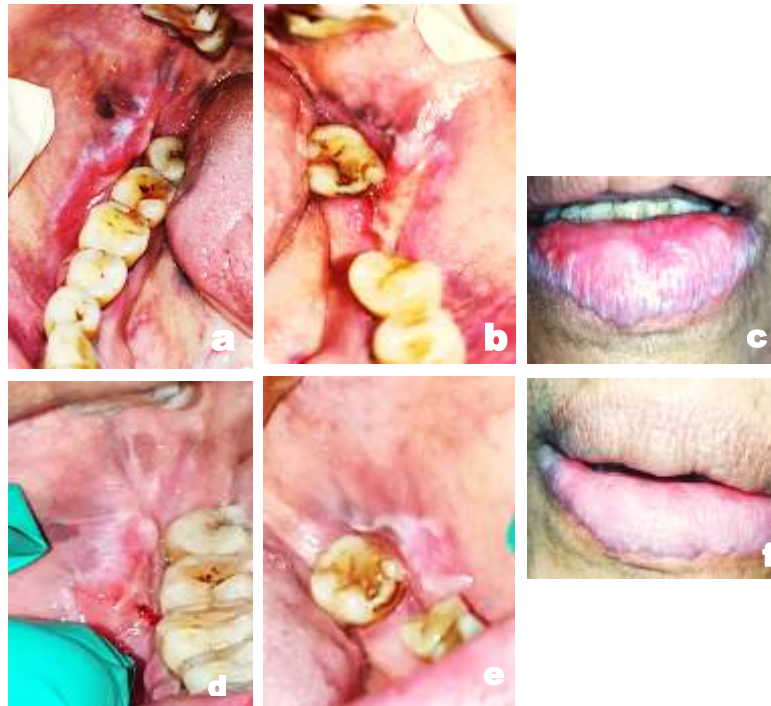

Figure (2): a, b, c: Clinical photograph of a 74 years old female patient showing atrophic OLP on the right side of buccal mucosa, erosive OLP on the left side of buccal mucosa and on the lower vermilion border. (Thongprasome score:4, VAS:8). d, e, f: Clinical photograph of the same patient showing partial healing on the right and left sides of the buccal mucosa and lower labial mucosa. (Thongprasom score:2, VAS:1)

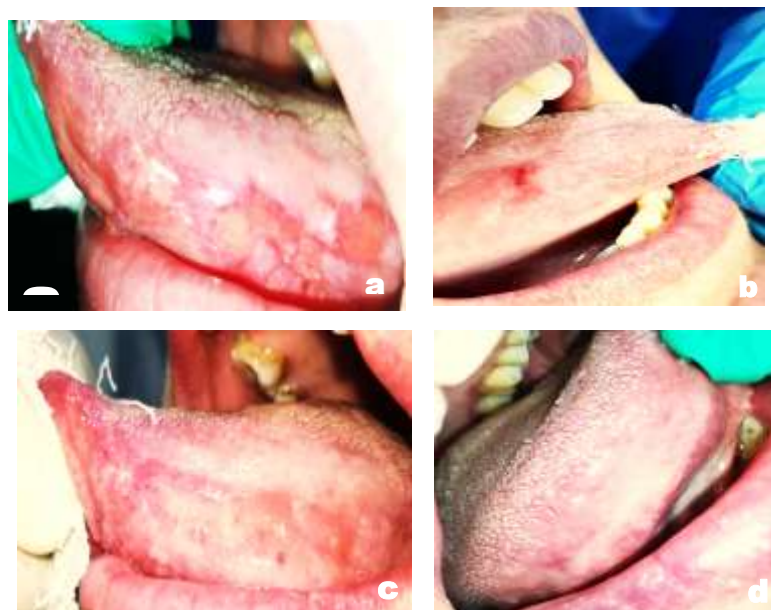

Figure (3): a,b: Clinical photograph of 46years old female patients showing atrophic and erosive OLP on the right and left sides of the tongue.(Thongprasome score:5,VAS:8). **c,d:** Clinical photograph of the same patient showing partial healing on the right and left sides of the tongue.(Thongprasome score:1,VAS:0).

Discussion

Up to our knowledge, the current study is the first randomized controlled clinical trial evaluating the effectiveness of topical use of Sesame oil in the formulation of gel in management of symptomatic OLP. Consequently, no similar previous studies are available for comparison with our results.

In our results, Triamcinolone was effective and safe, where the patients did not complain from any side effects. The current study found that Sesame oil can significantly reduce pain over a period of 4 weeks. Sesame oil contains gamma Tocopherol and α -tocopherol which are the two major constituents of vitamin E. Vitamin E has anti-inflammatory activity where it can down regulate dendritic cells migration, cyclooxygenase (Cox)-2 activity and production of prostaglandinE2 (PGE2) and interleukin (IL-12). Also vitamin E can regulate T-cell function via suppression of tumor necrosis factor (TNF)- α , IL-6 and IL-1 β release (Lee et al., 2018; Lewis et al., 2019). Furthermore, vitamin E has chemopreventive activity where it can inhibit cancer cell growth and differentiation (Iqbal et al., 2014). Many observational studies assessed the serum and salivary level of Vitamin E in OLP (Raietal, 2008; Abdolsamadi et al., 2014; Mohammed and Diajil, 2019). Naga et al. measured the level of salivary vitamin E in OLP patients compared to control and reported that the salivary level of Vitamin E was lower in OLP patients as compared to healthy controls. Moreover, serum level of Vitamin E was lower in erosive/atrophic OLP as compared to reticular OLP (Nagao et al., 2001). This justifies the use of vitamin E containing compounds in patients with OLP.

However, the present study found that Sesame oil could not bring about a significant reduction of lesion size over the treatment duration. Moreover,

TA had a higher statistically significant effect in reducing lesion size and pain than Sesame oil.

Inamdar et al, 2015 conducted a study on 30 patients with OLP and treated them with a 50 ml prepared formulation of aloe vera, licorice and sesame oil in the form of a gargle which was swished for a minimum of 5 min in the oral cavity twice daily for a period of 6-weeks. They found that there was a decrease in pain, erythema, burning sensation, and functional disturbance after using the prepared formulation.

Dayem et al (2020) have used Vitamin E in treatment of OLP. They used vitamin E systematically as an adjunctive treatment to topical triamcinolone acetonide., they found that the group treated with Vitamin E capsules and topical triamcinolone acetonide showed greater improvement in pain, clinical scores with decrease in salivary total antioxidant capacity .

Topical sesame oil has been researched in other diseases. Dharmavaram et al (2015) used topical Sesame oil for the treatment of recurrent aphthous stomatitis which is an inflammatory disease mediated by immune dysregulation like OLP. They found that topical sesame oil showed statistically significant reduction in pain and size of lesion. Sharquie et al. (2020) compared the effect of sesame oil and pumpkin oil in the management of recurrent aphthous ulcer and their prophylactic effect. They found that sesame oil showed higher statistically significant effect in the healing of recurrent aphthous ulcer and prophylactic effect after 1, 2 and 3 months from starting therapy.

This finding highlights the role of antioxidants in the treatment of OLP and the validity of pursuing this research venue. Contrary to this belief, sesame oil did not have favorable results in the current study where there was no significant lesion size reduction in the Sesame oil group. Possible explanations, would be that the current

study used sesame oil from raw sesame seeds which contain small amounts of sesamol as opposed to that present in roasted sesame oil where sesamol is converted to sesamol after roasting (**Kumar et al., 2015; Islam et al., 2016**). Sesamol is generally regarded as the main anti-oxidative and anti-inflammatory component of sesame oil (**Hsu et al., 2013**). Sesamol can suppress the production of TNF- α and down regulate cytokine release from dendritic cells in concentration lower than sesame oil and with stronger effects than sesame oil (**Khorrami et al., 2018**). Another explanation would be the use of local sesame seeds to manufacture the oils which could be contaminated with heavy metals (Pb, As, Cu, Cd, Zn). These metals could be from the soil, fertilizers, and even geographical conditions encountered during seed transport. The percentage of heavy metals in the oil differ according to the method of extraction. These include: grinding roasted sesame seed including Ardeh oil or cold pressed including virgin oil and refined oil, where the refined oil has the lowest amount of heavy metals (**De Leonardis et al., 2000; Pehlivan et al., 2008; Rounizi et al., 2020**). Moreover, cold pressed Sesame oil may contain Aflatoxins due to fungal infection during harvest, transportation, and storage (**Li et al., 2009; Sebaei et al. (2020)**). Found that 37 % of the Egyptian sesame samples included in their study had large amounts of aflatoxin of up to 20 $\mu\text{g}/\text{kg}$.

On the other hand, studies by **Hegde et al (2017) and Sawair et al. (2010)** investigated alternative treatments used by patients for treatment of recurrent aphthous ulcers. They found that Tahini is the major alternative treatment where all subjects who applied Tahini believed that Tahini was effective in relieving pain and reduction in the duration and frequency of ulceration. This results may be due to the difference in composition where Tahini is made from milled and roasted sesame seeds which contain high levels of beneficial nutrients such as calcium,

iron, potassium and phosphorus, antioxidants and vitamins (B, C and E) in addition to sesame oil (more than 50%) (**Gholami et al., 2020**).

Under physiological conditions, there are low lipid peroxidations rates (sub toxic conditions) and the cells can survive via activation of signaling pathways that increase the antioxidants proteins and finally the adaptive stress response. However, under pathological conditions, there are medium or high lipid peroxidation rates (toxic conditions), so oxidative damage predominates cells regeneration, and induces apoptosis (**Ayala et al., 2014**). Serum markers besides local markers of oxidative stress can be found in saliva so it is used in the early diagnose and in the surveillance of diseases in response to treatment (**Mansourian et al., 2016**).

Malondialdehyde (MDA) is the principal end product of lipid (long chain of polyunsaturated fatty acid) peroxidation so can be used as a marker for oxidative stress (**Shirzad et al., 2013**). Results of salivary MDA in our study revealed that no statistically significant difference was found in each study group as well as when comparing both groups. **Mansourian et al. (2016)** evaluated the level of MDA in patients with OLP before and after TA treatment and found that there was no significant difference in the reduction of salivary MDA levels before and after treatment which is in accordance with our results. MDA may not be a specific marker for oxidative stress levels

In conclusion, the palliative effect of sesame seed products is undeniable through-out numerous studies (**Hsu et al., 2008; Wichitsranoi et al., 2011; Roghani et al., 2013; Haidari et al., 2016**) Seeds rich in vitamin E have continuously proven to be effective in many mucosal diseases (**Iqbal et al., 2013; Bacci et al., 2017; Lewis et al., 2019; Dayem et al., 2020**). The findings of the current study suggest that sesame oil alone is not enough to achieve a better therapeutic effect in OLP patients than TA It can , however be used as a safe adjunctive drug in treatment of OLP.

Conflict of Interest:

The authors declare no conflict of interest.

Funding

This research did not receive any specific grant from funding agencies in the public, commercial, or not-for-profit sectors.

References:

1. Abbas, A.W. Zaidan,T.F, Y. Abbood Al-Barrak,A. (2014). Assessment of Serum and Salivary Malondialdehyde in Patients with Oral lichen planus. J Bagh College Dentistry . <https://doi.org/10.12816/0015203>.
2. Abdolsamadi, H., Rafieian, N., Goodarzi, M. T., Feradmal, J., & Ahmadi-motamayel, F. (2014). Levels of Salivary Antioxidant Vitamins and Lipid Peroxidation in Patients with Oral Lichen Planus and Healthy Individuals. Chonnam Medical Journal,58–62. <http://dx.doi.org/10.4068/cmj.2014.50.2.58>.
3. Al-Maweri, S. A., Kalakonda, B., Al-Soneidar, W. A., Al-Shamiri, H. M., Alakhali, M. S., & Alaizari, N. Efficacy of low-level laser therapy in management of symptomatic oral lichen planus: a systematic review. Lasers in medical science, (2017). 32(6), 1429-1437.
4. Alrashdan, M. S., Cirillo, N. and McCullough, M. ‘Oral lichen planus: a literature review and update’, Archives of Dermatological Research. Springer Berlin Heidelberg, (2016):308(8), pp. 539–551.
5. Amirchaghmaghi, M., Pakfetrat, A., Delavarian, Z., Ghalavani, H., & Ghazi, A. (2016). Evaluation of the Efficacy of Curcumin in the Treatment of Oral Lichen Planus :ARandomizedControlledTrial.10(5), 134–137. <https://doi.org/10.7860/JCDR/2016/16338.7870>
6. Anilakumar,K.R.,PAL,A., Khanum ,F.,Bawpal, A. S.,(2010). Nutritional , Medicinal and Industrial Uses of Sesame (Sesamum indicum L .) Seeds - An Overview. Agriculturae Conspectus Scientificus .75-4. antioxidant profile in patients with oral Lichen planus. J. Oral Pathol. Med. 40, 286–293
7. Ayala, A., Muñoz, M. F., & Argüelles, S. (2014). Lipid Peroxidation: Production, Metabolism, and Signaling Mechanisms of Malondialdehyde and 4-Hydroxy-2-Nonenal. 2014.
8. Bacci C, Vanzo V, Frigo AC, Stellini E, Sbricoli L, Valente M. Topical tocopherol for treatment of reticular oral lichen planus: a randomized, double- blind, crossover study. Oral Dis. 2017; 23 (1): 62- 68. doi: 10.1111/odi.12573.
9. Bigdeli Shamloo MB, Nasiri M, Dabirian A, Bakhtiyari A, Mojab F, Alavi Majd H. The Effects of Topical Sesame (Sesamum indicum) Oil on Pain Severity and Amount of Received Non-Steroid Anti- Inflammatory Drugs in Patients With Upper or Lower Extremities Trauma. Anesth Pain Med. 2015;5(3):e25085
10. Dayem, E. A., Abd, W., Mohamad, E., Shaker, O. G., & Ali, S. (2020). Effect

- of adjunctive systemic vitamin E on clinical parameters and salivary total antioxidant capacity in symptomatic oral lichen planus patients : Randomized controlled clinical trial. 2(1).
11. Dharmavaram.A,T. , Reddy.R.S.Nallakunt .R. “ Ozone ” – The New Nemesis of Canker Sore. (2015). 16–19. <https://doi.org/10.7860/JCDR/2015/1911.5617>
 12. Geetha T, Rohit B, Pal KI. Sesamol: an efficient antioxidant with potential therapeutic benefits. *Med Chem.* 2009. 5:367-371.
 13. Gholami,M.Davan,S.T.Gholami,M.,Bolandparvaz,S.,Gholami,M.,Chamanpara,P.,Shayan,L.(2020). Effects of Topical Sesame Oil Extracted from Tahini (. 8(3), 179–185. <https://doi.org/10.30476/BEAT.2020.82561.Journal>.
 14. Gorouhi F, Solhpour A, Beitollahi JM, Afshar S, Davari P, Hashemi P, et al. Randomized trial of pimecrolimus cream versus triamcinolone acetonide paste in the treatment of oral lichen planus. *J Am Acad Dermatol* 2007;57(5):806-13.
 15. Gupta, S., & Jawanda, M. K. (2015). Oral Lichen Planus : An Update on Etiology , Pathogenesis , Clinical Presentation , Diagnosis and Management. 60(3), 222–229.
 16. Gupta, S., Ghosh, S., & Gupta, S. Interventions for the management of oral lichen planus: a review of the conventional and novel therapies. *Oral Diseases*, (2017):23(8), 1029-1042.
 17. Haidari F, Mohammadshahi M, Zarei M, Gorji Z (2016) Effects of sesame butter (Ardeh) versus sesame oil on metabolic and oxidative stress markers in streptozotocin-induced diabetic rats. *Iran JMed Sci* 41(2):102–109
 18. Harikumar KB, Sung B, Tharakan ST, Pandey MK, Joy B, Guha S, et al. Sesamin manifests chemopreventive effects through the suppression of NF- κ B-regulated cell survival, proliferation, invasion, and angiogenic gene products. *Mol Cancer Res.* 2010. 8:1541-7786.
 19. Hegde, S., Ajila, V., Babu, S., & Rai, S. (2017). Traditional methods used by patients for the management of recurrent aphthous stomatitis. *Journal of Intercultural Ethno pharmacology* 6(4), 10–12. <https://doi.org/10.5455/jice.20171110112326>
 20. Hsu, D., Chen, S., Chu, P., & Liu, M. (2013). Therapeutic effects of sesame oil on monosodium urate crystal-induced acute inflammatory response in rats. (II), 1–10.2.659.
 21. Hsu, D.-Z., Chien, S.-P., Li, Y.-H., Chuang, Y.-C., Chang, Y.-C., & Liu, M.-Y. (2008). Sesame oil attenuates hepatic lipid peroxidation by inhibiting nitric oxide and superoxide anion generation in septic rats. *Journal of Parenteral and Enteral Nutrition*, 32(2), 154–159. <https://doi.org/10.1177/0148607108314766>.
 22. Inamdar, H., Sable, D. M., Subramaniam, A. V, Subramaniam, T., & Choudhery, A. (2015). Evaluation of efficacy of indigenously prepared formulation of Aloe vera , licorice and

- sesame oil in treatment of oral lichen planus : An in vivo study. *Journal of Advanced Clinical & Research Insights*, 2, 237–241. <https://doi.org/10.15713/ins.jcri.86>
23. Iqbal, M. A., Yesmin, S., Maaisha, F., Ibrahim, S., & Gotame, P. (2020). Oral lichen planus and its recent management : A review, *UpDCJ*; 10 (2): 29-34,DOI: <https://doi.org/10.3329/updcj.v10i2.50179>.
 24. Iqbal MA, Khan M, Kumar P, Kumar A, Ajai K, Role of vitamin e in prevention of oral cancer:-areview. *J Clin Diagn Res*. 2014; 8 (10): ZE05-7. doi786010,7860 /JCDR/2014/9166.4958
 25. Islam F, Gill RA, Ali B, Farooq MA, Xu L, Najeeb U, Zhou W (2016) Sesame. Ch. 6. In:Gupta SK (ed) *Breeding oilseeds crops for sustainable production opportunities and constraints*. Academic press is an imprint of Elsevier, pp 135–147. <https://doi.org/10.1016/B978-0-12-801309-0.00006-9>.
 26. Keshari, D., Patil, K., & Mahima, V. G. (2015). Efficacy of topical curcumin in the management of oral lichen planus : A randomized controlled-trial. 2(May 2014), 197–203. <https://doi.org/10.15713/ins.jcri.78>
 27. Khaira, S., Verma, P., & Gupta, S. (2020). Role of Sesame Oil Pulling in the Management of Oral Submucous Fibrosis : A Pilot Study. *Acta Scientific Dental Sciences* :4(8), 109–113. <https://doi.org/10.31080/ASDS.2020.04.0897>
 28. Khorrami, S., Daneshmandi, S., & Mosayebi, G. (2018). Sesame seeds essential oil and Sesamol modulate the pro-inflammatory function of macrophages and dendritic cells and promote Th2 response. *Medical Journal of the Islamic Republic of Iran (MJIRI)*. 32.98. <https://doi.org/10.14196/mjiri.32.98>
 29. Kumar, C. M., & Singh, S. A. (2015). Bioactive lignans from sesame (*Sesamum indicum* L .): evaluation of their antioxidant and antibacterial effects for food applications. *J Food Sci Technol* 52(5), 2934–2941. <https://doi.org/10.1007/s13197-014-1334-6>
 30. Lee GY, Han SN. The Role of Vitamin E in Immunity. *Nutrients*. 2018; 10 (11): E1614. doi: 10.3390/nu10111614.
 31. Lewis ED, Meydani SN, Wu D. Regulatory role of vitamin E in the immune system and inflammation. *IUBMB Life*. 2019; 71 (4): 487-494. doi: 10.1002 /iub.1976.
 32. Li, F.Q., Li, Y.W., Wang, Y.R., Luo,

- X.Y., 2009. Natural occurrence of aflatoxins in Chinese peanut butter and sesame paste. *J. Agric. Food Chem.* 57 (9), 3519–3524.
33. Mansourian, A., Hosseini, F. A., Kazemi, H. H., Mortazavi, N., & Moosavi, M. S. (2017). Salivary oxidative stress in oral lichen planus treated with triamcinolone mouthrinse. *Dental Research Journal Original.* 104–110
34. Mohammed, A. J. & Diajil, A. R. (2019). Salivary vitamin E and uric acid in patients with OLP and healthy individuals. *J. Bagh College Dentistry.* 39–43.
35. Monteiro, É., Chibli, L., Yamamoto, C., Pereira, M., Vilela, F., Rodarte, M., ... da Luz André de Araújo, A. (2014). Antinociceptive and anti-inflammatory activities of the sesame oil and sesamin. *Nutrients*, 6(5), 1931–1944.
<https://doi.org/10.3390/nu6051931>
36. Mostafa, B., & Ahmed, E. (2015). Prevalence of oral lichen planus among a sample of the Egyptian population. *Journal of clinical and experimental dentistry*, 7(1).
<https://doi.org/10.4317/jced>.
37. Nagao T, Warnakulasuriya S, Ikeda N, Fukano H, Yamamoto S, Yano M, Miyazaki H, Ito Y. Serum antioxidant micronutrient levels in oral lichen planus. *J Oral Pathol Med.* 2001; 30 (5): 264-267.
38. Navazesh M. “Methods for collecting saliva,” *Annals of the New York Academy of Sciences* 1993; 694: 72–77.
39. Okada, S., Sudo, A., & Nishio, J. (2015). Topical Application of Sesame Oil for the Prevention of Chemotherapy- Induced Oral Mucositis : Pilot Study in Seven Hematopoietic Cancer Patients *International Journal of Nursing & Clinical Practices.* 2, 1–6.
40. Pehlivan, E., Arslan, G., Gode, F., Altun, T., & Özcan, M. M. (2008). Determination of some inorganic metals in edible vegetable oils by inductively coupled plasma atomic emission spectroscopy (ICP- AES), *Grasas Y Aceites*, 59, 239– 244.
41. Radwan-Oczko, M. et al. (2017) ‘Psychopathological profile and quality of life of patients with oral lichen planus’, *Journal of Applied Oral Science*, 26, pp. 1–9. doi: 10.1590/1678-7757-2017-0146.
42. Rai B, Kharb S. Salivary lipid peroxidation product malondialdehyde in pre-cancer and cancer. *Adv Med Dent Sci* 2008;2:7-8.
43. Rödström PO, Hakeberg M, Jontell M, Nordin P. Erosive oral lichen planus treated with clobetasol propionate and triamcinolone acetonide in orabase: a double-blind clinical trial. *J Dermatol Treat.* 1994. <https://doi.org/10.3109/09546639409081837>
44. Roghani M, Jalali-Nadoushan MR, Baluchnejadmojarad T, Vaez Mahdavi

- MR, Naderi G, Roghani Dehkordi F, et al. Endothelium-dependent Effect of Sesame Seed Feeding on Vascular Reactivity of Streptozotocin-diabetic Rats: Underlying Mechanisms. *Iran J Pharm Res.* 2013;12:377-85. PubMed PMID: 24250645.
45. Rounizi ,K. S., Fateme, R., Mohajeri, A., Moshtaghi, H., Fatemeh, B., Sara, P., ... Khalili, E. (2020). The chemical composition and heavy metal content of sesame oil produced by different methods: A risk assessment study. *Food Sci Nutr.* 2021;9:2886–2893.
46. Sawair, F. (2010). Recurrent Aphthous Stomatitis: Do We Know What Patients Are Using to Treat the Ulcers : THE JOURNAL OF ALTERNATIVE AND COMPLEMENTARY MEDICINE , 16- 6. <https://doi.org/10.1089/acm.2009.0555>.
47. Sebaei, A. S., Refai, H. M., Elbadry, H. T., & Armeya, S. M. (2020). First risk assessment report of a flatoxins in Egyptian tahini. *Journal of Food Composition and Analysis*, 92(October 2019), 103550. <https://doi.org/10.1016/j.jfca.2020.103550>
48. Sharquie, K. E., Noaimi, A. A., & Ahmed, D. S. (2020). Topical Sesame Seed and Pumpkin Seed Oils have Therapeutic and Prophylactic Role in the Management of Recurrent Aphthous Stomatitis. *American Journal of Dermatology and Venereology* 2020, 9(3): 38-42 9(3), 38–42.
- <https://doi.org/10.5923/j.ajdv.20200903.02>.
49. Shirzad, A., Pouramir, M., Seyedmajidi, M., Jenabian, N., Bijani, A., & Motalebnejad, M. Salivary total antioxidant capacity and lipid peroxidation in patients with erosive oral lichen planus. *Journal of dental research, dental clinics, dental prospects*, (2013):8(1), 35.
50. Thomas AE, Varma B, Kurup S, et al. Evaluation of Efficacy of 1% Curcuminoids as Local Application in Management of Oral Lichen Planus - Interventional Study. *J Clin Diagn Res.* 2017; 11(4): 89–93.
51. Thongprasom, K. et al. (1992) ‘Relative efficacy of fluocinolone acetonide compared with triamcinolone acetonide in treatment of oral lichen planus’, *Journal of Oral Pathology & Medicine*, 21(10), pp. 456–458. doi: 10.1111/j.1600-0714.1992.tb00974.
52. Wichitsranoj J, Weerapreeyakul N, Boonsiri P, Settasiatani C, Settasiatani N, Komanasin N, et al. Antihypertensive and antioxidant effects of dietary black sesame meal in pre-hypertensive humans. *Nutr J.* 2011;10:82. doi: 10.1186/1475-2891-10-82. PubMed PMID: 21827664; PubMed Central PMCID: PMC3173298.

53. Woo, M., Han, S., & Song, Y. O. (2019). Sesame Oil Attenuates Renal Oxidative Stress Induced by a High Fat

Diet . Nutr. Food Sci. 2019;24(2):114-120, 114–120.
<https://doi.org/10.3746/pnf.2019.24.2.114> .