



Quercetin Ameliorates Hepatic Structure and Function, Alleviate Testicular Damage and Mitigate Oxidative Stress Induced by Monosodium Glutamate in Male Rats

Safa H. Qahl¹ and Reham Z. Hamza²

¹Department of Biology, College of Science, University of Jeddah, P.O. Box 80327, Jeddah 21589, Saudi Arabia.

²Department of Biology, College of Sciences, Taif University, P.O. Box 11099, Taif 21944, Saudi Arabia.

Quercetin (QR) is a potent free radical scavenging agent and possess potent antioxidant and protective effects. Monosodium glutamate (MOSG) is a well-known flavor enhancer that has side effects on many organs and tissues as recorded in many literatures. The current study aims to evaluate the antioxidant, hepatoprotective and testicular protective effects of QR on oxidative stress, hepatotoxicity and testicular damage induced by MOSG. **Methods:** Totally, 40 male albino rats were involved in the study and were divided into 4 groups: 1st control group with normal saline, 2nd group treated with MOSG, 3rd group treated with QR, 4th treated group treated with combination of MOSG and QR. Antioxidant biomarkers SOD, GPx, CAT, MPO, XO and MDA, SH and PC were evaluated in the hepatic tissues. Testosterone, inhibin-B and 8-OHDG which is a marker of DNA damage were examined in serum samples. Testes and liver tissues were studied and scored for the different histological alterations as key indicators of testicular and hepatic injury after MOSG administration and its potent ameliorative and antioxidant effects. Beside, comet assay of the testicular tissues was performed. **Results:** Administration of QR plus MOSG increased significantly the enzymatic antioxidants and declined the lipid peroxidation and DNA damage markers as compared with MOSG treated group alone. QR increased the level of testosterone hormone and improved histological structure of both testis and liver. **Conclusion:** It is apparent that QR inhibits hepatic and testicular damage and improves the antioxidant enzyme capacities and alleviate DNA damage in experimental male rats.

Keywords: Oxidative stress, Quercetin, Monosodium glutamate, Antioxidant, Histopathology, DNA damage.

Introduction

Monosodium glutamate (MOSG), is the white sodium salt of the glutamic acid [1]. MOSG is a well-common flavor, it is used mainly as a food additive for giving special taste [2]. Glutamate is mainly produced in the human body and displays a key role in the metabolism. MOSG is generally produced by the process of fermentation of starch [3].

Previous exposure of male rats to MOSG induced increment in oxidative stress, obesity, hepatotoxicity, tissue damage, neural abnormalities and cytotoxicity. MOSG ingestion is associated with a significant elevation in free radicals due to severe oxidative stress [4]. Previous literatures proved that MOSG administration induced different toxicities [5,6].

MOSG induced a wide range of toxicity on different organs, especially the hepatic tissues [7,8]. Additionally, Pavlovic *et al.* [9] demonstrated that administration of MOSG in high dosages induced severe oxidative stress in thymus glands of experimental animals. MOSG, induced dysfunction of male reproductive system and triggering of excessive reactive oxygen species (ROS), genetic disorders, testicular inflammation and hormonal disturbance [10].

MOSG impaired testicular structures and severe histological alternations as previously demonstrated [11-14]. MOSG produce a lot of symptoms such as dizziness, sweating and somewhat headaches. MOSG has a proved toxic effect on the testicular tissues after inducing a marked reduction in sperms (oligozoospermia) and elevates the abnormal morphology of sperms with a lot of deformation in experimental male rats [15].

*Corresponding author: Reham Z. Hamza, E-mail: reham.z@tu.edu.sa. Tel.: 00966531355470

(Received 17/09/2023, accepted 04/11/2023)

DOI: 10.21608/EJVS.2023.236111.1614

©2024 National Information and Documentation Center (NIDOC)

MOSG caused male infertility and alteration of sperm structure and morphology in experimental male rats [16,17].

Antioxidants play an important role in the alleviation of lipid peroxides by scavenging lipid peroxy radicals [18,19], and it also decline the oxidative damage in a lot of tissues in experimental animals [20]. Quercetin is a well-known polyphenolic flavonoid [21].

QR is a potent antioxidant found mainly in fruits and vegetables, it is capable of hepatoprotection and also decreasing the levels of bad cholesterol and triglycerides [22]. Also, QR is considered as a strong antioxidant agent, with high potency of free radicals scavenger. Additionally, QR is considered as a promoter of antioxidant enzymes superoxide dismutase and glutathione enzyme activities [22].

QR is considered as a powerful antioxidant [23]. It's enhanced antioxidant capacity is due to the presence of aromatic hydroxyl groups in its structure [24]. QR has the capacity of metal ion chelation, and modulation of cellular antioxidant capacities [25]. QR protects against oxidative stress by keeping the glutathione enzyme in its reduced form [26].

QR effectively mitigated MOSG-induced lipid peroxidation and antioxidant status alteration of different organs such as liver, kidney and brain. QR is currently used as a supplementary for a lot of health benefits [27].

The current study aimed to evaluate the ameliorative effect and potent antioxidant activity

of QR in alleviating of both hepatic and reproductive toxicities of MOSG treatment and evaluation of QR role as antioxidant and anti-genotoxic agent.

Material and Methods

Chemicals used:

MOSG (High analytical grade), was obtained from company of Fine Chemicals, India. The MOSG dosage was accurately adjusted weekly after recording the weight of each rat of treated experimental groups.

MOSG was administered at a dose (60 mg/kg) [28]. QR was obtained from Sigma Co., USA. QR was administrated at a dose (30 mg/kg) [18].

The Experimental animals and design

Forty adult male rats, with weight range (140 and 150 g) were continuously housed in hygiene standard cages with the ideal laboratory conditions. This study based on the European animal care Community Directive (86/609/EEC). This experimental work was carried out and approved under the ethical number:42-78. The treated rats were adapted to the laboratory conditions for only 15 days before starting the experiment. Male rats were separated into four treated groups: 1st control group was administrated 0.9 % normal saline (NaCl) (1ml); 2nd treated group was given MOSG (60 mg/kg); 3rd treated group was administrated with QR (30 mg/kg); 4th group was treated with MOSG firstly and then combined with QR. All treatments were given orally for 30 successive days as shown in Fig (1).

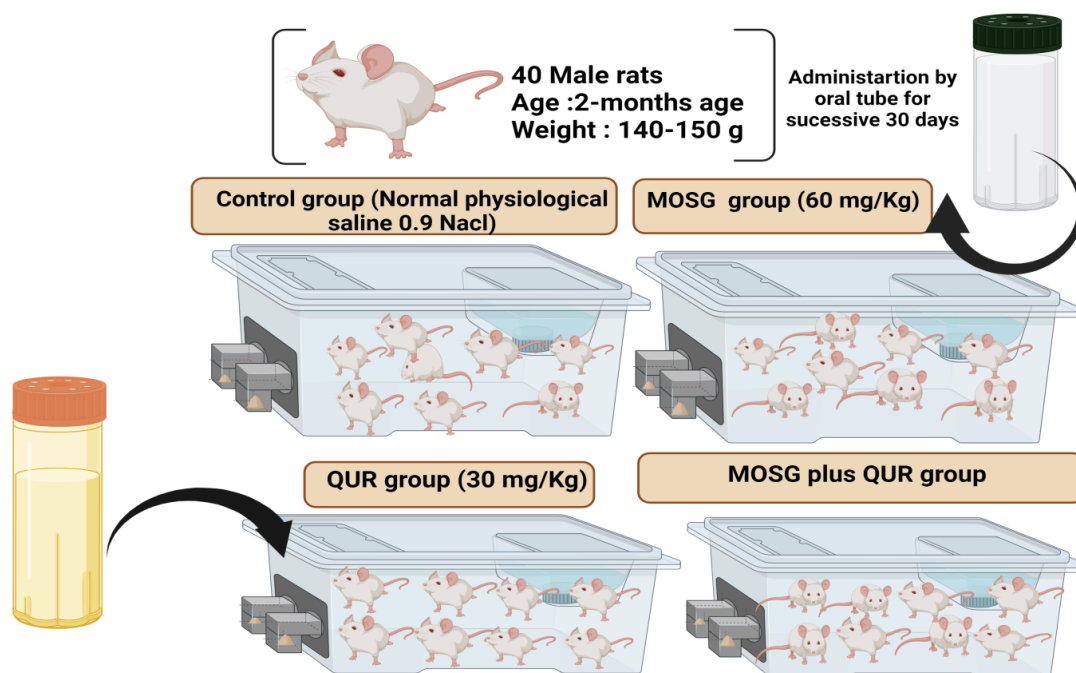


Fig. 1. Experimental design

Assessment of the hepatic functions and lipid profile

Blood samples were collected from the sacrificed male rats after light anesthesia, samples were collected from eye plexus. Serum samples were used for determination of both liver enzymes (AST and ALT) and lipid profile (Total Cholesterol , Triglycerides , HDL-C , LDL-c and vLDL-c) based on using (Biodiagnostic Co.) kits.

Preparation of liver tissue homogenates

Enzymatic and non-enzymatic antioxidants were determined in liver tissues homogenates (~0.30 g). After light Xylene/Ketamine euthanasia of male rats , Liver tissues were homogenized in ice-colded phosphate-buffered saline, using the ice cold homogenizer. The hepatic tissues' homogenates were centrifuged at 5000 r.p.m for 20 min at 4°C, and the supernatant was transferred into centrifuge tubes and preserved at -4°C until use.

Determination of liver tissues antioxidant enzymatic and non-enzymatic biomarkers

Superoxide dismutase activity (SOD) was evaluated according to Christine *et al.* [29] and expressed as (U/g). Catalase activity (CAT) (U/g) was assessed according to Christine *et al.* [29]. Glutathione peroxidase activity (GPx) was evaluated according to Hafeman *et al.* [30]. Myeloperoxidase activity (MPO) was estimated based on Suzuki *et al.* [31]. Xanthine oxidase activity (XO) was assayed based on Litwack *et al.* [32]. Thiol levels were estimated based on Hu. [33]. Protein carbonyl (PC) levels were estimated according to Weber *et al.* [34] , using commercial Bio-Diagnostic kits.

Malondialdehyde levels (MDA) were evaluated based on Ohkawa *et al.* [35] by using Bio-Diagnostic kits.

Testosterone hormone, inhibin-B and 2.8. plasma 8-hydroxydeoxyguanosine

Testosterone hormone levels were estimated based on ELISA kit by (Elecsys, Roche diagnostics) [36]. Inhibin-B was evaluated by using an ELISA kit (Biomatik), the detection range (12.50-1000 pg/ml). 8-hydroxydeoxyguanosine level (8-OHDG) was estimated by using the ELISA kit (Biosciences, Spain), within range (129 - 8000 pg/ml).

Examination of the histological sections

A small portion of both liver and testis tissues were fixed in neutral formalin (10%) and complete processes according to Gabe [37].

Comet assay (single-cell gel electrophoresis)

A small Portion of the testicular tissues were placed in a small Petri dish with an ice-cold solution. Cell viability was estimated from scoring of the comet images under basic conditions [38].

Statistical analysis

Data were expressed as mean ± SE. Statistical analysis was performed using one-way ANOVA. For each significant effect post hoc test was used [39].

Results

Hepatic functions and lipid profile

The results showed an increase in liver enzymes (AST and ALT) in the MOSG-treated group. Meanwhile, the combination of QUR and MOSG improved liver enzymes and restored virtually normal values, confirming that QUR caused a potent hepatoprotective action against MOSG toxicity (Table 1).

The same table revealed an increase in cholesterol and triglyceride levels in the MOSG-treated group, with a clear decrease in HDL-C and an increase in both LDL-c and vLDL-c levels. QUR reduces the negative effects of both cholesterol and triglycerides, restoring normal HDL-c levels while decreasing LDL-c and vLDL-c levels.

TABLE 1.Effect of MOSG or QUR and their combination on liver functions and lipid profile of male rats.

Parameters	Control	MOSG (60 mg/g)	QUR (30 mg/kg)	MOSG+ QUR
ALT (U/g)	13.25±1.52 ^c	87.69±3.65 ^a	13.05±2.58 ^c	21.02±3.58 ^b
AST (U/g)	15.39±2.69 ^c	67.68±3.65 ^a	15.87±1.98 ^c	18.69±2.68 ^b
Total cholesterol (mg/dL)	120.36±5.69 ^d	175.69±6.69 ^a	121.58±4.58 ^{cd}	134.25±5.65 ^b
Triglycerides (mg/dL)	96.58±3.25 ^d	146.25±5.25 ^a	97.58±4.65 ^{cd}	111.69±5.58 ^b
HDL-c (mg/dL)	40.52±4.25 ^a	30.69±4.87 ^c	40.87±3.69 ^a	37.58±3.69 ^b
LDL-c (mg/dL)	30.69±5.87 ^d	39.57±3.69 ^a	31.65±4.35 ^{cd}	34.25±3.69 ^b
vLDL-c (mg/dL)	19.31±2.02 ^d	29.25±3.69 ^a	19.51±3.69 ^{cd}	22.33±4.25 ^b

Biomarkers of Oxidative injury

The biochemical alterations in the antioxidant enzymes in the MOSG-treated group were substantial. The current findings revealed an

increase in lipid peroxidation levels, which was supported by an increase in MDA levels. The combination of QUR and MOSG reduced the level of lipid peroxidation (Table 2).

TABLE 2. Effect of MOSG or QUR and their combination on MDA , SOD, CAT and GPx levels in the hepatic tissues of male rats.

Parameters	Control	MOSG (60 mg/g)	QUR (20 mg/kg)	MOSG and QUR
MPO (nM/min/mg)	27.32±2.51ab	19.15±4.74d	26.84±2.67b	23.18±3.98c
XO (U/g)	38.70±3.45 ^c	28.43±4.17 ^a	37.68±3.78 ^c	33.56±4.74 ^b
TH (mmol/g)	0.72±0.61b	0.42±0.11c	0.73±0.23ab	0.71±0.07b
PC (nmol/mg)	1.63±0.54 ^c	10.52±1.44 ^a	1.62±0.15 ^c	1.89±0.75 ^b

Means in each category (mean ±SE) carrying different letters are significant at $P \leq 0.05$, the highest mean value has symbol (a) and decreasing alphabetically.

The activity of SOD, CAT, and GPx in liver tissue homogenates were clearly reduced in the MOSG-treated group. QUR with MOSG treatment, on the other hand, increased the levels of antioxidant enzymes (Table 2). MPO and XO levels were considerably lower in the MOSG group.

Both QUR and MOSG therapy increased the levels of these biomarkers (Table 3). Furthermore, there was a significant decrease in TH levels in hepatic tissues in the MOSG group. Finally, the group that received both MOSG and QUR afforded a marked increment in both PC levels as compared with MOSG treated groups (Table. 3).

TABLE 3 .Effect of MOSG or QUR and their combination on MPO , XO , protein carbonyl (PC) and Thiol (SH) in the hepatic tissues of male rats.

Parameters	Control	MOSG (60 mg/g)	QUR (20 mg/kg)	MOSG and QUR
MPO (nM/min/mg)	27.32±2.51 ^{ab}	19.15±4.74 ^d	26.84±2.67 ^b	23.18±3.98 ^c
XO (U/g)	38.70±3.45 ^c	28.43±4.17 ^a	37.68±3.78 ^c	33.56±4.74 ^b
TH (mmol/g)	0.72±0.61 ^b	0.42±0.11 ^c	0.73±0.23 ^{ab}	0.71±0.07 ^b
PC (nmol/mg)	1.63±0.54 ^c	10.52±1.44 ^a	1.62±0.15 ^c	1.89±0.75 ^b

Means in each category (mean ±SE) carrying different letters are significant at $P \leq 0.05$, the highest mean value has symbol (a) and decreasing alphabetically.

Testosterone hormone and inhibin-B levels

In the MOSG group, both testosterone hormone and inhibin-B levels were significantly lower. In the QUR group, testosterone and inhibin-B levels were significantly higher. The administration of QUR to MOSG resulted in a considerable increase in both testosterone and inhibin-B levels (Table 4).

Plasma 8-hydroxydeoxyguanosine (8-OHDG) level

The 8-OHDG level was elevated markedly in the MOSG treated group (Fig.2). Administration of QUR after MOSG, significantly decreased 8-OHDG levels of activity, thus QUR enhance the reproductive capacities (Fig.2).

TABLE 4. Effect of MOSG or QUR and their combination on testosterone and inhibin B levels of male rats

Parameters	Control	MOSG (60 mg/g)	QUR (20 mg/kg)	MOSG and QUR
Testosterone (µIU/mL)	2.63±0.72 ^b	0.41±0.17 ^d	2.75±0.84 ^{ab}	1.99±0.54 ^c
Inhibin-B (ng/ml)	0.75±0.41 ^a	0.18±0.08 ^c	0.72±0.15 ^a	0.36±0.05 ^b

Means in each category (mean ±SE) carrying different letters are significant at $P \leq 0.05$, the highest mean value has symbol (a) and decreasing alphabetically.

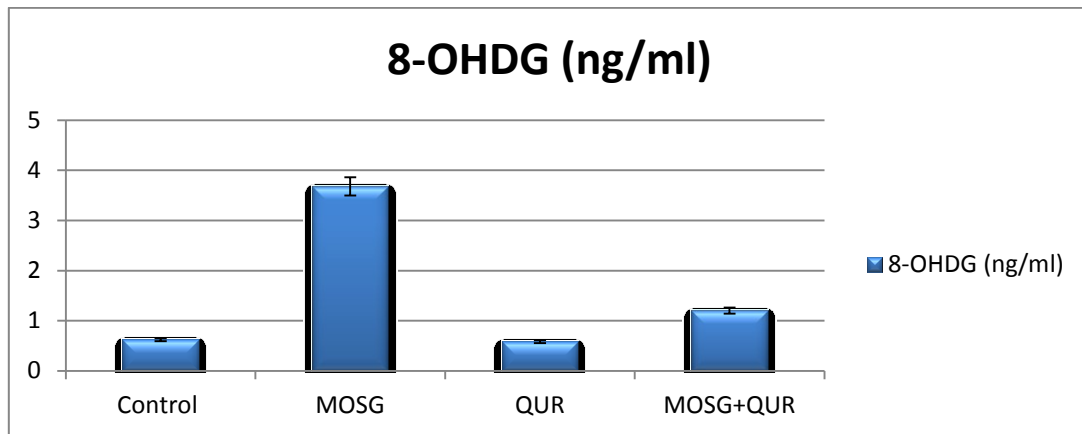


Fig. 2. Effect of MOSG and QUR on Plasma 8- hydroxydeoxyguanosine.

Comet assay

The comet analysis of testis tissues from the control group revealed intact nuclei with no tail (Fig. 4A). The MOSG-treated group had broken DNA strands with a comet-like head and a clear tail as a shadow area (Fig. 4C).The QUR-treated group had intact nuclei and DNA (Fig. 4B). MOSG plus

QUR improved DNA damage, resulting in a shorter tail and a low percentage of damaged DNA. Table 6 and Fig.3 revealed that the indices of apoptosis in the testis tissues were higher in the MOSG-treated group than in the control group. Meanwhile, a combination of MOSG and QUR therapy reduced DNA damage.

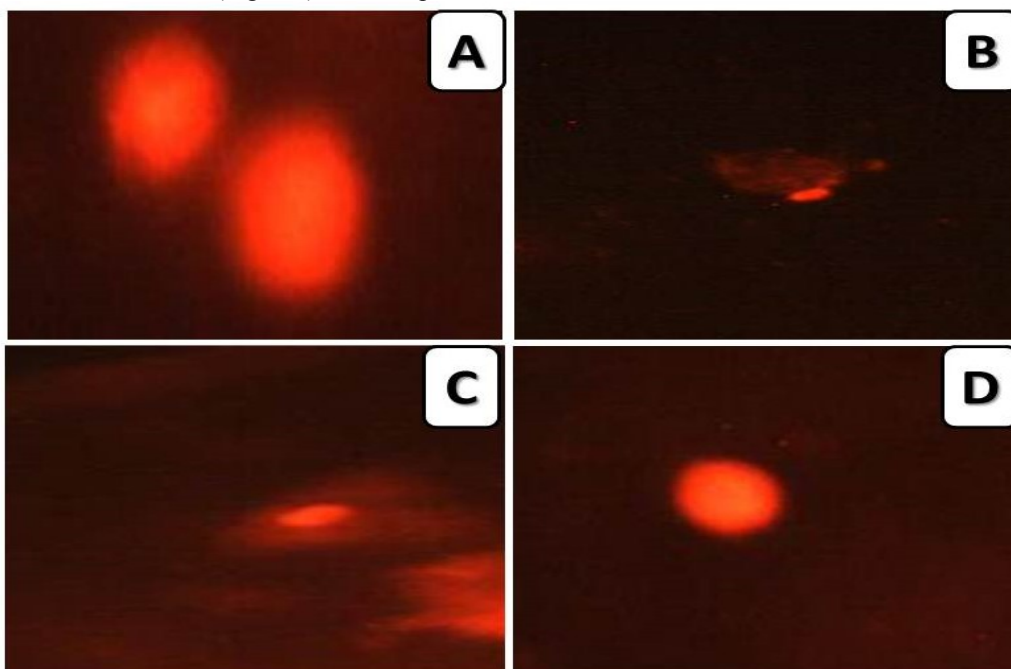
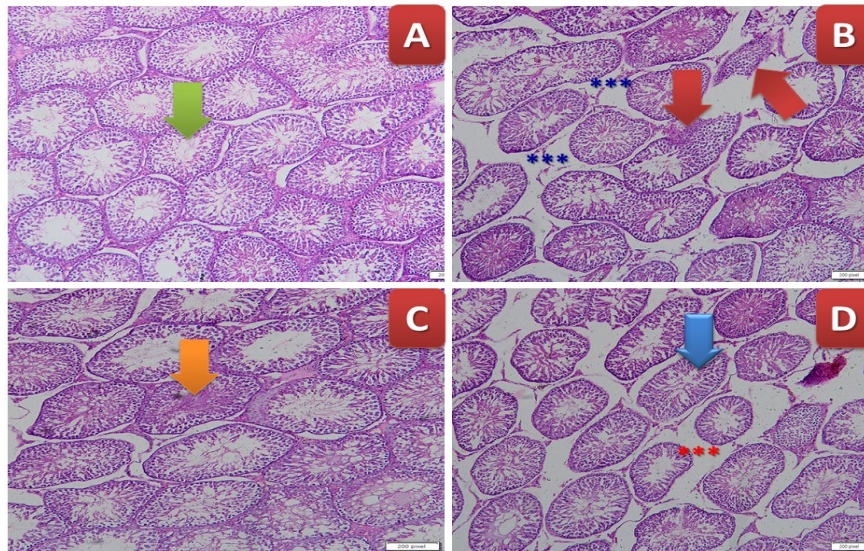
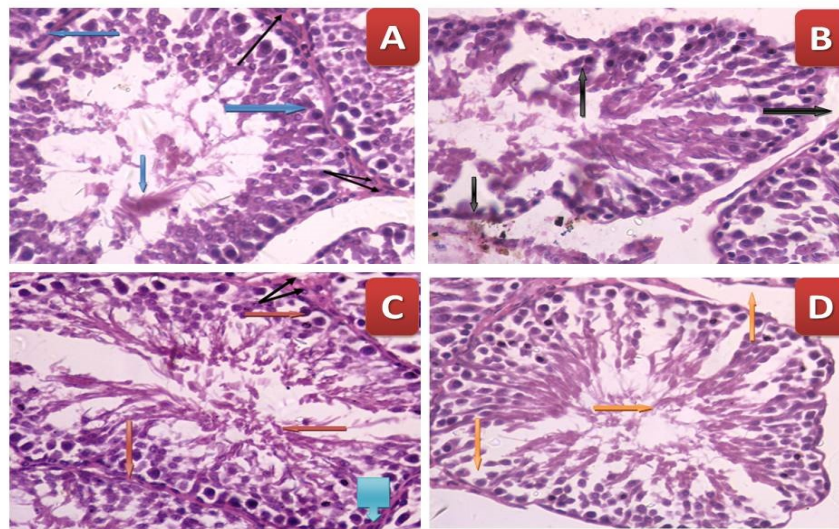


Fig.3 . Comet images of cells derived from liver of rat of group (A) control group which showed intact nuclei. (B) MOSG treated group which showed higher degree of damage with appearance of more than one apoptotic cells with large tail. (C) QUR treated group showed intact nuclei with undamaged DNA loop. (D) MOSG + QUR treated group showed amelioration of the recorded cells and less of percentage of damaged DNA and tail.



(A). Low magnification of testicular tissues of different treated groups



(B). Low magnification of testicular tissues of different treated groups

Fig.4 (A,B): Histopathological sections of the testes tissues (A) **control group** photomicrograph of cross section of experimental rat showing normal histological structure of seminiferous tubule and interstitial tissue (Blue Right side arrow). The seminiferous tubule consists of normal somatic sperms, and spermatogenic cells, surrounded by peritubularmyoid cells (thin black arrow), with collection of leydig cells in intertubular area (Double headed arrows) (H&Ex400) and appearance of normal seminiferous tubules (Green arrow) (H&EX100).

(B) **MOSG treated group** showing the seminiferous tubule contain some normal somatic sperms and showing toxicity in the form of degenerative changes of germ cells, expansion of interstitial space (Downward arrow) and disarrangement of spermatogonia with cellular debris (Upward arrow), with derangement of normal contour of the seminiferous tubule and loss of peritubularmyoid cells (H&Ex400), appearance of clear edema (Blue asterisks) and distortion of seminiferous tubules (Red arrow) (H&EX100).

(C) **QUR treated group** showing normal histological structure of seminiferous tubule and interstitial tissue (Orange right sided arrow). The seminiferous tubule consists of normal somatic sperms (Orange left sided arrow), and spermatogenic cells (Orange downward arrow), surrounded by peritubularmyoid cells (Blue wide arrow), with collection of leydig cells in intertubular area (Double headed arrow) (H&Ex400), appearance of normal seminiferous tubules filled with sperms (Orange arrow) (H&EX100).

(D) **MOSG + QUR treated group** showing very mild toxicity in the form of disarrangement and loss of some spermatogenic cells (Orange downward arrow), presence of normal somatic sperms (Orange right sided arrow), thinning and loss of interstitial tissue and loss of peritubularmyoid cells , resulting in expansion of the interstitial space (Orange downward arrow) (H&Ex400) , appearance of very mild edema (Red asterisks) and normal appearance of seminiferous tubules (Blue arrow) (H&EX100).

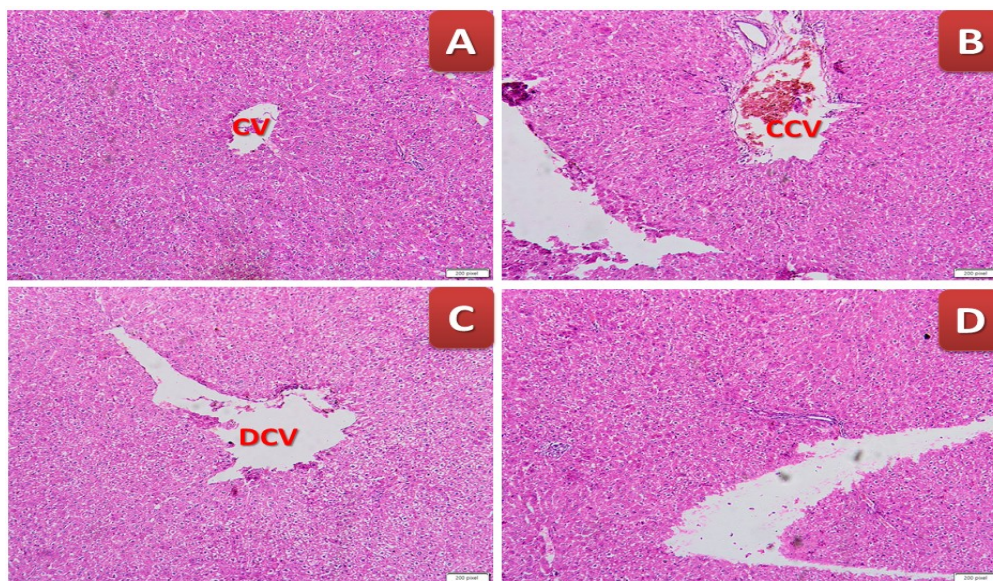
Histopathology evaluation of liver and testis tissues

The testicular tissues (A) Control group showing normal histological structure of seminiferous tubule and interstitial tissue. The seminiferous tubule consists of normal somatic sperms, and spermatogenic cells, surrounded by peritubularmyoid cells. (B) MOSG treated group showing the seminiferous tubule contain some normal somatic sperms and showing toxicity in the form of degenerative changes of germ cells. (C) QUR treated group showing normal histological structure of seminiferous tubule and interstitial tissue. The seminiferous tubule consists of normal somatic sperms. (D) MOSG + QUR treated group showing very mild toxicity in the form of disarrangement and loss of some spermatogenic cells, presence of normal somatic sperms, resulting in expansion of the interstitial space.

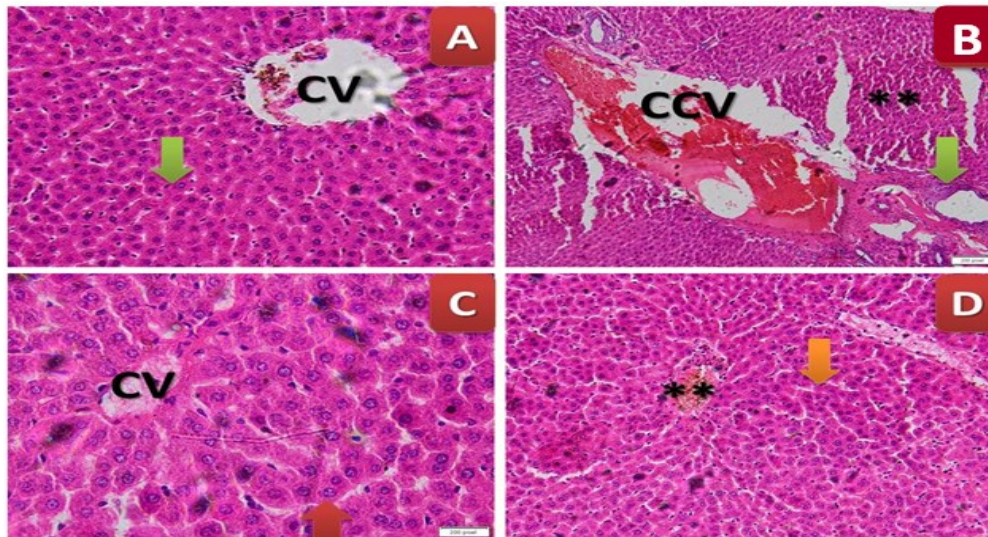
The hepatic tissues of different treated groups (A) Control group of rat liver showing normal

histological architecture with normal hepatocytes. (B) MOSG treated group showing severe hepatotoxicity in the form of hypertrophy of hepatocytes with increased eosinophilia, granular cytoplasm and vesicular nuclei, with moderate accumulation of hemorrhage inside it with congested central vein. (C) QUR treated group showing almost normal hepatic structure with polygonal hepatocytes and normal architecture. (D) MOSG with QUR treatment group demonstrates nearly normal hepatocellular structure with normal cytoplasm and central vein.

The histological index was evaluated based on the degree of microscopic features in the testis tissues as an effect of MOSG and QUR alone or in combination (Table.5). A significant lesion and inflammation was noticed in MOSG treated group as compared with the normal control group. A marked improvement in the testicular scores were observed in treated group with QUR, thus showing its amelioration effect.



(A): Low magnification of hepatic tissues of different treated groups.



(B). High magnification of hepatic tissues of different treated groups.

Fig.5 (A,B) .(A) Control group cross section of rat liver showing normal histological architecture with normal hepatocytes (H&E X400) and appearance of normal central vein (CV) (H&E X100). **(B) MOSG treated group** cross section of experimental rat liver showing severe toxicity in the form of hypertrophy of hepatocytes with appearance of binucleated hepatocytes and increased eosinophilia, granular cytoplasm and vesicular nuclei (**), there is dilatation of the central vein with moderate accumulation of hemorrhage inside it with congested central vein (CCV), focal necrosis in some hepatocytes with increased eosinophilia and nuclear disappearance (**), and appearance of Mallory-Denk hyalinized structure (Green arrow) (H&E X100) and (H&E X400). **(C) QUR treated group** showing almost normal hepatic structure with polygonal hepatocytes and normal architecture (H&E X400) and in low power appearance of some dilated central vein (DCV) (H&E X100) . **(D) MOSG plus QUR** treated group showing restoration of almost normal hepatocellular structure (Orange arrow) with normal cytoplasm and central vein (**)(H&E X400) and normal hepatocytes (H&E X100).

TABLE 5. Histological scoring index was evaluated based on the degree of microscopic alterations in testis tissues and the effect of QUR and MOSG.

Findings	Groups			
	Control	MOSG	QUR	MOSG + QUR
Maturation arrest	---	++	---	+-
layers of spermatogenic cells	+++	---	+++	++-
Few spermatids (azospermia)	---	+++	---	+-
Normal seminiferous tubules	+++	---	+++	++-
Ruptured seminiferous tubules	---	+++	---	+-

– No effect; --+ mild lesions found in 3 rats; +- moderate lesions found in 6 rats; ++-high moderate lesions found in 8 rats , +++ Severe lesions found in 9 rats at least (n=8).

TABLE 6. The effect on DNA damage level and (apoptosis %) in the testis of rat treated with MOSG and QUR

Group	Tail Length (px)	% DNA in Tail	Tail Moment (Unit)	Apoptosis %
Control group	2.10 ± 0.18 ^d	1.57 ± 0.26 ^d	0.26 ± 0.08 ^c	7.53 ± 1.01 ^c
MOSG	12.82 ± 1.07 ^a	25.67 ± 2.74 ^a	8.73 ± 1.67 ^a	84.07 ± 4.32 ^a
QUR	3.04 ± 0.25 ^c	2.02 ± 0.57 ^{cd}	0.25 ± 0.17 ^c	7.41 ± 1.79 ^c
MOSG+QUR	4.06 ± 1.08 ^{bc}	5.22 ± 1.17 ^b	1.98 ± 0.24 ^b	12.51 ± 2.14 ^b

Means in each category (mean ±SE) carrying different letters are significant at $P \leq 0.05$, the highest mean value has symbol decreasing alphabetically.

Discussion

MOSG is a well-known flavor enhancer worldwide. Active polyphenolic compounds such as QUR has potent antioxidant activity against toxicity and tissues damage injuries. The current study was assessed to evaluate the biochemical parameters, histopathological examination of liver and testis tissues, and genotoxicity changes after administration of MOSG and QUR either alone or in combination, as well as to clarify the genotoxicity of MOSG, to confirm that QUR has an antioxidant effect on MOSG-induced hepatic and testicular damage.

The mechanism of action of QUR against toxicity induced by polyphenols has been attributed to its antioxidant action resulting in the inhibition of process of oxidation [40].

The negative consequences of MOSG toxicity may be attributed to an inefficiency of leptin hormone in interacting with its receptors [41], which results in an increase in blood leptin hormone. The leptin hormone is strongly linked to fat accumulation in the human body [42].

This process causes adipose tissue build up and, as a result, hyperleptinemia. This appears to be the most common cause of hepatic metabolism problems.

All previous studies have shown that free radicals react with protein thiol (TH) to activate a variety of oxidation activities, including cellular absorption of triglycerides from the bloodstream [43]. This study provides a plausible explanation for the rise in blood total cholesterol, triglycerides, LDL-c, and vLDL-c levels in the MOSG-treated group. Furthermore, antioxidant activities (SOD, CAT, GPx, MPO, and XO) may be inversely associated to leptin hormone and thus decreased in the MOSG-treated group.

On the contrary, QUR administration elevated the antioxidant enzymes : SOD, CAT and GPx activities in MOSG-treated rats. It has been greatly afforded that QUR has a potent antioxidant activity by scavenging of free radicals after transporting into the cellular lipid membranes or by enhancing the antioxidant enzyme activities [44].

The current data greatly enhance the concept that QUR act as potent antioxidant by increasing antioxidant enzymes as SOD, CAT and GPx activities and significantly alleviated the toxicity of MOSG treated group, may be due to elevated H₂O₂ concentration [45].

The combination of MOSG and QUR elevated GPx activity as compared to male rats given only MOSG. This may be due to ability of QUR as a flavonoid to greatly change the cellular redox state.

QUR protects hepatic tissues and improves hepatic functioning [44].

SOD and reactive oxygen species play a dual role. At the physiological balance level, they are necessary for cell signalling, and at the pathological alteration levels they are considered harmful, as they can induce apoptosis, necrosis, and cellular death [46] and this add strength point to the current results that confirmed that QUR induced potent antioxidant activities and record high SOD levels.

MOSG-afforded metabolic mechanism alterations which may result in hepatic and testicular damages by elevating of liver enzymes ALT and AST activities, as mentioned previously by Yousef *et al.* [47]. Alteration in liver enzymes ALT and AST activities are associated with pathological mechanisms that greatly affect the cellular membrane's integrity causing highly selective membrane permeability.

Additionally, severe oxidative stress resulting from exposure to MOSG could lead to induction of DNA damage either in liver or testis tissues. This is in a great consistency with the obtained current results, treatment with MOSG induced DNA damage, as previously demonstrated a lot of literatures [18].

Because DNA damage is thought to be caused by severe oxidative stress, it is the most bio-monitoring metric of the QUR's impact on antioxidant status [48]. This comet assay is extensively used for assessing DNA damage and oxidative stress [49], and this was corroborated by increased 8-OHDG levels in MOSG-treated animals, which was accompanied by DNA strand breakage and the development of long tails with a high percentage of DNA damage.

Oxidative stress is a type of imbalance in oxidant/antioxidant equilibrium that can lead to a variety of disorders. A variety of human disorders have been linked to high levels of protein carbonyl (CO), including diabetes, Alzheimer's disease, rheumatoid arthritis, and respiratory syndromes. Because of the relative early formation and relative stability of carbonylated proteins, the protein CO is considered a marked oxidative stress biomarker and thus aids in the discovery of early oxidative stress cases and triggered free radicals, as well as taking steps to alleviate this oxidative stress [50].

Histopathology testing demonstrated significant improvements in the architecture of both the liver and testis tissues with QUR treatment when compared to MOSG treatment. These findings are consistent with those of Hamza and Diab [16], who observed that MOSG therapy was associated with sperm decrease. In the same context, recent research indicated that MOSG in combination with

QUR provided a significant improvement in spermatogenic state, confirming the robust antioxidant powers of QUR in mitigating the reproductive toxicity provided by MOSG.

The current histological results of testicular tissues were strongly approved by Alalwani.[51], who provide deformations of the spermatogenic layers with significant loss of interstitial cells, as well as cellular infiltration of the MOSG group, as supported by the observed histological structures.

Apoptosis status is described as the programmed cellular death which is characterized by cellular alterations that afford the cells to commit suicides [52]. An altered apoptotic process has been clearly observed in MOSG treated group.

QUR has a potent protective antioxidant activities on both hepatic tissues and testicular tissues. The hepatic and testicular sections in the QUR treated group showed normal hepatic and testicular structures and in the combination group of both MOSG and QUR , QUR greatly alleviated the inflammation and degenerative marks induced by MOSG treatment.

In the present study, QUR afforded a potent ameliorative effect against MOSG. This potent ameliorative effect may be due to the potent antioxidant effect of QUR and may be due to retardation of MOSG absorption in the gastrointestinal tract [53]. QUR may prevent oxidative damage to lipid cellular membranes and amelioration of the cellular membranes from this severe damage induced by the oxidative injury.

Conclusion

MOSG elevated significantly the oxidative damage in both liver and testes tissues and thus afforded deformation and disruption of their histological architecture, biochemical biomarkers and reduction of the sperm number and their quality. MOSG declined the levels of antioxidant enzymes and enhanced the marker of lipid peroxidation (MDA). The obtained results confirmed that QUR has an ameliorative key role against MOSG-induced toxicity. QUR enhanced the biochemical hepatic and testicular parameters in parallel with the improvement of hepatic and testicular structures and alleviation of DNA genotoxicity.

Conflict of interest

The author declares that there are no conflict of interest.

Acknowledgement

The researchers would like to acknowledge Deanship of Scientific Research, Taif University for funding this work.

Author's contribution

Safa H. Qahl , Reham Z. Hamza: Conceived and designed the experiments; Performed the experiments; Analyzed and interpreted the data; Contributed reagents, materials, analysis tools or data; Wrote the paper.

References

1. Furst, P. and Stehle, P. What are the essential elements needed for the determination of amino acid requirements in humans?. *J. Nutr.*, **34**, 1558–1565 (2004).
2. Farombi, E.O. and Onyema, O.O. Monosodium glutamate-induced oxidative damage and genotoxicity in the rat: modulatory role of vitamin C, vitamin E and quercetin. *Hum. Exp. Toxicol.*, **125**, 251–259 (2006).
3. Geha, R., Beiser, A., Ren, C., Patterson, R., Grammer, L. and Ditto, A. Review of allergic reaction to monosodium glutamate and outcome of a multicenter double blind placebo-controlled study. *J. Nutr.*, **130**, 1032S–1038S (2001).
4. Shi, Z., Yuan, B., Taylor, A.W., Dai, Y., Pan, X. and Gill, T.K. Monosodium glutamate is related to a higher increase in blood pressure over 5 years: findings from the Jiangsu Nutrition Study of Chinese adults. *J. Hypertens.*, **29**, 846-853 (2011).
5. Rogerio, A.P.,Dora,C.L., Andrade,E.L., Chaves, J.S., Silva, L.F.C., Lemos-Senna, E., Calixto, J.B. Anti-inflammatory effect of quercetin-loaded microemulsion in the airways allergic inflammatory model in mice. *Pharmacol. Res.*, **61**, 288–297 (2010).
6. Kumbhare, V., Gajbe, U., Singh, B.R., Reddy, A.K. and Shukla, S. Histological and histochemical changes in liver of adult rats treated with monosodium glutamate: a light microscopic study. *World J. Pharm. Sci.*, **4**, 898911 (2015).
7. Abdul-Hamid, M., Galaly, S.R., Ahmed, R.R. and Hamdalla, H.M. Histopathological and biochemical effect of quercetin on monosodium glutamate supplementation-induced testicular toxicity. *Beni-Suef Univ. J. Basic Appl. Sci.*, **10**, 73(2021).
8. Elatrash, A.M. and Abd El-Haleim, S.Z. Protective role of *ginkgo biloba* on monosodium glutamate:

- induced liver and kidney toxicity in rats. *Res. J. Pharma. Bio. Chem. Sci.*, **6(1)**, 1433 (2015).
9. Pavlovic, V., Pavlovic, D., Kocic, G., Sokolovic, D., Jevtovic-Stoimenov, T., Cekic, S. and Velickovic, D. Effect of monosodium glutamate on oxidative stress and apoptosis in rat thymus. *Mol. Cell Biochem.*, **303**(1–2), 161–166 (2007).
10. Kotb, S.M., El-Ghazouly, D. and Ameen, O. The potential cytoprotective effect of Vitamin C and Vitamin E on monosodium glutamate-induced testicular toxicity in rats. *Alex. J Med.*, **56**, 134–147 (2020).
11. Kayode, O.T., Rotimi, D.E., Kayode, A.A.A., Olaolu, T.D., and Ad eyemi, O.S. Monosodium Glutamate (MSG)-induced male reproductive dysfunction: a mini review. *Toxics*, **8**(1), 7 (2020).
12. Sakr, S.A. and Badaw, G.M. Protective effect of curcumin on monosodium glutamate-Induced reproductive toxicity in male albino rats. *Global Pharmacol. J.*, **7(4)**, 416–422 (2013).
13. Nayanatara, A., Vinodini, N., Damadar, G., Ahemed, B., Ramaswamy, C.S.M. and Bhat, M. Role of ascorbic acid in monosodium glutamate mediated effect on testicular weight sperm morphology and sperm count in rat testis. *J. Chin. Clin. Med.*, **3**, 1–5 (2008).
14. Nosseir, N.S., Ali, M.M. and Ebaid, H.M. A histological and morphometric study of monosodium glutamate toxic effect on testicular structure and potentiality of recovery in adult albino rat. *Res. J. Biol.*, **2(2)**, 66–78 (2012).
15. Hamza, R.Z. and AL-Harbi, M.S. Monosodium glutamate induced testicular toxicity and the possible ameliorative role of vitamin E or selenium in male rats. *Toxicology Reports*, **1**, 1037–1045 (2014).
16. Hamza, R.Z. and Diab, A.E.A. Testicular protective and antioxidant effects of selenium nanoparticles on Monosodium glutamate-induced testicular structure alterations in male mice. *Toxicology Reports*, **7**, 254–260 (2020).
17. Staroverov, S.A., Volkov, A.A., Larionov, S.V., Mezheny, P.V., Kozlov, S.V., Fomin, A.S. and Dykman, L.A. Study of transmissible gastroenteritis virus antigen conjugated immunogenic properties of selenium nanoparticles and gold. *Life Sci. J.*, **11** (11), 456–460 (2014).
18. Refat, M.S., Hamza, R.Z., Adam, A.M.A., Saad, H.A., Gobouri, A.A., Al-Harbi, F.S., Al-Salmi, F.A., Al-talhi, T. and El-Megharbel, S. Quercetin/Zinc complex and stem cells: A new drug therapy to ameliorate glycometabolic control and pulmonary dysfunction in diabetes mellitus: Structural characterization and genetic studies. *PLoS ONE*, **16(3)**, e0246265 (2021).
19. Igor, Y. I., Tatyana, N. P., Aleksander, A.A., Miguel, Â.A., Pinheiro, D.C., and Stanislay, G.R. Expression of Glutathione Peroxidase and Glutathione Reductase and Level of Free Radical Processes under Toxic Hepatitis in Rats. *J. Toxicol.*, 870628 (2013).
20. El-Megharbel, S.M., Al-Salmi, F.A., Al-Harhi, S., Alsolami, K. and Hamza, R.Z. Chitosan/selenium nanoparticles attenuate diclofenac sodium-induced testicular toxicity in male rats. *Crystals*, **11** (12), 1477 (2021).
21. Wach, A., Pyrzynska, K. and Biesaga, M. Quercetin content in some food and herbal samples. *Food Chem.*, **100**, 699–704 (2007).
22. Amália, P.M., Possa, M.N., Augusto, M.C., Francisca, L.S. Quercetin prevents oxidative stress in cirrhotic rats. *Dig. Dis. Sci.*, **52**, 2616–2621 (2007).
23. Gupta, S.C., Kismali, G. and Aggarwal, B.B. Curcumin, a component of turmeric: from farm to pharmacy. *Bio. Factors*. **39(1)**, 2–13 (2013).
24. Thie, D.G. and Crozier, A. Plant derived phenolic antioxidants. *Curr. Opin. Clin. Nutr. Metab.*, **3**, 447–451 (2000).
25. Casagrande, R., Georgetti, S.R., Verri, W.A., Dorta, D.J., dos Santos, A.C. and Fonseca, M.J. Protective effect of topical formulations containing quercetin against UVB-induced oxidative stress in hairless mice. *J. Photochem. Photobiol. B.*, **84**, 21–27 (2006).
26. Fuhrman, B. and Aviram, M. Flavonoids protect LDL from oxidation and attenuate atherosclerosis. *Curr. Opin. Lipidol.*, **12**, 41–48 (2001).
27. Farombi, E.O. and Onyema, O.O. Monosodium glutamate-induced oxidative damage and genotoxicity in the rat: modulatory role of vitamin C, vitamin E and quercetin. *Hum. Exp. Toxicol.*, **25(5)**, 251–259 (2006).
28. Hamza, R.Z. and Al-Baqami, N.M. Testicular protective effects of ellagic acid on monosodium glutamate-induced testicular structural alterations in male rats. *Ultrastructural Pathology*, **43** (4-5), 170-183 (2019).

29. Christine J. Weydert and Joseph, J. Cullen. Measurement of superoxide dismutase, Catalase, and Glutathione peroxidase in cultured cells and tissue. *Nat. Protoc.*, **5** (1), 51–66 (2010).
30. Hafeman, D.G., Sunde, R.A. and Hoekstra, W.G. Effect of dietary selenium on erythrocyte and liver glutathione peroxidase in the rat. *J. Nutr.*, **104**, 580–587 (1974).
31. Suzuki, K., Ota, H., Sasagawa, S., Sakatani, T. and Fujikura, T. Assay method for myeloperoxidase in human polymorphonuclear leukocytes. *Anal Biochem.*, **132**, 345–352 (1983).
32. Litwack, G., Bothwell, J.W., Williams, J.N. and Elvehjem, C.A. A colorimetric assay for xanthine oxide in rat liver homogenates. *J. Biol. Chem.* **200**, 303–310 (1953).
33. Hu, M.L. Measurement of protein thiol groups and glutathione in plasma. *Methods Enzymol.*, **233**, 380–385 (1994).
34. Weber, D., Michael, J., Davies, Tilman, G. Determination of protein carbonyls in plasma, cell extracts, tissue homogenates, isolated proteins: Focus on sample preparation and derivatization conditions. *Redox. Biol.*, **5**, 367–380 (2015).
35. Ohkawa, H., Ohishi, N. and Yagi, K. Assay for lipid peroxides in animal tissues by thiobarbituric acid reaction. *Anal Biochem.*, **95**, 351–358 (1970).
36. Wheeler, M.J. The determination of bio-available testosterone. *Ann. Clin. Biochem.* **32**, 345–357 (1995).
37. Gabe, M. (1968). *Techniques histologiques [Histological Techniques]*. Paris: Masson Publisher.
38. Collins, A.R. The comet assay for DNA damage and repair: principles, applications, and limitations. *Mol. Biotechnol.*, **26**(3), 249–261 (2004).
39. Duncan, D.B. Multiple range and multiple F-test. *Biometrics*, **11**, 1–42 (1955).
40. Rivera, L., Morón, R., Sánchez, M., Zarzuelo, A. and Galisteo, M. Quercetin ameliorates metabolic syndrome and improves the inflammatory status in obese Zucker rats. *Obesity*, **16**, 2081–2087 (2008).
41. Afifi, M.M. and Abbas, A.M. Monosodium glutamate versus diet induced obesity in pregnant rats and their offspring. *Acta Physiol. Hung.*, **98**, 177–188 (2011).
42. Wein, S., Behm, N., Petersen, R.K., Kristiansen, K., Wolfram, S. Quercetin enhances adiponectin secretion by a PPAR-gamma independent mechanism. *Eur. J. Pharm. Sci.*, **41**, 16–22 (2010).
43. Chen, K., Thomas, S.R., and Keaney, J.F. Beyond LDL oxidation: ROS in vascular signal transduction. *Free Radic. Biol. Med.*, **35** (2), 117–132 (2003).
44. Vieira, E.K., Bona, S., Di Naso, F.C., Porawski, M., Tieppo, J. and Marroni, N.P. Quercetin treatment ameliorates systemic oxidative stress in cirrhotic rats. *ISRN Gastroenterol.*, 1–6 (2011).
45. Myhrstad, M.C., Carlsen, H., Nordstrom, O., Blomhoff, R. and Moskaug, J.J. Flavonoids increase the intracellular glutathione level by transactivation of the gamma-glutamylcysteine synthetase catalytic subunit promoter. *Free Radic. Biol. Med.*, **32**, 386–393 (2002).
46. Celia, M.C.A., José, M.P.L., Celia, A.J., Francisco, J.P. and Pérez-Lebeña, E. Superoxide Anion Chemistry—Its Role at the Core of the Innate Immunity. *Int. J. Mol. Sci.*, **24**(3), 1841(2023).
47. Yousef, M.I., Omar, S.A., El-Guendi, M.I. and Abdelmegid, L.A. Potential protective effects of quercetin and curcumin on paracetamol-induced histological changes, oxidative stress, impaired liver and kidney functions and haematotoxicity in rat. *Food. Chem. Toxicol.*, **48**, 3246–3261 (2010).
48. Nandhakumar, S., Parasuraman, S., Shanmugam, M.M., Rao, K.R., Chand, P. and Bhat, B.V. Evaluation of DNA damage using single-cell gel electrophoresis (Comet Assay). *J. Pharmacol. Pharmacother.*, **2**(2), 107–11 (2011).
49. Simon, L., Brunborg, G., Stevenson, M., Lutton, D., McManus, J. and Lewis, S.E. Clinical significance of sperm DNA damage in assisted reproduction outcome. *Hum. Reprod.*, **25** (7), 1594–1608 (2010).
50. Dalle-Donne, I., Rossi, R., Giustarini, D., Milzani, A. and Colombo, R. Protein carbonyl groups as biomarkers of oxidative stress. *Clin. Chim. Acta.*, **329**(1–2), 23–38 (2003).
51. Alalwani, D.A. Monosodium glutamate induced testicular lesions in rats (histological study), Middle East Fertil. Soc. *J. Middle East Fertility Society Journal*, **19**(4), 274–280 (2014).
52. Vaux, D.L. and Flavell, R.A. Apoptosis genes and autoimmunity. *Curr. Opin. Immunol.*, **12**, 719–724 (2000).
53. Gupta, S., Gupta, H.K. and Soni, J. Effect of vitamin E and selenium supplementation on concentrations of plasma cortisol and erythrocyte lipid peroxides and the incidence of retinal fetal membranes in crossbred dairy cattle. *Theriogenology*, **64**, 1273–1286 (2005).

الكيرستين يحسن بنية الكبد ووظيفته، ويخفف من تلف الخصية ويخفف من الإجهاد التأكسدي الناجم عن جلوتامات أحادية الصوديوم في ذكور الجرذان

صفاء قحل¹ وريهام حمزه²

¹ قسم الأحياء، كلية العلوم، جامعة جدة، ص.ب. ص.ب. ٨٠٣٢٧، جدة ٢١٥٨٩، المملكة العربية السعودية.

² قسم الأحياء، كلية العلوم، جامعة الطائف، ص.ب. ص.ب. ١١٠٩٩، الطائف ٢١٩٤٤، المملكة العربية السعودية.

تعتبر مادة الكيرستين (QR) عامل قوي لإزالة الشوارد الحرة وتمتلك هذه المادة تأثيرات قوية مضادة للأكسدة. مادة جلوتامات الصوديوم الأحادية (MOSG) هي مادة مُحسّنة للنكهة ولكن لها العديد من الآثار الجانبية على العديد من الأعضاء والأنسجة كما هو مذكور في العديد من الدراسات السابقة. تهدف الدراسة الحالية إلى تقييم التأثيرات الوقائية المضادة للأكسدة لمادة الكيرستين على الكبد والخصية ضد الإجهاد التأكسدي والسمية الكبدية وتلف الخصية الناجم عن إعطاء مادة جلوتامات الصوديوم الأحادية. تمت الدراسة على عدد ٤٠ من ذكور الفئران وتم تقسيمهم إلى ٤ مجموعات: المجموعة الأولى المعالجة بمحلول ملحي طبيعي (مجموعة ضابطة)، المجموعة الثانية المعالجة بمادة جلوتامات الصوديوم الأحادية، المجموعة الثالثة المعالجة بمادة الكيرستين، المجموعة الرابعة المعالجة بمزيج من مادة جلوتامات الصوديوم الأحادية والكيرستين. تم تقييم المؤشرات الحيوية المضادة للأكسدة إنزيم السوبر أوكسيد ديسميوتاز، إنزيم الحلوتاثيون بير أوكسيداز، إنزيم الكاتاليز، إنزيم الميلوبير أوكسيداز، إنزيم الزانزين أوكسيداز، الثيول والكاربونيل ومؤشر الأكسدة الفوقية للدهون (المالون داي ألدهيد) في المستخلص النسيجي للكبد. تم قياس نسبة هرمون الذكورة، هرمون التستوستيرون، وتم قياس نسبة انهيبين-B وعامل هيدروكسي دي أوكسي جوانسين وهو علامة على تلف الحمض النووي. تم فحص التركيب النسيجي للخصيتين والكبد وتسجيل التباين النسيجي كمؤشر على تلف الخصية والكبد بعد تناول أحادي جلوتامات الصوديوم إما منفرداً أو بالإضافة للكيرستين وتقييم التأثيرات المضادة للأكسدة لمادة الكيرستين. إلى جانب ذلك، تم إجراء تحليل فحص المذنب لأنسجة الخصية لتقييم تلف الحمض النووي. أدى إعطاء الكيرستين متزامنة مع مادة جلوتامات الصوديوم الأحادية إلى زيادة كبيرة في مضادات الأكسدة الأنزيمية وخفض مؤشر الأكسدة الفوقية للدهون وعلامات تلف الحمض النووي مقارنة مع المجموعة المعالجة بجلوتامات الصوديوم الأحادية منفرداً. أدى إعطاء مادة الكيرستين إلى زيادة مستوى هرمون التستوستيرون وتحسين البنية النسيجية لكل من الخصية والكبد. ويمكن الاستنتاج بأن مادة الكيرستين تمنع تلف الكبد والخصية وتحسن قدرات الإنزيمات المضادة للأكسدة وتخفف من تلف الحمض النووي في ذكور الجرذان التجريبية.

كلمات مفتاحية: الإجهاد التأكسدي، كيرستين، جلوتامات أحادية الصوديوم، مضادات الأكسدة، تلف الحمض النووي.