

PREDICTION OF LIVER FIBROSIS IN CHRONIC LIVER DISEASED CHILDREN BY USING TISSUE FIBRONECTIN AND TRANSIENT ELASTOGRAPHY

By

Shireen Rashad Ghallab*, **Esaad Mohammed Menazie¹**, **Hanaa Ahmed El- Araby²**,
Osama Lofty El-Abd², **Marwa El-Hady Abd El-Moniem¹** and **Dina Mohammed Sweed²**

¹Department of Pediatrics, Faculty of Medicine, Al-Azhar University (For Girls), Cairo, Egypt

²National Liver Institute, Menoufia University, Menoufia, Egypt

*Department of Pediatrics, Damanhur Teaching Hospital, Damanhur, Behira, Egypt

Corresponding author: Shireen Rashad Soliman Ghallab,

Mobile: (+02) 01152303029, **E-mail:** shireenrashad@yahoo.com

ABSTRACT

Background: *Chronic liver diseases are important causes of morbidity and mortality due to progressive fibrosis. Liver biopsy used for diagnosis of fibrosis but is invasive. Transient elastography is painless, rapid, and non-invasive and can be done in outpatient setting.*

Aim: *Our objective is evaluating the role of tissue fibronectin to assess the degree of fibrosis in children with chronic liver diseases in comparison with transient elastography.*

Patients and Methods: *This was a cross sectional study done on 60 children aged from 2months to 18 years with chronic liver diseases from National Liver Institute, menoufia university during the period from January 2020 to November 2021 where transient elastography was performed for them at the same time with needle liver biopsy.*

This study included children with; children with autoimmune hepatitis, children with chronic virus infection; children with congenital hepatic malformation as well as children with Wilson disease, while children with severe ascites and those with morbid obesity were excluded from the study.

All children will be subjected to the following: Full history taking, thorough clinical examination; full investigation; fibronectin hepatocyte score and transient elastography.

Results: *Our results found good correlation between fibronectin hepatocyte score and the degree of fibrosis diagnosed by transient elastography in advanced stages of liver diseases. Among our studied children the high fibronectin hepatocyte score was*

detected in children with grade 4 fibrosis followed by grade 3 fibrosis suggesting significant association between severity of fibrosis and elevated scores.

Conclusion: From our study we can conclude that transient elastography is a bedside test and it is preferred over invasive hepatic fibronectin score and liver biopsy in detecting degree of liver fibrosis in children with chronic liver diseases. So, we recommend it for follow up of the cases instead of liver biopsy.

Key words: Chronic liver disease, hepatic tissue fibronectin, transient elastography, liver biopsy.

INTRODUCTION

Chronic liver diseases is characterized by progressive fibrosis caused by repeated injury due to either metabolic dysfunction, alcohol abuse, viral hepatitis, or autoimmune disease that represent a significant cause of morbidity and mortality worldwide (**Pokorska-Śpiewak et al., 2015**).

Accurate assessment of fibrosis stage and early detection of cirrhosis are vital for determining prognosis and guiding management (**Motola et al., 2014**).

At the cellular level, an imbalance occurs between extracellular matrix (ECM) synthesis and degradation resulting in fibrosis and eventual cirrhosis of the liver (**Pokorska-Śpiewak et al., 2017**).

Fibrosis is characterized by excess deposition of extracellular matrix (ECM) components including different collagens and non-collagenous proteins such as

laminin, fibronectin, undulin, and so on. The key cellular mediator of fibrosis is the hepatic stellate cells (HSCs) which when activated serve as the primary collagen-producing cell. Liver biopsy has been the gold standard in diagnosing and staging liver fibrosis and also has the advantage of assessing other disease aspects including inflammation, steatosis and necrosis (**Pokorska-Śpiewak et al., 2017**).

According to the recent recommendations of the European Association for the Study of the Liver (EASL), noninvasive methods can be used instead of liver biopsy to assess liver disease severity prior to therapy, and liver biopsy should be reserved only for cases with potential additional comorbidities or any uncertainty (**European Association for the Study of the Live, 2018**).

The serum biomarkers for detection of fibrosis include both direct and indirect markers which reflect the removal or deposition of extracellular matrix in the liver.

Indirect markers can be identified in routine blood tests and indicate alterations in liver function (**Lee et al., 2013**).

Fibronectin, which is produced by HSCs, is a multifunctional glycoprotein and ECM component that is present in the cell membrane and cytoplasm (**Mòdol et al., 2015**).

Fibronectin is associated with cell cycle progression, participates in cell adhesion and proliferation, and has an important role in fibrotic progression (**Kawelke et al., 2011; Liu et al., 2016**).

Fibronectin appears to have an important role in liver fibrogenesis, FN expression may be considered a critical factor mediating the long-term consequences of several chronic liver diseases (**Altrock et al., 2015; Liu et al., 2016**).

Transient elastography (TE) Fibroscan is painless, rapid, and can be performed in the outpatient setting. TE is the most studied noninvasive technique and rapid bedside method used to assess liver fibrosis by measuring liver stiffness (**Özkan et al., 2017**).

Transient elastography performance is low in patients with ascites or morbid obesity (**Behairy Bel et al., 2016**).

However, biopsy is often considered an “imperfect” gold standard since it suffers from intra/inter-observer variability and is associated with several complications (**Dezsófi et al., 2015**).

Therefore, efforts have been made to develop an alternative, noninvasive methods to liver biopsy, including imaging studies (elastography) and serum and tissue biomarkers (**Lewindon et al., 2016**).

PATIENTS AND METHODS

Ethical Consideration:

1. A written informed consent was obtained from patient or their legal guardians.
2. An approval by the local ethical committee was obtained before the study.
3. The authors declared no potential conflict of interest with respect to the research, authorship, and/ or publication of this article.
4. All the data of the patient and results of the study are confidential and the patients have the right to keep it.
5. The researcher explains the aim of the study to the patients.
6. Financial disclosure, the researcher declared that there is

no fund regarding the study publication.

Calculation of sample size:

Sample size estimation was done using the Epi info7 program for sample size calculation, with 0.05 alpha error, confidence interval of 0.95 and the power of the study 0.80.

Study design:

This is a cross sectional study, comprised 60 children aged from 2 months to 18 years with chronic liver diseases selected according to: History, Primary clinical diagnosis and investigations. They selected from liver institute Menoufia University during the period January 2020 to November 2021.

Inclusion criteria:

Children with chronic liver diseases including any of the following:

1. Children with autoimmune hepatitis.
2. Children with Congenital hepatic malformation. e.g.: congenital hepatic fibrosis, biliary atresia
3. Children with Inborn errors of metabolism. e.g.: Galactosemia.
4. Children with chronic hepatitis C virus infection.
5. Children with bilharziasis.

Exclusion criteria:

1. Children with ascites.
2. Children with morbid obesity.
3. Children with non-alcoholic fatty liver disease.
4. Children with acute liver insult.

Study procedure:

Clinico-laboratory data:

All children subjected to the following:

- Full history taking (Age, sex, family history, nutritional history, consanguinity, birth order).
- Full clinical examination (vital signs, anthropometric measurements, chest, heart, abdominal and extremities).
- Full investigation (CBC, AST, ALT, PT, PTT, INR, TSB, direct and indirect GGT and Alkaline phosphatase, stool analysis to diagnose bilharziasis, Eliza and PCR to diagnose HCV infection).

Transient elastography: an intercostal placed transmitter measures the velocity of elastic waves by pulse ultrasound that correlates with liver stiffness, i.e., fibrosis. An ultrasound transforming detector with oscillation source of medium amplitude and low frequency. It is a novel, rapid, and non-invasive

technique which measures liver stiffness. Briefly, this system is equipped with a probe consisting of an ultrasonic transducer mounted on the axis of a vibrator. A vibration of mild amplitude and low frequency is transmitted from the vibrator to the tissue by the transducer itself. This vibration induces an elastic shear wave which propagates through the tissue. In the meantime, pulse-echo ultrasonic acquisitions are performed to follow the propagation of the shear wave and measure its velocity, which is directly related to tissue stiffness (or elastic modulus). The harder the tissue, the faster the shear wave propagates

Liver biopsy:

Needle liver biopsy performed percutaneously using a Menghini needle (Hepafix kit 1.4 or 1.6 mm, Braun).

Histopathological reviewing:

- Hematoxlin and eosin (H&E) stained slides examined for histopathological evaluation of liver specimens including grade, stage of chronic hepatitis and the possible etiological cause purposed by the International Association for the Study of the Liver (IASL) (Desmet et al., 1994; Krishna, 2021).

- Masson trichrome (MT) stained slides examined to assess the stage of fibrosis (Cabibi et al., 2015).
- Immunohistochemical staining for fibronectin protein performed for each case on 4-5 μ m liver tissue sections on a positively charged slide according to the data sheet.

Statistical analysis:

Data were fed to the computer and analyzed using IBM SPSS software package version 20.0. (Armonk, NY: IBM Corp) Qualitative data were described using number and percent. Kolmogorov-Smirnov test. was used to verify the normality of distribution Quantitative data were described using range (minimum and maximum), mean, standard deviation, median and interquartile range (IQR). Significance of the obtained results was judged at the 5% level.

1. Kruskal Wallis test: For abnormally distributed quantitative variables, to compare between more than two studied groups, and Post Hoc (Dunn's multiple comparisons test) for pairwise comparisons.
2. Spearman coefficient: To correlate between two

distributed abnormally quantitative variables.

RESULTS

Table (1): Distribution of the studied cases according to demographic and clinical data (n=60)

Demographic Data	No.	%
Sex		
Male	28	46.7
Female	32	53.3
Age (years)		
Min. – Max.	0.19 – 17.0	
Mean \pm SD.	5.24 \pm 5.27	
Median (IQR)	3.0 (0.50 – 9.50)	
Symptoms		
Yellowish discoloration of sclera(jaundice)	33	55.0
Abdominal enlargement	37	61.7
Bleeding from nose	11	18.3
Change color of urine	38	63.3
Stool color		
Normal	46	76.7
Clay	14	23.3
Signs		
Jaundice	25	41.7
Hepatomegaly	37	61.7
Splenomegaly	29	48.3
Dark urine	21	35.0
Hypoglycemia	31	51.7
Clay color stool	12	20.0
Fever	1	1.7
Epistaxis	16	26.7
Intra cranial hemorrhage	2	3.3
Ascites	2	3.3

SD: Standard deviation

IQR: Inter quartile range

*Among our studied children 53.3% were females and 46.7% were males.

*The age ranged between 0.19 years to 17 years with median of three years.

*The commonest clinical presentation among our studied children was change in color of urine 63.3% followed by abdominal enlargement 61.7% then jaundice 55.0% and lastly bleeding from nose 18.3%.

*Regarding finding on clinical examination of our studied children the commonest finding was hepatomegaly 61.7%

followed by hypoglycemia 51.7% followed by splenomegaly 48.3% and jaundice 41.7%.

Table (2): Distribution of the studied cases according to Ultrasound (n=60)

Ultrasound	No.	%
Normal	24	40.0
Abnormal	36	60.0
Hepatomegaly	23	38.3
Splenomegaly	26	43.3
Cirrhotic liver	10	16.7

Among our studied children 60.0% has abnormal US. 43.3% showed splenomegaly 38.3%

showed hepatomegaly, while 16.7% showed cirrhotic liver.

Table (3): Relation between Fibronectin hepatocytes H score and Transient Elastography (Fibroscan) (n=60)

Fibroscan	N	Fibronectin hepatocytes H score			H	p
		Min. – Max.	Mean ± SD.	Median (IQR)		
F0	3	0.0 – 130.0	43.33 ^a ± 75.06	0.0(0.0–65.0)	18.983*	0.001*
F1	7	0.0 – 120.0	51.43 ^a ± 50.14	80.0 (0.0–80.0)		
F2	15	0.0 – 260.0	121.33 ^a ± 84.42	110.0 (65.0–170.0)		
F3	12	70.0 – 240.0	133.33 ^a ± 64.15	115.0 (75.0–190.0)		
F4	23	0.0 – 280.0	193.48 ± 78.89	200.0(165.0–250.0)		

SD: Standard deviation

IQR: Inter quartile range

H: H for Kruskal Wallis test

p: p value for comparing between the different fibroscan group

*: Statistically significant at $p \leq 0.05$

a: Sig. with F4

Among our studied children the high Fibronectin hepatocytes H score was detected in children with grade 4 fibrosis followed by

grade 3 fibrosis suggesting significant association between severity of fibrosis and elevated scores.

Table (4): Correlation between fibronectin hepatocytes H score and Transient Elastography (Fibroscan) (n=60)

	Fibronectin hepatocytes H score	
	r_s	p
Transient Elastography (Fibroscan)	0.552*	<0.001*

rs: Spearman coefficient

*: Statistically significant at $p \leq 0.05$

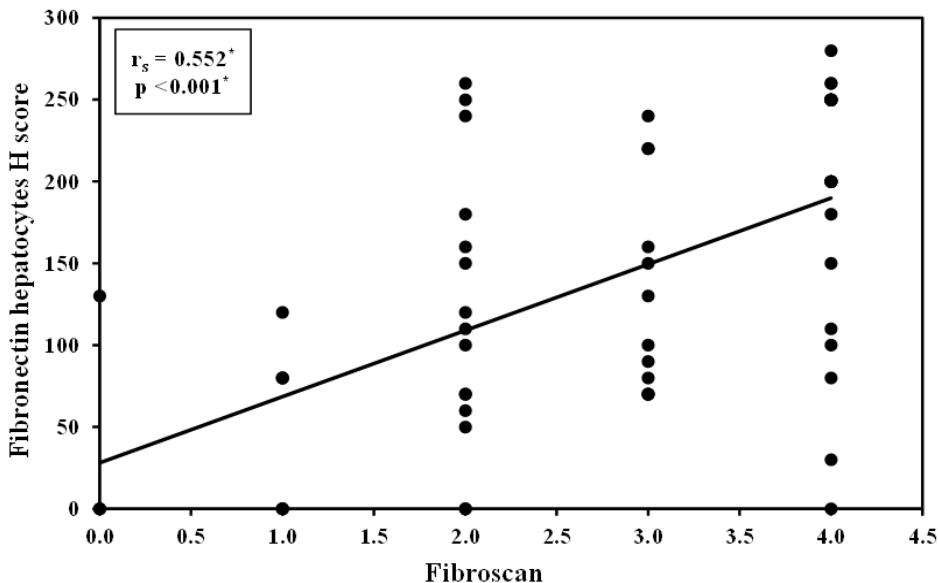


Figure (4): Correlation between fibronectin hepatocytes H score and Fibroscan (n=60).

There is significant correlation between fibronectin hepatocytes H score and fibrosis degree in our studied children by fibroscan., so we recommend

fibronectin hepatocyte H score as useful assessment tool for early detection of degree of fibrosis in chronic liver diseases in children.

DISCUSSION

After chronic liver injury, a sequence of pathological and physiological processes linked to liver cell necrosis and degeneration, which finally result in extracellular matrix and

collagen deposition resulting in liver fibrosis (Li et al., 2018).

The stage of liver fibrosis is the most important predictive factor for initiation and duration of antiviral treatment, where patients with early fibrosis stages respond

better to antiviral treatment with a higher sustained virologic response rate (**Ghafar et al., 2020**).

The biopsy is widely recognized as the gold standard for diagnosing and staging liver fibrosis. This approach, however, has some drawbacks, including the possibility of sampling variability, pain, and low-patient acceptance. Furthermore, it is still debatable whether a tissue diagnosis of liver fibrosis is needed. In cases of viral hepatitis, there are now an increasing number of effective noninvasive approaches that are widely used in clinical practice, resulting in a substantial reduction in the need for liver biopsy (**Li et al., 2018; Behairy et al., 2021**).

Fibronectin (FN) is a high-molecular-weight multi-functional glycoprotein

That plays a vitally important role during restoration of the liver tissue. Plasmatic fibronectin (pFN) is produced by hepatocytes, circulates in plasma in nonactive form, and during tissue damage becomes involved in the fibrin clots, taking effect on the function of thrombocytes and underlying hemostasis. Cellular FN (cFN) is synthesized by many types of cells, including fibroblasts, epithelial cells, endothelial cells, leukocytes, etc. It is collected by

cells when they migrate for restoration of the damaged tissue (**Dolhikh et al., 2020**).

Our results revealed that females were more commonly affected by chronic liver disease in pediatrics but without a significant difference. The age was in the normal mean of the pediatric age group.

Behairy and his colleagues, (2021), found in their study that Females are more commonly affected than males which was in agreement with what we found but the age runs in lines with what we found in our study (**Behairy et al., 2021**).

Abou-Taleb and his coworkers, (2019), found in their study that males were significantly affected by CLD which disagree with our study (**Abou-Taleb et al., 2019**).

In our study the common symptoms were change in the color of urine, followed by abdominal enlargement then yellowish discoloration of the sclera while the clay stool was no significantly present in cases of our study.

The above symptoms were in agree with what found by **Behairy and his colleagues, (2021)**, in their study (**Behairy et al., 2021**).

The most common clinical finding in our cases were abdominal mass "hepatomegaly or splenomegaly", then jaundice manifestations "dark urine, clay stool and/or tinged sclera", and the least finding were fever and complications "hemorrhagic complications and/or ascites"; hypoglycemia also was found in a good proportion of cases.

Behairy and his colleagues, (2021), found in their study that CLD presented commonly by jaundice, abdominal distension and clay color stool which was in agree with our results (**Behairy et al., 2021**).

Abou-Taleb and his coworkers, (2019), found in their study that the main presentation of cases were abdominal distension "due to abdominal mass; hepatomegaly and/or splenomegaly", manifestations of jaundice, clay stool and dark urine which agrees with what we found in our study (**Abou-Taleb et al., 2019**).

Behera and Murmu, (2018), found in their study that Pallor was present in 85% of patients. Icterus and Hepatomegaly were present in 70% of patients for each, splenomegaly in 47.5% of patients which was in agree with our results while they found Ascites in 65% and fever in 70%

of patients which disagree with our results (**Behera & Murmu, 2018**).

In our study, there was a positive correlation between fibroscan "transient elastography" diagnosis of fibrosis and the grade of fibrosis as it detects abdominal mass and cirrhotic changes in a significant percentage of cases.

Behairy and his colleagues, (2021), found that abdominal ultrasound revealed the presence of hepatomegaly in 80% of cases and splenomegaly in 30% of cases which run in lines with our findings (**Behairy et al., 2021**).

In our study, there was a positive correlation between fibronectin level of detection and hepatocytes H score of fibrosis.

Su and his coworkers, (2020), documented that immuno-histochemical analysis suggested that FN-EDA expression was significantly stronger in hepatic fibrotic tissues than in normal tissues (**Su et al., 2020**).

Dolhikh and his colleagues, (2020), found in their study that cellular FN significantly increased over inflammatory processes, namely chronic diffuse liver diseases of non-virulent etiology which run in lines with our findings (**Dolhikh et al., 2020**).

Ghafar and his coworkers, (2020), found in their study that level of fibronectin was elevated with fibrosis which was in agree with our results but without significance to differentiate the fibrosis stage which disagreed with our results (**Ghafar et al., 2020**). Also, **Liu and his colleagues, (2016)**, document in their study that FN have an early and critical role during the process of liver fibrogenesis without differentiation between the degree of fibrosis which disagree with our results (**Liu et al., 2016**).

Our results revealed that there were a significant association between elevated level of fibronectin and hepatocytes H-score with PFIC (progressive familial intra hepatic cholestasis) and biliary atresia, BUT both are elevated without significant association in cases of AIH (autoimmune hepatitis), glycogen storage disease, Wilson's disease, Bilharzial fibrosis and paucity.

CONCLUSIONS

As regarding giving nearly equal results by transient elastography and hepatocyte fibronectin H score in diagnosis of liver fibrosis in children with chronic liver diseases so transient elastography is superior to hepatocyte fibronectin H score as it is non-invasive, cheap and easy

to be performed without danger, The usage of transient elastography and hepatocyte fibronectin H score is more accurate for early detection of fibrosis in progressive familial intrahepatic cholestasis (PFIC), biliary atresia and autoimmune hepatitis ,Transient elastography for diagnosis of stages of liver fibrosis in children with chronic liver diseases is a bedside test and it is preferred over invasive hepatocyte fibronectin score and liver biopsy and can replace invasive liver biopsy in the follow up of the cases.

RECOMMENDATION

We recommend the use of transient elastography for diagnosis of stage of liver fibrosis in chronic liver diseases in children as bedside test as it is preferred over invasive fibronectin hepatocyte score.

LIMITATIONS OF THE STUDY

The first limitation was difficulty in doing transient elastography in preschool children due to lack of cooperation, narrow intercostal spaces in infants and it requires fasting. The second limitation was difficulty in doing liver biopsy in children with low platelets count less than 60000 and high INR values greater than 1.5 unless after correction.

REFERENCES

1. **Altrock, E, e Sens, C, Wuerfel, C, Vasel, M, Kawelke, N, Dooley, S, et al. (2015):** Inhibition of fibronectin deposition improves experimental liver fibrosis. *J Hepatol*, 62(3): 625-633.
2. **Behairy Bel, S, Sira, MM, Zalata, KR, Salama el, SE, & Abd-Allah, MA. (2016):** Transient elastography compared to liver biopsy and morphometry for predicting fibrosis in pediatric chronic liver disease: Does etiology matter? *World J Gastroenterol*, 22(16): 4238-4249.
3. **Cabibi, D, Bronte, F, Porcasi, R, Ingraio, S, Giannone, AG, Maida, M, et al. (2015):** Comparison of Histochemical Stainings in Evaluation of Liver Fibrosis and Correlation with Transient Elastography in Chronic Hepatitis. *Anal Cell Pathol (Amst)*, 2015: 431750.
4. **Cassinotto, C, Lapuyade, B, Mouries, A, Hiriart, JB, Vergniol, J, Gaye, D, et al. (2014):** Non-invasive assessment of liver fibrosis with impulse elastography: comparison of Supersonic Shear Imaging with ARFI and FibroScan®. *J Hepatol*, 61(3): 550-557.
5. **Desmet, VJ, Gerber, M, Hoofnagle, JH, Manns, M, & Scheuer, PJ. (1994):** Classification of chronic hepatitis: diagnosis, grading and staging. *Hepatology*, 19(6): 1513-1520.
6. **Dezsófi, A, Baumann, U, Dhawan, A, Durmaz, O, Fischler, B, Hadzic, N, et al. (2015):** Liver biopsy in children: position paper of the ESPGHAN Hepatology Committee. *J Pediatr Gastroenterol Nutr*, 60(3): 408-420.
7. **Dolhikh, H, Maslak, H, Didenko, V, Klenina, I, & Dolhikh, A. (2020):** Levels of isoforms of fibronectin and $\alpha 5/CD49e$ integrin on lymphocytes and in blood plasma in the conditions of chronic diffuse liver diseases. *Regulatory Mechanisms in Biosystems*, 11(4): 475-482.
8. **European Association for the Study of the Live. (2018):** EASL Clinical Practice Guidelines for the management of patients with decompensated cirrhosis. *J Hepatol*, 1: 1-55.
9. **Kawelke, N, Vasel, M, Sens, C, Au, A, Dooley, S, & Nakchbandi, IA. (2011):** Fibronectin protects from excessive liver fibrosis by modulating the availability of and responsiveness of stellate cells to active TGF- β . *PLoS One*, 6(11): e28181.
10. **Kliegman, RM, & Geme, J. (2020):** Reference Intervals for Laboratory Tests and Procedures. In: Kliegman, R (Ed.), *Nelson Textbook of Pediatrics, 2-Volume Set (NelsonPediatrics)*. 20st ed. Maryland: Johns Hopkins. p.p. 2466.
11. **Krishna, M. (2021):** Histological Grading and Staging of Chronic Hepatitis. *Clin Liver Dis (Hoboken)*, 17(4): 222-226.
12. **Lee, CK, Perez-Atayde, AR, Mitchell, PD, Raza, R, Afdhal, NH, & Jonas, MM. (2013):** Serum biomarkers and transient elastography as predictors of advanced liver fibrosis in a United States cohort: the Boston children's hospital experience. *J Pediatr*,

- 163(4): 1058-1064.
13. **Lewindon, PJ, Balouch, F, Pereira, TN, Puertolas-Lopez, MV, Noble, C, Wixey, JA, et al. (2016):** Transient liver elastography in unsedated control children: Impact of age and intercurrent illness. *J Paediatr Child Health*, 52(6): 637-642.
 14. **Li, C, Li, R, & Zhang, W. (2018):** Progress in non-invasive detection of liver fibrosis. *Cancer Biol Med*, 15(2): 124-136.
 15. **Liu, XY, Liu, RX, Hou, F, Cui, LJ, Li, CY, Chi, C, et al. (2016):** Fibronectin expression is critical for liver fibrogenesis in vivo and in vitro. *Mol Med Rep*, 14(4): 3669-3675.
 16. **Mòdol, T, Brice, N, Ruiz de Galarreta, M, García Garzón, A, Iraburu, MJ, Martínez-Irujo, JJ, et al. (2015):** Fibronectin peptides as potential regulators of hepatic fibrosis through apoptosis of hepatic stellate cells. *J Cell Physiol*, 230(3): 546-553.
 17. **Motola, DL, Caravan, P, Chung, RT, & Fuchs, BC. (2014):** Noninvasive Biomarkers of Liver Fibrosis: Clinical Applications and Future Directions. *Curr Pathobiol Rep*, 2(4): 245-256.
 18. **Özkan, MB, Bilgici, MC, Eren, E, Caltepe, G, Yilmaz, G, Kara, C, et al. (2017):** Role of Point Shear Wave Elastography in the Determination of the Severity of Fibrosis in Pediatric Liver Diseases with Pathologic Correlations. *J Ultrasound Med*, 36(11): 2337-2344.
 19. **Pokorska-Śpiewak, M, Kowalik-Mikołajewska, B, Aniszewska, M, Pluta, M, & Marczyńska, M. (2017):** Novel serum biomarkers modified by the body mass index z-score for the detection of liver fibrosis and steatosis in children with chronic hepatitis C. *BMC Infectious Diseases*, 17(1): 361.
 20. **Pokorska-Śpiewak, M, Kowalik-Mikołajewska, B, Aniszewska, M, Pluta, M, Walewska-Zielecka, B, & Marczyńska, M. (2015):** Determinants of liver disease progression in children with chronic hepatitis C virus infection. *Pol J Pathol*, 66(4): 368-375.
 21. **Yang, W, Huang, H, Wang, Y, Yu, X, & Yang, Z. (2014):** High red blood cell distribution width is closely associated with nonalcoholic fatty liver disease. *Eur J Gastroenterol Hepatol*, 26(2): 174-178.