



## Comparative Study of Autogenous Fresh Tooth Graft and Platelet Rich Fibrin Mixture versus Autogenous Fresh Tooth Graft Only For Immediate Dental Implant Placement

Ahmed Sameir Abdel-Raheim Gabra\*, Mohsen Fawzy Abu-Elhassan,  
Hosam El-dein Mohammed Ali, Mohamed Mahgub El-Ashmawy<sup>\*1</sup>

Codex : 09/2023/10

Aadj@azhar.edu.eg

### KEYWORDS

Autogenous Fresh Tooth Graft,  
Platelet Rich Fibrin,  
Immediate Dental Implant,  
Sticky bone, Alveolar bone

### ABSTRACT

**Aim:** This study was designed to compare between autogenous fresh tooth graft with/without platelet rich fibrin on osseodensification of immediate dental implant..  
**Subjects and methods:** Twelve implant fixtures were inserted in 6 patients divided equally into two groups. The patients were selected from those attending outpatient clinic, Oral and Maxillofacial Surgery Department, at the Faculty of Dental Medicine, Boys, Assiut, Al-Azhar University .Clinical examination was made to all patients as: Quality, quantity of the bone, mucosa, contour of the underlying bone and crown to bone relationship. Preoperative panoramic radiographs and cone beam CT were taken for every patient to determine alveolar bone height & width. The change in the implant stability and bone density was measured using cone beam computerized tomography (CBCT) immediately, and after 6 months of healing. All readings were recorded and analysis and statistically. **Results:** The mean value of horizontal and vertical bone loss in group (1) and group (2) at 6 months showed statistical significant differences between two groups. The mean value of bone density in group(1) and group(2) at months  $955.00 \pm 52.92$  and  $670.83 \pm 8.01$  respectively with statistical significant differences between two groups. **Conclusion:** It may be concluded that this method is valuable for preservation of alveolar bone and obtaining vital and good quality bone structure.

### INTRODUCTION

Loss of bone height is one of dilemma which complicated oral rehabilitation after tooth extraction therefore bone height decreases progressively by 25% during the first year after tooth loss, with a total of 4 mm of height lost during this first year post-extraction. The changes in vascularisation as a result of bone resorption are also important, with intrabony vascularisation shifting to centripetal periosteal vascularization, These dimensional changes that occur in the alveolar process may make it difficult to place an implant in a proper three-dimensional position<sup>(1,2)</sup>.

1. Department of Oral and Maxillofacial Surgery, Faculty of Dental Medicine, Al-Azhar University ,Assiut, Egypt

\* Corresponding Author e-mail:  
dentistahmed8843@gmail.com

In order to overcome the negative consequences of tooth extraction, various treatment approaches were used such as immediate implants and non resorbable xenograft biomaterial<sup>(3)</sup>. Immediate implant placement is a well-recognized and a successful treatment option following tooth removal, Therefore a risk of losing vestibular bone height and soft tissue which is unacceptable from rehabilitation of view<sup>(4)</sup>.

Accordingly several studies evaluated different types of bone graft to overcome the bone resorption for labial/buccal or lingual/palatal aspects, There are; 1- Autograft, 2- Allograft, 3- Xenograft, 4- Alloplastic graft, 5- Growth factors<sup>(5)</sup>.

Autogenous grafts are always the gold standard and the benchmark of all graft types because of Its osteoinductive, osteoconductive, and osteogenic. However, secondary surgical sites, pain, high rates of donor site morbidity, and limited supply of graft material are the main disadvantages of autogenous graft<sup>(6,7)</sup>.

Therefore, there are several trials to overcome the bone resorption, in the same context, demineralized autologous tooth dentin has been introduced as a new alternative to autogenous bone graft as it has osteoinductivity. An extracted tooth from the patient can be used as noble bone graft material after appropriate decalcification and sterilization process, it has been widely used for ridge and sinus augmentation. Dentin and alveolar bone are identical both chemically and histologically, and have the same embryologic origin. So, dentin can be used as a graft material that is gradually replaced by bone<sup>(8,9-12)</sup>.

Some studies have reported the success of implants with fresh tooth graft using PRF as an important source of multiple growth factors to increase the rate of bone formation the a graft<sup>(13,14)</sup>.

Platelet-rich fibrin was first introduced in France by Choukroun et al in 2006<sup>(15)</sup>. It was considered a second-generation platelet concentrate as it is

produced without any anticoagulants or gelifying agents. PRF is being completely autogenous in nature, simple and relatively inexpensive with a specific three-dimensional architecture of the fibrin. PRF has also shown increased levels of inflammatory and healing cytokines. After activation of the platelets which are trapped within fibrin matrix, growth factors are released and stimulate the mitogenic response in the bone periosteum during normal wound healing for repair of the bone. Better understanding of physiologic properties of platelets in wound healing since the last two decades led to an increase in its therapeutic applications in the various forms showing varying results. PRF represents a new revolutionary step in the platelet gel therapeutic concept<sup>(16)</sup>.

Accordingly, this study was be a trial to investigate the effect of autogenous fresh tooth graft with or without PRF on osteointegration of immediate dental implant.

## AIM OF THE STUDY

The aim of the present study was to compare between autogenous fresh tooth graft with/without platelet rich fibrin on osseodensification of immediate dental implant.

## PATIENT AND METHODS

This Randomized Controlled Clinical Trial study was conducted on twelve adult patients of both genders. All patients badly destructed teeth indicated for extraction and immediate implant placement. An informed consent was obtained from all patients. The patients were selected from the Out Patient Clinic of the Oral & Maxillofacial Surgery Department, Faculty of Dentistry, Assiut, Al-Azhar University.

### Patients were divided into two groups:

**Group(1):** Autogenous fresh tooth graft around immediate dental implant placement with PRF.



**Group(2):** Autogenous fresh tooth graft around immediate dental implant placement without PRF.

The inclusion criteria of this study were; Healthy adult patients (over 18 years of age), without any systemic complication, Patients who required extraction of teeth for periodontal reasons (teeth with an impossible prognosis), root caries or fractures who were also candidates for immediate replacement with an osseointegrated implant, Patients who accepted the study conditions signed their written informed consent and agreed to attend the scheduled follow-up appointments, Good dental hygiene, Non smokers or patients who smoked less than 10 cig/day were be included. While the exclusion criteria were; periapical or periodontal active infection involving the teeth to be extracted, patients receiving chemotherapy or radiotherapy, alcohol or drug abuse, heavy smokers, patients who have uncontrolled systemic disorders such as uncontrolled diabetes mellitus, autoimmune disease and patients with parafunctional habits such as bruxism, clenching, excessive gum chewing, lip or fingernail biting.

### **The Implant system**

Implant (Two-stage screw NucleOSS™ T6 Implant System) was mounted on a color-coded fixture mount, designed for use as a transfer, or shortened for use as a straight abutment.

### **A -Preoperative phase**

All patients underwent pre-operative clinical examination: Patients' data were collected; name, gender and age, medical and dental histories were taken and the oral mucosa of the edentulous area was examined by inspection and palpation. Also, all patients underwent standardized periapical radiography to detect any periapical pathology and a pre-operative panoramic radiograph examination to select the proper size of the implants to be installed with aids of CBCT.

### **B -Operative phase**

All patients were instructed to rinse with chlorhexidine mouth wash (Listermix plus, SIGMA Pharmaceutical Industries, Egypt) immediately before operation for 2 minutes.

All patients were treated using local anesthesia, articaine HCL and epinephrine 1:20.000 (Septodont, by Novocol Pharmaceutical of Canada, Inc.)

#### **In group (1)**

##### **A)Tooth extraction;**

The extractions was performed atraumatically using manual periostomes in order to avoid alveolar ridge alterations at the time of the extraction. A thorough alveolar curettage was subsequently carried out. In those cases in which the extracted tooth had a root canal treatment, this was not used as donor material.

##### **B) Tooth processing;**

Preparation and processing of the tooth graft Immediately after extraction, carious lesions and discolored dentin or remnants of periodontal ligament (PDL) and calculus should be removed by high speed tungsten carbide burs. The roots was splited in case of multi-rooted teeth. The cleaned teeth including crown and root was dried by air syringe and grind by newly designed 'Smart Dentin Grinder'. Dentin particles between 300-1200 µm were be collected. The particulate dentin from the drawer was be immersed in basic alcohol for 10 minutes, in a small sterile glass container. After decanting the basic alcohol cleanser, the particulate was washed twice, in sterile phosphate buffered saline (PBS). The PBS was decanted leaving wet particulate dentin ready for grafting.

##### **C) Preparation of platelet rich fibrin;**

Around 5 ml of whole venous blood was collected in each of the two sterile vacutainer

tubes of 6 ml capacity without anticoagulant. The vacutainer tubes were placed in a centrifugal machine at 3000 revolutions per minute (rpm) for 10 minutes, after which it settles into the following layers: red lower fraction containing red blood cells, upper straw colored cellular plasma and the middle fraction containing the fibrin clot. The upper straw colored layer was removed and middle fraction collected, 2 mm below lower separating line, which is the PRF.

#### **D) Implant Insertion;**

Drilling for implant placement with sequential drills, and the implant will be placed in fresh extracted socket using implant ratchet. Ratchet was used to insert the implant and tight in its bed in a clockwise direction to the determine length. The tightening of implant using insertion torque of 50 Ncm. Smart peg was applied to implant to determine and read the primary stability with osstell machine. The cover screw was removed from the bottom of the implant vial by a hex tool and screwed into the implant body. The buccal and the palatal soft tissue were approximated and sutured by interrupted suture.

#### **In group (2)**

The involved tooth was luxated using Periosteal and small straight elevator. The root was extracted using remaining root forceps. Drills were used in the sequential manner to prepare implant site and extended 3 mm down the apex of the extracted tooth. The implant was inserted in the osteotomy site with the same manner as aforementioned in first group.

#### **A-Postoperative phase**

All patients were advised to apply cold packs extra orally intermittently every 10 minutes for 2 hours on the first day. Chlorohexidine mouth wash was started on the 2nd post-operative day for one week and the sutures were removed after one week

post surgically. Amoxicillin 875 mg /claviulanic acid 125 mg antibiotic tablet (Augmentin 1 gm, Glaxosmithkline, Australia), one tablet every 12 hours for 5 days postoperatively. Diclofenac sodium non-steroidal anti-inflammatory drugs 50 mg tabs (Cataflam, Novartis pharma, Basel, Switzerland) one tablet every 8 hours for five days. Chymotrypsin + trypsin ® tablets (Alphintern, Kahira. pharm & chem. Ind. co., Cairo, Egypt), was administrated half an hour before meals 3 times for 7 days.

#### **B- Follow up phase**

##### **Clinical evaluation**

**Early follow up:** was performed daily for the first week after implant placement, then weekly for the first month for any signs of infection, pain, swelling or any post-operative complications.

##### **Patients were evaluated clinically for:**

**Pain** was evaluated using the Visual Analogue Scale. A score of 0 was defined as no pain, and 10 points was defined as the most severe intolerable pain.

**Post-operative complications** were evaluated as the presence of pain, tenderness, infection or swelling that may indicate the presence of peri-implant disease and possible accelerated bone loss. Any post-operative complications were recorded.

**Long term follows up** was performed at 4 and 6 months after surgery regarding gingival and periodontal condition and implant stability.

##### **Patients were evaluated clinically for:**

**Peri-implant probing depth:** measuring the distance from the gingival margin buccal, palatal, mesial and distal crestal bone margins. Mesial and distal pockets were measured from the buccal aspect as close as possible to contact points while facial and lingual pockets were measured at the midline of the implant.



**Measurement of implant secondary stability** was performed by Osstell™. after 6 months from implant placement.

### Radiographic evaluation

All implants involved in this study were followed up radiographically by Cone beam computed tomography (CBCT) to evaluate horizontal and vertical dimensional changes to the labial bone following immediate implant placement, It was done at 6 months.

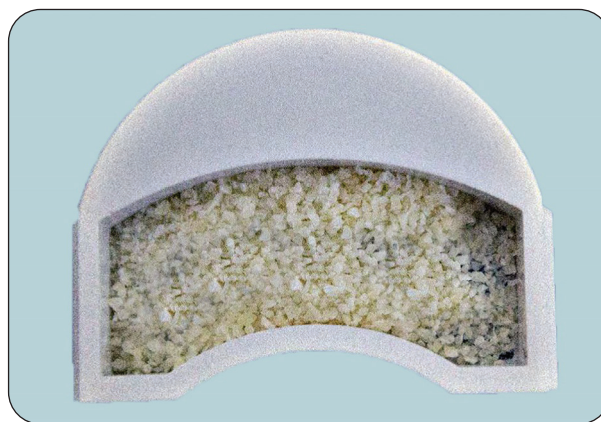
*Sagittal images were used to measure buccal bone-width as follows:*

**Horizontal bone level:** Starting from the implant shoulder a fixed distance was taken as a reference line and the horizontal bone level was measured throughout the three follow up periods.

**Vertical bone level:** A line from the apex of the implant parallel to the reference horizontal line of the CBCT was drawn and the marginal bone level was measured from the reference line to the marginal bone crest parallel to the implant.



Photograph showing the Smart Dentin Grinder device



Photograph showing the grinded particles in the collecting chamber

### Statistical analysis

Data were represented as mean and standard deviation. Repeated measures analysis of variance (ANOVA) test was used to compare numeric variables within the studied group of patients. Post Hoc test was done if ANOVA or Friedman tests were positive. Using SPSS version in all tests, result was considered statistically significant if the p- value was less than 0.05.

## RESULTS

12 implant fixtures were inserted in 6 patients divided equally into two groups( 6 implant in each group). The male patients was 6 (50% ) and female patients was 6 (50%). Each patient received two implants, one of them was tooth graft with PRF around immediate dental implant and other one without PRF. The age ranged from 20 to 35, with a mean value of  $31.17 \pm 6.05$ .

All patients underwent surgery in local anesthesia and no complications had been recorded during the operation.

### I. Clinical evaluation

All patients had been examined periodically during the follow-up period up to 6 months. Healing was uneventful in all cases with no post-operative complications.



- Pain, swelling or infection;** all patients experienced slight to mild pain at the surgical site which disappeared completely after the 2<sup>nd</sup> and 3<sup>rd</sup> days & all patients experienced mild to moderate edema which also disappeared completely after five days. All patients continued the follow up period without any signs of infection.
- Implant stability evaluation;** in the study group, the mean implant stability quotient at

3 months was  $82.83 \pm 5.53$  ISQ, There was an increase after 6 months to  $90.67 \pm 1.21$  ISQ which was not statistically significant. In the control group the mean implant stability quotient at 3 months  $70.50 \pm 3.56$  ISQ there was an increase after 6 months to  $77.67 \pm 5.61$  ISQ which was statistically significant. The difference between the two groups was statistically significant (Table 1).

**Table (1)** Comparison of Implant stability quotient (ISQ) between Immediate post-operative placement, 3 months and 6 months within group(1) and group (2).

	Immediate post-operative placement	At 3 months	At 6 months	Test used	P
Group(1) (n= 6)	54.83±9.79	82.83±5.53	90.67±1.21	F=47.17	0.002*
Post-hoc		P1=0.009*	P2=0.001* P3=0.08		
Group(2) (n= 6)	61.83±11.41	70.50±3.56	77.67±5.61	F=8.302	0.038*
Post-hoc		P1=0.17	P2=0.03* P3=0.04*		

Data expressed as mean±SD SD: standard deviation

P:Probability

\*:significance <0.05

Test used: Repeated measures ANOVA followed by post-hoc Bonferroni

P1: significance between Immediate & After 3 months

P2: significance between Immediate & After 6 months

P3: significance between After 3 months & After 6 months

## II. Radiographic evaluation

All patients had been examined radiographically using Cone beam computed tomography (CBCT) it was done to evaluate horizontal and vertical dimensional changes to the labial bone following maxillary anterior single immediate implant placement.

- Horizontal bone loss; in the study group the mean horizontal bone loss after 6 months was (0.065-0.130), while in control group the mean horizontal bone loss after 6 months was (0.450-0.690). The difference in horizontal bone loss between both groups after six months from implant placement was statistically significant (Table 2).

**Table (2)** Comparison of horizontal bone loss between 3 months & 6 months in group(1) and group (2).

	At 3 months	At 6 months	Test used	P
Group(1) (n= 6)	0.055 (0.045-0.080)	0.077 (0.065-0.130)	Z= -2.226	0.026*
Group(2) (n= 6)	0.510 (0.300-0.580)	0.595 (0.450-0.690)	Z= -2.201	0.028*

Data expressed as median (IQR)

IQR:interquartile range P:Probability

\*:significance <0.05

Test used: Wilcoxon signed rank test



2. Vertical bone loss; in the study group the mean vertical bone loss after 6 months was (0.480 -0.530), while in control group the mean vertical bone loss after 6 months was (1.400 - 1.640). The difference in vertical bone loss between both groups after six months from implant placement was statistically significant (Table 3).

### 3. Bone density;

Cone-beam was done to measure bone density with hounsfield units (HU) at six points aligned immediately labial or buccal to the placed implant using the imaging software. The mean value of bone density in group(1) and group(2) at 6 months was  $955.00 \pm 52.92$  and  $670.83 \pm 8.01$  respectively

with statistical significant differences between two groups.

**Table (3)** Comparison of vertical bone loss between 3 months & 6 months within group(1) and group(2).

	At 3 months	At 6 months	Test used	P
Group(1) (n= 6)	0.135 (0.080-0.220)	0.510 (0.480-0.530)	Z= -2.201	0.028*
Group(2) (n= 6)	0.590 (0.400-0.940)	1.490 (1.400-1.640)	Z= -2.207	0.027*

Data expressed as median (IQR)

IQR:interquartile range P:Probability

\*:significance <0.05

Test used: Wilcoxon signed rank test

**Table (4)** Comparison of Bone density between Pre-operative procedures, and at 3,6 months within group(1) and group(2).

	Pre-operative procedures	At 3 months	At 6 months	Test used	P
Group(1) (n= 6)	658.33±12.91	745.00±22.80	955.00±52.92	F=155.093	<0.001*
Post-hoc		P1=<0.001*	P2=<0.001* P3=<0.001*		
Group(2) (n= 6)	650.50±6.28	660.00±8.94	670.83±8.01	F= 35.737	0.003*
Post-hoc		P1=0.003*	P2=0.001* P3=0.009*		

Data expressed as mean±SD

SD: standard deviation

P:Probability

\*:significance <0.05

Test used: Repeated measures ANOVA followed by post-hoc Bonferroni

P1:significance between Pre-operative procedures & At 3months

P2:significance between Pre-operative procedures & At 6months

P3:significance between At 3 months & At 6 months

## DISCUSSION

Ridge alteration is a physiological process that must occur after either single or multiple teeth extraction, alveolar ridge undergoes resorption in both vertical and horizontal aspects<sup>(17)</sup>. Ridge loss starts after extraction and continues throughout life, its fastest rate during first three months, and then the rate decreases gradually<sup>(18)</sup>. Resorption occurs

spontaneously in both horizontal and vertical dimensions, but it is more rapid and aggressive in horizontal dimension than in vertical one. Many studies stated that about 50% of the horizontal dimension was lost after six months vertical dimension decreases also, it decreases more rapidly on buccal side, after six months vertical dimension decreases by about 1.7mm<sup>(19)</sup>.

There are different bone graft materials, including autogenous bone grafts, allografts, xenografts, and alloplastic grafts, are used to promote new bone formation. Autogenous bone grafts are considered the gold standard because they have osteogenesis, osteoinductive and osteoconductive effects and also accelerate healing. However, as a limited graft area, resorption problems and a second wound site infection are among the disadvantages of autogenous bone grafts. Allogenic, xenogenic, and synthetic graft materials are also used. Allografts have a less osteogenic and more immunogenic effect than autogenous bone grafts and increase the risk of transmitting infectious diseases. Additionally, xenografts and alloplastic grafts have more osteoconductive effects and cannot contribute to the desired regeneration<sup>(20,21)</sup>.

Recently grafts prepared from extracted teeth have been described as alternative bone grafts to avoid disadvantages of other grafts, because bone and tooth have a similar structure as both derive from the neural crest cells, and contained the same percentages of inorganic and organic components<sup>(7,22)</sup>.

In the present study the absorption of autogenous tooth graft (ATG) was slower than that of other grafts as autogenous bone, xenograft, allograft, alloplastic materials, because ATG was denser, which seems to be a common problem of autogenous tooth grafts<sup>(23)</sup>.

In our study the advantages of ATG which is highly osteogenic and does not have the disadvantage of an autologous bone, might be an additional alternative for patients with an aversion to allogenic or xenogenic graft materials, another advantage in comparison to autologous bone harvesting procedures is that there is no donor site comorbidity, which may reduce post-operative complaints and complications drastically, also the clinician is not dependent on prefabricated biomaterials from manufacturers and may reduce material costs, a faster bone healing effect compared to the unfilled control group<sup>(24)</sup>.

Demineralized dentin was used as graft material, where the extracted tooth was sent to Korea Tooth Bank® to be crushed and subjected to a dehydration, defatting and demineralization processes and then lyophilized, then sterilized with ethylene oxide gas, then sent back to the clinic or hospital, this process takes days to weeks to be done<sup>(25,26)</sup>. A more recent device (VacuaSonic®) used to produce demineralized dentin graft chairside, but the process takes minimum of two hours, which is sometimes not applicable or acceptable by patients<sup>(27)</sup>.

In the present study, the tooth extracted was grinded using Smart Dentin Grinder®(SDG) and sterilized by dentin cleanser then washed twice by phosphate buffered saline(PBS) to be ready for grafting within 15-20 minutes. SDG saving time, money and eliminating the need for second operation or waiting for a long time before grafting.

Platelet rich fibrin(PRF) consists of a fibrin network and is a second-generation platelet concentrate that accelerates soft and hard tissue healing. The fibrin network includes stem cells and affects the vascularization and angiogenesis of healing. PRF ensures mechanical stabilization by binding the graft particules. Furthermore, PRF contains several growth factors that accelerate healing. Autogenous PRF with tooth graft provides a beneficial effect in different areas of periodontal and bone surgery, including periodontal therapy, repair of bony defects and sinus floor augmentation<sup>(28)</sup>.

In current study the use of tooth graft combined with PRF to increase mean bone volume and radiographic density in a clinical study, the present study was in agreement with Ezgi YC, et al<sup>(29)</sup>. The presence of new bone formation in tooth graft mixture with PRF play an important role in osteoblast differentiation and early bone healing, considering the physiological stages of bone healing after tooth extraction, it is known that osteoblasts move together with fibroblasts to form a callus-like texture, this soft callus tissue then becomes mineralized into mature bone tissue, Therefore, a





high rate of connective tissue in the group(1) at 3 months may be considered as an indication that for new bone formation continues<sup>(26,30)</sup>.

The rate of new bone and new vessels formation were evaluated histopathologically around autogenous tooth graft as seen dense mesh fibrillar formations in the tooth graft mixture with PRF group which were not seen in group(2), among the trabecular structure of the newly formed bone tissue and nonresorbed tooth particles were noteworthy<sup>(29)</sup>. It is thought that dense fibrillar structures may have osteoconduction properties by acting as a scaffold between trabecula and tooth particles<sup>(125)</sup>. also it was clearly observed that the connection between the autogenous tooth graft and bone cells occurred and the new bone formed directly on the surface of the tooth graft particles<sup>(32)</sup>.

One of the advantages of using PRF with autogenous tooth graft is increase the stabilization of graft particles<sup>(28)</sup>.

For implant stability quotient(ISQ), the mean value of ISQ at 3&6 months respectively of group (2) showed decrease in ISQ with significant differences when compared to that in group(1) at 3&6 months respectively. PRF can significantly improve implant stability and give good tissue acceptance and biocompatibility, the present study was in agreement with the study of Qu C, et al<sup>(33)</sup>.

For marginal bone loss, the accepted guidelines for implant induced bone loss since the late 1980s are less than 1.5 mm for the first year after implant loading and less than 0.2 mm for each additional year. There are other study describing a mean crestal bone loss of 0.6 mm for the first year and 0.2 mm for the following years up to 36 months after implant loading<sup>(34,35)</sup>, these studies show significant variability in marginal bone loss following dental implants.

In the present study the mean value of marginal bone loss at 3&6 months respectively of group(2) showed increase in vertical bone loss with significant

differences when compared to that in group(1) at 3&6 months respectively. The minimized marginal bone loss for group(1) is possibly due to the use of rough surfaced implants which increase the contact area between implant surface and newly formed bone, Also tapered implant design allow for better stress distribution at the marginal bone implant interface, the present study was in agreement with the study of Hartlev J, et al.,<sup>(36)</sup>.

For bone density the mean value of bone density at 3&6 months respectively for group(2) showed decrease in bone density with significant differences when compared to that in group(1) at 3&6 months respectively. This increase of bone density for group(1) indicates effective new bone formation, mineralization, remodeling and maturation at the grafted site, also improvement of peri-implant bone architecture and mineralization which increases implant primary stability and osseointegration<sup>(37)</sup>. New bone within graft particles, slow resorption rate results of tooth graft in remaining graft particles with high density of graft, This finding can explain the statistically significant difference in bone density between group(1) and group(2) after 6 months, the present study was in agreement with the study of Kizildag A, et al<sup>(28)</sup>.

## CONCLUSIONS

1. Fresh autogenous tooth graft may be an alternative graft material that can eliminate the disadvantages of conventional graft materials.
2. The use of fresh autogenous tooth graft with PRF increases bone formation capacity and give a predictable clinical and radiographic evidence of bone formation and faster healing.
3. Long-term clinical follow-up is needed to determine the long-term bone formation and survival rates of dental implants on grafted sites. Further clinical studies are needed to compare the new bone formation capacity of autogenous tooth graft with different graft materials.

## REFERENCES

1. Cardaropoli G, Araujo M, Lindhe J. Dynamics of bone tissue formation in tooth extraction sites. An experimental study in dogs. *J Clin Perio.* 2003;30:809-18.
2. Cawood J I, Howell R A. Reconstructive preprosthetics surgery. I Anatomical considerations. *Int J Oral Maxillofac Imp.* 1991;20:75-82.
3. Botticelli D, Berglundh T, Lindhe J. Hard tissue alterations following immediate implant placement in extraction sites. *J of Clin Perio.* 2004;31:820-28.
4. Lang N P, Pun L, Lau K Y, Li K Y, Wong M C. A systematic review on survival and success rates of implants placed immediately into fresh extraction sockets after at least 1 year. *Clin Oral Imp Res.* 2012;23:39-66.
5. Jeong TM, Lee JK. The Efficacy of the Graft Materials after Sinus Elevation: Retrospective Comparative Study Using Panoramic Radiography. *Maxillofac Plast Reconstr Surg.* 2014;36:146-53.
6. Kühl DS, Götz QH, Brochhausen DC, Jakse MN, Filippi HA, d'Hoedt B, Kreisler M. The influence of substitute materials on bone density after maxillary sinus augmentation: a microcomputed tomography study. *Int J Oral Maxillofac Imp.* 2012;27:1541-46.
7. Kim YK, Kim SG, Byeon JH, Lee HJ, Um IU, Lim SC, Kim SY. Development of a novel bone grafting material using autogenous teeth. *Oral Surg Oral Med Oral Pathol Oral Radio Endo.* 2010;4:496-503
8. Pohl VM, Schuh CD, Fischer MB, Haas RM. A New Method Using Autogenous Impacted Third Molars for Sinus Augmentation to Enhance Implant Treatment: Case Series with Preliminary Results of an Open, Prospective Longitudinal Study. *Int J Oral Maxillofac Imp.* 2016;31:622-30.
9. Jun SH, Ahn JS, Lee JI, Ahn KJ, Yun PY, Kim YK. A prospective study on the effectiveness of newly developed autogenous tooth bone graft material for sinus bone graft procedure. *J Adv Prosthodont.* 2014;6:528-38.
10. Lee DH, Yang KY, Lee JK. Porcine study on the efficacy of autogenous tooth bone in the maxillary sinus. *J Korean Assoc Oral Maxillofac Surg.* 2013;39:120-6.
11. Romero MJ, Hernandez AF, Penarrocha DM, Soto PD, Penarrocha OD, Penarrocha MA. Simultaneous and delayed direct sinus lift versus conventional implants: Retrospective study with 5-years minimum follow-up. *Med Oral Patol Oral Cir Bucal.* 2018;23:752-60.
12. Kim GW, Yeo IS, Kim SG, Um IW, Kim YK. Analysis of crystalline structure of autogenous tooth bone graft material: X-Ray diffraction analysis. *J Korean Assoc Oral Maxillofac Surg.* 2011;37:225-8.
13. Mazor Z et al. Platelet-rich plasma for bone graft enhancement in sinus floor augmentation with simultaneous implant placement: patient series study. *Imp Dent.* 2004;13:65-72
14. Moon JW et al. New bone formation in the maxillary sinus using peripheral venous blood alone. *J Oral Maxillofac Surg.* 2011;69:2357-67
15. Choukroun J, Diss A, Simonpieri A, Girard MO, Schoeffler C, Dohan SL. Platelet-rich fibrin (PRF): a second-generation platelet concentrate. Part V: histologic evaluations of PRF effects on bone allograft maturation in sinus lift. *Oral Surg Oral Med Oral Pathol Oral Radiol Endod.* 2006;101:299-303.
16. Dohan DM, Choukroun J, Diss A, Dohan SL, Dohan AJ, Mouhyi J. Platelet-rich fibrin (PRF): a second-generation platelet concentrate. Part II: platelet-related biologic features. *Oral Surg Oral Med Oral Pathol Oral Radiol Endod.* 2006;101:e45-50.
17. Orgeas GV, Clementini M, Risi VD, Sanctis MD. Surgical Techniques for Alveolar Socket Preservation: A Systematic Review. *Int J Oral Maxillofac Implants.* 2013; 28:1049-61.
18. Weijden FVD, Dellacqua F, Slot DE. Alveolar bone dimensional changes of post-extraction sockets in humans: a systematic review. *J Clin Periodontol.* 2009; 36:1048-58.
19. Horowitz R, Holtzclaw D, Rosen PS. A Review on Alveolar Ridge Preservation Following Tooth Extraction. *J Evid Based Dent Pract.* 2012; 12:149-60.
20. Widmark G, Andersson B, Ivanoff CJ. Mandibular bone graft in the anterior maxilla for single-tooth implants. Presentation of surgical method. *Int J Oral Maxillofac Surg.* 1997; 26:106-109.
21. Fella BH, Gauthier O, Weiss P, et al. Osteogenicity of biphasic calcium phosphate ceramics and bone autograft in a goat model. *Biomaterials,* 2008; 29:1177-88.
22. Kim YK, Lee J, Um IW, et al. Tooth-derived bone graft material. *J Korean Assoc Oral Maxillofac Surg.* 2013; 39:103-11.
23. Shuxin Z, et al. Comparison of Autogenous Tooth Materials and Other Bone Grafts. *Tissue Eng Regen Med.* 2021; 18:327-4.



24. Orten AV, Goetz W, Bilhan H. Tooth-Derived Granules in Combination with Platelet-Rich Fibrin (“Sticky Tooth”) in Socket Preservation: A Histological Evaluation. *Dent J*. 2022; 10, 29.
25. Kim YK, Kim SG, Oh JS, Jin SC, Son JS, Kim SY, et al. Analysis of the Inorganic Component of Autogenous Tooth Bone Graft Material. *J Nanoscience Nanotechn*. 2011; 1:7442-5.
26. Kim YK, Yun PY, Um IW, Lee HJ, Yi YJ, Bae JH, et al. Alveolar ridge preservation of an extraction socket using autogenous tooth bone graft material for implant site development: prospective case series. *J Adv Prosthodont*. 2014; 6:521-7.
27. Kim ES. Autogenous fresh demineralized tooth graft prepared at chairside for dental implant. *Maxillofac Plas Recons Surg*. 2015; 37:8-13.
28. Kizildag A, Tasdemir U, Arabaci T, et al. Evaluation of new bone formation using autogenous tooth bone graft combined with platelet-rich fibrin in calvarial defects. *J Craniofac Surg*. 2019; 30:1662-66.
29. Ezgi YC, Nilufer O, Emin OM. Effect of Autogenous Dentin Graft on New Bone Formation. *J Craniofac Surg*. 2021; 32: 1354-60.
30. Bormann KH, Suarez-Cunqueiro MM, Sinikovic B, et al. Dentin as a suitable bone substitute comparable to ss-TCP-an experimental study in mice. *Microvasc Res*. 2012; 84:116-22.
31. Cardaropoli D, Nevins M, Schupbach P. New bone formation using an extracted tooth as a biomaterial: a case report with histologic evidence. *Int J Periodont Rest Dent*. 2019; 39:157-163.
32. Kim MG, et al. The effect of autogenous tooth bone graft material without organic matter and type I collagen treatment on bone regeneration. *Maxillofacial Plastic and Reconstructive Surgery*. 2021; 43:17:1-13.
33. Qu C, Luo F, Hong G, and Wan Q. Effects of platelet concentrates on implant stability and marginal bone loss: a systematic review and meta-analysis. *BMC Oral Health*. 2021; 21; 1-16.
34. Buser D, Chappuis V, Kuchler U, Bornstein MM, Wittneben JG, Buser R, et al. Long-term stability of early implant placement with contour augmentation. *J Dent Res* 2013; 92: 176S-82S.
35. Warren P, Chaffee N, Felton DA. A retrospective radiographic analysis of bone loss following placement of TiO2 grit-blasted implants in the posterior maxilla and mandible. *Int J Oral Maxillofac Imp*. 2002; 17: 399-404.
36. Hartlev J, Schou S, Isidor F, Nørholt SE. A clinical and radiographic study of implants placed in autogenous bone grafts covered by either a platelet-rich fibrin membrane or deproteinised bovine bone mineral and a collagen membrane: a pilot randomised controlled clinical trial with a 2-year follow-up. *Int J Imp Dent*. 2021; 7: 1-8.
37. Almasoud NN, Tanneru N, Marei HF. Alveolar bone density and its clinical implication in the placement of dental implants and orthodontic mini-implants. *Saudi Med J*. 2016; 37:684-9.



## دراسة مقارنة طعم الاسنان الذاتية الطازجه و الفيبرين الغنى بالصفائح الدموية مقابل طعم الاسنان وحيدا فى وضع غرسة الاسنان الفوريه

احمد سمير عبد الرحيم، محسن فوزى ابو الحسن ، حسام الدين محمد على ، محمد محجوب العشماوى

1. قسم جراحة الفم والوجه والفكين. كلية طب الأسنان. جامعة الازهرينين. أسيوط. مصر. مصر  
\* البريد الإلكتروني: DENTISTAHMED8843@GMAIL.COM

### الملخص :

**الهدف:** تم تصميم هذه الدراسة للمقارنة بين طعم الأسنان الطازج ذاتي المنشأ مع أو بدون الفيبرين الغني بالصفائح الدموية عند تكتيف العظام في زراعة الأسنان الفورية.

**المواد والأساليب:** تم إدخال اثني عشر تركيبات زرع في 6 مرضى مقسمين بالتساوي إلى مجموعتين. تم اختيار المرضى من المراجعين للعيادة الخارجية بقسم جراحة الفم والوجه والفكين بكلية طب الأسنان بنين أسيوط جامعة الأزهر. تم إجراء الفحص السريري لجميع المرضى من حيث: جودة. كمية العظام. الغشاء الخاطي. محيط العظام الأساسية والعلاقة بين التاج والعظام. تم أخذ صور شعاعية بانورامية قبل الجراحة والأشعة المقطعية المحروبية لكل مريض لتحديد ارتفاع وعرض العظم السنخي. تم قياس التغير في ثبات الزرعة وكثافة العظام باستخدام التصوير المقطعي المحوسب بالحزمة المحروبية (CBCT) فوراً. وبعد 6 أشهر من الشفاء. تم تسجيل جميع القراءات وتحليلها إحصائياً.

**النتائج:** متوسط قيمة فقدان العظام الأفقي والرأسي في المجموعة (1) والمجموعة (2) عند 6 أشهر أظهر فروق ذات دلالة إحصائية بين المجموعتين. متوسط قيمة كثافة العظام في المجموعة (1) والمجموعة (2) عند أشهر.  $52.92 \pm 955.00$  و  $8.01 \pm 670.83$  على التوالي مع وجود فروق ذات دلالة إحصائية بين المجموعتين.

**الخلاصة:** يمكن الاستنتاج أن هذه الطريقة مفيدة للحفاظ على العظم السنخي والحصول على بنية عظمية حيوية وجيدة النوعية..

**الكلمات المفتاحية:** طعم أسنان طازج ذاتي المنشأ. الفيبرين الغني بالصفائح الدموية. زراعة أسنان فورية. عظم لزج. عظم سنخي.

