

# Significance of Bethesda Grade of Scoring in Comparison with Post-Operative Histopathology in Detection of Cancer Thyroid

Original  
Article

*Emad Eldin Fareed, Mohamed Ali Lasheen, Mohamed Ibrahim Monier and Saleh Ibrahim Shehta\**

*Departments of General Surgery, Armed Forces College of Medicine (AFCM), Cairo, Egypt.*

## ABSTRACT

**Background:** The frequency of thyroid cancers has been noticeably rising over the last several decades, with a lifetime risk of around 1.2 percent of men and women becoming more probable as a result of increased screening programs and early identification of this neoplasm.

**Study aim:** Assess the discriminant ability of Bethesda score in patients undergoing thyroid surgery in relation to postoperative histopathology for appropriate triaging of patients with thyroid nodule to appropriate decision.

**Patients and Methods:** A prospective cohort research was done among 83 patients in the Department of surgery in collaboration with the Department of pathology in military Hospitals over 1 year. Patients aged 16 years or above having solitary or more thyroid nodules detected either clinically or radiologically with preoperative FNAC which categorized with Bethesda score of grading and having subsequently undergone surgery were included.

**Results:** The correlation between TBSRTC and final postoperative Histopathology to calculate ROM for each category: TBSRTC II ROM (6.1%), TBSRTC III ROM (25.0%), TBSRTC IV ROM (75.0%), TBSRTC V ROM (87.5%) and finally TBSRTC VI revealed malignancy in all cases with (100%) ROM. Sensitivity of TBSRTC was 76.0%, specificity was 94.83% with total accuracy of 89.16%.

**Conclusion:** The Bethesda system for thyroid FNA smears contributed to more accurate cytological diagnosis and had the additional benefit of predicting the likelihood of malignancy, allowing the clinician to plan for follow-up or surgery and the extent of surgery to decrease the number of unnecessary thyroid operations for people with benign nodules.

**Key Words:** Bethesda, FNAC, histopathology, TBSRTC, thyroid cancer, thyroid nodule.

**Received:** 14 June 2023, **Accepted:** 16 November 2023

**Corresponding Author:** Saleh Ibrahim Shehta, MSc, Departments of General Surgery, Armed Forces College of Medicine (AFCM), Cairo, Egypt. **Tel.:** 01095399644, **E-mail:** salehibrahimshehta@gmail.com

**ISSN:** 2812-5509, 2023, Vol. 1, No. 1

## INTRODUCTION

Reporting of thyroid FNA requires effective communication between pathologists, physicians, radiologists, and surgeons as well as cytohistological correlation. So, it's important to have uniform diagnostic language. For triaging patients with thyroid nodules, fine needle aspiration (FNA) is used as a preoperative diagnostic method that is straightforward, safe, and economical<sup>[1]</sup>.

An outpatient treatment that is safe, minimally invasive, and used to sample thyroid nodules is FNA. FNA may be guided by either palpation or ultrasonography (US), however US provides a number of benefits over palpation. Accurate biopsies of tiny, nonpalpable nodules are made possible by real-time ultrasound because it makes it possible to see the needle within the lesion<sup>[2]</sup>.

Currently, one of the most widely used and reliable methods for presurgical assessing thyroid nodules is fine-needle aspiration cytology (FNAC). Based on the findings

of this examination, the scope of surgery and subsequent therapy may be planned. If a nodule has neoplastic potential, which FNAC may detect, is the most important piece of information<sup>[3]</sup>.

Despite significant advancements in clinical diagnostics over the last several years, thyroid cancer is still difficult to diagnose and cure. FNAB observations and the final histological investigation results may not always support an anticipated diagnosis. A very comparable clinical circumstance that may develop and hinder identification is incidental thyroid cancer in a multinodular goiter. Choosing which nodule to biopsy is one of the most challenging aspects of treating numerous thyroid cancers that may be malignant<sup>[4]</sup>.

Regarding the choice of a nodule for biopsy, there is no consensus among physicians; however sonographic traits that are indicative of cancer have been documented. They consist of a solitary nodule, a solid lesion, hypoechogenicity, and a form, edge, and size that are uneven<sup>[5]</sup>.

In addition to determining suitable triaging for patients with thyroid cancer to proper decision-making, the purpose of this research is to evaluate the discriminant capacity of the Bethesda score in patients having thyroid surgery in connection to postoperative histology.

#### **PATIENTS AND METHODS:**

A prospective cohort study conducted over a year in Military hospitals by the Department of Surgery in collaboration with the Department of Pathology. After receiving the approval from the Institute Ethics Committee, all thyroid FNA smears and thyroidectomy specimens received in the Department of Pathology from August 2021 to August 2022 were included in the study.

The Bethesda system was used to review and categorise FNA smears. Cytohistological correlation was performed on cases with surgical follow-up.

#### ***Study population and sampling:***

The study includes 83 patients who had their thyroid swelling evaluated using FNA. The patients' ages ranged from 16 to 60 years. Age, gender, Bethesda category of each preoperative FNA, size of the nodule, extent of surgical resection, histologic subtype, extrathyroidal extension, multifocality, margin status, number of lymph nodes with metastases, and total number of lymph nodes examined, were all collected for each patient. Follow-up data, such as; whether the patient had postoperative radioactive iodine (RAI), local or distant recurrence, reoperation for cancer recurrence, and length of follow-up, were also reviewed.

#### ***Data collection:***

Patients in the outpatient clinic have all been evaluated using clinical, laboratory, and radiological tools. A detailed medical history was taken, and patients were then examined thoroughly, including a focused local neck examination. Thyroid-stimulating hormone (TSH) and serum Calcitonin are among the laboratory tests performed. Diagnostic imaging included during the study: radionuclide thyroid scan/scintigraphy, which was performed in patients with thyroid nodule and low serum TSH to rule out the possibility of subclinical hyperthyroidism. Thyroid ultrasound: conventional ultrasound or elastography if possible, scored according to TIRADS classification. FNAC was implemented for all patients with TIRADS 2 and above. Patients were admitted to the General Surgery Department and prepared for surgery, and the operation was performed after signing a fully informed separate consent for the operation.

#### ***Operative preparations:***

Complete history taking and full clinical examination. Laboratory investigations included the following: Full

blood count, blood urea and creatinine. serum liver enzymes such aspartate transaminase and alanine transaminase; fasting blood sugar; free T3, free T4, and thyroid-stimulating hormone (TSH); and thyroglobulin, anti-thyroglobulin ABs, and Calcitonin if indicated and Thyroglobulin level pre and post-operative follow up. Imaging evaluation included the following: Neck U/S, Chest radiograph for retrosternal goiter and preoperative assessment, a computed tomographic scan was performed for patients with huge retrosternal, or clinically malignant goitre, as well as suspected retropharyngeal extension of the nodules and preoperative routine indirect laryngoscopy to visualize both vocal cords for all patients. ECG. Histopathological examination: Preoperative FNAC: the thyroid gland was carefully palpated and the nodule(s) to be biopsied were identified. The procedure was thoroughly explained to the patient, and all of his or her questions were answered. We informed our patients that no local anaesthetic was used, that the biopsy would take several minutes, that three to six aspirations would be performed, and that we expected no serious complications, but that there would be minor discomfort similar to a venipuncture. Histopathological examinations: FNAC results have been correlated with postoperative histopathological results.

#### ***Inclusion and Exclusion criteria:***

All patients presented with solitary or multiple thyroid nodules without any history of thyroid surgery were included.

Patients with TI-RADS 1&2 and nodules less than 1 cm in size with no U/S feature suspicious for malignancy (no indication for FNAC or surgery), who had biopsy-proven lymph node metastases preoperatively were all excluded because the Bethesda category of these nodules did not factor into their management, previous thyroid or parathyroid operations, unsatisfactory FNAC sample, age below 16 or above 60 years, patients' inability to offer informed consent.

#### ***Thyroid US Technique:***

A radiologist with experience in thyroid ultrasound performed the Real-time B-mode US and Doppler assessment of the thyroid nodules. The ultrasound scans were performed using a **Siemens Acuson S1000 Ultrasound machine** equipped with a high-frequency linear array transducer (4–12 MHz).

#### ***The US-guided FNAC Biopsy Technique:***

After obtaining written informed consent and placing the patient in the supine position with the hyper-extended neck, the pathologist and radiologist performed all procedures. Betadine (povidone-iodine) solution was used to cleanse the skin and the 4-12 MHz linear transducer.

A sterile gel used as a coupling agent. The initial US study was carried out to determine the nodule of interest that indicated for FNAC according to the guidelines (Fig. 3, 2). The non-cutting bevelled edge needle (25-gauge, 5 cm long) was then held in the right hand, and the transducer in the left.

### ***Surgery:***

All of the patients in our study underwent surgery. Patients with papillary or medullary thyroid cancer lesions underwent neck U/S + CT imaging to rule out any metastatic lesions.

For patients with significant goitres, US + CT imaging of the neck was performed to rule out any retrosternal extension. Furthermore, prior to surgery, all patients had their vocal cord function assessed and reported in the file.

### ***Operative Technique:***

General anaesthesia, endotracheal intubation, and a supine position with a fixed extended neck were done for the procedures. 2–3 cm above the sternal notch, a collar incision was done.

The parathyroid glands were identified and protected, as were the recurrent laryngeal nerves. Following removal of the dissected thyroid gland/lobe, hemostasis, a suction drain was placed for 24 hours. Finally, the wound was closed in layers. The specimens were then sent to the laboratory for Histopathology evaluation.

### ***Post-operative care:***

The same protocol was carried out for all patients post thyroidectomy as a postoperative care. Patients were

closely monitored following surgery, and hypocalcemic symptoms such as numbness, facial paresthesia, positive Chvostek's signs, and muscular spasm were noted as soon as they occurred. Calcium gluconate infusion was a common calcium supplement for hypocalcemia. Post-operatively PTH (case-by-case basis) and calcium levels were measured and recorded the following morning after surgery. extra calcimate tablets were added to the therapeutic plan.

### ***For data entry and analysis:***

The Statistical Package for Social Science (SPSS) twentieth (20) edition will be used (IBM Corp. Released 2011. IBM SPSS Statistics for Mac, Armonk, NY, USA). Qualitative data will be expressed as numbers and percentages (%), while quantitative data will be expressed as means  $\pm$ SD.

Nodules with benign FNA cytology and benign pathology were classified as negative cases. Follicular neoplasm/suspicious for follicular neoplasm, malignant cases confirmed to be malignant on final histology were classified as true positive. Nodules with cytological results of Follicular Neoplasm (FN)/suspicious follicular Neoplasm (SFN) or suspicious for malignancy (SM) or malignant diagnosed as benign after surgical excision were classified as false positives. Cases with benign cytology that turned out to be malignant on histopathology were considered false negatives.

### **RESULTS:**

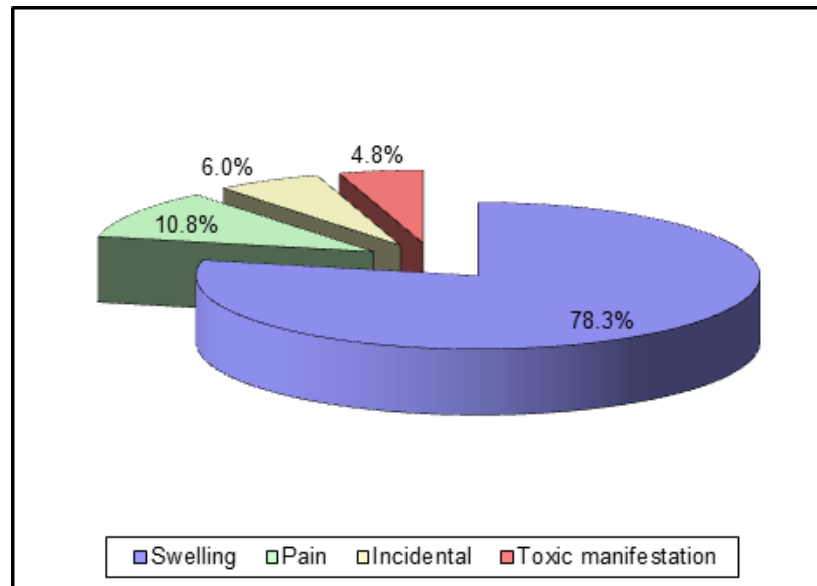
The study has included 83 patients over a period of one year; 48.2% males and 51.8% females, male, with mean of  $45.66 \pm 12.30$ ; range: 18-60 years.

**Table 1:** Demographic data and characteristics of the studied patients

		No. = 83	Total NO.
Age (years)	Mean $\pm$ SD	45.66 $\pm$ 12.30	
	Range	18 – 60	83
Sex	Females	43 (51.8%)	83
	Males	40 (48.2%)	
Co morbidities	Free	60 (72.3%)	83
	DM	12 (14.5%)	
	HTN	4 (4.8%)	
	IHD	1 (1.2%)	
	HTN + DM	2 (2.4%)	
	IHD + DM	3 (3.6%)	
	DM + HTN + IHD	1 (1.2%)	

main Presentation	Swelling	65 (78.3%)	83
	Pain	9 (10.8%)	
	Incidental	5 (6.0%)	
	Toxic manifestation	4 (4.8%)	

Data are presented in this table as mean ± SD & numbers; ranges & percentages are in parenthesis. **DM**: Diabetes mellitus; **HTN**: Hypertensive; **IHD**; Ischemic Heart Disease.



**Fig. 1:** Main presentation of the studied patients

The most common presentation was neck swelling in 78.3% of patients, followed by pain in 10.8% of patients,

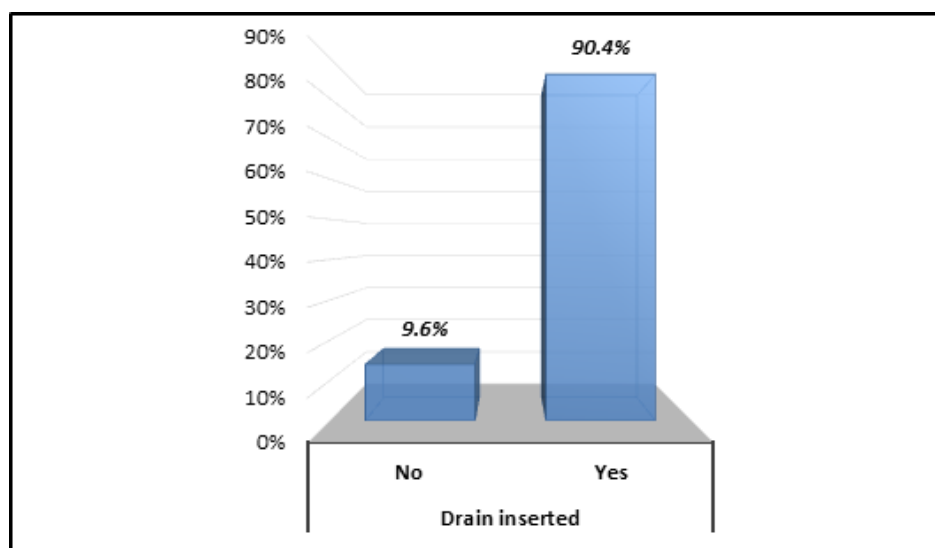
incidentally discovered in 6% of patients and toxic manifestation in 4.8% of patients.

**Table 2:** Extent of surgical resection: Hemi and total thyroidectomy.

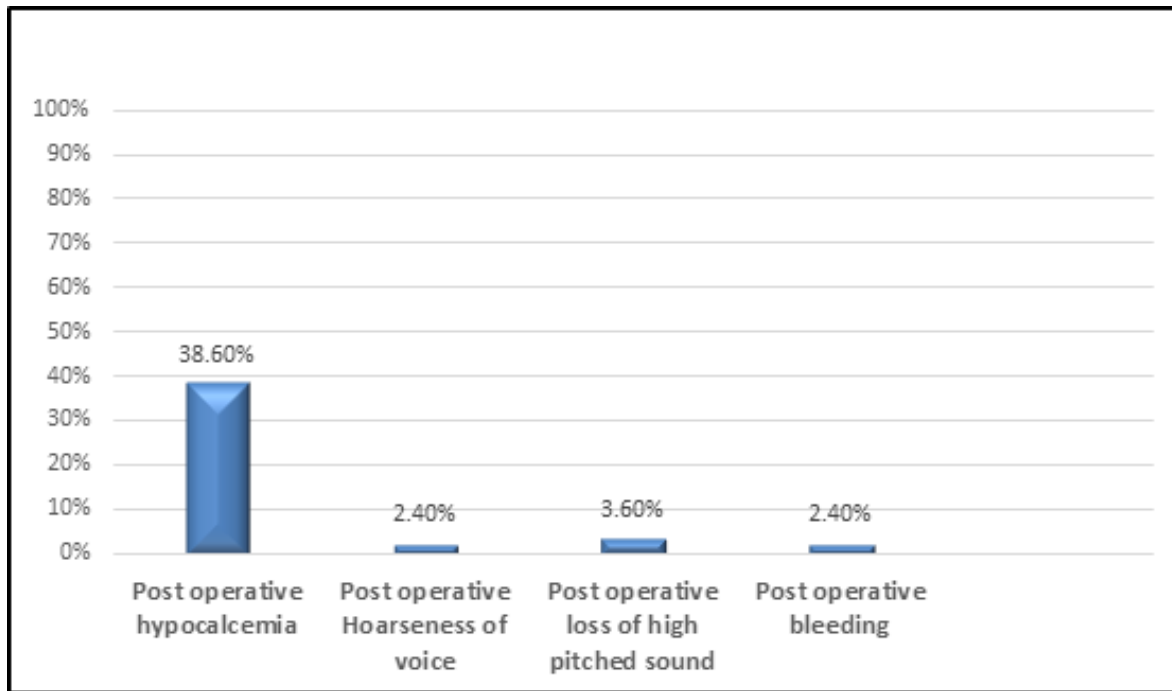
		No. = 83	(100%)
Extent of surgical resection	Hemi-Thyroidectomy	9	(10.8%)
	Total-Thyroidectomy	74	(89.2%)

Previous table and bar chart based on histopathology results showed that all patients with malignant lesions

underwent total thyroidectomy (26 cases), while 84.2% (48 cases) of benign lesions underwent total thyroidectomy.



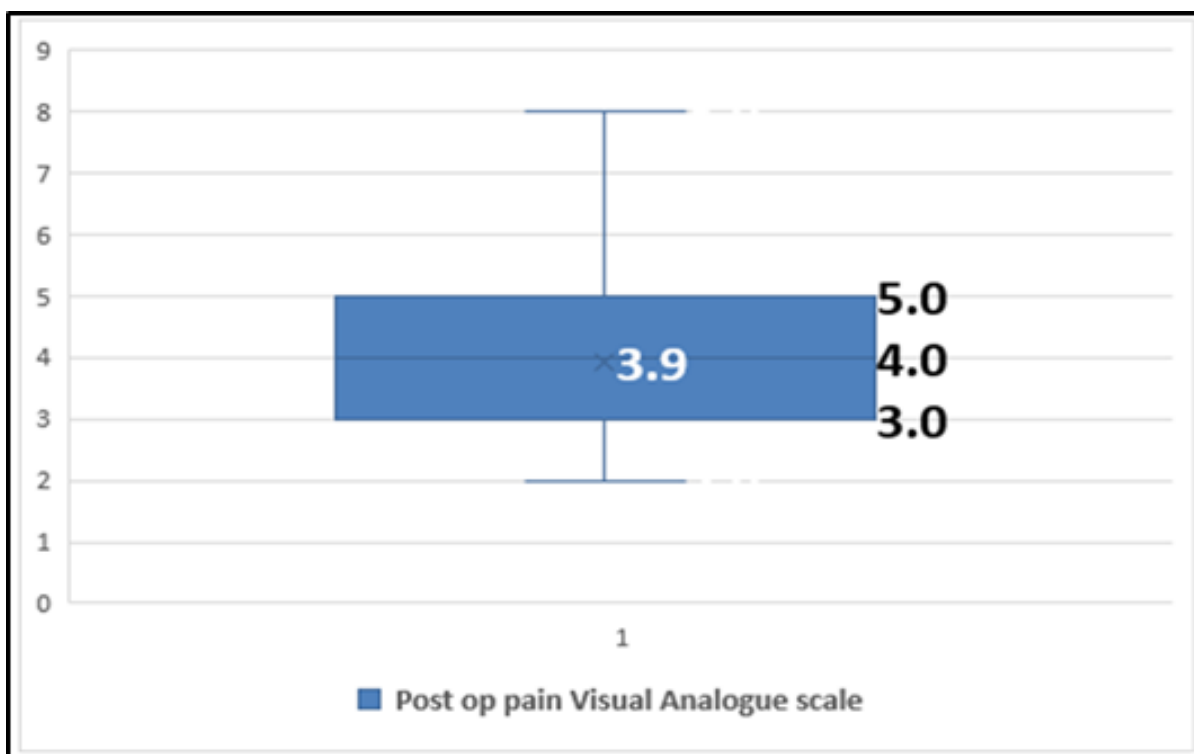
**Fig. 2:** percentage of patients with post op drain



**Fig. 3:** Percentage of postoperative complications among the studied patients

The Previous Figure and Bar chart showed that 46.9% of total population had experienced some complications, the most common post-operative complication was temporary hypocalcemia 38.6% among the whole population,

followed by Post-operative loss of high-pitched sound 3.6% and transient hoarseness of voice as well as Post-operative bleeding 2.4% respectively.



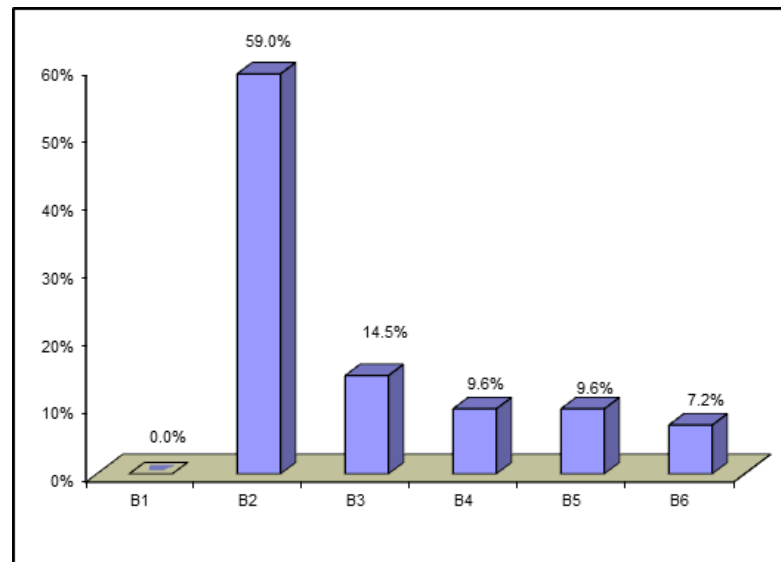
**Fig. 4:** post-operative pain assessment (range and mean) using Visual Analog Scale

Visual Analog Scale (VAS): The patients were asked to rate their pain level on a scale of 0 to 10, with 0 indicating "no pain" and 10 indicating "severe pain.". The mean score

among studied patients was  $3.93 \pm 1.56$  SD (orange circle) with range between 2-8 VAS (yellow circles).

**Table 3:** Bethesda category grade distribution among the patients

	No. = 83	(100%)
B2	49	(59.0%)
B3	12	(14.5%)
B4	8	(9.6%)
B5	8	(9.6%)
B6	6	(7.2%)



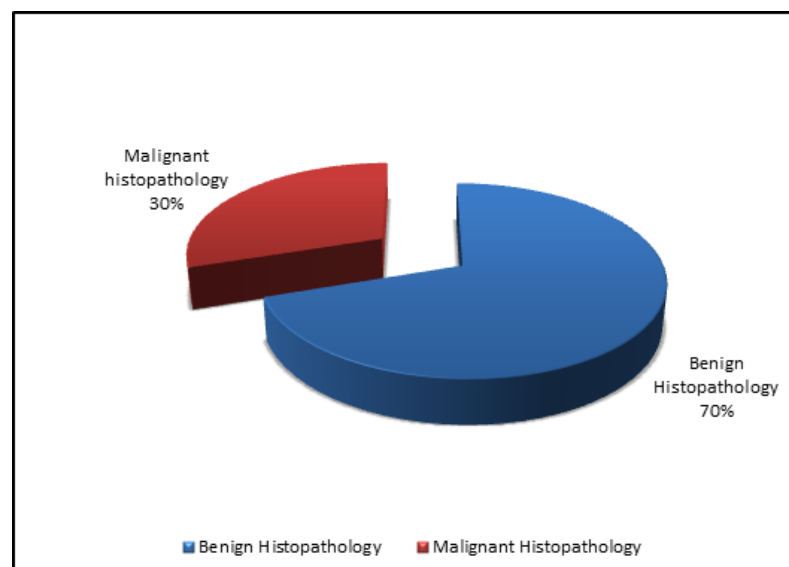
**Fig. 5:** Bethesda grade distribution among the studied patients

The previous table and bar chart demonstrate Preoperative TBSRTC II was assigned to (59.0%) of

patients, TBSRTC III to (14.5%), TBSRTC IV to (9.6%), TBSRTC V to (9.6%) and VI to (7.2%) of all patients.

**Table 4:** Postoperative histopathological results of the studied patients

Postoperative Histopathology	No. = 83	(100%)
Benign	58	(69.9%)
Malignant	25	(30.1%)



**Fig. 6:** Postoperative histopathological results of the studied patients

Postoperative histopathology revealed malignancy in 25 patients with a percentage (30.1%) of total patients as shown in the previous table and the pie chart.

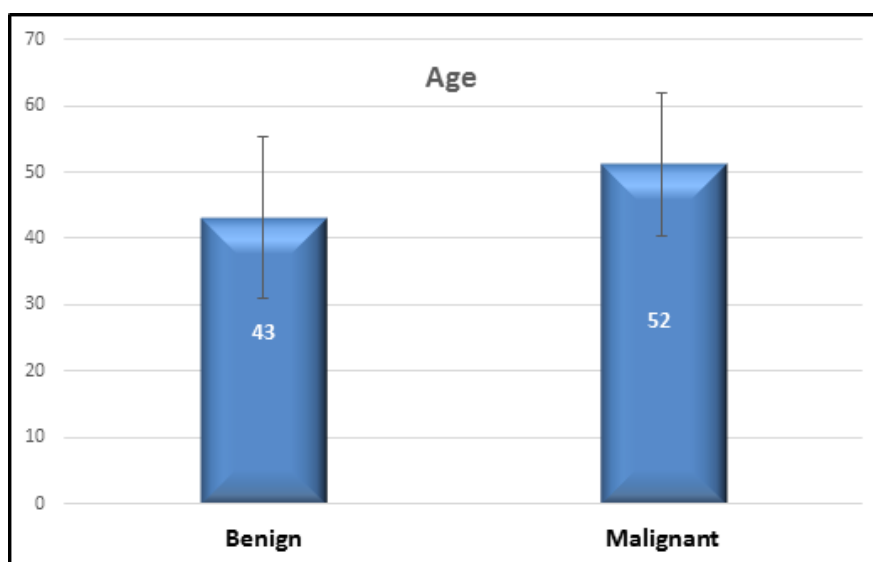
**Table 5:** Relation between Histopathology results with the demographic data

		Histopathology		Test value	P-value	Sig.
		Benign	Malignant			
Age	Mean±SD	43.16 ± 12.22	51.15 ± 10.78	-2.864•	0.005	HS
	Range	18 – 60	21 – 60			
Sex	Females	34 (58.6%)	9 (36%)	4.482*	0.034	S
	Males	24 (41.4%)	16 (64%)			
Co morbidities	Free	46 (79.3%)	14 (56%)	12.886*	0.045	S
	DM	8 (13.7%)	4 (16%)			
	HTN	0 (0.0%)	4 (16%)			
	IHD	1 (1.7%)	0 (0.0%)			
	HTN + DM	1 (1.7%)	1 (4%)			
	IHD + DM	2 (3.4%)	1 (4%)			
	DM + HTN + IHD	0 (0.0%)	1 (4%)			
Presentation	Swelling	50 (86.2%)	15(60%)	12.058*	0.007	HS
	Pain	6 (10.3%)	3 (12%)			
	Incidental	2 (3.5%)	3 (12%)			
	Toxic manifestation	0 (0.0%)	4 (16%)			

P-value >0.05: Non significant (NS); P-value <0.05: Significant (S); P-value < 0.01: highly significant (HS)

The mean and standard deviation of age was statistically significantly higher in malignant lesions when, compared to benign lesions, (51.15 ± 10.78 Versus 43.16 ± 12.22). There was a statistically significant difference in the gender

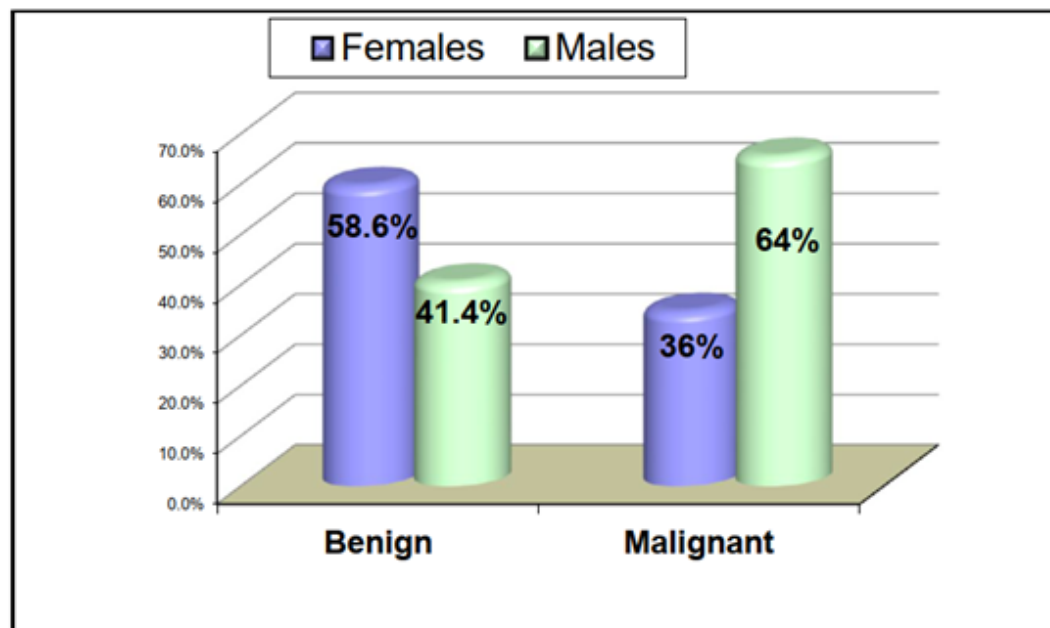
distribution, with a higher percentage of females having benign lesions (58.6%) and a higher percentage of males having malignant lesions (64%).



**Fig. 7:** Showed relation between Histopathology results with mean age in years

Previous bar chart shows that the mean and standard deviation of age was higher in malignant lesions than benign lesions, (51.15 ± 10.78 Versus 43.16 ± 12.22).





**Fig. 8:** Showed relation between Histopathology results with sex

Previous bar chart shows difference in the gender distribution among histopathology, with a higher percentage of females having benign lesions (58.6%) than

males (41.4%) and a higher percentage of males having malignant lesions (64%) than females (36%).

**Table 6:** Relation between Histopathology results with Bethesda category score

		Histopathology		Test value*	P-value	Sig.
		Benign (58)	Malignant (25)			
# Bethesda score	B1	Excluded (0.0%)	Excluded (0.0%)	51.315	<0.001	HS
	B2	46 (79.3%)	3 (12%)			
	B3	9 (15.5%)	3 (12%)			
	B4	2 (3.4%)	6 (24%)			
	B5	1 (1.7%)	7 (28%)			
	B6	0 (0.0%)	6 (24%)			
Bethesda score	B2	46 (80.7%)	3 (12%)	42.350	<0.001	HS
	B3+B4	11 (19%)	9 (36%)			
	B5+B6	1 (1.8%)	13 (52%)			
**Bethesda III & IV	FN	2 (10.0%)	4 (40.0%)	7.200	0.066	NS
	FLUS	6 (60.0%)	4 (40.0%)			
	AUS	3 (30.0%)	0 (0.0%)			
	SFN	0 (0.0%)	1 (20.0%)			

P-value >0.05: Non significant (NS); P-value <0.05: Significant (S); P-value < 0.01: highly significant (HS)

\*: Chi-square test

# Bethesda grade I was excluded.

According to the previous table, there was a statistically significant relationship observed between histopathology results and preoperative Bethesda score, Histopathology and Bethesda II, Bethesda III + IV, Bethesda V + VI with

(p-value 0.001), but no statistically significant relationship was observed between histopathology and Bethesda III and IV subtypes with (p-value=0.066).



**Table 7:** Postoperative histopathological results according to besthesda category score

Diagnostic Category of TBSRTC	No.(83) (100%)	Postoperative Histopathology		Risk of malignancy(%)
		Benign	Malignant	
I	0	0	0	Not applicable
II	49 (59.0%)	46	3	6.1%
III	12 (14.5%)	9	3	25.0%
IV	8 (9.6%)	2	6	75%
V	8 (9.6%)	1	7	87.5%
VI	6 (7.2%)	0	6	100.0%

TBSRTC: The Bethesda System for Reporting Thyroid Cytology. Thyroid preoperative FNAC results based on

the Bethesda system correlated with final postoperative Histopathology reports.

**Table 8:** Diagnostic accuracy of fine needle aspiration (FNA) results according to postoperative histopathological results.

	HPE malignant	HPE benign	Total no.
Besthesda categories (IV, V, VI) (probably Malignant)	19	3	22
Besthesda categories (II, III) (probably Benign)	6	55	61
Total	25	58	83

## DISCUSSION

In this study, we aimed to assess our 1-year experience with TBSRTC categorization of FNAC and institutional implied malignancy risks for each group. Our findings can help future patients be managed more accurately.

In our study TBSRTC I was excluded because our institution routinely repeated FNAC to this category in order to upgrade its category for proper decision making for each patient, and it is difficult to assess the malignancy risk for the non-diagnostic category (ND) because only a small percentage of ND nodules undergo operation.

Ultrasound guidance and on-site specimen adequacy evaluation were strongly advised to reduce the percentage of unsatisfactory biopsies<sup>[6]</sup>. We perform FNAB under ultrasound guidance on a regular basis at our institution, but no on-site assessment was performed.

In our study the risk of malignancy for category II was 6.1%, which is slightly higher than the 0-3% reported by TBSRTC in this category. The implied malignancy risk for category II is 0-3%, with clinical follow-up of patients recommended as management for them. Despite the fact that thyroidectomy is not recommended for category II patients, patients in our study were operated on primarily for cosmetic and pressure symptoms.

In our study, the diagnosis of TBRSTC III was proposed to be 25% of thyroid FNABs, which is

consistent with the TBRSTC (6-18%). This category's interpretation, which includes "atypia of unknown significance" and "follicular lesion of unknown significance," varies greatly between pathologists and institutions.

Layfield *et al.*, found a range of 2.5-28.6% between individual pathologists and 3.3-14.9% between three academic institutions<sup>[7]</sup>. Because confirmatory diagnosis is only available in a small number of patients selected for operation who have suspicious clinical or U/G characteristics, determining the actual risk of malignancy in category III is difficult.

Patients were also subjected to selection bias, which exaggerates the prevalence of cancer<sup>[8]</sup>. A study done by Park *et al.*, found that the malignancy risk in AUS/FLUS cases was 69%, which was higher than our study and TBSRTC guidelines. This was due to the fact, that patient highly suspicious for malignancy had surgery without FNA repetition.

Our study had (9.6%) cases category V suspicious for malignancy (SN) and (7.2%) malignant cases Category VI with risk of malignancy 87.5% and 100% respectively which was in good correlation with Partyka *et al's* study. Histologic follow-up revealed no false positives for lesions that were cytologically interpreted as definitively malignant, - in other words, no false positives in the positive for malignancy category. However, one case of follicular adenoma was a false positive for cases that were cytologically interpreted as suspicious for malignancy Bethesda V<sup>[9]</sup>.

The risk of malignancy ROM of category II in our study was comparable to the findings of Wu *et al.*<sup>[10]</sup> This ROM 6.1% (3/49) was due to the misclassification of two papillary carcinomas and one follicular carcinoma as benign TBRSTC. When compared to Wu *et al.*<sup>[10]</sup> study, our study was able to precisely predict the ROM of TBSRTC III, IV, V and VI, which could be attributed to our institute's routine practice of correlating cytology with clinical, biochemical, and radiological features. When compared to Wu *et al.*<sup>[10]</sup> study, the FN/SFN TBRSTC IV category had a ROM of 75% (6/8) after analysis of post-operative histopathology one case had nodular goitre and the other had papillary hyperplasia and this illustrates the negative two cases in this category, both of which were classified as TBSRTC IV lesions. Another reason could be the difference in sample size and the lower number of cases in our study.

## CONCLUSION

In conclusion, our study demonstrates that the diagnostic approach used for reporting thyroid FNA proposed by the NCI Thyroid FNA Scientific Conference is an excellent screening test in identifying patients who may have thyroid papillary carcinomas and other thyroid malignancies, with an acceptable sensitivity (76%) and specificity (94.83%) by adhering to strict cytologic criteria, with few false positives. Furthermore, each diagnostic category conveys a different level of cancer risk to direct caregivers.

## CONFLICT OF INTEREST

There are no conflicts of interest.

## REFERENCES

- Asotra S & Sharma J (2008): Role of AgNORs in thyroid lesions on fine needle aspiration cytology smears. *Journal of Cytology*. 25(1):18-21.
- Sengupta A, Pal R, Kar S, Zaman FA, Sengupta S, Pal S (2011): Fine needle aspiration cytology as the primary diagnostic tool in thyroid enlargement. *Journal of natural science, biology, and medicine*. 2(1):113-116.
- Sirry MA, Abdelwahab EM, Abdelaziz HT & Badr MF (2018): A study of correlation of fine-needle aspiration cytology with postoperative histopathological examination in patients with either solitary thyroid nodule or multiple nodules. *The Scientific Journal of Al-Azhar Medical Faculty, Girls*. 2(2):41-44.
- Ahn SS, Kim E-K, Kang DR, Lim S-K, Kwak JY, Kim MJ (2010): Biopsy of thyroid nodules: comparison of three sets of guidelines. *American Journal of Roentgenology*. 194(1):31-37.
- Algin O, Algin E, Gokalp G, Ocakoğlu G, Erdoğan C, Saraydaroglu O, *et al.* (2010): Role of duplex power Doppler ultrasound in differentiation between malignant and benign thyroid nodules. *Korean journal of radiology*. 11(6):594-602.
- Chamorro FMM, Calle JA, Stein JE, Merchancano L, Briñez AMM, Wilches AaP (2018): Experience of the implementation of rapid on-site evaluation in ultrasound-guided fine-needle aspiration biopsy of thyroid nodules. *Current Problems in Diagnostic Radiology*. 47(4):220-224.
- Layfield LJ, Morton M, Cramer HM, Hirschowitz S (2009): Implications of the proposed thyroid fine-needle aspiration category of "follicular lesion of undetermined significance": a five-year multi-institutional analysis. *Diagnostic cytopathology*. 37(10):710-714.
- Ho AS, Sarti EE, Jain KS, Wang H, Nixon IJ, Shaha AR, *et al.* (2014): Malignancy rate in thyroid nodules classified as Bethesda category III (AUS/FLUS). *Thyroid*. 24(5):832-839.
- Partyka KL, Huang EC, Cramer HM, Chen S, Wu HH (2016): Histologic and clinical follow-up of thyroid fine-needle aspirates in pediatric patients. *Cancer cytopathology*. 124(7):467-471.
- Wu H, Rose C, Elsheikh TM (2012): The Bethesda system for reporting thyroid cytopathology: an experience of 1,382 cases in a community practice setting with the implication for risk of neoplasm and risk of malignancy. *Diagnostic cytopathology*. 40(5):399-403.