

Allen's Based Algorithm for Management of Fingertip Injuries in EL Helmya Armed Forces Hospital

Original
Article

Omar Hany Shawer, Mohamed Mamdouh AbdelHalim, Mohamed Samir Badawy, Ahmed Harfoush, Tarek Elmenoufy and Ahmed El Badawy

Departments of Plastic, Reconstructive and Burn Surgery, Armed Forces College of Medicine, Cairo, Egypt.

ABSTRACT

Background: Hand trauma especially fingertip injury is one of the commonest presentations in emergency departments. Fingertip reconstruction is a delicate procedure and there are different approaches for fingertip repair ranging from the simplest procedure to the most sophisticated one to achieve the best functional outcome. The study aims to establish an algorithm for the best reconstructive options for each type of fingertip injuries according to the experience of El Helmya Armed Forces Hospital.

Patients and Methods: This is a retrospective cohort study for different approaches for each type of fingertip injuries and was conducted on all admitted patients with fingertip injuries from January 2018 to January 2021 in El Helmya Armed Forces Hospital, Egypt.

Results: From 282 patients who met our inclusion criteria, the index finger was the most commonly injured in 83 patients (29.4%) while the thumb finger was the least injured one in only 19 patients (6.7%). 107 patients (37.9%) were classified according to Allen's classification as type I injury followed by type III injury in 65 patients (23%). Healing by secondary intention was the most prevalent option for the management of type I injuries in 31 patients (29%) while shortening and direct closure procedure was the commonest strategy for the management of type IV injuries in 36 patients (70.6%).

Conclusion: Algorithms for the management of fingertip injuries may be different for military people because patients' occupations and early return to the field with minimal disability are cornerstones for treating such injuries.

Key Words: Amputation, classification, hand trauma, nail bed injury, reconstruction.

Received: 8 November 2022, **Accepted:** 21 November 2023

Corresponding Author: Omar Hany Shawer, MSc, Departments of Plastic, Reconstructive and Burn Surgery, Armed Forces College of Medicine, Cairo, Egypt. **Tel.:** 01005957869, **E-mail:** Omarhany9600@gmail.com

ISSN: 2812-5509, 2023, Vol. 1, No. 1

INTRODUCTION

The hand is a very precious part of the body which represents an important tool in nonverbal communication, social interactions and productivity^[1]. Fingertip is the portion distal to flexor digitorum superficialis insertion anteriorly and lateral slips of extensor tendons insertion dorsally. It is responsible for sensation, delicate motor activities and hand aesthetics^[2].

Fingertip injuries are the commonest presentation of traumatic hand injuries in emergency departments^[3]. The ultimate goal for any fingertip reconstruction is maximizing restoration of fingertip contour, aesthetic outcome, padding sensation, pain-free pulp, preservation of digit length, early return to work, and preservation of nail bed as possible^[4].

So, there are many options for fingertip reconstruction including healing by secondary intention, skin grafting, and local, regional and free flaps^[5]. Unfortunately, there is weak evidence to support any algorithm for fingertip injuries treatment among US and worldwide hand surgeons.

Management recommendations are preferences disparate and evidence-based articles are extreme-ranging^[6].

PATIENTS AND METHODS:

This retrospective cohort study was conducted on all admitted patients of both sexes with fingertip injuries and amputations at or above the level of the distal interphalangeal joint from January 2018 to January 2021 in El Helmya Armed Forces Hospital, Egypt.

This study was revised and approved by the Armed Forces College of Medicine Ethical Review Committee (33/ 25-9-2021) and approval was obtained from the hospital management for access to the patients' files.

Patients with amputation proximal to distal interphalangeal joint or other hand trauma were not included in this study. Also, patients with multiple digits trauma or multiple-level amputations or associated life-threatening trauma were excluded from this study.

According to Allen's classification^[7], all included patients are categorized into four groups:

- **Allen's type 1:** involving pulp injury only without exposed bone.
- **Allen's type 2:** involving pulp and nail bed injury with exposed bone.
- **Allen's type 3:** involving partial loss of distal phalanx with exposed bone.
- **Allen's type 4:** involving injury proximal to the lunula with exposed bone.

Patients of each group were evaluated for the type of surgical intervention and involved digit.

Then, the data were analyzed by SPSS (statistical package for social science) version 26.0 on IBM compatible computer (SPSS Inc., Chicago, IL, USA). The qualitative data was described as numbers and percentages and analyzed by using Chi square test and Fisher's exact test. Quantitative data were tested for normality using Shapiro-Wilks test, assuming normality at $P > 0.05$. Quantitative data were described as mean, standard deviation and range, using Student's "t" test, if normally distributed, or Mann-Whitney U test, and Kruskal-Wallis test, if not normally distributed. The accepted level of significance in this work started at 0.05 ($P < 0.05$ was considered significant).

RESULTS:

341 patients were admitted to the hospital from January 2018 to January 2021 and 282 patients met our inclusion criteria with ages ranging from 12 – 51 years (mean of 25.17). 275 patients (97.5%) were males and 7 patients (2.5%) were females. 131 patients (46.5%) had non-skillful occupations and 95 patients (33.7%) had no occupation. 35 patients (12.4%) had skillful occupations, 17 patients (6%) had a government job and 4 patients (1.4%) with a professional job.

249 patients (88.3%) were right-handed and 33 patients (12.7%) were left-handed. The sociodemographic and clinical data of included patients were declared in (Table 1).

Allen's based algorithm for management of fingertip injuries for each finger:

1- Thumb: healing by secondary intention was the most prevalent strategy for management of Allen's type I injuries in 3 patients (60%) while Moberg flap was commonly used for management of Allen's type II injuries in 3 patients (60%). The first dorsal metacarpal artery flap was the workhorse option for the management of Allen type III & IV injuries in 7 patients (78%) (Figure 1).

2. Index finger: healing by secondary intention was the preferred strategy for the management of Allen type I injuries in 10 patients (40%) while Homo-digital island flap was the most used option for the management of Allen type II & III injuries in 17 patients (43%). Bone shortening & direct closure was the commonest option for the management of Allen type IV injuries in 11 patients (61%) (Figure 2).

3. Middle finger: full thickness skin graft & V-Y flap were the commonest strategies used for the management of Allen type I injuries in 6 patients (29%) for each. while homo-digital island flap was the workhorse option for the management of Allen type II, III & IV injuries in 25 patients (57%) (Figure 3).

4. Ring finger: full thickness skin graft was the commonest strategy for the management of Allen type I injuries in 10 patients (38%) while V-Y flap was the preferred procedure for Allen's type II injuries management in 8 patients (73%). Cross-finger flap was reserved for the management of Allen type III injuries in 8 patients (67%) while Bone shortening & direct closure was the only procedure done for the management of Allen type IV injuries in 10 patients (100%) (Figure 4).

5. Little finger: full thickness skin graft was the most used procedure for the management of Allen type I injuries in 10 patients (53%). V-Y flap was commonly used for the management of Allen type II injuries in 6 patients (67%) while Bone shortening & direct closure was reserved for the management of Allen type III & IV injuries in 13 patients (68%) (Figure 5).

From previous data, an algorithm for management of different types of fingertip injuries for each digit could be concluded as shown in (Table 2).

Table 1: Showing the sociodemographic characteristics and clinical data of included patients.

		No. (N=282)	%
Gender	Male	275	97.5
	Female	7	2.5
Occupation	Skillful	35	12.4
	Non-skillful	131	46.5
	Governmental	17	6
	Professional	4	1.4
Smoking	Non- working	95	33.7
		145	51.4
Dominant hand	Right	249	88.3
	Left	33	11.7
Affected hand	Right	150	53.2
	Left	132	46.8
Comorbidities	Hypertension	6	2.1
	Diabetes mellitus	2	0.7
	Ischemic heart disease	3	1.1
Mode of trauma	Crushing	125	44.3
	Sharp	157	55.7
Availability of amputated part		23	8.2
Allen's classification	Type I	107	37.9
	Type II	59	20.9
	Type III	65	23
	Type IV	51	18.1
Affected finger	Thumb	19	6.7
	Index	83	29.4
	Middle	73	25.9
	Ring	59	20.9
	Little	48	17
Procedure	Composite graft	13	4.6
	Cross finger flap	31	11
	First dorsal metacarpal artery flap	9	3.2
	Full-thickness skin graft	42	14.9
	Healing by secondary intension	31	11
	Heterodigital island flap	6	2.1
	Homodigital island flap	36	12.8
	Hypothenar flap	3	1.1
	Moberg flap	7	2.5
	Shortening and direct closure	53	18.8
	Split-thickness skin graft	8	2.8
	Thenar flap	3	1.1
	V-Y flap	40	14.2
	Re-implantation	0	0
Reversed cross finger	0	0	

Table 2: Algorithm for fingertip injuries reconstruction.

	Thumb	Index finger	Middle finger	Ring & Little fingers
	<ul style="list-style-type: none"> • Conservative treatment 	<ul style="list-style-type: none"> ➤ Conservative treatment 	<ul style="list-style-type: none"> • Full-thickness skin graft 	<ul style="list-style-type: none"> ➤ Full-thickness skin graft
Allen's type I	<ul style="list-style-type: none"> • Moberg flap 	<ul style="list-style-type: none"> ➤ Full-thickness skin graft ➤ Homo-digital Island flap 	<ul style="list-style-type: none"> • V-Y flap • Conservative treatment 	<ul style="list-style-type: none"> ➤ Conservative treatment
Allen's type II	<ul style="list-style-type: none"> • Moberg flap • First dorsal metacarpal artery flap 	<ul style="list-style-type: none"> ➤ Homo-digital Island flap ➤ V-Y flap 	<ul style="list-style-type: none"> • Homo-digital Island flap • Bone shortening & direct closure • V-Y flap 	<ul style="list-style-type: none"> ➤ V-Y flap ➤ Cross-finger flap
Allen's type III	<ul style="list-style-type: none"> • First dorsal metacarpal artery flap • Moberg flap 	<ul style="list-style-type: none"> ➤ Homo-digital Island flap ➤ Cross-finger flap 	<ul style="list-style-type: none"> • Homo-digital Island flap • Cross-finger flap 	<ul style="list-style-type: none"> ➤ Bone shortening & direct closure ➤ Cross-finger flap
Allen's type IV	<ul style="list-style-type: none"> • First dorsal metacarpal artery flap 	<ul style="list-style-type: none"> ➤ Bone shortening & direct closure ➤ Homo-digital Island flap 	<ul style="list-style-type: none"> • Homo-digital Island flap • Bone shortening & direct closure 	<ul style="list-style-type: none"> ➤ Bone shortening & direct closure

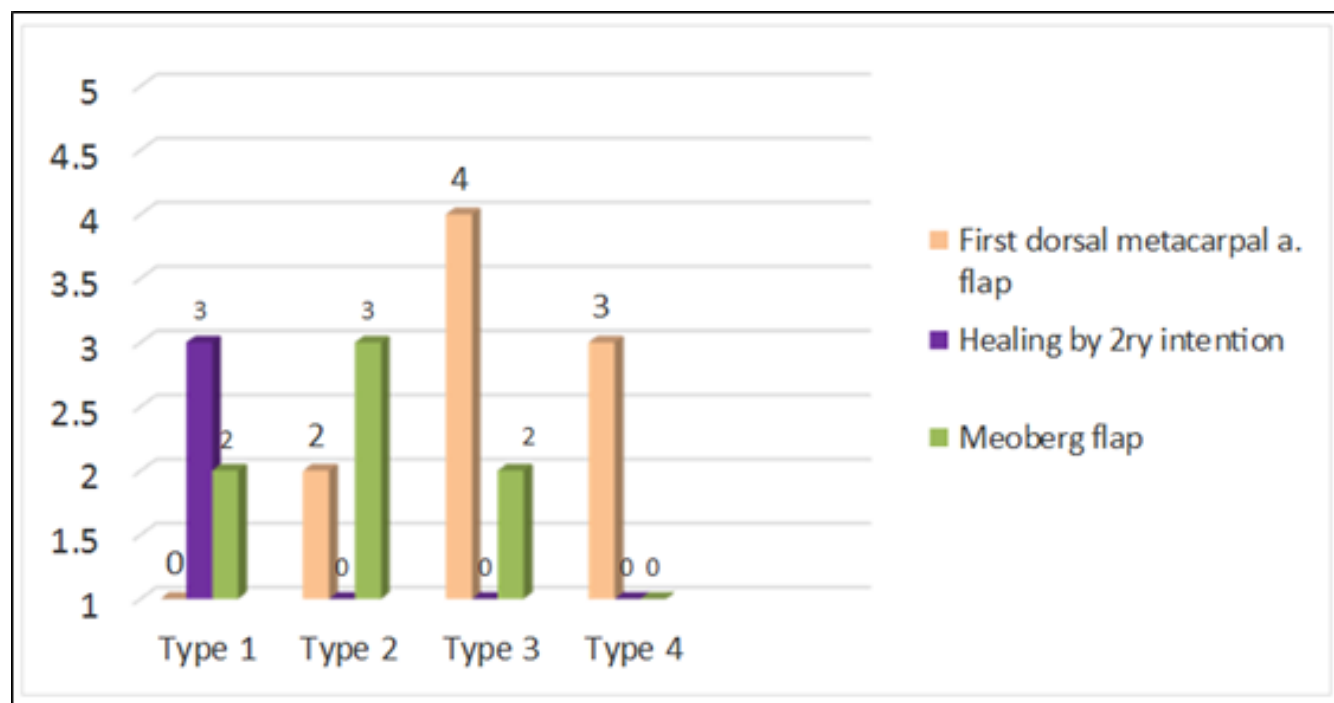


Fig. 1: Allen's classification and procedures done for thumb injuries.

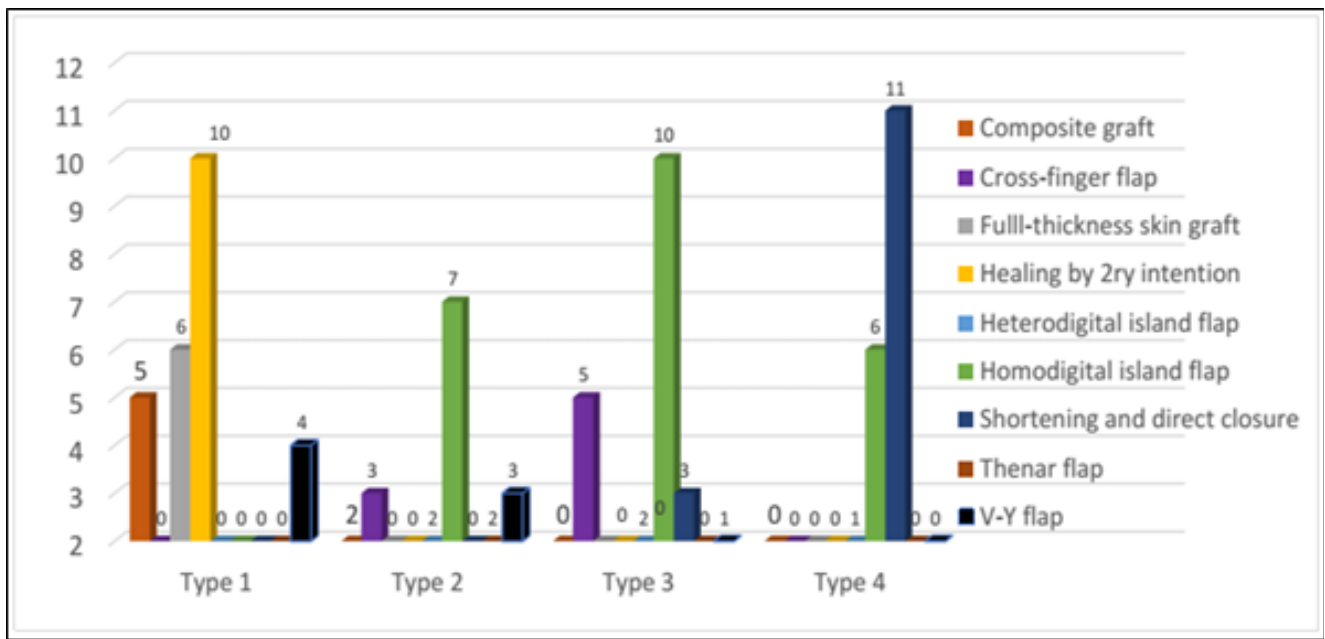


Fig. 2: Allen's classification and procedures done for index finger injuries.

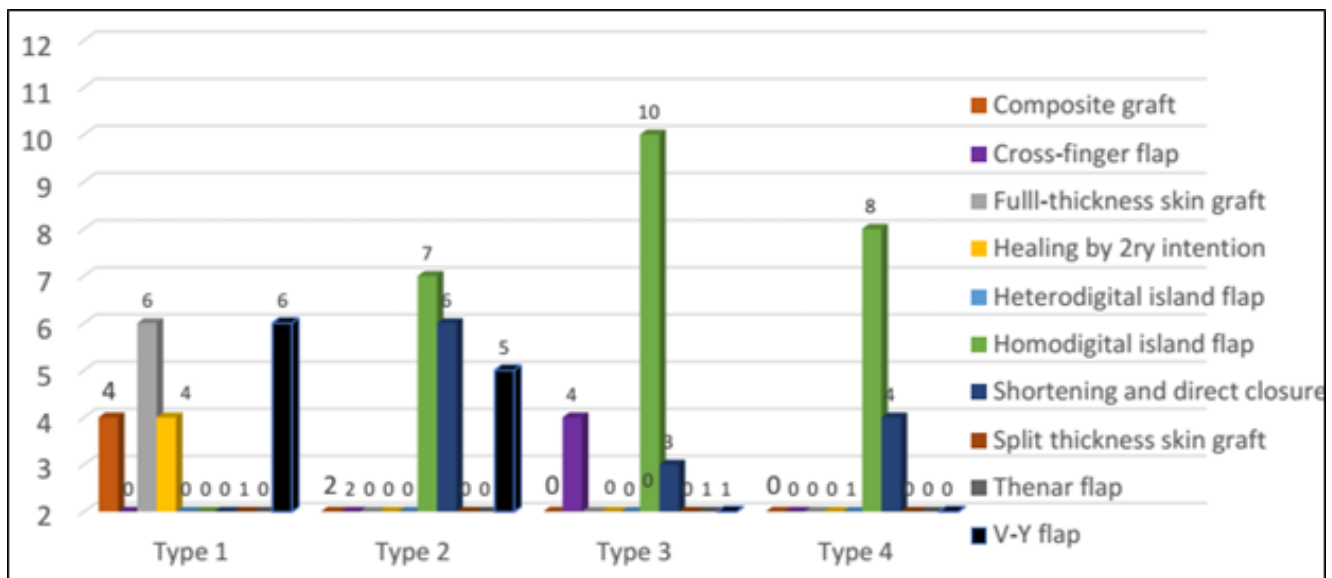


Fig. 3: Allen's classification and procedures done for middle finger injuries.

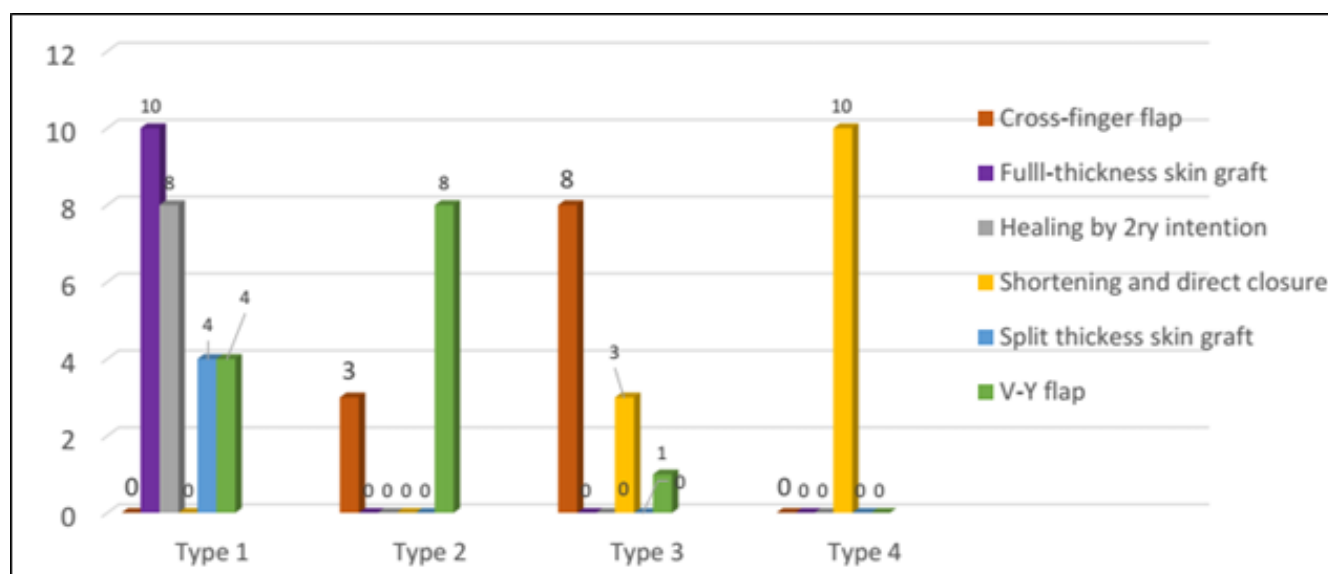


Fig. 4: Allen's classification and procedures done for ring finger injuries.

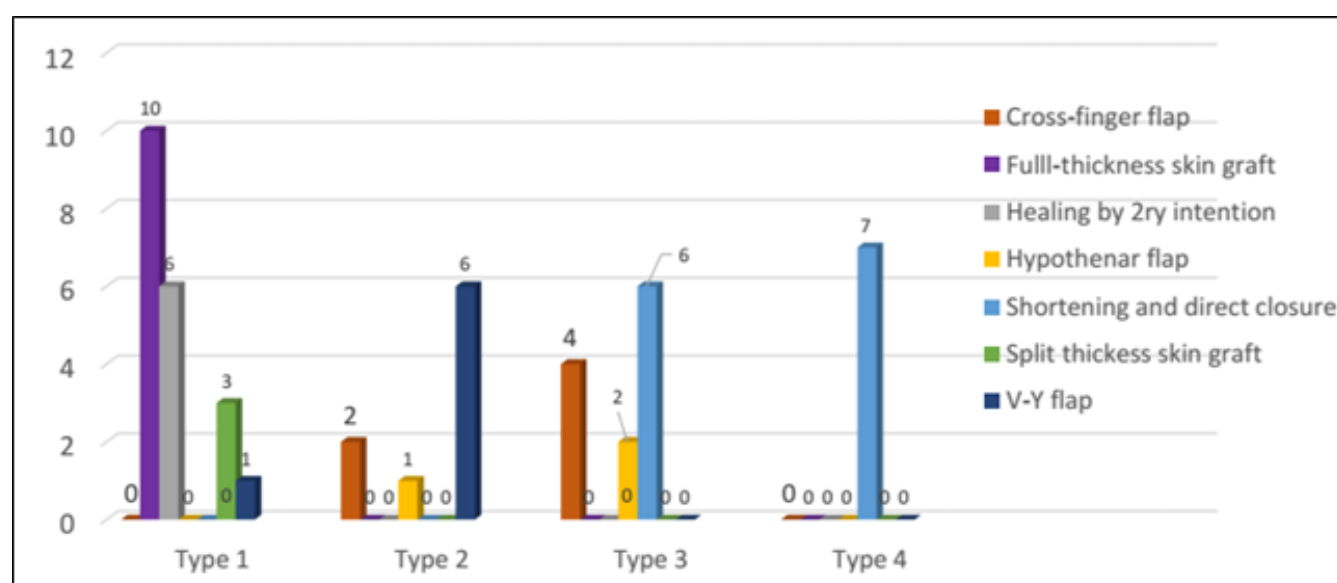


Fig. 5: Allen's classification and procedures done for little finger injuries.

DISCUSSION

El Helmya Armed Forces hospital is a tertiary hand trauma center that specialized in the management of all types of hand trauma and fingertip injuries. The hospital deals with patients of both sexes and all age groups whether they were military people or civilians. Although the large flow rate to the hospital, there is no settled protocol for the management of fingertip injuries.

The aim of any algorithm for fingertip reconstruction is to maximize the functional outcomes, like sensation recovery, restoration of movement, preservation of

digit length, aesthetic appearance and early return to daily activities, which fits each group of patients according to their characteristics^[8].

Military people are different in their management as many factors could affect the choice of the most suitable procedure for the management of such injuries. Factors like the profession of patients and prompt return to duty with almost no complications have to be taken into consideration in determining the procedure of choice.

In our study, it was found that healing by secondary intention and full-thickness skin graft were

the commonest procedures for the management of Allen's type I injuries while homodigital island flap and V-Y flap were the most prevalent techniques for management of Allen's type II injuries. Homodigital island flap, cross finger flap, skeletal shortening and direct closure were frequently used for the management of Allen's type III injuries while bone shortening and direct closure procedure was obviously used for the management of Allen's type IV injuries.

Regarding our algorithm, our results were supported by a study that found in their survey study among the united states and international hand surgeons for the most common six procedures for the management of fingertip injuries based on Allen's classification^[6].

On the contrary, another study concluded an algorithmic approach for fingertip injuries management based on defect size and injury geometry and this was unlike our work^[8].

CONCLUSION

The fingertip is a crucial part of the hand, So, an interprofessional approach to fingertip injuries is essential to limit morbidity. The choice of the most suitable management option depends on a triad of surgeon factors (experience & skills), Patient factors (age, sex & occupation) and defect analysis (injured finger, type of injury and bone exposure).

CONFLICT OF INTEREST

There are no conflicts of interest.

REFERENCES

1. Johnson SP, Sebastin SJ, Rehim SA, Chung KC. The importance of hand appearance as a patient-reported outcome in hand surgery. *Plast Reconstr Surg - Glob Open*. 2015;3(11):1–10.
2. Venkatesh A, Khajuria A, Greig A. Management of pediatric distal fingertip injuries: A systematic literature review. *Plast Reconstr Surg - Glob Open*. 2020;1–8.
3. Bjorklund KA, Rice DM, Amalfi AN. Pediatric Digital Necrosis Secondary to Dressing Application: A Case Series. *Hand*. 2018;13(4):NP14–6.
4. Hassan K. The Role of Reversed Homodigital Island Flap in Digital Reconstruction. *Egypt J Plast Reconstr Surg*. 2020;43(3):575–80.
5. Martin-Playa P, Foo A. Approach to Fingertip Injuries. *Clin Plast Surg* [Internet]. 2019;46(3):275-83. Available from: <https://doi.org/10.1016/j.cps.2019.02.001>
6. Miller AJ, Rivlin M, Kirkpatrick W, Abboudi J, Jones C. Fingertip Amputation Treatment: A Survey Study. *Am J Orthop (Belle Mead NJ)*. 2015;44(9):E331-9.
7. Allen MJ. Conservative management of finger tip injuries in adults. *Hand*. 1980;12(3):257-65.
8. Lemmon JA, Janis JE, Rohrich RJ. Soft-tissue injuries of the fingertip: Methods of evaluation and treatment. An algorithmic approach. *Plast Reconstr Surg*. 2008;122(3):105-17.