

## The Effect of Sildenafil Citrate (Viagra®) on Nasal Olfactory Mucosa of Adult Male Albino Rat: Caspase-3 and Inducible Nitric Oxide Synthase Protein Expressions

Diaa El Din M. El Hennawi<sup>1</sup>, Mohamed R. Ahmed<sup>1</sup>, Mohamed T. El Tabbakh<sup>1</sup>, Ahmed S. Abdelrehem<sup>1</sup> and Amina A. Dessouki<sup>2\*</sup>

<sup>1</sup>Otorhinolaryngology Department, Faculty of Medicine, Suez Canal University, Ismailia, Egypt

<sup>2</sup>Pathology Department, Faculty of Veterinary Medicine, Suez Canal University, Ismailia, Egypt

### ABSTRACT

Like all human senses, the sense of olfaction (smell) plays an important role in person's life. The sense of smell serves as a first warning signal, warning to the smoke of a fire, spoiled food, or the odor of a natural gas leak or dangerous fumes. Olfactory mucosa is a component of nervous system which regenerate throughout person's lifetime. Dysfunction of olfactory sensitivity may be a side effect of chronic use of high sildenafil doses. Sildenafil is oral drug effective for erectile dysfunction in men, and approximately 20% of patients complain about nasal congestion after sildenafil administration. Aim of this study was to evaluate effect of long-term sildenafil administration on rat olfactory mucosa. Forty-five male albino rats were divided into three equal groups, group I kept as control. Rats in groups II and III received sildenafil citrate orally at doses of 50 mg/kg and 100 mg/kg, respectively for three months. At the end, olfactory mucosa removed, fixed in proper fixations for histopathology, immunohistochemistry, and SEM. Results revealed that rats treated with high dose of sildenafil revealed loss of smell as well as alteration of histological pictures, immunohistochemical staining of apoptotic markers and SEM of olfactory mucosa while the rats in group II revealed normal sense of olfaction and normal histology of olfactory mucosa. In conclusion, chronic use of 100 mg sildenafil citrate led to olfactory dysfunction through stimulation of iNOS and Caspase 3 apoptotic markers whereas low dose needs further investigation and may introduce a prospective therapy for a post COVID 19 dysfunction.

**Keywords:** Caspase 3; Electron microscope; iNOS; Olfactory mucosa.



### INTRODUCTION

Olfaction is one of the five primary human senses that enables individuals to detect various dangers, including fire or toxic fumes. Olfactory dysfunction is commonly associated with several conditions, such as poor mental health, reduced cognition, and decreased appetite (Boesveldt and Parma, 2021; Hura *et al.*, 2020). Furthermore, the impairment of the sense of smell has a detrimental impact on an individual's overall quality of life (Boesveldt and Parma, 2021; Hura *et al.*, 2020).

Olfactory loss has been identified as one of the common symptoms related to COVID-19 infection (Jafar *et al.*, 2021). Olfactory disturbances have a wide-ranging impact on the lives of patients, as there is a lack of knowledge of the disorder among clinicians, so there is a need to improve our understanding of olfactory disturbance (Erskine and Philpott, 2020). Olfactory disturbance can be also occurred due to the use of certain medications and can also be a symptom of psychiatric disease, and growing evidence connects olfactory problems to serious neurodegenerative disease even death (Schubert *et al.*, 2017). The olfactory region is situated at the top of the nasal cavity, and its neuroepithelium is the only portion of central nervous system that is immediately exposed to the outside environment. The olfactory mucosa is lined by pseudostratified columnar epithelium that comprises basal cells, supporting cells, microvillar cells, and olfactory cells.

Olfactory receptors (receptors for scent perceptions) and tiny serous glands are also present in olfactory regions. The olfactory epithelium has a total surface area of 200-400 mm (Ross and Pawlina, 2006, Purves *et al.*, 2001). The structure, function, and physiology of olfactory mucosa are poorly understood. It contains the specialized sensory organ of smell, which is a component of the nasal mucosa. Depressive symptoms and mood swings are brought on by olfactory system diseases (Nordin and Brämerson, 2008). In addition, Olfactory sensory neurons are located within the nasal cavity and are constantly replaced by new neurons derived from stem cells, making the olfactory system one of uncommon nervous system systems that can undergo regeneration throughout life.

Olfactory dysfunction can be brought on by a variety of factors, including ageing, head injuries, brain tumor removal, neurodegenerative diseases, and infection. This disorder has a negative impact on patient life quality, mental well-being, memory abilities, mortality rate and nutritional status (Beecher *et al.*, 2018). One of medications that altered sense of olfaction is sildenafil citrate. Sildenafil is the approved medication for treating erectile dysfunction specifically inhibits phosphodiesterase 5 (PDE5), an isozyme in the corpus cavernosum that degrades cyclic guanosine monophosphate (c-GMP). Because cGMP levels are rising, nitric oxide (NO), a relaxing agent produced by the endothelium, causes smooth muscle relaxation and blood vessel dilation. Sildenafil elevates c-GMP levels and improves effects of NO on vascular smooth muscle

\* Corresponding author e-mail: [aminadessouki@vet.suez.edu.eg](mailto:aminadessouki@vet.suez.edu.eg)

dilatation via inhibiting PDE5 (Senthilkumar *et al.*, 2007). Approximately 20% of patients treated with sildenafil for erectile dysfunction complain of nasal congestion after using sildenafil. Increased sildenafil dosages may result in diminished olfactory sensitivity (Gudziol *et al.*, 2007).

Nitric oxide (NO) levels control neuronal differentiation and cell division in epithelial cell cultures of adult olfactory. Nitric oxide synthase (NOS) inhibition decreased neural progenitor proliferation and promoted neuronal differentiation. NO release had the opposite impact. These findings imply that NOS expression and activity could be increased in the olfactory epithelium through regeneration, promoting the proliferation of neural precursor cells (Sülz *et al.*, 2009). The inducible (iNOS) and neuronal (nNOS) isoforms of this enzyme appear to be involved in this action, although the underlying mechanism is unclear. In other parts of the nervous system, it has been documented that NO has a mitogenic impact as a mechanism of injury-induced regeneration (Sun *et al.*, 2005).

The emergence of many resistant cases of post COVID, smell disorders attract our attention to proceed with this research. So, the aim of this study was to investigate the influence of long-term sildenafil administration on rat olfactory mucosa through histopathological, scanning electron microscopy examinations and immune-histochemical detection of caspase-3 and inducible nitric oxide synthase protein expression.

## MATERIALS AND METHODS

Forty-five Male albino rats that were in good health and weighed 200–250 g, age range from 7- 10 weeks were obtained from pharmaceutical Pharco Company, Cairo, Egypt. The research ethics committee of the Suez Canal University in Ismailia, Egypt, described the protocols and rules for using experimental animals, and these were followed throughout the experiment. Prior to the studies, Each and every rat was kept in common plastic cages with a sawdust-covered floor to minimize the possibility of harmful contact with the hard surface of the cages under the proper condition such as temperature, light (25–27°C and a 12-hour light/dark cycle), and relative humidity around 50–60%, in a well-ventilated room with unrestricted to drinking water from the tap, and on a standard granulated ration made in accordance with MRC and containing crude protein of 21%, crude fat of 5%, and crude fibers of 3%. Prior to the trial, the animals spent two weeks acclimated to the lab environment.

### Buried Food Test

The buried food test evaluates how quickly an animal that has been fasting overnight can find a piece recognizable, palatable food—like cookies, cereal, chocolate chips, or food pellet, buried behind a layer of bedding. According to the idea, rat with access to limited food are likely to suffer olfactory impairments if they can't employ odour cues to find the food within

15 minutes. Most rats with normal olfactory abilities can locate the hidden food item within minutes. The rats' olfactory abilities were tested using the "buried food test," which enables them to locate the food beneath the wood chips in less than five minutes. According to Yang and Crawley (2009), the test on the buried food was conducted. The buried food test was done at the beginning of the study to exclude any rats with disturbed olfactory function. Sildenafil citrate (Viagra); Sildenafil citrate as a 100mg tablet was provided from Pfizer, Egypt as a 100mg tablet for oral administration. The sildenafil citrate (100mg) tablet was crumbled and diluted in distilled water.

### Experimental Design

The animals were divided into three equal groups. For 3 months the control group received 0.5 cc of distilled water orally, the low dose group received 5 mg/kg/day of sildenafil citrate and the high-dose group received 10 mg/kg/day of sildenafil citrate (Reagan-Shaw *et al.*, 2008, Loran *et al.*, 2009). The buried food test was repeated at 4, 8 and 12 weeks to assess the olfactory functions for the 3 groups (Yang and Crawley, 2009).

### Tissue sampling

After the end of the experimental trial, rats were euthanized using phenobarbitone then sacrificed and the nasal mucosa (respiratory and olfactory) was removed after death. Olfactory nasal mucosa was obtained from rats (Stamegna *et al.*, 2014).

### Histopathological examination

For histological analysis, nasal olfactory epithelium was fixed in 10% neutral buffered formalin. After being cut into 5-mm-thick sections and placed into tissue cassettes, the specimens were dehydrated in ethanol at increasing concentrations, cleared with xylene, and embedded into paraffin blocks using customary paraffin-embedding procedures. The 5-mm-thick sections were then processed to obtain hematoxylin and eosin (H&E) (Bancroft and Gamble, 2008). Scoring of nasal epithelium for the presence of degeneration, hyperplasia of goblet cells and congestion of blood vessels of lamina propria was done according to (Gibson-Corley *et al.*, 2013) as follow: score 0= no change; 1= <10%; 2= 11-25%; 3= 26-45%; 4= 46-75%; 5=>76%. Lesions in 10 randomly selected fields were examined and averaged. Also scoring of Olfactory cilia heights was scored by the ImageJ program.

### Scanning Electron Microscope (SEM)

Olfactory mucosae were fixed in 2.5% glutaraldehyde for 24 hours at 4°C. The samples were then dried at the critical point and dehydrated using ethanol in gradual concentrations. On metal stubs, dried samples were mounted using double-sided adhesive tape. The specimens were next "sputtered" with a layer of gold that was 100 nm thick using a BIO-RAD sputtering device (Cambridge, England), and they were scanned at various angles using a scanning electron microscope (SEM, Model-JEOL ASID-10, Cambridge Ltd., England) at the National Research Centre in Cairo, Egypt.

## Immunohistochemistry (IHC)

The nasal mucosal sections were first deparaffinized, followed by moistening and submerging in 3% H<sub>2</sub>O<sub>2</sub>. Subsequently, the tissue sections were incubated in a blocking buffer (protein block, serum-free solution; DAKO Corporation, Carpinteria, CA). For the immunohistochemical examination, polyclonal rabbit antibodies against caspase 3 (Rabbit pAb Catalogue No.: A11953, diluted at 1:50) and anti-iNOS (Rabbit pAb Catalogue No.: A0312, diluted at 1:100) from Ab-clonal company, Woburn, MA, USA, were used. The sections were treated with caspase 3/iNOS antibodies overnight. As negative controls, sections were treated with phosphate-buffered saline (PBS) instead. The following day, after washing with PBS, the sections were treated with horseradish peroxidase and a secondary antibody (biotin bovine antirat). To visualize the immunological reaction, 3,3'-Diaminobenzidine chromogen (DAB, Sigma Chemical Co, USA) was applied to the sections after rinsing with PBS. Hematoxylin staining was performed on the sections, followed by washing with distilled water. Finally, the sections were cleared and covered.

Under a light microscope, the sections were evaluated and assigned a score based on the strength of the caspase 3 immunoreaction. This comprehensive immunohistochemical protocol allowed for the specific detection and assessment of caspase 3 and iNOS expression in the nasal mucosal sections.

## Semiquantitative analysis of caspase and iNOS

To quantify the intensity of immunostaining, the Image J software (Crowe and Yue, 2019) was operated. In each group, 10 randomly chosen fields from different parts were examined. The inverse mean density was then calculated to assess the semi-quantitative analysis of caspase and iNOS. This approach allowed for a reliable and objective measurement of the immunostaining intensity, contributing to a comprehensive evaluation of the observed results.

## Statistical analysis

The obtained results were analyzed using SPSS version 20 (SPSS Inc., Chicago). A one-way ANOVA was conducted to examine the statistical significance of the data. Subsequently, the Duncan Multiple Range test was applied to identify specific differences between pairs of means. A significance level of  $p \leq 0.05$  was considered statistically significant. This analysis allowed for a comprehensive assessment of the data and provided insights into the significance of the observed differences. The data presented, in this study, are reported as means with five replicates  $\pm$  SE (standard error).

## RESULTS

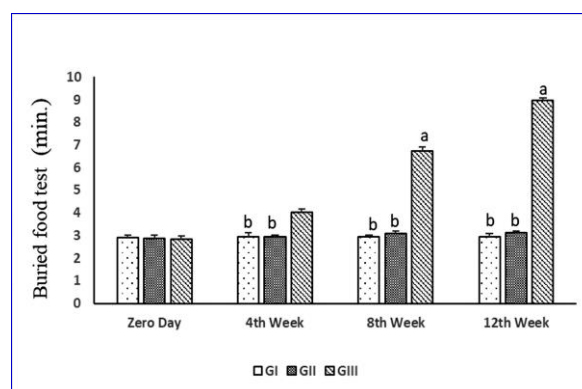
All rats at the beginning of the study spent (average 3 minutes) to find the buried chocolate cookies. Both the control and low dose sildenafil citrate treated rats (50 mg) groups showed non-significant ( $p > 0.05$ ) variations in buried food test along the different times (Day 0, 4th, 8th and 12th weeks). However, high dose

sildenafil citrate treated rats (100 mg) revealed marked ( $p \leq 0.01$ ) time delay in buried food test from the 4th week till the end of the experiment. The prolongation in the time of chocolate cookies found in the high dose group was 3 folds than that in the control group (Figure 1).

## Light microscopic (LM) results

### Olfactory mucosa

In the most examined rats of control group, the olfactory mucosa lined by pseudo stratified columnar epithelium comprises basal cells, olfactory neurons (receptor cells), and supporting cells. The upper part of the epithelium appears to have rows of pale oval-shaped supporting cell nuclei. The lower two-thirds of the epithelium were taken up by olfactory neuron nuclei, and basal cells were situated next to the basal lamina. Group II revealed highly intact mucosa with prominent cilia and mild congestion of blood vessels. Group III, mucosa of rats showed moderate enlargement and swelling of the whole mucosal layer due to severe congestion of the blood vessels and occasional hyperplasia of the mucosa. Mild loss and shortening of olfactory cilia were also observed (Figure2).



**Figure (1)** Buried food test (min.) of control (GI) and sildenafil citrate treated rats (GII: 50 mg/kg and GIII: 100 mg/kg)

## Semi-quantitative scoring of olfactory cilia heights (OCH)

The control and low dose sildenafil citrate-treated (50 mg) groups showed highly significant ( $P \leq 0.01$ ) increase in the morphometric analysis of OCH, when compared to high dose sildenafil citrate-treated rats (100 mg). Moreover, the morphometric analysis of OCH tended to increase in low dose sildenafil citrate-treated (50 mg) group than the control group.

## Scanning Electron Microscopy

The scanning electron micrograph displayed a normal olfactory surface with smooth vesicles and intact bipolarity of olfactory neuron cell. In group II treated rats, the olfactory surface of the nasal cavity exhibited numerous intact bipolar olfactory cells arranged in a normal pattern, characterized by normal cilia and dendrites. However, in the olfactory surface of rats treated with 100 mg sildenafil, numerous olfactory vesicles were observed with a rough, corrugated, and shrivelled surface. Additionally, there was a loss of ciliary surface and a disruption of

bipolarity in both cilia and dendrites (see Figure 3). This finding indicates the detrimental effects of the 100 mg sildenafil treatment on the structure and integrity of the olfactory surface.

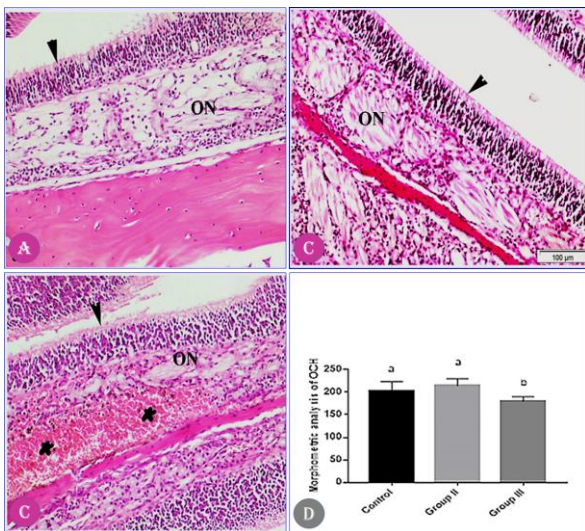
**Immunohistochemistry**

*Immunohistochemistry staining for iNOS*

Immunohistochemistry staining for iNOS of the olfactory mucosa of group I (a and b) showed mild immunoreaction in the nerve fascicles, in the lamina propria and between the olfactory epithelia. Group II (c and d), the olfactory mucosa is mildly reacted in the lamina propria of the mucosa and end olfactory nerves. Group III (e and f), showed deep immunoreaction in the nerve fascicles, in the lamina propria and between the olfactory epithelium and the initial parts of the olfactory nerves (Figure 4).

*Immunohistochemistry staining for Caspase 3*


In the immunohistochemistry staining for Caspase 3, the results revealed varying degrees of immunoreactions in different groups. Group I (a) exhibited mild to moderate immunoreactions of the olfactory mucosa. Group II (b) showed mild immunoreactions of the olfactory mucosa. On the other hand, Group III (c) displayed intense immunoreactions of the olfactory mucosa (Figure 5). These findings provide valuable insights into the differential expression of Caspase 3 in the different groups, suggesting potential variations in the underlying cellular processes and signaling pathways related to apoptosis.



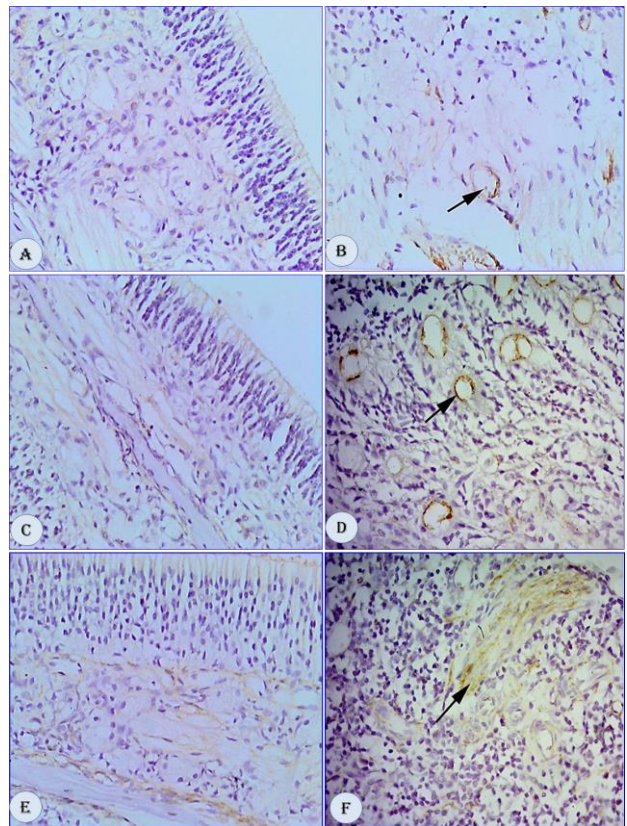
**Figure (2):** Olfactory epithelium of nasal concha: (a) Group I (control) showing normal olfactory mucosa and normal Olfactory neuron (ON), and olfactory cilia (arrowhead). (b), Group II (50 mg/kg sildenafil citrate) showing normal olfactory mucosa with highly prominent olfactory cilia (arrowhead). (c) Group III (100 mg/kg sildenafil citrate) showing detachment of olfactory cilia (arrowhead) and congestion of blood vessels (asterisk). H&E. Bar 100 µm. (d) Morphometric analysis (mean ±SE) of olfactory cilia height (OCH) in sildenafil citrate treated rats. Different superscripts within the same rows indicates significant variation at ( $p \leq 0.01$ )

**Immunohistochemically Scoring**

Regarding the immunostained area percentage of olfactory iNOS, the rats treated with a high dose of sildenafil citrate (100 mg) exhibited a highly significant ( $p \leq 0.01$ ) elevation compared to both the control

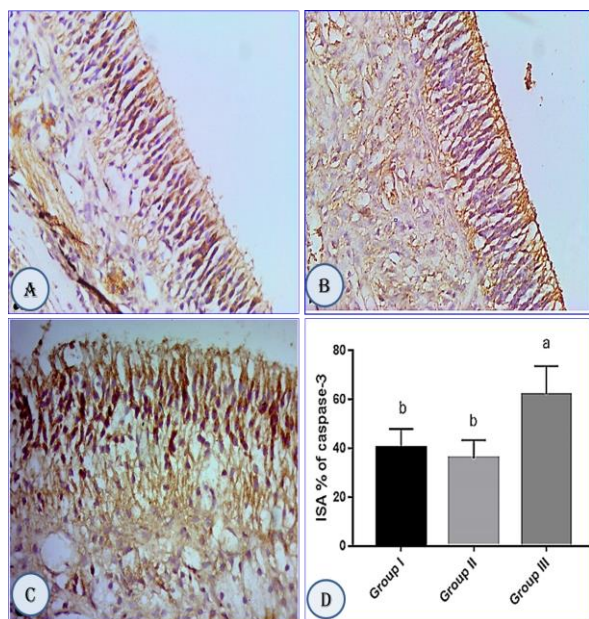


**Figure (3):** Scanning electron micrograph of olfactory mucosa of the nasal cavity in control rats (a) showing typical normal olfactory vesicle (arrow) with smooth normal surface Bar 5µm. Group II (b), showing the bipolar olfactory cells having normal surface and dendrites (arrow), Bar 2µm. Group III (c & d) showing numerous hyperplastic olfactory vesicles (arrow) with rough corrugated surface and loss of ciliary surface. Bar 5µm.

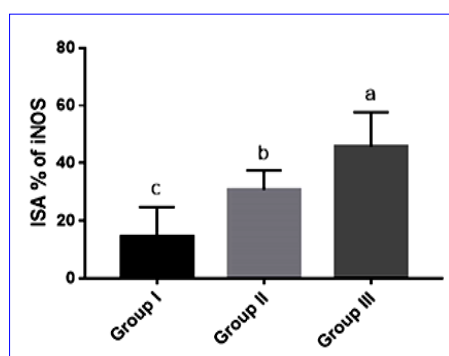


**Figure (4):** Immunohistochemistry staining for iNOS (inducible nitric oxide synthase) in the olfactory mucosa tissue. A and B: Group I (control), displaying mild immunoreactivity in the nerve fascicles, lamina propria, and between the olfactory epithelia. C and D: Group II (50 mg/kg sildenafil citrate), exhibiting mild immunoreactivity in the lamina propria of the mucosa and end olfactory nerves (indicated by arrows). E and F: Group III (100 mg/kg sildenafil citrate), demonstrating intense immunoreactivity in the nerve fascicles, lamina propria, and between the olfactory epithelium and the initial parts of the olfactory nerves (arrow).

and low dose sildenafil citrate-treated (50 mg) groups. Furthermore, the high dose sildenafil citrate-treated rats (100 mg) demonstrated a significant ( $p \leq 0.01$ ) elevation compared to both the control and low dose groups in the immunostained area percentage of olfactory caspase-3 (Figure 6). These findings emphasize the profound impact of sildenafil citrate dosage on the immunostained area percentages of olfactory iNOS and caspase-3, suggesting potential implications for the underlying molecular mechanisms and cellular processes (Fig. 6).



**Figure (5):** Immunohistochemistry staining for Casp 3 of the olfactory mucosa of treated rats. (a), Group I showing mild to moderate immunoreactions of the olfactory mucosa; (b), Group II showing mild immunoreactions of the olfactory mucosa; (c), Group III showing intense immunoreactions of the olfactory mucosa and (d), Immunostained area % (ISA %) of caspase-3 in control (GI) and sildenafil citrate treated-rats (GII: 50 mg/kg and GIII: 100 mg/kg).



**Figure (6):** Immunostained area % (ISA %) of iNOS in control (GI) and sildenafil citrate treated rats (GII: 50 mg/kg and GIII: 100 mg/kg).

## DISCUSSION

Olfaction, the sense of smell, has received relatively less attention compared to other sensory organs such as hearing or sight. However, there is a growing recognition of the need to clarify its functions and mechanisms. Smell plays a significant role in social communication among humans and is considered a

reliable standard in certain contexts. Moreover, the importance of the sense of smell has been highlighted during the COVID-19 pandemic.

Sildenafil citrate, commonly known as Viagra, is a drug used for the treatment of erectile dysfunction, a prevalent medical condition affecting 10%–52% of men (Tharakan and Manyam, 2005). This condition affects a substantial population of 322 million people globally, with approximately 30 million individuals residing in Africa. Chronic usage of sildenafil has been associated with side effects, primarily due to its vasodilator properties. In this study, the influence of sildenafil citrate on the histological structure of the nasal conchae in adult male albino rats was investigated using light and electron microscopes (Gebreyohannes *et al.*, 2016). This research aims to provide insights into the potential impact of sildenafil citrate on the nasal tissue morphology and shed light on the histological changes associated with its use.

In the present study, different degrees of degeneration and submucosal edema were observed in olfactory mucosa using the routine H&E staining. This increased risk of nasal mucosa toxicity attributed to the repeated exposure to the high dose of sildenafil treatment (10 mg/ kgm) and could result from chronically high levels of cyclic guanosine monophosphate (cGMP), which prevents the nitric oxide's decomposition as recorded by (Behn and Potter, 2001). Similar to this, Eweka *et al.* (2010) observed that adult Wistar rats given sildenafil citrate over an extended period of time encountered varying degrees of intercellular vacuolations in the superior colliculus (intracranial visual relay center) and cellular degeneration. Chronic treatment with sildenafil citrate (100 mg/ kgm) for 4 weeks (Viagra) caused the optic nerve and retina's structure of the rat to be influenced by the toxic effect of nitric oxide.

The olfactory neuron is bipolar, whereas a single unbranched axon forms the synapse in the olfactory bulb, the second extends into the mucous and ends in an olfactory vesicle. Fine olfactory cilia protrude into the mucus from each knob. As a result, cilia detect odorants on the surface of the olfactory epithelium (Liu *et al.*, 2010) and consequently, the olfactory capabilities may be dependent also on the height of the olfactory cilia. Olfactory sensory neurons in vertebrates detect odorants using multiple cilia, which protrude from the end of the dendrite (Ching *et al.*, 2022).

In the present study morphometric analysis of the olfactory cilia height in the sildenafil citrate 100 mg treated group indicated degeneration, loss of cilia and decrease in its height compared to control group, whereas the 50 mg sildenafil citrate showed a pronounced preserved height of the olfactory cilia compared to control group and the 100-gm sildenafil. This result might explain the delay of rats in the group treated with higher sildenafil group in finding the buried chocolate cookies in the buried food test done in current study.

Results of the SEM in this study the sildenafil 50 mg treated group rats had numerous intact bipolar olfactory

cells arranged in normal intact pattern and had normal cilia and dendrites. Meanwhile, olfactory surface of the 100 mg sildenafil revealed numerous olfactory vesicles with rough corrugated surface along with loss of cilia and lack of mucous production. These results explain that the delay of rats in higher sildenafil group in finding the buried chocolate cookies in the buried food test done in our present study could be attributed to the loss ciliary surface and damage of some olfactory neuron cells as explained by Liu *et al.* (2010) who reported that olfactory receptor neurons and their cilia are the site of odorant detection. And also, the olfactory capabilities may be dependent also on the height of the olfactory cilia. And consequently, the olfactory capabilities may be dependent also on the height of the olfactory cilia (Challis *et al.*, 2015).

According to Gudziol *et al.* (2007), who stated that sildenafil (at a dose of 100 mg) had a significant effect on olfaction, the present results of the dose 100 mg were in line with their findings. This study aligns with reports of nonspecific side effects of sildenafil beginning at a dose of around 100 mg, with a higher frequency of dyspepsia or altered eyesight. This may be related to nonspecific effects of sildenafil on nasal swell bodies.

It has been proposed that sildenafil's angiogenic effect is mediated by an increase in NO and (cGMP) accumulation, which exhibits an endothelial relaxant activity, or by a protein kinase G-dependent pathway that is unrelated to the production of nitric oxide. Furthermore, data supporting the therapeutic effectiveness of sildenafil as an anti-angiogenic drug in human patients with neurological and vascular problems is rising (Farooq *et al.*, 2008).

Since iNOS-derived NO, the increased levels of NO obtained in the current study might promoted the adverse damage of nasal mucosa in rats receiving the high dose of sildenafil citrate, where the iNOS was significantly expressed in olfactory mucosa. The increased level of NO could be attribute to the inhibiting effect of sildenafil on the breakdown of cyclic guanosine monophosphate (cGMP), which regulates many of the biologic actions of NO (Shi and Nuttall, 2002). The loss of olfactory cilia obtained in our histological and scanning electron microscopy could be also attributed to the direct damage of NO which is confirmed the immunohistochemical expression off iNOS. Our results came parallel to the study of Shi and Nuttall (2002) that studied the effect of sildenafil on inner ear and assumed that an excessive stimulation of the NO/GMP pathway by NO free radicals can cause direct damage to hair cells, hair cell loss, and defective cochlear microcirculation.

Regarding the expression of caspase-3 as an apoptotic marker used in the present study, the immunoreactive cells observed significant increase in the 100 mg sildenafil group. Apoptosis could be the cause of sildenafil olfactory injury. Apoptosis is triggered by the activation of intracellular signals cascades, which in turn activate cysteine proteases (caspases) in a variety of cell types. Caspase 3

catalyzes the cleavage of terminal death substrates, causing cells to be destroyed in a systematic manner, resulting in DNA fragmentation and apoptotic cell death. As a result of uncontrolled synthesis, in a number of systems, NO's cytotoxic capacity can cause cell death via oxidative stress, disrupted energy metabolism, and DNA and mitochondrial damage (Kim *et al.*, 1999). This complex process may also be responsible for sildenafil-mediated olfactory epithelial cytotoxicity. Our findings aligned with those of Bakir *et al.* (2012), who studied the long-term effects of sildenafil administration on the rat inner ear using 50 mg Viagra tablets.

NO (nitric oxide) has been shown to play a dual role in apoptosis, acting as both a pro-apoptotic and anti-apoptotic factor depending on the cell type and context. According to Kim *et al.* (1999), the decision of a cell to undergo apoptosis is influenced by the interplay between apoptotic and anti-apoptotic factors. The data from the study suggest that NO contributes to maintaining this balance by inhibiting the apoptotic process through various mechanisms. One well established mechanism by which NO inhibits apoptosis is through the suppression of caspase activity, a key component of the apoptotic pathway.

According to a recent article, sildenafil, a medicine that modulates this system and regulates caspase activity, may aid in the treatment of several disorders. Sildenafil restricts necrosis and apoptosis via a NO-dependent pathway (Salloum *et al.*, 2008). As a result, several scientists proposed that continuous usage of modest doses of sildenafil has a protective effect against necrosis and apoptosis.

This research holds promise in enhancing our understanding of the pathogenesis of certain disorders and identifying effective treatment approaches. The vasodilatory effect of sildenafil has garnered significant interest due to its potential application in the management of vascular occlusive diseases, as noted by several researchers. The impact of sildenafil on retinal blood vessel diameter in healthy individuals has been investigated in prior studies (Grunwald *et al.*, 2002; Polak *et al.*, 2003).

## CONCLUSION

The present study provides evidence of the harmful impact of sildenafil citrate, the active ingredient in Viagra, on the nasal and olfactory systems, particularly through an increase in apoptosis. These findings align with previous research conducted in this area. It is important to note that the side effects on olfaction appear to be dose-related, with a significant increase observed with a 100 mg sildenafil dose, while the low dose did not show the same impact. Therefore, further studies are warranted to investigate the effects of sildenafil on olfactory function using both high and low doses, particularly in cases of induced olfactory impairment. In conclusion, the current study highlights the need for additional research to better understand the causes of olfactory impairment and to explore potential solutions for the treatment of this troublesome

condition. The findings emphasize the importance of considering the potential side effects of sildenafil citrate on olfaction and the necessity for further investigations in this area.

## REFERENCES

- BAKIR, S., FIRAT, U., GÜN, R., BOZKURT, Y., YORGANCILAR, E., KINIŞ, V., PENBEGÜL, N., GÖKALP, O. AND TOPÇU, İ. 2012. Histopathologic results of long-term sildenafil administration on rat inner ear. *American journal of otolaryngology*, 33, 667-672.
- BANCROFT, J. D. AND GAMBLE, M. 2008. *Theory and practice of histological techniques*, Elsevier health sciences.
- BEECHER, K., ST JOHN, J. A. AND CHEHREH-ASA, F. 2018. Factors that modulate olfactory dysfunction. *Neural Regeneration Research*, 13, 1151.
- BEHN, D. AND POTTER, M. J. 2001. Sildenafil-mediated reduction in retinal function in heterozygous mice lacking the  $\gamma$ -subunit of phosphodiesterase. *Investigative ophthalmology and visual science*, 42, 523-527.
- BOESVELDT, S. AND PARMA, V. 2021. The importance of the olfactory system in human well-being, through nutrition and social behavior. *Cell and tissue research*, 383, 559-567.
- CHALLIS, R. C., TIAN, H., WANG, J., HE, J., JIANG, J., CHEN, X., YIN, W., CONNELLY, T., MA, L. AND YU, C. R. 2015. An olfactory cilia pattern in the mammalian nose ensures high sensitivity to odors. *Current Biology*, 25, 2503-2512.
- CHING, K., WANG, J. T. AND STEARNS, T. 2022. Long-range migration of centrioles to the apical surface of the olfactory epithelium. *Elife*, 11, e74399.
- CROWE, A. R. AND YUE, W. 2019. Semi-quantitative determination of protein expression using immunohistochemistry staining and analysis: an integrated protocol. *Bio-protocol*, 9, e3465-e3465.
- ERSKINE, S. E. PHILPOTT, C. M. 2020. An unmet need: Patients with smell and taste disorders. *Clinical Otolaryngology*, 45, 197-203.
- EWEKA, A. O., EWEKA, A. AND OM'INIABOHS, F. A. 2010. Histological studies of the effects of monosodium glutamate of the fallopian tubes of adult female Wistar rats. *North American journal of medical sciences*, 2, 146.
- FAROOQ, M. U., NARAVETLA, B., MOORE, P. W., MAJID, A., GUPTA, R. AND KASSAB, M. Y. 2008. Role of sildenafil in neurological disorders. *Clinical neuropharmacology*, 31, 353-362.
- GEBREYOHANNES, E. A., BHAGAVATHULA, A. S., GEBRESILLASSIE, B. M., TEFERA, Y. G., BELACHEW, S. A. AND ERKU, D. A. 2016. Recreational use of phosphodiesterase 5 inhibitors and its associated factors among undergraduate male students in an Ethiopian University: a cross-sectional study. *The World Journal of Men's Health*, 34, 186-193.
- Gibson-Corley, K.N., Olivier, A.K., Meyerholz, D.K., 2013. Principles for valid histopathologic scoring in research. *Vet Pathol* 50, 1007-1015.
- GRUNWALD, J. E., METELITSINA, T. AND GRUNWALD, L. 2002. Effect of sildenafil citrate (Viagra) on retinal blood vessel diameter. *Am J Ophthalmol*, 133, 809-12.
- GUDZIOL, V., MÜCK-WEYMANN, M., SEIZINGER, O., RAUH, R., SIFFERT, W. AND HUMMEL, T. 2007. Sildenafil affects olfactory function. *The Journal of urology*, 177, 258-261.
- HURA, N., XIE, D. X., CHOBY, G. W., SCHLOSSER, R. J., ORLOV, C. P., SEAL, S. M. AND ROWAN, N. R. Treatment of post-viral olfactory dysfunction: an evidence-based review with recommendations. *International forum of allergy AND rhinology*, 2020. Wiley Online Library, 1065-1086.
- JAFAR, A., LASSO, A., SHORR, R., HUTTON, B. AND KILTY, S. 2021. Olfactory recovery following infection with COVID-19: A systematic review. *PLoS One*, 16, e0259321.
- KIM, Y.-M., BOMBECK, C. A. AND BILLIAR, T. R. 1999. Nitric oxide as a bifunctional regulator of apoptosis. *Circulation research*, 84, 253-256.
- LIU, Q., YE, W., YU, H., HU, N., DU, L., WANG, P. AND YANG, M. 2010. Olfactory mucosa tissue-based biosensor: A bioelectronic nose with receptor cells in intact olfactory epithelium. *Sensors and Actuators B: Chemical*, 146, 527-533.
- LORAN, O. B., STRÖBERG, P., LEE, S. W., PARK, N. C., KIM, S.-W., TSENG, L.-J., COLLINS, S. AND STECHER, V. J. 2009. Sildenafil citrate 100 mg starting dose in men with erectile dysfunction in an international, double-blind, placebo-controlled study: effect on the sexual experience and reducing feelings of anxiety about the next intercourse attempt. *The journal of sexual medicine*, 6, 2826-2835.
- NORDIN, S. AND BRÄMERSON, A. 2008. Complaints of olfactory disorders: epidemiology, assessment and clinical implications. *Current opinion in allergy and clinical immunology*, 8, 10-15.
- POLAK, K., WIMPISSINGER, B., BERISHA, F., GEORGOPOULOS, M. AND SCHMETTERER, L. 2003. Effects of Sildenafil on Retinal Blood Flow and Flicker-Induced Retinal Vasodilatation in Healthy Subjects. *Investigative Ophthalmology AND Visual Science*, 44, 4872-4876.
- PURVES, D., AUGUSTINE, G., FITZPATRICK, D., KATZ, L., LAMANTIA, A., MCNAMARA, J. AND WILLIAMS, S. 2001. The olfactory epithelium and olfactory receptor neurons. *Neuroscience*.
- REAGAN-SHAW, S., NIHAL, M. AND AHMAD, N. 2008. Dose translation from animal to human studies revisited. *The FASEB journal*, 22, 659-661.
- ROSS, M. AND PAWLINA, W. 2006. *Histology: A text and atlas*. Baltimore, Philadelphia. Lipincott Williams and Wilkins.
- SALLOUM, F. N., ABBATE, A., DAS, A., HOUSER, J.-E., MUDRICK, C. A., QURESHI, I. Z., HOKE, N. N., ROY, S. K., BROWN, W. R. AND PRAB-

- HAKAR, S. 2008. Sildenafil (Viagra) attenuates ischemic cardiomyopathy and improves left ventricular function in mice. *American Journal of Physiology-Heart and Circulatory Physiology*, 294, H1398-H1406.
- SCHUBERT, C. R., FISCHER, M. E., PINTO, A. A., KLEIN, B. E., KLEIN, R., TWEED, T. S. AND CRUICKSHANKS, K. J. 2017. Sensory impairments and risk of mortality in older adults. *Journals of Gerontology Series A: Biomedical Sciences and Medical Sciences*, 72, 710-715.
- SENTHILKUMAR, A., SMITH, R. D., KHITHA, J., ARORA, N., VEERAREDDY, S., LANGSTON, W., CHIDLOW JR, J. H., BARLOW, S. C., TENG, X. AND PATEL, R. P. 2007. Sildenafil promotes ischemia-induced angiogenesis through a PKG-dependent pathway. *Arteriosclerosis, thrombosis, and vascular biology*, 27, 1947-1954.
- SHI, X. AND NUTTALL, A. L. 2002. The demonstration of nitric oxide in cochlear blood vessels in vivo and in vitro: the role of endothelial nitric oxide in venular permeability. *Hearing research*, 172, 73-80.
- STAMEGNA, J.-C., GIRARD, S. D., VERON, A., SICARD, G., KHRESTCHATISKY, M., FERON, F. & ROMAN, F. S. 2014. A unique method for the isolation of nasal olfactory stem cells in living rats. *Stem cell research*, 12, 673-679.
- SÜLZ, L., ASTORGA, G., BELLETTE, B., ITURRIAGA, R., MACKAY-SIM, A. AND BACIGALUPO, J. 2009. Nitric oxide regulates neurogenesis in adult olfactory epithelium in vitro. *Nitric Oxide*, 20, 238-252.
- SUN, Y., JIN, K., CHILDS, J. T., XIE, L., MAO, X. O. AND GREENBERG, D. A. 2005. Neuronal nitric oxide synthase and ischemia-induced neurogenesis. *Journal of Cerebral Blood Flow & Metabolism*, 25, 485-492.
- THARAKAN, B. AND MANYAM, B. V. 2005. Botanical therapies in sexual dysfunction. *Phytotherapy research*, 19, 457-463.
- YANG, M. AND CRAWLEY, J. N. 2009. Simple behavioral assessment of mouse olfaction. *Curr Protoc Neurosci*, Chapter 8, Unit 8.24.

## تأثير سيترات السيلدينافيل (الفياجرا®) على الغشاء المخاطي الشمي للأنف لدى ذكور الفئران البيضاء البالغة: تعبيرات Caspase 3 وبروتين سينسيز أكسيد النيتريك المحفز.

ضياء الدين محمد الحناوي<sup>1</sup>، محمد رفعت أحمد<sup>1</sup>، محمد طباطبا<sup>1</sup>، أحمد سلامة عبد الرحيم<sup>1</sup>، أمينة علي دسوقي<sup>2</sup>  
<sup>1</sup>قسم الأنف والأذن والحنجرة، كلية الطب جامعة قناة السويس، الإسماعيلية، مصر  
<sup>2</sup>قسم علم الأمراض، كلية الطب البيطري، جامعة قناة السويس، الإسماعيلية، مصر

### الملخص العربي

تلعب حاسة الشم دورًا مهمًا في حياة الإنسان مثل جميع الحواس البشرية. و لذلك تعتبر حاسة الشم بمثابة إشارة إنذار أولى، إنذار لدخان حريق، أو طعام فاسد، أو رائحة تسرب غاز طبيعي أو أبخرة خطيرة. الغشاء المخاطي الشمي هو أحد مكونات الجهاز العصبي الذي يتجدد طوال حياة الشخص. قد يكون الخلل في حساسية الشم أحد الآثار الجانبية للاستخدام المزمن لجرعات عالية من السيلدينافيل. السيلدينافيل هو دواء يؤخذ عن طريق الفم وهو فعال لعلاج ضعف الانتصاب لدى الرجال، ويشكو حوالي 20% من المرضى من احتقان الأنف بعد تناول السيلدينافيل. كان الهدف من هذه الدراسة هو تقييم تأثير إعطاء السيلدينافيل على المدى الطويل على الغشاء المخاطي الشمي لدى الفئران. تم تقسيم خمسة وأربعين ذكرًا من الفئران البيضاء إلى ثلاث مجموعات متساوية، احتفظت بالمجموعة الضابطة. تلقت الفئران في المجموعتين الثانية والثالثة سترات السيلدينافيل عن طريق الفم بجرعات 50 ملجم / كجم و 100 ملجم / كجم على التوالي لمدة ثلاثة أشهر. بعدها تمت إزالة الغشاء المخاطي الشمي، وتثبيتته في التثبيتات المناسبة لعمل التشريح المرضي، والكيمياء المناعية، وSEM. أوضحت النتائج أن الفئران التي عولجت بجرعة عالية من السيلدينافيل كشفت عن فقدان حاسة الشم بالإضافة إلى تغير في الصور النسيجية وتلطخ كيميائي مناعي لعلامات موت الخلايا المبرمج وSEM للغشاء المخاطي الشمي بينما كشفت الفئران في المجموعة الثانية عن حاسة شم طبيعية وأنسجة طبيعية للغشاء المخاطي الشمي. ومن هذه الدراسة يمكن استخلاص أن: الاستخدام المزمن لـ 100 ملجم من سترات السيلدينافيل تؤدي إلى خلل وظيفي في حاسة الشم من خلال تحفيز علامات موت الخلايا المبرمج لـ iNOS و Caspase 3، بينما تحتاج الجرعة المنخفضة إلى مزيد من البحث وقد تقدم علاجًا محتملاً لخلل وظيفي بعد كوفيد 19.



