











# INTERNATIONAL JOURNAL OF MEDICAL ARTS



Volume 5, Issue 10, October 2023

<https://ijma.journals.ekb.eg/>



Print ISSN: 2636-4174

Online ISSN: 2682-3780





Available online at Journal Website  
<https://ijma.journals.ekb.eg/>  
 Main Subject [Ophthalmology]



## Original Article

# Assessment of Macular Microvascular Changes after Intravitreal Ranibizumab Injection in Diabetic Macular Edema

Asmaa Abdallah Abd-Elnaby \*, Jihan Abdallah Mohamed, Mona Mohamad Aly

Department of Ophthalmology, Faculty of Medicine [for girls], Al-Azhar University, Cairo, Egypt

## ABSTRACT

### Article information

**Received:** 16-10-2023

**Accepted:** 14-11-2023

DOI: 10.21608/IJMA.2023.242815.1840.

\*Corresponding author

**Email:** [a7medmusba7@gmail.com](mailto:a7medmusba7@gmail.com)

**Citation:** Abd-Elnaby AA, Mohamed JA, Aly MM. Assessment of Macular Microvascular Changes after Intravitreal Ranibizumab Injection in Diabetic Macular Edema. IJMA 2023 October; 5 [10]: 3693-3700. doi: 10.21608/IJMA.2023.242815.1840.

**Objective:** With the help of optical coherence tomography angiography, this study sought to determine if the retinal capillary plexus and choriocapillaris in diabetic macular edema patients' eyes had changed after Ranibizumab is administered intravitreally once.

**Patients and Methods:** A prospective, interventional, randomized clinical trial with 20 diabetic macular edema patients' eyes were chosen from outpatient clinic Ophthalmology department of Al-Azhar university hospital, Cairo, Egypt during period from 2022 to 2023. Prior to intravitreal ranibizumab treatment and one month after, the visual acuity of each patient was assessed. Optical Coherence Tomography Angiography was performed at baseline preoperatively and 1 month postoperatively for assessing superficial capillary plexus, deep capillary plexus, vascular density, Foveal avascular zone, and choriocapillaris vessels density.

**Results:** The BCVA showed a considerable improvement [p < 0.001] and significant reduction in the CFT [p value < 0.001]. Also, choriocapillaris showed a significant improvement [p value < 0.001]. On the other hand, there were in significant changes in the superficial capillary plexus, deep capillary plexus, vascular density, and Foveal avascular zone before and after treatment.

**Conclusion:** Intravitreal ranibizumab effectively decreased macular thickness and improved visual acuity and choriocapillaris.

**Keywords:** Retinal capillary plexus; Choriocapillaris; Optical coherence tomography angiography; Intravitreal; Ranibizumab.



This is an open-access article registered under the Creative Commons, ShareAlike 4.0 International license [CC BY-SA 4.0] [<https://creativecommons.org/licenses/by-sa/4.0/legalcode>].

## INTRODUCTION

Diabetes is a chronic condition that has the fastest rate of spreading in the globe. A common and distinct microvascular consequence of diabetes called diabetic retinopathy [DR] results in gradual vision loss and, in severe circumstances, blindness. The two main kinds are proliferative diabetic retinopathy [PDR] and non-proliferative diabetic retinopathy [NPDR]. The most typical sight-threatening consequences of diabetes are diabetic macular edema [DME], diabetic macular ischemia [DMI] and PDR [1].

An innovative and fascinating approach for learning more about the retinochoroidal microvasculature is optical coherence tomography angiography [OCTA] [2]. Vascular indicators such vessel density, total vessel length, and vascular architecture have been used in recent investigations on the role of OCTA in DR. These measurements could be able to identify alterations in the severity and development of DR. Additionally, diabetic macular ischemia may be identified with OCTA as a non-invasive imaging technique, which could improve visual prognosis [3].

Ranibizumab is an intraocular anti-VEGF antibody fragment that blocks the biologic action of all known active VEGF isoforms. For the purpose of treatment of diabetic macular edema and macular edema brought on by retinal vein blockage, intravitreal ranibizumab injection has been authorized [4].

## PATIENTS AND METHODS

Type of the study: 20 eyes from 20 individuals with diabetic macular edema were chosen from outpatient clinic Ophthalmology department of Al-Azhar university hospital, Cairo, Egypt during period from 2022 to 2023. The Al-Azhar University medical ethics committee's guidelines for all study procedures were followed. Following thorough explanation, everyone involved signed a written informed permission.

**Inclusion criteria:** Diabetic individuals having diabetic macular edema.

**Exclusion criteria:** Patient with tractional retinal detachment, vitreous hemorrhage, having dense cataract and chronic or recurrent inflammation of eye.

**Methods:** Patients who fulfilled all inclusion requirements were assessed by complete history taking, comprehensive clinical assessment.

## Ophthalmic evaluation included

Best corrected visual acuity [BCVA] by usage of Snellen's chart and converted into logMAR.

Visual acuity chart preoperatively and one month postoperatively.

The cornea, sclera, iris, anterior chamber, lens, and pupil are examined during an examination of the anterior segment using slit lamp.

Using indirect ophthalmoscopy and slit lamp biomicroscopy with a + 90 Diopter lens, examine the fundus to evaluate the condition of the macular and peripheral retina.

Intraocular pressure evaluation utilizing Goldmann applanation tonometer.

Optical Coherence Tomography Angiography: all individuals underwent it at baseline prior to surgery and one month thereafter.

## Optical coherence tomography Angiography

En face 3 mm x 3 mm OCTA pictures have been taken at baseline and one month following intravitreal ranibizumab treatment using an Optovue Avanti XR4 instrument [Version 2018.1.1.63, Optovue, Inc, Fremont, CA]. It took several scans with noticeable motion or blinking artefacts to get an acceptable-quality image. Internal limiting membrane and 9  $\mu$ m higher than the inner plexiform layer was used as inner and outer boundaries to automatically segment the superficial capillary plexus en face picture. With an inner boundary 9  $\mu$ m above the IPL and an outside boundary 9  $\mu$ m below the outer plexiform layer, deep capillary plexus [DCP] en face picture was taken. The apparatus automatically created vascular density [VD] of SCP and Q3 DCP in fovea, parafovea, and the entire picture, which was then recorded. The proportion of the imaged region that is made up of blood vessels was utilized to define VD.

Foveal avascular zone [FAZ] was automatically determined. A ring that was constrained by FAZ shape and a parallel outside border 300  $\mu$ m from FAZ area foveal density-300 [FD-300] had its foveal density automatically measured as well. VD and FAZ measures were conducted using the same methodology both before and after intravitreal ranibizumab injections.

Central foveal thickness [CFT] was calculated automatically by optical coherence tomography angiography. The built-in programme also performed a custom slab evaluation of the choriocapillaris VD. The choriocapillaris slab was segmented automatically from 9 µm above Bruch's membrane [BRM] to 31 µm below BRM.

**Data collection and analysis:** The collected data were processed, summarized, and statistically assessed via IBM SPSS statistics software, version 28.0, IBM Corp., Chicago, USA, 2021. Using the Shapiro-Wilk test, quantitative data were checked for normality before being summarized as mean and standard deviation then compared with paired t-tests. numbers and percentages used to represent qualitative data. If the p value was < 0.050, significance was proved; otherwise, it was not.

## RESULTS

**Demographic data of studied cases [age, sex, and IOP]:** Mean ± SD of Age [years] and IOP [mmHg] was 61.7 ± 5.9 and 52.0–71.0 respectively. Males and females were 30.0% and 70.0% respectively as illustrated in table [1].

**BCVA [LogMAR]:** Mean ± SD of BCVA before, and after treatment was 1.0 ± 0.2, and 0.8 ± 0.2 respectively and this was significant improvement [p < 0.001] [table 2].

**Central foveal thickness:** Mean ± SD of central foveal thickness [CFT-µm] before, and after treatment was 345.2 ± 98.0, and 291.1± 68.4. Significant reduction was seen. [p < 0.001] [table 3].

**Foveal vessel density [%] in SCP:** Mean ± SD of Foveal vessel density in SCP before, and

after treatment was 14.24 ± 5.25, and 13.55 ± 4.93 respectively. The reduction was statistically non-significant [p=0.070] [figure 1].

**Foveal vessel density [%] in DCP:** Mean ± SD of Foveal vessel density [%] in DCP before, and after treatment was 25.51 ± 3.47, and 24.04 ± 4.87. The reduction was statistically non-significant [p=0.153] [figure 1].

**Parafoveal vessel density [%] in SCP:** Mean ± SD before, and after treatment was 42.16 ± 3.21, and 42.65 ± 4.14 respectively. The elevation was statistically non-significant [p=0.450] [figure 1].

**Parafoveal vessel density [%] in DCP:** Mean ± SD pre, and post injection was 44.23 ± 3.19, and 43.10 ± 3.56. The reduction was statistically non-significant [p=0.078] [figure 1].

**Whole image vessel density in SCP:** Mean ± SD before, and after injection was 40.12 ± 3.21, and 40.89 ± 3.53 respectively. The elevation was statistically non-significant [p=0.089] [figure 2].

**Whole image vessel density in DCP:** Mean ± SD before, and after treatment was 41.61 ± 2.81, and 40.68 ± 3.04 respectively. The reduction was statistically non-significant [p=0.076] [figure 2].

**Foveal avascular zone area [mm<sup>2</sup>]:** Mean ± SD before, and after treatment was 0.35 ± 0.11, and 0.38 ± 0.10 respectively. The elevation was non-significant [p=0.057] [figure 3].

**Choriocapillaris vessel density in subfoveal area [%]:** The change before and after treatment was 64.73 ± 5.00, and 66.97 ± 4.99 respectively. The elevation has been significant [p < 0.001] [table 4].

**Table [1]:** Demographic data of cases

Variables	Mean ± SD	Range
Age [years]	61.7 ± 5.9	52.0 –71.0
IOP [mmHg]	15.9 ± 2.1	12.0 – 19.0
Sex [No., %]	Male	6
	Female	14

**Table [2]:** BCVA [LogMAR] of cases

Time	Mean ± SD	Range	^ p-value
Before	1.0 ± 0.2	0.7–1.3	<0.001*
After	0.8 ± 0.2	0.5–1.3	

^Paired t-test. \*Significant

**Table [3]:** Central foveal thickness in our study

Time	Mean ± SD	Range	^p-value
Before	345.2±98.0	217.0–530.0	<0.001*
After	291.1±68.4	205.0–470.0	

^Paired t-test. \*Significant

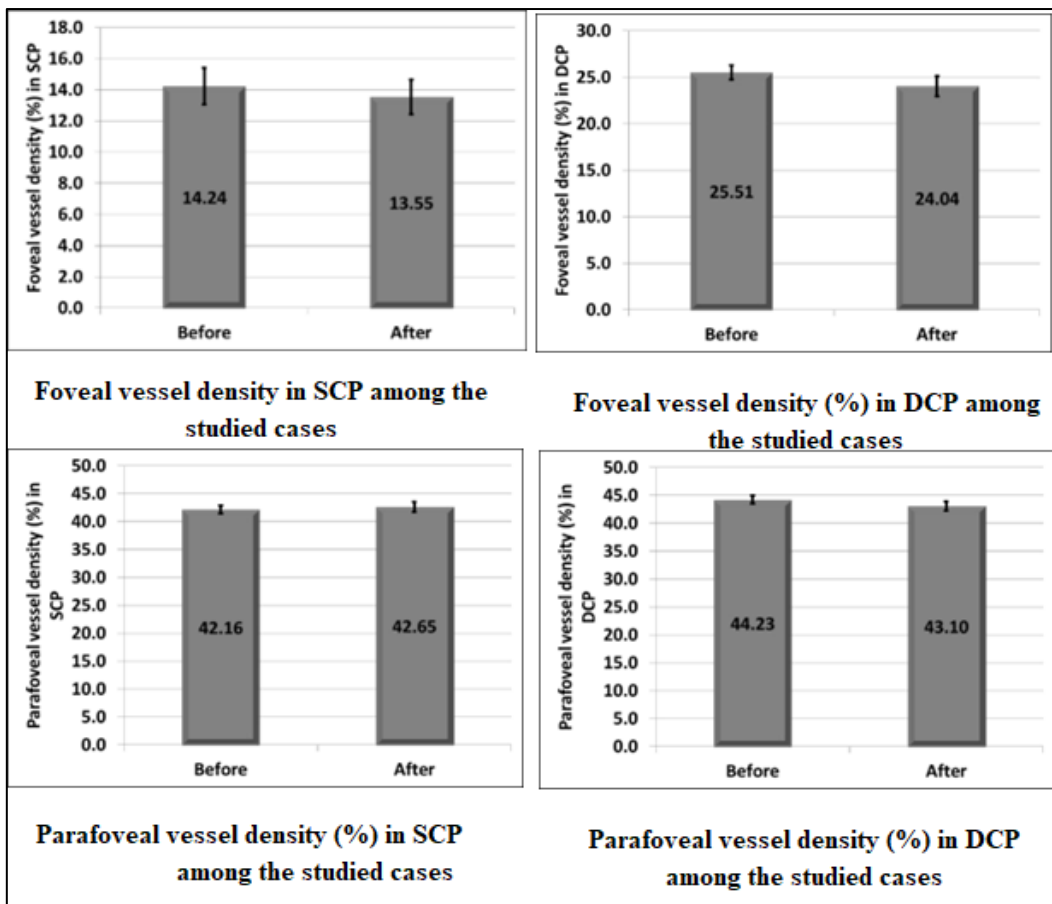


Figure [1]: Changes in SCP and DCP before and after Intravitreal ranibizumab

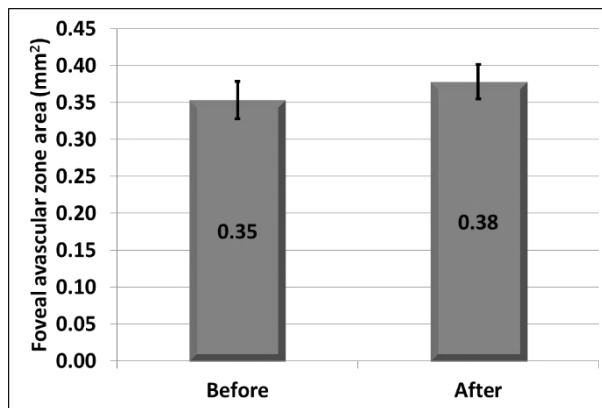


Figure 2: Foveal avascular zone area among the studied cases

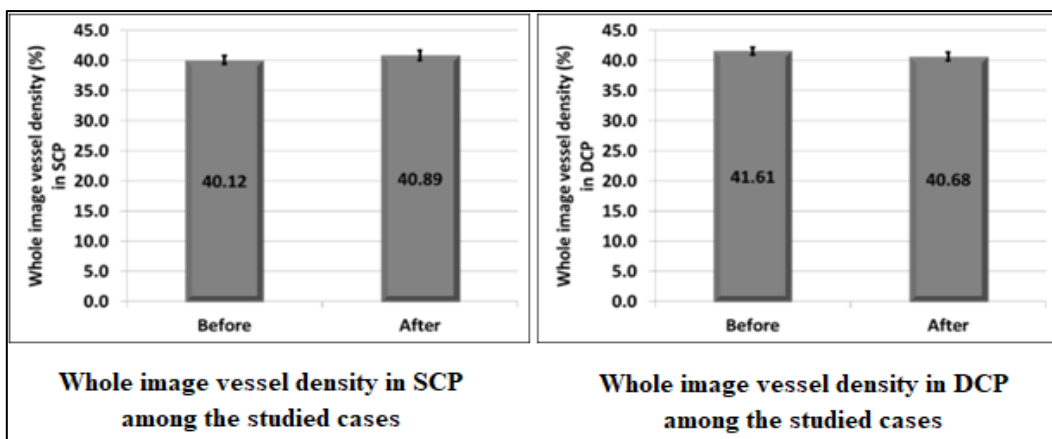
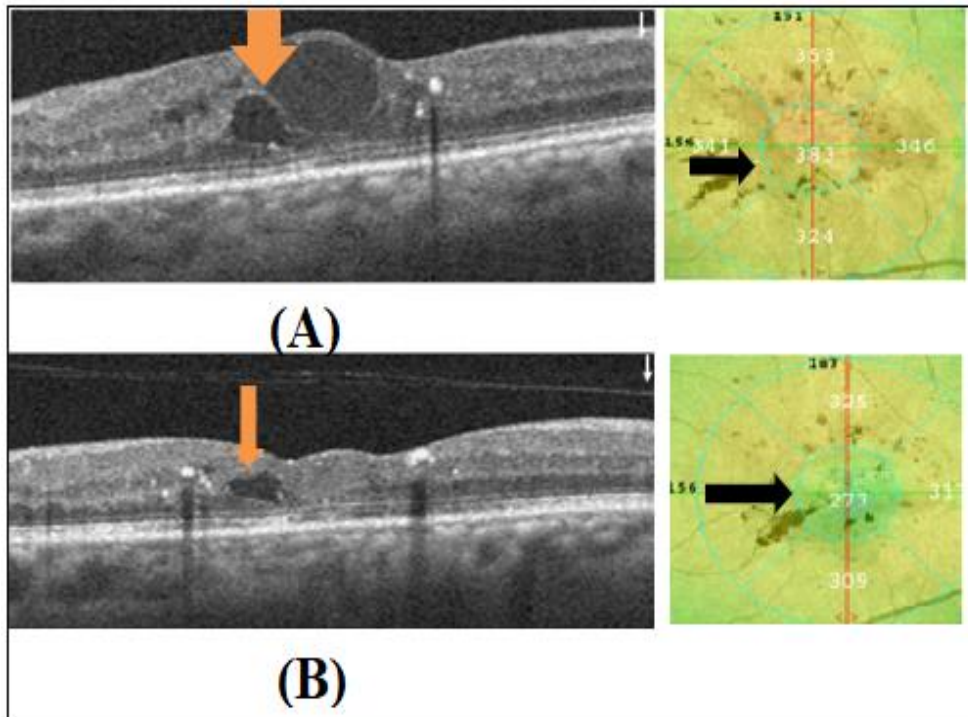


Figure [3]: Changes in whole image vessel density in SCP and DCP before and after Intravitreal ranibizumab

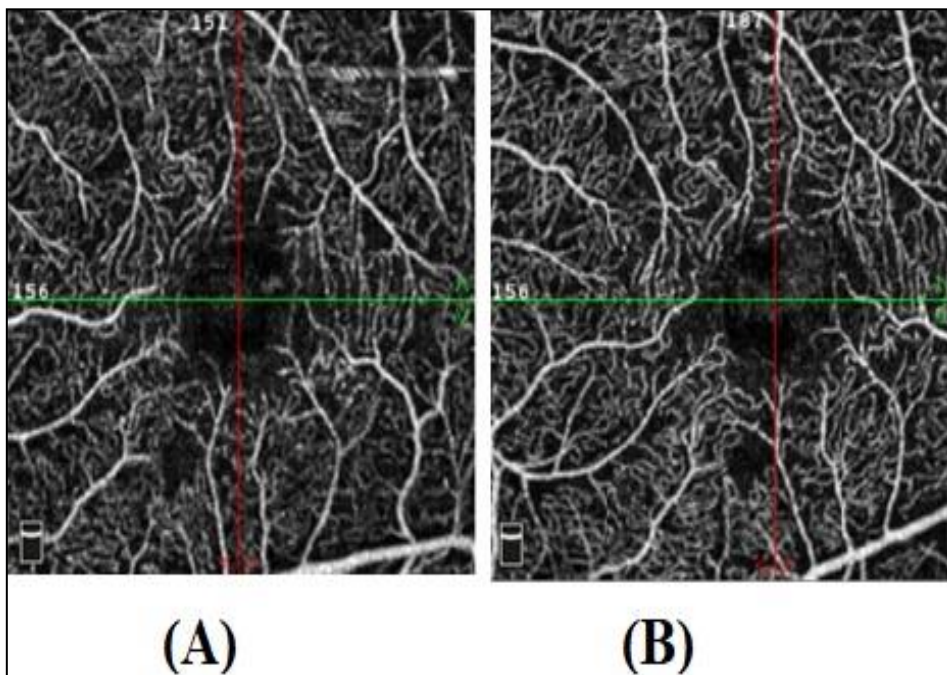
**Table [4]:** Choriocapillaris vessel density in subfoveal area [%]

Time	Mean ± SD	Range	^p-value
<b>Before</b>	64.73±5.00	56.73–71.78	<b>&lt;0.001*</b>
<b>After</b>	66.97±4.99	60.06–75.13	


^Paired t-test. \*Significant



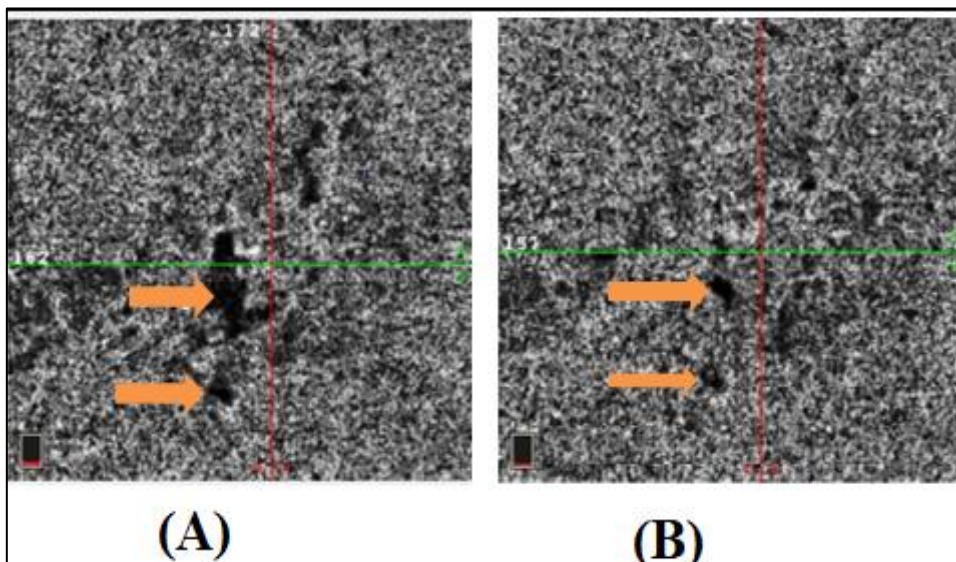
**Figure [4]: Case No [1]:** Optical coherence tomography image of macula before [A] and after [B] intravitreal ranibizumab injection. The preinjection central foveal thickness was 383 μm, which decreased to 273 μm after injection



**Figure 5: Case No [2]:** Enface image of the superficial capillary plexus taken with optical coherence tomography angiography before [A] and after [B] an intravitreal ranibizumab injection. The preinjection superficial capillary plexus was 42.2 %, which improved to 43.9 % after injection.



**Figure 6: Case No [3]:** Before [A] and after [B] an intravitreal ranibizumab injection, an enface image of the deep capillary plexus taken using optical coherence tomography angiography is shown. The preinjection deep capillary plexus was 45.8 %, which decreased to 43 % after injection.



**Figure 7: Case No [4]:** Enface images of the choriocapillaris obtained using Enface optical coherence tomography before [A] and after [B] intravitreal ranibizumab injection. The preinjection foveal choriocapillaris vessel density was 61.06%, which improved to 67.14% after injection

## DISCUSSION

There are numerous data demonstrating ranibizumab's effectiveness in treating patients with DME [5].

This study used optical coherence tomography angiography to examine retinal capillary plexus and choriocapillaris in diabetic macular edema patients' eyes after receiving intravitreal injection of Ranibizumab once.

After receiving a single intravitreal injection of ranibizumab, 20 individuals with diabetic macular edema had their eyes scanned using optical coherence tomography angiography for this study.

The study's findings revealed that age [years] and IOP [mmHg] had mean and SD values of  $61.7 \pm 5.9$  and  $52.0-71.0$ , respectively. There were 30.0% men and 70.0% females, respectively. This was in line with **Tawfek et al.** [4] who reported that 71.4% [43] of the participants were female and 28.3% [17] were male. The group's average age was  $46.95 \pm 7.82$  years [32–63].

According to our findings, the mean and standard deviation of BCVA before and after treatment  $1.0 \pm 0.2$ , and  $0.8 \pm 0.2$ . Statistics showed that the improvement was significant [ $p < 0.001$ ]. **Elbeheiri et al.** [5], were in accordance to our results and showed that the mean VA prior to therapy was  $1.22 \pm 0.36$  and was  $1.03 \pm 0.31$  at one month. The VA in the included



cases showed a very statistically significant improvement after one month compared to the pre-treatment value [ $p < 0.001$ ]. Also, **Lai et al.** [6] have shown that IVR was connected to a significant improvement in BCVA [BCVA increased from 0.64 at baseline to 0.56 at time-point of months 1] [ $P < 0.05$ ]. The study concluded that, in instances with DME, assessing efficiency as soon as one month after an IVR may be able to anticipate the functional and structural effects of ranibizumab in addition to prediction made using the basal value of BCVA.

According to our findings, the mean and standard deviation of Central Foveal Thickness [CFT- $\mu\text{m}$ ] before and after therapy were  $345.2 \pm 98.0$  and  $291.1 \pm 68.4$ , respectively. Statistics showed that the reduction was significant [ $p < 0.001$ ]. This was in line with **Yasuda et al.** [7]'s study who reported one month after treatment, CMT showed significant improvement  $P < 0.001$ . Also, **Elbeheiri et al.** [5] reported that the mean Macular thickness before treatment was  $467.39 \pm 120.04$ , and at 1 month was  $362.89 \pm 130.33$ . There was a statistically significant decrease in the macular thickness in the included cases after one month as compared with before treatment value [ $p < 0.001$ ].

As a result of treatment, the mean  $\pm$  SD of foveal vascular density in SCP was  $14.24 \pm 5.25$ , as opposed to  $13.55 \pm 4.93$  previously. As of statistical significance [ $p=0.070$ ], the decline was not significant. Furthermore, the mean SD of the foveal vascular density [%] in DCP before and after treatment was  $25.51 \pm 3.47$  and  $24.04 \pm 4.87$ , respectively. It was statistically insignificant that the reduction occurred [ $p=0.153$ ]. Similar findings were made by **Li et al.** [8] who discovered that the deep vascular complex's [DVC] VD had not undergone any noticeable modifications. Whether it was 30 minutes or a month after the injection, there were no changes in the VD of the DVC in the macula and fovea region [ $p > 0.05$ ]. However, they discovered that the VD of the superficial vascular complex [SVC] had decreased statistically significantly, as they could observe decreases in the VD of the SVC in the macula [mean difference 3.10,  $p < 0.001$ ] and in the fovea [mean difference 2.74,  $p = 0.006$ ]. The outcome was in agreement to **Takusagawa et al.** [9]'s finding that SVC was significantly more affected than DVC.

The mean  $\pm$  SD of Whole image vessel density in SCP before, and after injection was  $40.12 \pm 3.21$ , and  $40.89 \pm 3.53$  respectively. The elevation was statistically non-significant [ $p=0.089$ ]. Mean

$\pm$  SD of Whole image vessel density in DCP before, and after treatment was  $41.61 \pm 2.81$ , and  $40.68 \pm 3.04$  respectively. The reduction was statistically non-significant [ $p=0.076$ ]. This was in contrary to **Elnahry et al.** [10] who documented that the full retinal thickness [Full] and the VD of Full was reduced by 8%, and the skeleton VD of Full was reduced by 13.3%, which were all statistically significant [ $p < 0.05$ ].

According to our findings, the mean and standard deviation of the Foveal Avascular Zone area before and after therapy were  $0.35 \pm 0.11$  and  $0.38 \pm 0.10$ , respectively. [ $p=0.057$ ]. The elevation was not statistically significant. This was comparable to the findings of **Li et al.** [8] who discovered that no significant changes were observed in any of the FAZ parameters, including FAZ area, FAZ perimeter, and FAZ AI, whether it was 30 minutes or a month after the injection [ $p > 0.05$ ].

Our results showed that the change in the Choriocapillaris vessel density in subfoveal area before and after treatment was  $64.73 \pm 5.00$ , and  $66.97 \pm 4.99$  respectively. The elevation was statistically significant [ $p < 0.001$ ]. This was consistent with **Pessoa et al.** [11]'s findings that the choriocapillaris flow density [CCD] was collected from OCT angiography and assessed both before and after treatment in their research of DME eyes divided into vitrectomized [group 1] and non-vitrectomized [group 2] eyes. A substantial rise in CCD was observed [ $p=0.010$ ]. This finding was explained by the fact that anti-VEGF therapy reduces choroidal thickness, most likely as a result of decreased choroidal vascular permeability. On the other hand, as indicated by the rise in CCD, interstitial fluid pressure is lowered due to the major choroidal arteries' reduced permeability, which may also encourage blood flow in the choriocapillaris. In contrast to our results, **Cennamo et al.** [12] found no significant variation [ $p > 0.05$ ] between baseline and after loading phase in vessel density in any of the CC's sectors was recorded. These findings could possibly be explained by the macular and choroidal thickness may be affected by intravitreal anti-VEGF injections, but not blood flow to the retina and choriocapillaris. Also, this study had a limitation which was a relatively small sample size of the groups of subjects.

**Conclusion:** According to the results of the current trial, intravitreal ranibizumab efficiently reduced macular thickness and enhanced visual acuity and vessels density of choriocapillaris.

**Financial and non-financial relations and activities of interest:** None

## REFERENCES

1. Sun Z, Yang D, Tang Z, Ng DS, Cheung CY. Optical coherence tomography angiography in diabetic retinopathy: an updated review. *Eye [Lond]*. 2021 Jan;35[1]:149-161. doi: 10.1038/s41433-020-01233-y.
2. Markan A, Agarwal A, Arora A, Bazgain K, Rana V, Gupta V. Novel imaging biomarkers in diabetic retinopathy and diabetic macular edema. *Ther Adv Ophthalmol*. 2020 Sep 4;12:2515841420950513. doi: 10.1177/25158414-20950513.
3. Sun Z, Tang F, Wong R, Lok J, Szeto SKH, Chan JCK, *et al*. OCT Angiography Metrics Predict Progression of Diabetic Retinopathy and Development of Diabetic Macular Edema: A Prospective Study. *Ophthalmology*. 2019 Dec;126[12]:1675-1684. doi: 10.1016/j.ophtha.2019.06.016.
4. Tawfek AZ, Elgharieb ME, Alnahass HS, Alnahrawy OM, Gab-Alla AA. Effect of Intravitreal Injection of Ranibizumab on Macular Perfusion by Optical Coherence Tomography Angiography. *Suez Canal Univ Med J*. 2022 Jul 1;25[2]:1-6. doi: 10.21608/SCUMJ.2022.223250.
5. Elbeheiri R, El-Tarshouby SM, Abouelkheir HE, Abdelkader AM. Ranibizumab Response in Diabetic Macular Edema at Mansoura Ophthalmology Center. *Egypt J Ophthalmol*. 2022 Mar 1;2[1]:19-28. doi: 10.21608/EJOMOS.2022.104823.1040.
6. Lai K, Huang C, Li L, Gong Y, Xu F, Zhong X, Lu L, Jin C. Anatomical and functional responses in eyes with diabetic macular edema treated with "1 + PRN" ranibizumab: one-year outcomes in population of mainland China. *BMC Ophthalmol*. 2020;20[1]:229. doi: 10.1186/s12886-020-01510-0.
7. Yasuda K, Noma H, Oyama E, Yanagida K, Asakage M, Shimura M. Effects of Intravitreal Ranibizumab Injection to Treat Macular Edema due to Central Retinal Vein Occlusion on Choroidal Findings and Functional-Morphological Parameters. *Ophthalmic Res*. 2023 Jun 16;66[1]:1063-1070. doi: 10.1159/000531498.
8. Li X, Chen Q, Yu X. Acute and subacute intraocular pressure and macular microvascular structure changes after intravitreal ranibizumab injection in eyes with branch retinal vein occlusion. *BMC Ophthalmol*. 2023 Apr 18;23[1]:160. doi: 10.1186/s12886-023-02889-2.
9. Takusagawa HL, Liu L, Ma KN, Jia Y, Gao SS, Zhang M, *et al*. Projection-Resolved Optical Coherence Tomography Angiography of Macular Retinal Circulation in Glaucoma. *Ophthalmology*. 2017 Nov;124[11]:1589-1599. doi: 10.1016/j.ophtha.2017.06.002.
10. Elnahry AG, Abdel-Kader AA, Raafat KA, Elrakhawy K. Evaluation of Changes in Macular Perfusion Detected by Optical Coherence Tomography Angiography following 3 Intravitreal Monthly Bevacizumab Injections for Diabetic Macular Edema in the IMPACT Study. *J Ophthalmol*. 2020;2020:5814165. doi: 10.1155/2020/5814165.
11. Pessoa B, Marques JH, Leite J, Silva N, José D, Coelho C, Figueira J, Meireles A, Melo-Beirão JN. Choroidal Blood Flow After Intravitreal Ranibizumab in Vitrectomized and Non-Vitrectomized Eyes with Diabetic Macular Edema. *Clin Ophthalmol*. 2021;15:4081-4090. doi: 10.2147/OPHTH.S325037.
12. Cennamo G, Montorio D, D'Alessandro A, Napolitano P, D'Andrea L, Tranfa F. Prospective Study of Vessel Density by Optical Coherence Tomography Angiography After Intravitreal Bevacizumab in Exudative Age-Related Macular Degeneration. *Ophthalmol Ther*. 2020;9[1]:77-85. doi: 10.1007/s40123-019-00221-0.



# International Journal

<https://ijma.journals.ekb.eg/>

Print ISSN: 2636-4174

Online ISSN: 2682-3780

# of Medical Arts