



## Hepato-renal and splenic cytotoxic effects of American cockroach *Periplaneta americana* hemolymph in Solid Ehrlich carcinoma cells-bearing mice

Esraa Gamal<sup>1,\*</sup>, Mohamed M. Tawfik<sup>1</sup>, Mohamed A. Abdel-Rahman<sup>2</sup>, Mohamed K. Hassan<sup>1</sup> and Ahmed K. Hassan<sup>1</sup>

<sup>1</sup> Zoology Department, Faculty of Science, Port Said University, Port Said, Egypt.

<sup>2</sup> Zoology Department, Faculty of Science, Suez Canal University, Ismailia, Egypt.

\*Corresponding author: [esoogamal2008@gmail.com](mailto:esoogamal2008@gmail.com)

### ABSTRACT

Cancer is one of the communal reasons -for death worldwide. *Periplaneta americana* (*P. americana*) hemolymph revealed a wide range of biological activities, including antibacterial, anticancer, antiviral, and antiinflammation. Using histopathological approaches, this study was conducted to evaluate the safety of *P. americana* hemolymph by investigating its toxicological effects on liver, kidney, and spleen tissues of Solid Ehrlich carcinoma cells bearing mice. The results showed remarkable inflammatory and necrotizing toxic effects of *P. americana* hemolymph on mice's liver with no remnant of liver tissues. It also induced tubular necrosis of renal tubular kidney tissue, and lymphoid hyperplasia with significant congested red pulp in spleen tissue after treatment for 14 days. These findings concluded that *P. americana* hemolymph has prominent hepato-renal and splenic cytotoxic effects of Solid Ehrlich carcinoma cells bearing mice. The histopathological data of *P. americana* hemolymph should be considered while using these materials in the discovery and development of anticancer agents.

### Key Words:

histology, *Periplaneta americana*, liver, kidney, spleen, hemolymph.

### 1. INTRODUCTION

Cancer is the second leading reason for human death following cardiovascular diseases in developing as well as in advanced countries [1]. According to statistics from the World Health Organization (WHO) for the year 2020 in Egypt, the number of new cancer cases was 134632 and the number of deaths was 89042 persons. Cancer is an uncontrollable growth of cells leading to phenotypic in many forms, from mild to life-threatening. Tumor can be developed in many ways, either from DNA destroy, or a mutation in the DNA by loss of function of the controlling and repressor systems in the cell cycle [2]. Various therapies have been used for treating cancer such as chemo, radio, immune, and gene therapy which are very unaffordable in addition to their toxicity to healthy cells leads to many side effects. Therefore, there is still an urgent need to find a replacement natural safe way to treat cancer with lesser effects on normal cells [3].

Natural products are important as a rich reservoir of bioactive compounds with strong therapeutic potentials as anticancer and antimicrobial. In the earlier decades, great efforts have been made to separate new natural products from plants as morphine which had been isolated from the *Papaver somniferum* plant [4]. Likewise, insect preparations such as honey and the venom of bees are alternative medicines for reducing inflammation, cancer therapy, and antioxidant as well as antimicrobial agents [5], [6], [7] [8]. Pederin and cantharidin which are defense secretions of the rove and blister beetles possess anticancer activity [9].

Insects are considered vectors of an extensive array of human and animal parasites leading to numerous infections such as yellow fever and malaria. Unexpectedly, insects are a source of diverse natural constituents that could be used in the evolution of natural bioactive composites and have roles in medical, veterinary, as well as agricultural usages [10]. Insects have been used in traditional medication in several parts of the world. In Chinese medicine, the promising effect of many insects on different illnesses has been known for 3,000 years. Nearly 300 insect species were used in the innovation of about 1,700 traditional Chinese remedies[11]. Additionally, insects possess noteworthy potential sources of many antimicrobial peptides (AMPs), and the confirmation of their antimicrobial effects continuously increases. These AMPs are released into the insect hemolymph; somewhere they attack the elements of the bacterial or fungal cell wall.

Haemolymph is recognized as the blood of insects, it is a complex fluid that has different compartments such as hemocytes, and plasma, in addition to dissolved inorganic and organic molecules. It constitutes around 16-40% of the body weight of insects [12]. This hemolymph serves a function analogous to blood in mammals; it transports nourishment substances, waste products, and signal molecules. Although hemolymph doesn't play a role in respiration it plays a main role in insect immunity because it contains cells and antimicrobial peptides capable of immobilizing and killing invading microorganisms [13].

Cockroaches are among the known primitive-winged insects, with a high diversity of ~4,000 species worldwide. Third of these species are considered as household insects [14]. Cockroaches are widely found in unhygienic environments, so they share environmental niches with human and animal health, and these creatures play a potential role in the transmission of pathogenic organisms in households and hospitals. Cockroaches are physically transmitting allergens from the environment to human habitations suggests their routine exposure to infectious agents is important to humans. The ability of cockroaches to live under such threats and ward off diseases indicates their resistance to pathogenic microbes including superbugs as well as toxicants and hazardous materials, such organisms could be a good source of antimicrobial against human pathogens [15],[16], [17].

*P. americana* is the biggest body size species of cockroaches. They Originated from South America, measure 30–40 mm in length, and are reddish brown. The American cockroach lives in hot areas of buildings like kitchens, heating rooms, warehouses, and sewage systems [18]. A large number of studies have shown that *P. americana* has anti-tumor, anti-bacterial, and anti-viral activity [19].

Selective and more efficient new drugs are urgently needed to address cancer, and these natural products pose challenges to organs such as the liver, kidney, and spleen. Owing to the liver being the major target organ of toxicity, it can show histopathological abnormalities, such as hepatocyte degenerative changes and fat accumulation [20]. Therefore, the objective of this study is to evaluate the toxicity of hemolymph of *P. americana* on the liver, as well as kidney and spleen tissue.

## 2. MATERIALS AND METHODS

**2.1 Collection of Cockroaches:** Adult American cockroaches (*P. Americana*, n = 400) were collected from sewage pipes at Ismailia, Egypt, using sterile surgical gloves. The collected insects were caged into plastic containers with small holes on the top of the lid to provide air for insect respiration.

**2.2 Extraction of Hemolymph:** Collected cockroaches were anesthetized with pure chloroform solution. The limb surface of cockroaches was sterilized with 70% alcohol, then the hemolymph was collected by cutting the leg of the insect with a fine sterile scissor, and the hemolymph was aspirated with an insulin syringe and collected in sterilized tubes. To remove the hemocytes from the hemolymph, it was centrifuged at 10000 rpm at 4°C for 15 minutes. After centrifugation, the supernatant was collected and kept at -20°C until lyophilized using freeze-drying lyophilizer [21]. The obtained lyophilized crude of the extracted hemolymph from the total number of cockroaches was 165mg.

**2.3 Animals:** Forty-two male Swiss albino mice weighing around 20–25 gm were housed in plastic cages (ten animals/cage) under standard laboratory conditions (27 ± 2 °C; 70–80 % humidity; 12-h light/darkness cycle) with standard pellet diet and water were used during the current experiment. These mice were acclimatized to laboratory conditions in the animal house of the Zoology Department at the Faculty of Science, Port Said University, for seven days before experimentation for adaptation after transportation, they were procured from the Egyptian National Cancer Institute, Giza, Egypt. For the induction of solid tumor and obtaining the Ehrlich solid tumor (EST) model, thirty-six mice were intramuscularly injected with 0.2 ml of saline containing 2.5 x 10<sup>6</sup> viable Ehrlich Ascites Carcinoma (EAC) in the right thigh of the lower limb of each mouse. EAC cells were purchased from the Egyptian National Cancer Institute, Giza, Egypt.

The solid tumor was developed within 7 days afterward the injection with EAC cells, and then the mice with distinguished tumors were used in the study. The animals were handled in accordance with current guidelines for the care of laboratory animals and ethical guidelines for the investigation of experimental pain in conscious animals. All efforts were made to minimize the number of animals used and their suffering.

**2.4 Experimental design:** The mice with induced tumors were randomly allocated into six groups, each of six mice per group. The 7<sup>th</sup> group was six normal mice deliberated as a negative control group. So, the seven groups were characterized as follows:

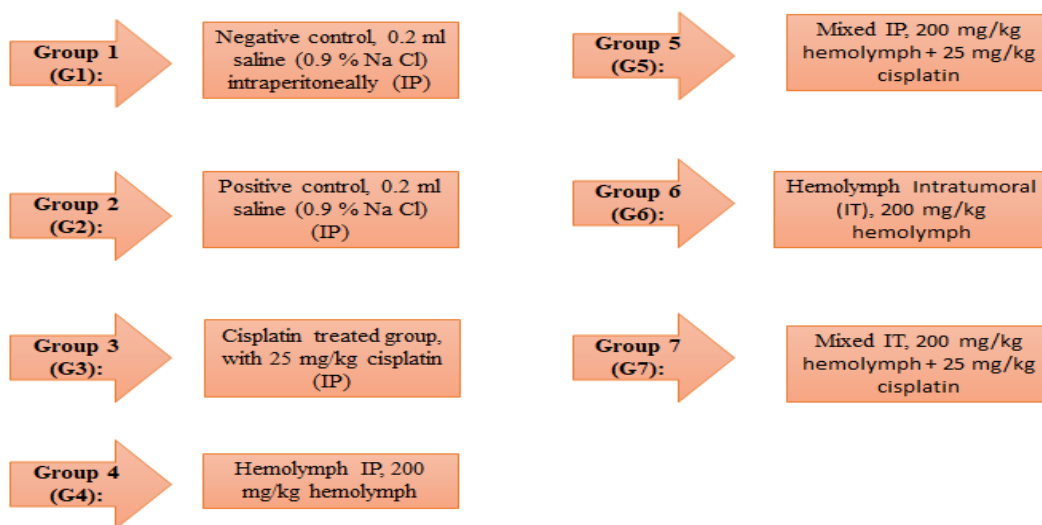


Figure 1: Experimental design[22] , [23]

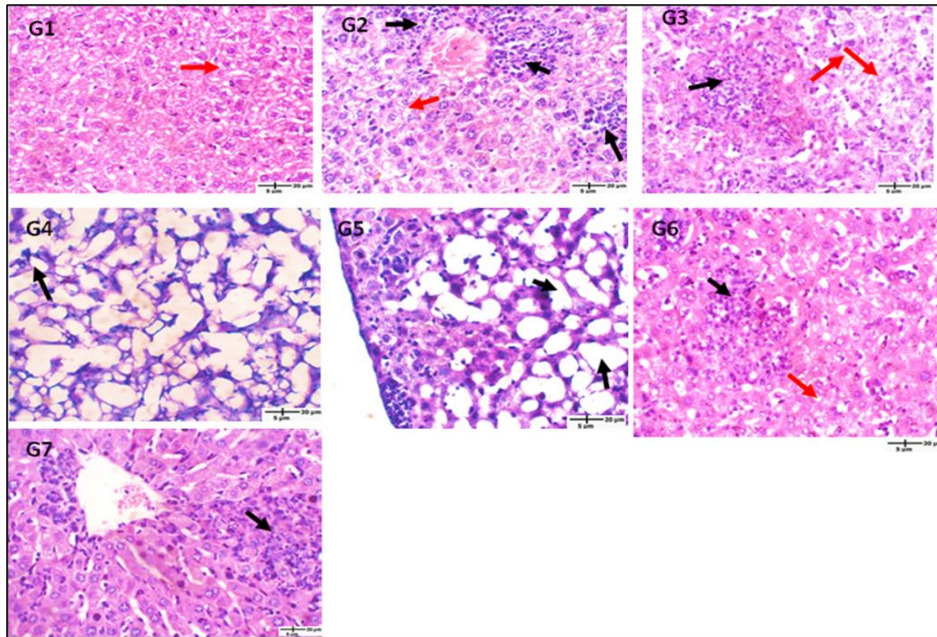
### 2.5 Histopathological examination:

By the completion of the experiment, the mice were gently sacrificed and abdominally dissected. The liver, kidney, and spleen were carefully removed immediately from the dissected mice and washed with a physiological saline solution (0.9% NaCl) to remove the residual blood on their surfaces which might hamper the fixation process. Organ samples were rinsed in the fixative (10% Neutral buffered formalin) for 24 hours. Dehydration and clearing of the tissues were processed routinely and then embedded in paraffin wax [24]. Sections about 5 microns thick were equipped using a microtome and then mounted on clean glass slides. These tissue sections were deparaffinized using xylene twice each for 5 minutes and then rehydrated with descendent-graded concentrations of ethyl alcohol and finally stained with hematoxylin and eosin (H&E) dye. The obtained stained sections were examined and photographed by using a microscope (ZEISS Primo Star), the images were captured in characteristic fields by a Canon A620 Power shot camera.

## 3. RESULTS AND DISCUSSION

### 3.1 The hemolymph of *P. americana* affects the livers of EST-bearing mice:

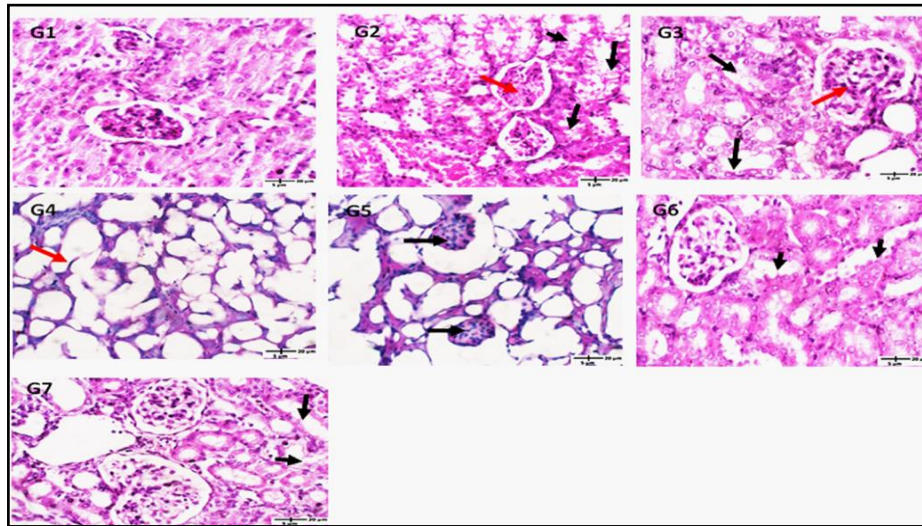
Histological investigation of liver sections of the negative control group showed normal hepatic architecture with sinusoidal spaces and distinct hepatocytes. The normal hepatocytes had a polygonal shape with eosinophilic cytoplasm and a large sphere-shaped nucleus with a remarkable nucleolus where as some hepatocytes had two nuclei (Figure 2, G1). The positive control group showed chronic inflammatory cells and the hepatocytes were substituted with a focal area of grade 3 necrosis and inflammatory cells. The rest of the hepatocytes revealed noticeable hydropic degeneration (Figure 2, G2). Cisplatin treated group displayed normal liver architecture although few areas of confluent grade 1 necrosis with chronic inflammatory cell infiltrate substituting hepatocytes were notable, in addition, some of the hepatocytes indicated moderate hydropic degeneration (Figure 2, G3). The hemolymph IP-treated group showed noticeable grade 6 necrosis accompanied by inflammatory cells where liver tissue couldn't be distinguished due to hepatocyte degeneration (Figure 2, G4). The mixed IP treated group showed just residue of liver tissue with foci of lobular inflammation and the rest of the liver exhibited grade 6 necrosis with inflammatory cells (Figure 2, G5). The hemolymph IT treated group had the expansion of portal tracts with chronic inflammatory cells making occasional portal-to-portal tract extension. There is a significant piecemeal grade 4 necrosis and a prominent area of confluent necrosis with chronic inflammatory cells infiltrating replacing hepatocytes where the recognized hepatocytes showed mild hydropic degeneration (Figure 2, G6). In the mixed IT-treated group, expansion of portal tract with chronic inflammation and confluent grade 4 necrosis with chronic inflammatory cell infiltrate replacing hepatocytes were shown. The hepatocytes in this group showed no hydropic degeneration (Figure 2, G 7).



**Figure. 2.** T.S. in mice liver showed histopathological changes after treatment with different treatment compared with normal mice. G1: negative control group, G2: positive control group, G3: cisplatin treated group, G4: hemolymph IP treated group, G5: cisplatin+ hemolymph (mixed) IP treated group, G6: hemolymph IT treated group, and G7: cisplatin+ hemolymph (mixed) IT treated group. Where, areas of necrosis (Black arrows), the rest of the hepatocytes revealed marked hydropic degeneration (red arrow). Sections were stained with hematoxylin-eosin and examined under a light microscope (40X).

### 3.2 The haemolymph of *P. americana* effect on the kidney of EST-bearing mice:

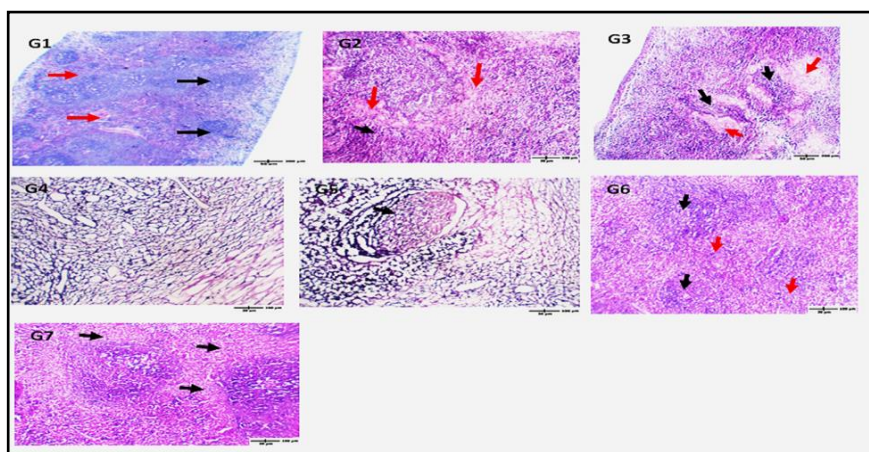
Microscopic investigation of kidney sections of negative control mice displayed normal histological structures of the renal corpuscles and tubules. The corpuscles were composed of the glomerulus which was encircled by Bowman's capsule. The proximal convoluted tubules (PCT) were lined by cuboidal cells with complete brush border, the distal convoluted tubules owning considerably low cuboidal to flatten shaped epithelial cells and have a relatively regular distinct lumen (Figure 3, G1). The kidney tubules of the positive control group exhibited evidence of acute tubular injury, flattening of tubular epithelial cells, grade 3 cell necrosis, loss of brush border and apical vacuolization, and some glomeruli showed mild mesangial expansion; class IIA (Figure 3, G2). In the cisplatin-treated group, few tubules had manifestations of slight grade 1 tubular injury, and some glomeruli presented mild mesangial expansion; class I (Figure 3, G3). The hemolymph IP-treated group demonstrated noticeable grade 1 necrosis of renal tubules where glomeruli couldn't be detected (Figure 3, G4). Furthermore, the mixed IP-treated group displayed noticeable grade 4 renal tubular necrosis and fibrotic sclerosed glomeruli; class IV (Figure 3, G5). The hemolymph IT and mixed IT treated groups had few tubules that showed manifestations of grade 1 mild tubular injury and glomerular injury was not detected (Figure 3, G6 and G7).



**Figure. 3.** T.S. in mice kidneys displayed histopathological changes after treatment with different treatment compared with normal mice. G1: negative control group, G2: positive control group, G3: cisplatin treated group, G4: hemolymph IP treated group, G5: cisplatin+ hemolymph (mixed) IP treated group, G6: hemolymph IT treated group, and G7: cisplatin+ hemolymph (mixed) IT treated group. Black arrows referring to areas of flattening of tubular epithelial cells, necrosis of cells, loss of brush border, and apical vacuolization. The red arrow referring to glomeruli with mild mesangial expansion. Sections were stained with hematoxylin-eosin and examined under a light microscope (40X).

### 3.3 The hemolymph of *P. americana* affect the spleen of EST-bearing mice:

Spleen sections from the negative control group revealed that the splenic architecture was uniform, in which white pulp was made of lymphoid follicles, and red pulp was developed between splenic sinusoids (Figure 4.G1). The positive control group revealed evidence of moderate lymphoid hyperplasia and mildly congested red pulp (Figure 4.G2). The cisplatin-treated group exhibited signs of moderate lymphoid hyperplasia and congested red pulp (Figure 4.G3). The IP hemolymph-treated group revealed marked necrosis with no remnant of normal splenic tissue (Figure 4.G4). In the IP mixed-treated group, marked necrosis with the remnant of white pulp was observed (Figure 4.G5). The IT haemolymph-treated group showed evidence of mild lymphoid hyperplasia and significant congested red pulp (Figure 4.G6). Finally, the IT mixed-treated group displayed moderate congested red pulp that was easily distinguished (Figure 4.G7).



**Figure. 4.** T.S. in mice spleens indicated the histopathological changes after treatment with different treatment compared with normal mice. G1: negative control group, G2: positive control group, G3: cisplatin-treated group, G4: haemolymph IP treated group, G5: cisplatin+ hemolymph (mixed) IP treated group, G6: hemolymph IM treated group, and G7: cisplatin+ haemolymph (mixed) IT treated group. Black arrows refer to areas of white pulp formed of lymphoid follicles in between splenic sinusoids forming red pulp (Red arrows). Sections were hematoxylin-eosin stained and examined under a light microscope (4X and 10X).

The experimental model of cancer plays a remarkable role in cancer therapy and alternative drug discovery. A considerable number of *in vivo* experimental studies based on laboratory animals include induction of carcinoma by Ehrlich cells, it is an aggressive and rapidly growing carcinoma which able to improve in both the ascitic and solid forms depending on whether they, Ehrlich cells, inoculated intraperitoneal or subcutaneously respectively [22,23]. Ehrlich carcinoma is an undifferentiated carcinoma characterized by fast proliferation, high translatable capability, and 100% malignancy. Instead, tumor growth can make changes in liver, kidney, and spleen functions and structure [24,25].

Several widely-used anticancer therapeutics originate from natural sources, the insects have been relatively ignored as a source of modern treatments although they have provided valuable natural products [29]. Furthermore, insects were supposed to possess antimalarial and anticancer compounds, however, the data about their toxicity are required to assess the safety margin before they could be used in drug discovery studies and medical purposes [11].

In the present study, the histopathological evaluation of liver tissues after treatment with *P. americana* hemolymph in mice revealed that the hemolymph-treated group had marked necrosis with an inflammatory cell infiltration with no remnant of liver tissues. Similar necrotic effects have been detected after treatment of normal liver tissues with the extract of aqueous beetle cocoon *Larinus maculates*. This latter study investigation showed a moderate aggregation in the hepatic central vein and moderate to severe cell infiltration of the white blood cells within the liver tissue at a low dose of the beetle extract. On the other hand, the treatment with a high dose of the same extract revealed severe aggregation and cell infiltration in the liver tissue of the treated mice [30].

The presence of severe aggregation, cell filtration, and necrotic hepatocytes could have resulted in an inflammatory response against the pathogenic effect of the treatment. These necrotic effects of such insect products may be attributed to the effect of proteases which are very common in insects [31]. Some proteases have been shown to have toxic effects on tissues, particularly when they are present in high concentrations and they can cause damage and abnormal prolongation of the inflammatory stages of healing that prevents the wound from progressing to the proliferative phase, hence, the protease activity may contribute to necrosis to tissue [29, 30].

Histological examination of the kidney tissues after treatment with *P. americana* hemolymph in mice in the existing study exhibited tubular necrosis of renal tubules of the kidneys. The results of the investigation revealed some degree of renal damage following cockroach hemolymph treatment. Previous studies have reported the presence of lectins in the cavities of cockroaches which identify the foreign or harmful bacteria and stimulate the innate immunity response against pathogens [34]. Lectins are a common group of proteins present in arthropods and possess a variety of biological effects such as antimicrobial, antioxidant, and anticancer activities and can be considered as a potential natural bioactive agent [32,33]. However, lectin also is known to have some toxic effects at high concentrations creating some complications in terms of its usage as a therapy against proliferating cells [37]. However, if it was used at low doses as appeared in cockroach lysates, lectin showed antimicrobial activity and was safe for human cells [38]. The presence of lectins in different biological extracts reflected necrotic effect/s in kidney cells with asymmetric glomerulus and thickening of proximal and distal tubules [39].

Similarly, the histopathology of the spleen tissues of treated groups with *P. americana* hemolymph in mice showed marked necrosis and the tissue was found between mild to moderate lymphoid hyperplasia and significant congested red pulp. These findings may shed light on the lectin effect of cockroaches on spleen tissue [40].

The results observed that the hemolymph of *P. americana* showed anticancer activity against the solid Ehrlich carcinoma in mice when they were treated at different doses with the hemolymph. However, the hemolymph of *P. americana* treatment showed a necrotic effect on liver, kidney, and spleen tissues. In this regard, the selection of new natural anticancer products is important to be evaluated based on their safety versus efficacy.

#### 4. CONCLUSION

The present study revealed the hemolymph extract of American cockroach *P. americana* toxicity when used as an anticancer in Solid Ehrlich carcinoma-induced mice. The extract exhibited anticancer activity nevertheless it revealed a necrotic effect on liver, kidney, and spleen organs.

#### 5. REFERENCES

- [1] B. P. Bandgar, S. S. Gawande, R. G. Bodade, J. V. Totre, and C. N. Khobragade, "Synthesis and biological evaluation of simple methoxylated chalcones as anticancer, anti-inflammatory and antioxidant agents," *Bioorganic & medicinal chemistry*, vol. 18, no. 3, pp. 1364–1370, 2010.
- [2] I. Calcaterra, G. Iannuzzo, F. Dell'Aquila, and M. N. D. Di Minno, "Pathophysiological role of synovitis in hemophilic arthropathy development: a two-hit hypothesis," *Frontiers in Physiology*, vol. 11, p. 541, 2020.
- [3] Rodrigues, E.G., Dobroff, A.S., Cavarsan, C.F., Paschoalin, T., Nimrichter, L., Mortara, R.A., Santos, E.L., Fázio, M.A., Miranda, A., Daffre, S., "Effective topical treatment of subcutaneous murine B16F10-Nex2 melanoma by the antimicrobial peptide gomesin," *Neoplasia*, vol. 10, no. 1, pp. 61–68, 2008.
- [4] A. A. Siddiqui, F. Iram, S. Siddiqui, and K. Sahu, "Role of natural products in drug discovery process," *International journal of drug development and research*, vol. 6, no. 2, pp. 0–0, 2014.
- [5] O. O. Erejuwa, S. A. Sulaiman, and M. S. Ab Wahab, "Honey: a novel antioxidant," *Molecules*, vol. 17, no. 4, pp. 4400–4423, 2012.
- [6] M.-Y. Huang, L.-L. Zhang, J. Ding, and J.-J. Lu, "Anticancer drug discovery from Chinese medicinal herbs," *Chinese medicine*, vol. 13, no. 1, pp. 1–9, 2018.
- [7] Y. Bellik, "Bee venom: its potential use in alternative medicine," *Anti-infective agents*, vol. 13, no. 1, pp. 3–16, 2015.
- [8] D. J. Newman and G. M. Cragg, "Natural products as sources of new drugs over the nearly four decades from 01/1981 to 09/2019," *Journal of natural products*, vol. 83, no. 3, pp. 770–803, 2020.
- [9] A. T. Dossey, "Insects and their chemical weaponry: new potential for drug discovery," *Natural product reports*, vol. 27, no. 12, pp. 1737–1757, 2010.
- [10] N. L. El-Tantawy, "Helminthes and insects: maladies or therapies," *Parasitology research*, vol. 114, no. 2, pp. 359–377, 2015.
- [11] N. A. Ratcliffe, C. B. Mello, E. S. Garcia, T. M. Butt, and P. Azambuja, "Insect natural products and processes: new treatments for human disease," *Insect biochemistry and molecular biology*, vol. 41, no. 10, pp. 747–769, 2011.
- [12] A. Z. Sahalan, B. Omar, A. Y. Mohamed, and J. Jeffery, "Antibacterial activity of extracted hemolymph from larvae and pupae of local fly species, *Musca domestica* and *Chrysomya megacephala*," *Jurnal Sains Kesihatan Malaysia*, vol. 4, no. 2, pp. 1–11, 2007.
- [13] K. Kavanagh and E. P. Reeves, "Exploiting the potential of insects for in vivo pathogenicity testing of microbial pathogens," *FEMS microbiology reviews*, vol. 28, no. 1, pp. 101–112, 2004.
- [14] Chung, H.S., Yu, T.H., Kim, B.J., Kim, S.M., Kim, J.Y., Yu, H.S., Jeong, H.J., Ock, M.S., 2005. Expressed sequence tags analysis of *Blattella germanica*. *The Korean Journal of Parasitology* 43, 149.
- [15] A. Salehzadeh, P. Tavacol, and H. Mahjub, "Bacterial, fungal and parasitic contamination of cockroaches in public hospitals of Hamadan, Iran," *Journal of vector borne diseases*, vol. 44, no. 2, p. 105, 2007.
- [16] M. Stankiewicz, M. Dąbrowski, and M. E. De Lima, "Nervous system of *Periplaneta americana* cockroach as a model in toxinological studies: A short historical and actual view," *Journal of Toxicology*, vol. 2012, 2012.



- [17] Ali, S.M., Siddiqui, R., Ong, S.-K., Shah, M.R., Anwar, A., Heard, P.J., Khan, N.A., 2017. Identification and characterization of antibacterial compound (s) of cockroaches (*Periplaneta americana*). *Applied Microbiology and Biotechnology* 101, 253–286.
- [18] Li, S., Zhu, S., Jia, Q., Yuan, D., Ren, C., Li, K., Liu, S., Cui, Y., Zhao, H., Cao, Y., 2018. The genomic and functional landscapes of developmental plasticity in the American cockroach. *Nature Communications* 9, 1008.
- [19] Y. Zhao, A. Yang, P. Tu, and Z. Hu, “Anti-tumor effects of the American cockroach, *Periplaneta americana*,” *Chinese medicine*, vol. 12, no. 1, pp. 1–6, 2017.
- [20] K. Yuet Ping, I. Darah, Y. Chen, S. Sreeramanan, and S. Sasidharan, “Acute and subchronic toxicity study of *Euphorbia hirta* L. methanol extract in rats,” *BioMed research international*, vol. 2013, 2013.
- [21] U. M. Seraj, M. I. Hoq, M. N. Anwar, and S. Chowdhury, “A 61kDa antibacterial protein isolated and purified from the hemolymph of the American cockroach *Periplaneta americana*,” *Pakistan Journal of Biological Sciences (Pakistan)*, 2003.
- [22] Na Li, Rongzhu Lu, Yuanyuan Yu, Ying Lu, Lu Huang, Juan Jin, Lidan Zhang & Jun Chen., “Protective effect of *Periplaneta americana* extract in ulcerative colitis rats induced by dinitrochlorobenzene and acetic acid,” *Pharmaceutical Biology*, vol. 54, no. 11, pp. 2560–2567, Nov. 2016, doi: 10.3109/13880209.2016.1170862.
- [23] Cierra N. Sharp, Mark A. Doll, Tess V. Dupre, Parag P. Shah, Marimuthu Subathra, Deanna Siow, Gavin E. Arteel, Judit Megyesi, Levi J. Beverly, and Leah J. Siskind, “Repeated administration of low-dose cisplatin in mice induces fibrosis,” *American Journal of Physiology-Renal Physiology*, vol. 310, no. 6, pp. F560–F568, Mar. 2016, doi: 10.1152/ajprenal.00512.2015.
- [24] D. Elkotby, A. K. Hassan, R. Emad, and I. Bahgat, “Histological changes in islets of Langerhans of pancreas in alloxan-induced diabetic rats following Egyptian honey bee venom treatments,” *Int J Pure Appl Zool*, vol. 6, no. 1, pp. 1–6, 2018.
- [25] V. T. DeVita, T. S. Lawrence, and S. A. Rosenberg, *Cancer: principles & practice of oncology: primer of the molecular biology of cancer*. Lippincott Williams & Wilkins, 2012.
- [26] Mishra, S., Tamta, A.K., Sarikhani, M., Desingu, P.A., Kizkekra, S.M., Pandit, A.S., Kumar, S., Khan, D., Raghavan, S.C., Sundaresan, N.R., “Subcutaneous Ehrlich Ascites Carcinoma mice model for studying cancer-induced cardiomyopathy,” *Scientific reports*, vol. 8, no. 1, p. 5599, 2018.
- [27] M. M. El-Keey, M. A. El Ghonamy, T. M. Ali, W. M. Ibrahim, and E. Tousson, “Effect of sulforaphane and methotrexate combined treatment on histone deacetylase activity in solid ehrlich carcinoma,” *Journal of Bioscience and Applied Research*, vol. 3, no. 3, pp. 62–69, 2017.
- [28] M. A. Aldubayan, R. M. Elgharabawy, A. S. Ahmed, and E. Tousson, “Antineoplastic activity and curative role of avenanthramides against the growth of ehrlich solid tumors in mice,” *Oxidative medicine and cellular longevity*, vol. 2019, 2019.
- [29] H. Izuta, Y. Chikaraishi, M. Shimazawa, S. Mishima, and H. Hara, “10-Hydroxy-2-decenoic acid, a major fatty acid from royal jelly, inhibits VEGF-induced angiogenesis in human umbilical vein endothelial cells,” *Evidence-based complementary and alternative medicine*, vol. 6, no. 4, pp. 489–494, 2009.
- [30] M. A. Jawad, A. J. Kadhim, and S. Y. Hasan, “Histological Study of the Effect of Aqueous Extract of the Beetle Cocoon on Liver Tissue of Male Mice,” *Archives of Razi Institute*, vol. 76, no. 5, pp. 1561–1564, 2021.
- [31] M. R. Kanost and H. Jiang, “Clip-domain serine proteases as immune factors in insect hemolymph,” *Current opinion in insect science*, vol. 11, pp. 47–55, 2015.
- [32] X. Saelens et al., “Protein synthesis persists during necrotic cell death,” *The Journal of cell biology*, vol. 168, no. 4, pp. 545–551, 2005.
- [33] R. Legerstee, “The ‘chronic’ wound debate,” *Wounds International*, vol. 1, no. 1, pp. 1–2, 2009.
- [34] R. Siddiqui, Y. Elmashak, and N. A. Khan, “Cockroaches: a potential source of novel bioactive molecule (s) for the benefit of human health,” *Applied entomology and zoology*, vol. 58, no. 1, pp. 1–11, 2023.
- [35] Cheung, R.C.F., Wong, J.H., Pan, W., Chan, Y.S., Yin, C., Dan, X., Ng, T.B., 2015. Marine lectins and their medicinal applications. *Applied Microbiology and Biotechnology* 99, 3755–3773.
- [36] I Pinto, I.R., Chaves, H.V., Vasconcelos, A.S., de Sousa, F.C.F., Santi-Gadelha, T., de Lacerda, J.T.J., Ribeiro, K.A., Freitas, R.S., Maciel, L.M., Viana, A.F.S.C., 2019. Antiulcer and antioxidant

- activity of a lectin from *Mucuna pruriens* seeds on ethanol-induced gastropathy: involvement of alpha-2 adrenoceptors and prostaglandins. *Current Pharmaceutical Design* 25, 1430–1439.
- [37] T. Yau, X. Dan, C. C. W. Ng, and T. B. Ng, “Lectins with potential for anti-cancer therapy,” *Molecules*, vol. 20, no. 3, pp. 3791–3810, 2015.
- [38] Ali, S.M., Siddiqui, R., Ong, S.-K., Shah, M.R., Anwar, A., Heard, P.J., Khan, N.A., 2017. Identification and characterization of antibacterial compound (s) of cockroaches (*Periplaneta americana*). *Applied Microbiology and Biotechnology* 101, 253–286.
- [39] L. L. de Siqueira Patriota *et al.*, “Microgramma vacciniifolia frond lectin (MvFL) exhibits antitumor activity against sarcoma 180 in mice,” *Phytomedicine Plus*, vol. 1, no. 1, p. 100013, 2021.
- [40] S. K. Lam and T. B. Ng, “Lectins: production and practical applications,” *Applied microbiology and biotechnology*, vol. 89, pp. 45–55, 2011.