

Evaluation of gastric tube as an operative procedure for esophageal replacement in pediatric age group: A single centre experience**Ahmed Khairi^a, Yasser Saad Eldin^a, Karim Badr^a, Ahmed Elrouby^{a*}**

^aDepartment of Pediatric Surgery, Faculty of Medicine, Alexandria University, Alexandria, Egypt

Abstract

Background: Long-gap esophageal atresia (EA) and post-corrosive esophageal stricture (PCES) are the most common indications for esophageal replacement in children.

Objectives: This study was conducted to evaluate gastric tube as an operative procedure for esophageal replacement in pediatric age group.

Patients and Methods: Our prospective study included 20 patients who were presented to Alexandria University Specialized Pediatric Hospital for esophageal replacement during the period from June 2021 to January 2023. The study included 16 patients with EA and 4 patients with PCES; there were 12 males and 8 females. The age of the studied patients at the time of the operation ranged from 9 months to 50 months. The weight of the included patients at the time of operation ranged from 10 to 15 kg. All patients were operated on by retrosternal isoperistaltic gastric tube procedure by the same surgical team.

Results: All cases have excellent to good results according to long-term follow-up. Cervical wound leakage followed by anastomotic stricture was the most common postoperative complication. Most cases with cervical leakage healed spontaneously without any surgical intervention and most cases with anastomotic stricture responded well to regular esophageal dilatations. We had only one case of mortality (5%) due to severe chest infection and sepsis.

Conclusion: In experienced hands, the rate of complications in gastric tube esophagoplasty is minimal.

Keywords: Esophageal atresia; Corrosive esophageal stricture; Gastric tube.

DOI: 10.21608/svuijm.2023.240068.1712

***Correspondence:** elroubypaedo@gmail.com; ahmed.elrouby@alexmed.edu.eg

Received: 6 October, 2023.

Revised: 2 November, 2023.

Accepted: 10 November, 2023.

Published: 2 December, 2023

Cite this article as: Ahmed Khairi, Yasser Saad Eldin, Karim Badr, Ahmed Elrouby (2023) Evaluation of gastric tube as an operative procedure for esophageal replacement in pediatric age group: A single centre experience. *SVU-International Journal of Medical Sciences*. Vol.6, Issue 2, pp: 880-899 .

Copyright: © Khairi et al (2023) Immediate open access to its content on the principle that making research freely available to the public supports a greater global exchange of knowledge. Users have the right to Read, download, copy, distribute, print or share link to the full texts under a [Creative Commons BY-NC-SA 4.0 International License](https://creativecommons.org/licenses/by-nc-sa/4.0/)

Introduction

Long-gap esophageal atresia (EA) and intractable corrosive esophageal strictures (PCES) are the main two indications for esophageal replacement in children. (**Spitz et al.,2004; Hamza et al.,2003; Lee et al.,2014; Chirica et al., 2015; Pearson et al.,2010; Richard et al., 2005**)

EA is considered one of the major congenital gastrointestinal defects with an incidence of one in every 2500 live births. (**Krishnan,2019**) On the other hand, PCES remains a significant health concern with an estimated incidence of 5000–15,000 caustic ingestions occurring in the USA every year. (**Lobeck and Von Allmen,2017**) Acidic solutions typically result in instantaneous pain, and unless purposeful ingestion occurs, the agent is quickly ejected. However, alkali solutions frequently have no taste or smell and must be ingested before defensive reflexes may be triggered. (**Havanond,2003**)

So an efficient conduit from the mouth to the stomach needs to be created, to satisfy the nutritional needs of the child. This conduit should continue to grow with the child and function well into adult life. (**Spitz,2011**) Colon interposition, gastric tube interposition, gastric pull-up, and jejunal interposition are all surgical esophageal replacement options. (**Richard et al., 2005**)

Our study will highlight the outcome and complications of a single-center experience in gastric tube

esophagoplasty (GTE) procedure for esophageal replacement in the pediatric age group.

Patients and methods

Data collection: This prospective study included 20 patients who were indicated for esophageal replacement at Alexandria University Specialized Pediatric Hospital during the period from June 2021 to January 2023.

Criteria of selection: All patients with post-corrosive esophageal stricture who failed endoscopic dilatation and long gap esophageal atresia, operated by the gastric tube esophagoplasty procedure who were presented to our center during the period of study were enrolled in our study. The studied patients were enrolled in our study with an age ranging between 6 months and 10 years and weights higher than 10 kilograms. Patients with other major co-morbidities as severe cardiac anomalies being unfit for surgery were excluded from our study.

Preoperative assessment: All patients were subjected to full routine clinical examination and investigative studies preoperatively to assess their fitness for surgery and detect any associated anomalies. Preoperative chest X-ray and barium contrast study were performed at least one month after ingestion of the corrosive to detect the site and extent of the esophageal stricture as well as to study the gastric size and to detect any associated pathological gastric stricture and/or secondary gastro-esophageal reflux. (**Fig.1**)

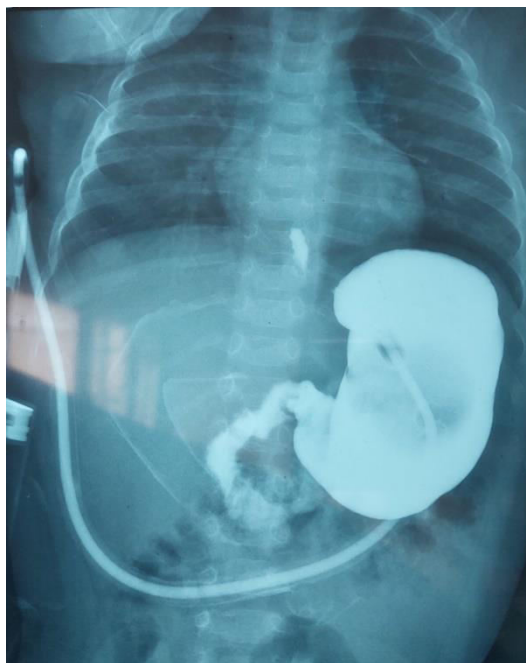


Fig.1. Pre-operative barium study showing an average gastric capacity

A preoperative endoscopic study was performed as a trial for dilatation for the post-corrosive stricture group. Cases that failed 2 attempts of surgical dilatation by Savary-Guillard dilators were considered as a failure and prepared for esophageal replacement. ECHO was performed for esophageal atresia patients to exclude cardiac anomalies

Patients were admitted one day before surgery for routine clinical and laboratory evaluation. They were given a plain diet and fluids 24 hours before surgery. Before starting the operation, reliable intravenous access was secured (usually a right internal jugular central catheter), and a urinary catheter was inserted to monitor urine output.

The parents or the patient's guardians signed an informed consent after a complete discussion with them about the operative procedure and possible operative and postoperative complications

which included anastomotic stricture which may need postoperative dilatations and the possibility of anastomotic leakage. All cases were done under general anesthesia & and operated upon by the same surgical team.

Operative technique for GTE procedure: We performed a retrosternal isoperistaltic gastric tube esophagoplasty in all of the included patients. (Sharma and Gupta,2017 ; Lewis Spitz and Arnold Coran,2012 ; Arul and Parikh,2008)

1. **Position :**The patient was placed in the supine position, with neck extension using a pillow below the shoulders and turning of the neck to the right. The abdomen, chest, and neck were prepared and exposed in one operative field.
2. **Operative Procedure:**

The abdomen was opened through an upper midline incision. The gastrotomy,

if present, was taken down. The surgical anatomy of the stomach was examined as well as its blood supply. The gastrocolic omentum was divided and its vessels were ligated as far as possible from the gastroepiploic arch, and the short gastric vessels were also ligated and divided. The

distance between a point at the level of the esophagostomy (if present) or at a point between the two heads of the sternomastoid muscle and another point at the fundus of the stomach was measured (the length of the new tube). (**Fig.2**)

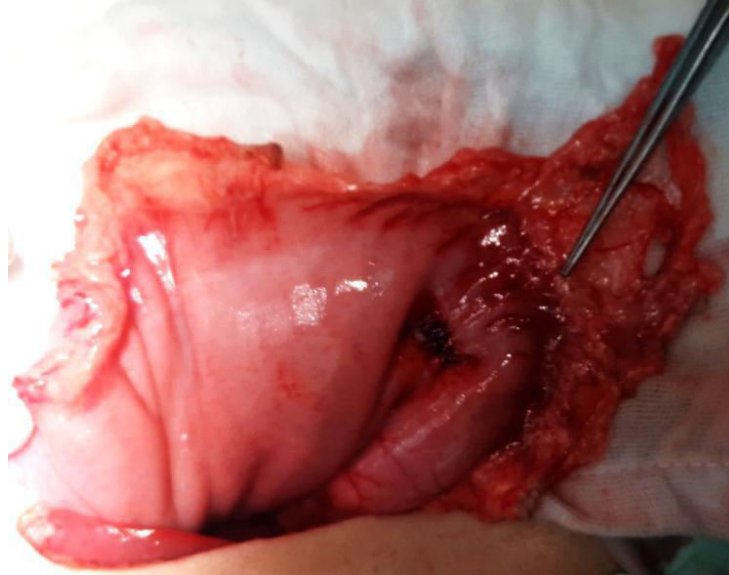


Fig.2. Identification of the gastroepiploic vessels before tube fashioning.

The tube was based distally receiving its blood supply from the right gastroepiploic vessels. The incision was made at the fundus of the stomach and a Nelton tube (18-24 Fr) was inserted along the greater curvature of the stomach and the length of the future gastric tube was designed and measured. (**Fig. 3**)

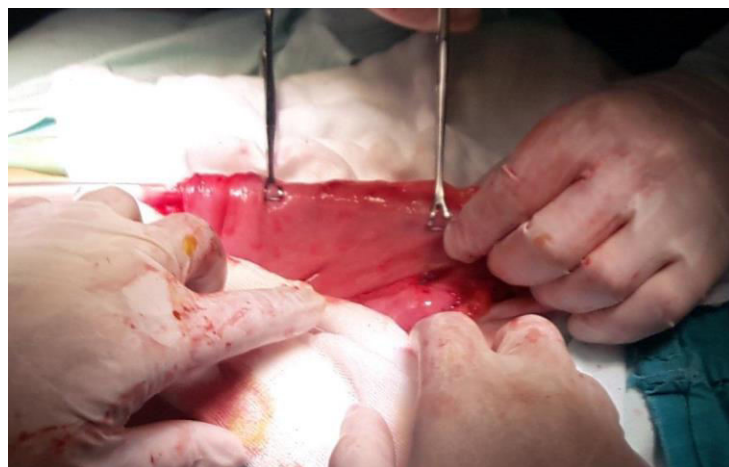

Fig.3. Preparing the greater curvature for the fashioning of the isoperistaltic gastric tube.

A GIA stapler was used to perform the future tube usually with two or three applications. Seromuscular interrupted

reinforcement sutures were done by Vicryl 4/0 along the stapler line. (Fig. 4 & Fig. 5)

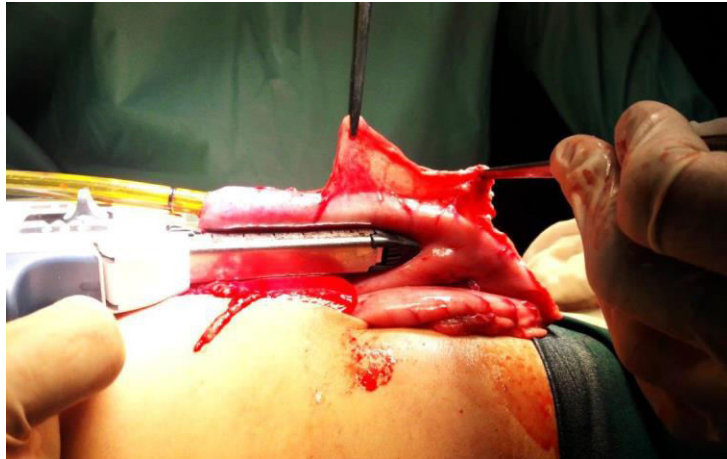


Fig. 4. Fashioning of the isoperistaltic gastric tube starting from the fundus of the stomach (1st fire using GIA stapler).

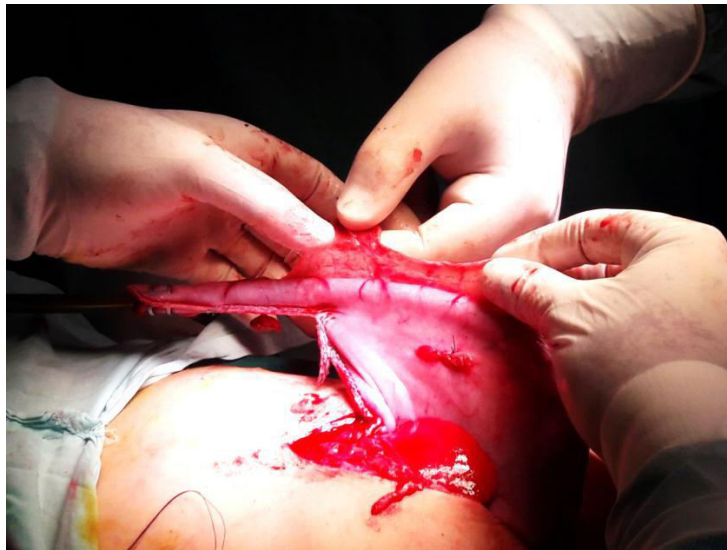

Fig.5. The gastric tube before applying the 2nd fire with the GIA stapler.

A patency test was done by injection of saline to ensure water

tightness and exclude any leakage along the suture line. (Fig. 6)

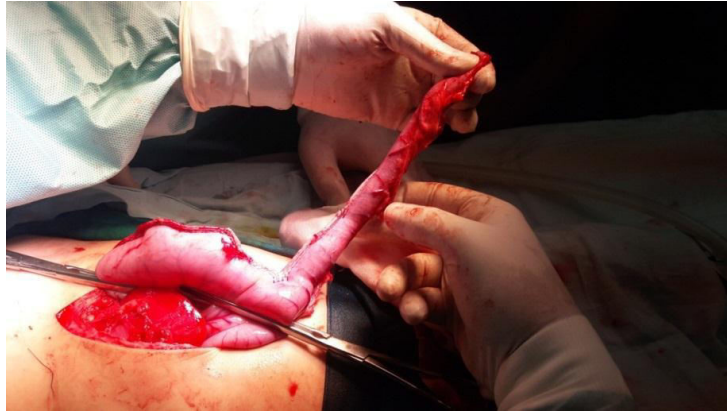

Fig. 6. Water-tight testing of the fashioned isoperistaltic gastric tube to exclude any leakage.

The retrosternal route was performed starting by dissection between the sternal origin of the diaphragm and the xiphisternum. This retrosternal tunnel was created by blunt dissection from below, in close contact with the posterior surface of the sternum. Using the surgeon's index finger until it reached the suprasternal notch where an incision was done -taking care of the surrounding vessels-. The other surgeon's index finger was inserted through the newly performed incision starting blunt dissection from above until

it met the other finger coming from below to complete the tunnel. The tube was passed retrosternal by passing it anterior to the left lobe of the liver and posterior to the xiphisternum. The wide thoracic inlet was secured by detaching the strap muscles from the manubrium.

Transhiatal esophagectomy was done in patients with PCES by cutting the left triangular ligament of the liver followed by dissection of the esophagus encircling it with a tape. The esophageal hiatus was then explored with the help of retractors inside the hiatus. (**Fig. 7**)

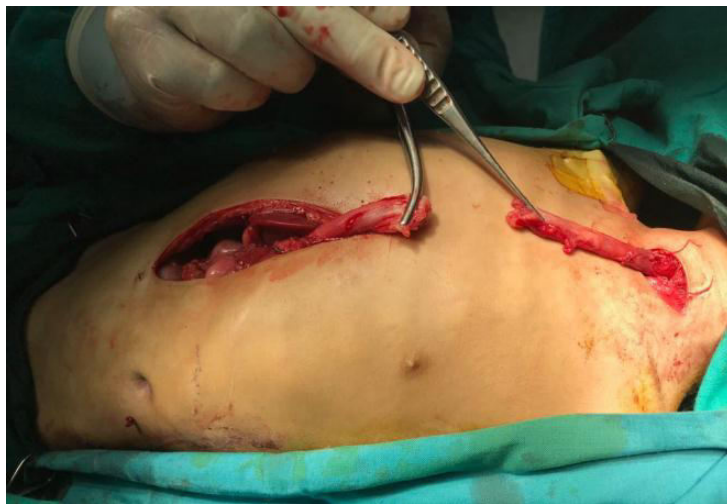

Fig.7. Complete upper and lower esophageal dissection during esophagectomy.

Using blunt and sharp dissection, the esophagus was freed as high as possible carefully to avoid pleural injury. Simultaneous upper and lower blunt finger dissection of the esophagus was done until the dissection was complete (Both fingers touch each other). The esophagectomy then was done by cutting the esophagus at the cardia with the

closure of the gastric end. The esophagus then was passed upward from the cervical incision.

Through a left lower transverse cervical incision, the upper esophagus was dissected and prepared to be anastomosed to the proximal end of the gastric tube. (Fig.8)

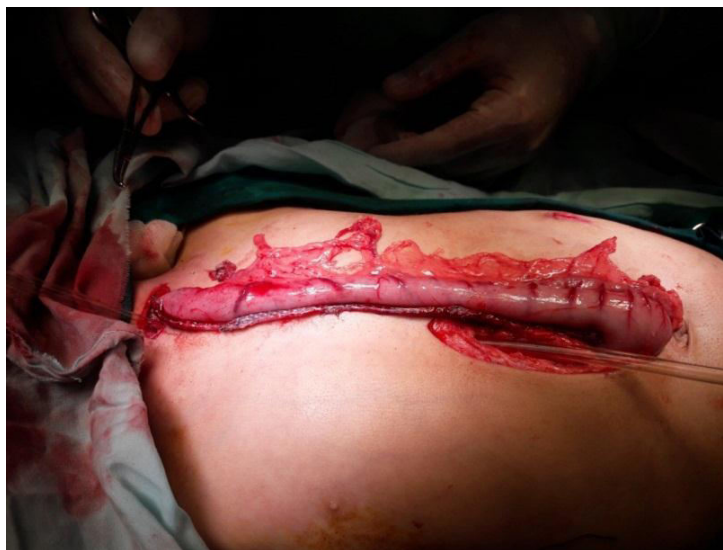

Fig.8. The completely fashioned isoperistaltic gastric tube based on the right gastroepiploic arcade.

The esophagogastric anastomosis was made between the cervical esophagus and the proximal end of the gastric tube by interrupted sutures, using Vicryl 4/0 starting by the posterior wall followed by the introduction of the nasogastric tube and finally closure of the anterior wall.

The fashioning of the gastrostomy was made to allow maintenance of postoperative nutrition and help increase the capacity of the residual stomach. Closure of the abdomen after inserting an intra-peritoneal drain. Closure of the cervical wound after inserting cervical rubber drain.

- **Postoperative care**

After confirming good postoperative recovery; the patients were

transferred to the surgical ICU and kept in the semi-sitting position to avoid reflux and reduce the incidence of chest infection. Chest physiotherapy started on the 2nd postoperative day.

Daily wound dressing was done with local antiseptic and topical antibiotic in association with drain monitoring.

IV fluids in addition to PPI proton pump inhibitors, analgesics, and parenteral broad-spectrum antibiotics were given. A chest x-ray was performed on all patients after complete stabilization to exclude the presence of pneumothorax.

Early postoperative assessment to detect any complications; such as graft necrosis, bleeding, leakage, chest

infection, and wound complications. Also, the cervical wound was monitored for any cervical salivary fistula, as well as the number of saliva-soaked gauzes per day.

The patients were kept NPO until full restoration of normal intestinal motility as indicated by good intestinal sounds, lax abdomen, clear gastrostomy tube aspirate, and passage of stool when a contrast study was done –usually at the end of the 1st postoperative week to exclude any anastomotic leakage. After ensuring an intact conduit; oral feeding was started and the abdominal drain was removed. The cervical drain was removed when there was no residual discharge. The patients continued postoperatively on oral PPI and/or H2 blocker to avoid reflux and its

consequences, e.g. esophagitis and peptic ulceration.

The postoperative follow-up

The follow-up was done at the outpatient clinic at the 2nd postoperative week and at the end of the 1st, 3rd, and 6th postoperative months to monitor the development of any late complications e.g. dysphagia, stricture, adhesive intestinal, and/ or any respiratory or swallowing problems and manage accordingly.

Clinical and radiological follow-up was done by performing a Barium study at the 6th postoperative week and the end of the 6th postoperative month (**Fig.9**). The contrast study was done to exclude any stricture, reflux, and/ or redundancy of the gastric tube.

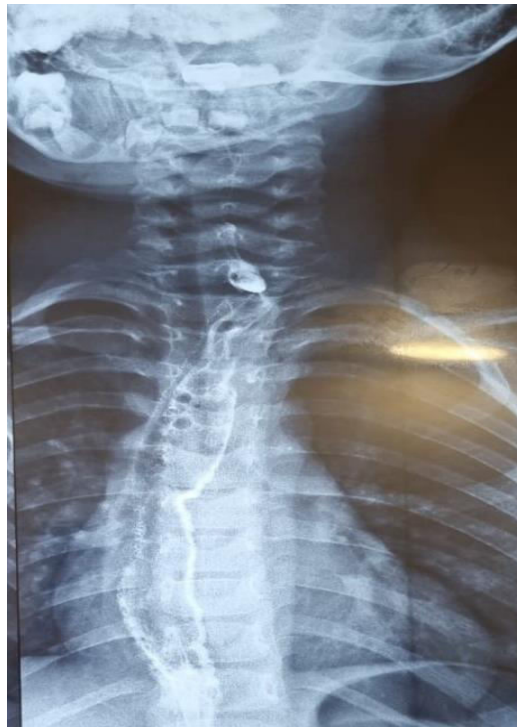

Fig.9. Antero-posterior view of a postoperative Barium study showing the retrosternal gastric tube.

Statistical analysis

Data were fed to the computer and analyzed using IBM SPSS software

package version 20.0. (Armonk, NY: IBM Corp). Qualitative data were described using numbers and

percentages. Quantitative data were described using range (minimum and maximum), mean, standard deviation, median, and interquartile range (IQR).

Results

Demographic data

Our study included 20 patients in whom GTE was done during the study period for esophageal replacement at El Shatby University Hospital for children. The patients were divided into two groups according to the indication for replacement; Group A included patients

with long-gap EA (n=16) and Group B included patients with PCES (n=4).

The male-to-female ratio was 3:2 in our study with the age of the studied patients at the time of the operation ranging from 9 to 50 months. The mean age in Group A was (12.38 ± 2.19) months and (31.0 ± 15.53) months in Group B. Weight of the studied patients at the time of surgery ranged from 10 to 15 kg. The mean weight in Group A was 10.97 ± 1.01 kg and 12.38 ± 2.06 kg in Group B. (Table. 1)

Table 1. Comparison between the two studied groups according to the demographic data

Demographic data	Total (n = 20)		Group A (n = 16)		Group B (n = 4)	
	No.	%	No.	%	No.	%
Sex						
Male	16	80.0	13	81.3	3	75.0
Female	4	20.0	3	18.8	1	25.0
Age (month)						
Min. – Max.	9.0 –50.0		9.0 – 16.0		14.0 – 50.0	
Mean ± SD.	16.10 ±10.02		12.38 ± 2.19		31.0 ± 15.53	
Median (IQR)	13.50 (12.0 –15.0)		12.0 (10.50 – 14.0)		30.0 (19.0 – 43.0)	
Weight (kg)						
Min. – Max.	10.0 –15.0		10.0 – 13.0		10.0 – 15.0	
Mean ± SD.	11.25 ±1.34		10.97 ± 1.01		12.38 ± 2.06	
Median (IQR)	11.0 (10.0 –12.0)		10.75 (10.0 – 11.75)		12.25 (11.0 – 13.75)	

Group A = patients with esophageal atresia and group B = patients with post-corrosive esophageal stricture

All cases of EA had esophagostomy and feeding gastrostomy after failed primary repair. On the other hand, half of the patients with PCES required a feeding gastrostomy to improve their general condition before the operation, and all of them did not show any improvement after repeated endoscopic dilatations.

Operative data

All of the studied patients were operated on by the same surgical team

using an isoperistaltic GTE based on the right gastroepiploic arcade in a retrosternal position without any conduit passing trans-hiatal; pyloroplasty was not done in any cases.

As for the operative duration; it ranged from 90 to 160 minutes with a mean of 116.56 ± 13.51 minutes in Group A and 137.50 ± 20.62 minutes in Group B. Gastrostomy feeding was started two to ten postoperative days with a mean of 4.06 ± 1.98 days in Group

A and 2.75 ± 0.96 days in Group B. All patients started oral feeding between the 5th and 15th postoperative days according to the restoration of intestinal motility with a mean of 9.38 ± 3.40 days in Group A and 6.50 ± 1.29 days in Group B.

The duration of hospital stay ranged between 7 to 12 days. Only 3 stayed for a longer duration reaching about 28 days as they had severe postoperative chest infection requiring mechanical ventilation.

Early postoperative complications:

As seen in (Table 2), postoperative chest infection including pneumonia and bronchopneumonia developed in 7 patients (35%); 6 patients in Group A and one patient in Group B. Four patients had a mild presentation and were managed by I.V. antibiotics and proper chest care and the other 3 patients had severe respiratory distress and were mechanically ventilated with gradual improvement in two patients who were discharged safely and the

remaining patient deteriorated and died from severe infection and sepsis.

Pneumothorax was diagnosed in 3 patients (15%), this developed after esophagectomy in one patient and during creation of retrosternal tunnel in the remaining 2 patients. Pneumothorax was diagnosed intraoperative in 2 patients and on the 1st postoperative day in the other patient after performing X- ray chest due to respiratory stress. All patients were managed by chest tube successfully.

Abdominal wound complications developed in 4 patients (20%); all of them belonging to Group A. Mild wound infection improved gradually with repeated wound dressing in 3 patients. However, the remaining patient progressed to wound dehiscence with a burst abdomen on the 7th postoperative day; closure was done using tension suture under general anesthesia. No patient developed an incisional hernia.

Table 2. Comparison between the two studied groups according to the early postoperative complications

Variables	Total (n = 20)		Group A (n = 16)		Group B (n = 4)	
	No.	%	No.	%	No.	%
Abdominal wound complication	4	20.0	4	25.0	0	0.0
Chest infection	7	35.0	6	37.5	1	25.0
Mechanical ventilation	3	15.0	2	12.5	1	25.0
Cervical wound leakage	8	40.0	6	37.5	2	50.0
Pneumothorax	3	15.0	2	12.5	1	25.0
Bleeding	0	0	0	0	0	0
Graft necrosis	0	0	0	0	0	0
Leakage (thorax or abdomen)	1	5	1	6.25	0	0

Group A = patients with esophageal atresia and group B = patients with post-corrosive esophageal stricture

Major cervical anastomotic leakage was documented in one patient who was managed by side esophagostomy on the 6th postoperative day with redo anastomosis after 3 months. In contrast; a minor leakage creating a cervical fistula developed in 8

patients (40%); six patients were in Group A and two patients in Group B. Fortunately, all cervical fistulas healed spontaneously from 8 days to one month postoperatively with conservative treatment. (Fig. 10)

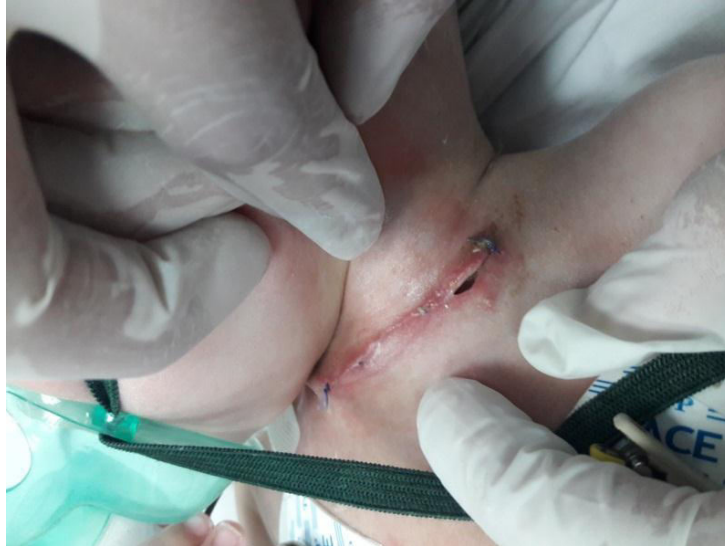

Fig. 10. Early cervical fistula following gastric tube esophagoplasty.

Careful dissection with the avoidance of any tube twist resulted in the absence of any single case of bleeding or graft necrosis.

Unfortunately, we had one mortality case belonging to Group A (5%) due to severe bronchopneumonia and sepsis.

Late postoperative complications: As seen in (Table 3), regarding the late postoperative complications; anastomotic stricture with dysphagia to a solid diet developed in 5 patients (25%), four of them belonged to Group A, and one case belonged to Group B. All of such

patients responded well to regular esophageal dilatations. Two patients showed rapid improvement after 1-2 sessions, 2 patients needed 2-4 sessions and the last patient did not improve except with more than 4 sessions.

Reflux was detected in 3 cases (15%); two cases in Group A and one case in Group B; all of them were diagnosed by the follow-up barium study. Two patients showed mild degrees and one patient showed moderate degree. All patients improved on medical management including semisolid food, PPI, and semi-sitting position. (Fig. 11).

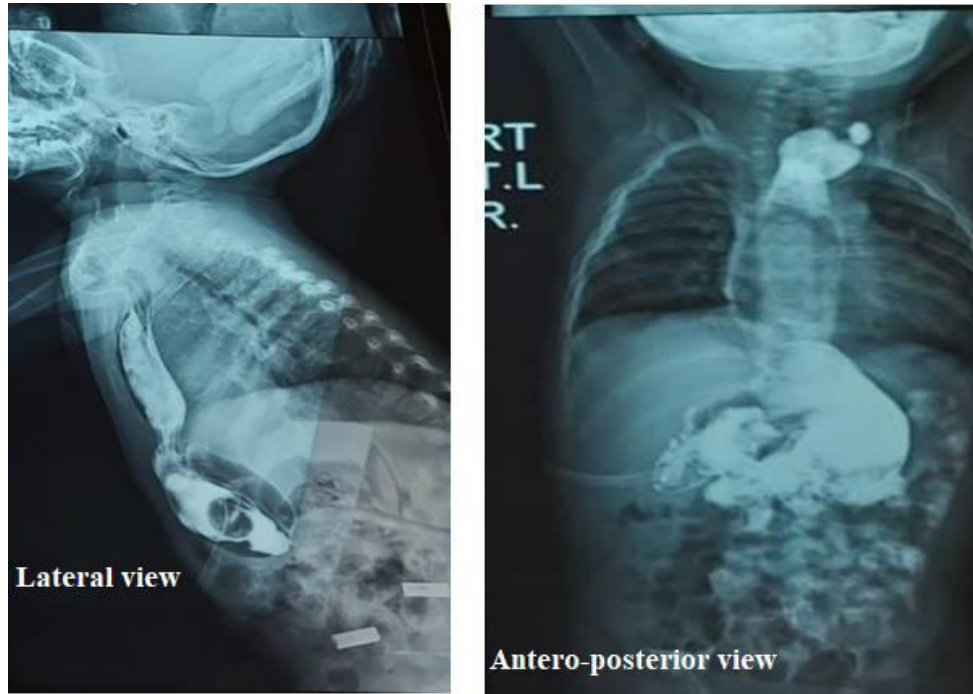


Fig.11. Postoperative Barium study showing reflux

Table 3. Comparison between the two studied groups according to the late postoperative complications

	Total (n = 20)		Group A (n = 16)		Group B (n = 4)	
	No.	%	No.	%	No.	%
Stricture	5	25.0	4	25.0	1	25.0
Reflux	3	15.0	2	12.5	1	25.0
Redundancy	1	5.0	0	0.0	1	25.0
Adhesive I.O.	0	0	0	0	0	0
Cervical swelling	4	20.0	3	18.8	1	25.0

Group A = patients with esophageal atresia and group B = patients with post-corrosive esophageal stricture

Graft redundancy was found in one patient in Group B. This patient presented on the 3rd postoperative month by nocturnal regurgitation. The baby

improved by stopping oral feeding 2 hours before sleeping and elevation the bed to semi sitting position. (Fig. 12)

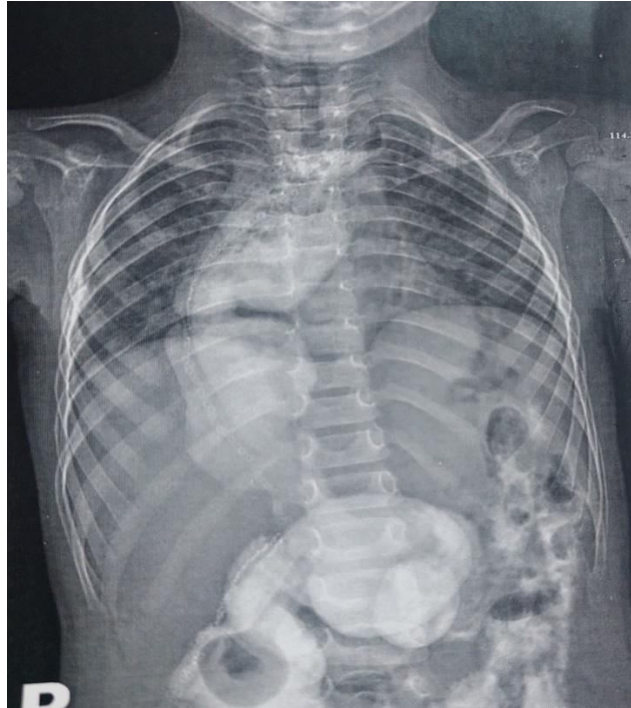

Fig.12: Postoperative Barium Study Showing Tube Redundancy

Evident cervical swelling was noticed during crying or coughing in 4 patients (20%); 3 of them were in Group A and one patient was in Group B. The cause was most probably due to improper healing of the sternomastoid muscle, however, all patients improved spontaneously over time.

Mechanical intestinal obstruction due to intestinal adhesions never happened in our cases.

The gastrostomy tube was clamped and removed after 3 postoperative months for spontaneous closure in 17 patients (85%). On the other hand, it was surgically closed in 3 patients; 2 from Group A and one patient from Group B who complained of severe dysphagia due to anastomotic stricture that required repeated esophageal dilatations followed by its closure.

Discussion

In the present study, we suggested to use of the gastric tube as an alternative to the more popularly used colon interposition procedure. This procedure provides better healing power of the anastomosis, wide anastomotic stoma in the neck, and simple surgical steps as it involves only one cervical anastomosis. The blood supply of the stomach is better than the colon which reduces the risk of complications resulting from ischemic necrosis. The gastric tube mucosa is also resistant to acid secretion especially with the absence of a cardia in those patients, thus resulting in a better conduit than the colon. Also, the gastric tube does not require prior GI preparation compared to colon bypass, which requires both chemical and mechanical preparation. In the long-term, the gastric tube does not

undergo redundancy as colonic tissue and thus avoids all associated symptoms. (Elfiky et al.,2017)

There is a general agreement that nine months is enough to replace the esophagus when the child has attained the upright position & and can sustain major surgery. (Richard et al., 2005; Holland and Fitzgerald,2010) But the weight of the child should not be less than 10 kg. (Pietro Bagolan and Andrea Conforti,2017)

All of our patients were operated on by the same surgical team performing retrosternal isoperistaltic gastric tube esophageal replacement in comparison to (Elfiky et al.,2017) study in which the isoperistaltic gastric tube was used in (90%) of their patients while the reversed gastric tube was used in the remaining (10%) of patients. The retrosternal route was used in (76%) of their studied patients, while the transhiatal route was used in the remaining (24%) of patients.

Several studies support the construction of a cervical esophagostomy with a feeding gastrostomy in case of failed primary repair in EA (Al-Salem et al.,2006 ; Steven et al.,2013). All of our patients who were enrolled in this study with EA had a cervical esophagostomy with feeding gastrostomy after failed primary repair.

Half of the patients (50%) who were enrolled in our study due to PCES had a pre-operative feeding gastrostomy in comparison to 60.8% reported in (Elfiky et al.,2017) As for the operative duration, it is significantly shorter in patients with GTE (60-90 min in our study) than in those with other replacement options (165–210 min). (Amel Hashish et al.,2003) The shorter operative duration in the GTE could be

attributed to many factors including the utilization of the stapler in the neo-tube formation, the total abdominal approach without the need for thoracotomy, and the presence of a single cervical anastomosis. Also, the retrosternal route dissection consumes a shorter operative duration as mentioned by (Elfiky et al.,2017). There was no evidence of intraoperative bleeding complications in our patients as also recorded by (Elfiky et al.,2017)

Pyloroplasty was not needed in our cases contrary to Borgnon et al. (Borgnon et al.,2004) who performed pyloroplasty in some cases and. (Youn et al.,2018; Milickovic et al.,2016) who performed pyloroplasty in all of their studied patients.

During the early postoperative period, Chest infection developed in our study in 7 patients (35%) similar to the findings of (Elfiky et al.,2017) in his series in which chest infection developed in 34% of patients. A lower incidence was reported in a series conducted by (Huh et al.,2014) who documented chest infection in 14.3% of their studied patients. Pneumothorax occurred in 3 of our studied patients (15%) as compared to 12% in (Elfiky et al.,2017)series and 33% in.(Hunter et al.,2009)

Children are particularly susceptible to infection because of the immaturity of the immune system and because of depleted nutritional status. The magnitude of the operative procedure for esophageal replacement produces an extreme catabolic state, which readily exhausts the energy reserves of a marginally nourished patient. Therefore, the major infections following esophageal replacement are pneumonia and sepsis. (Elfiky et al.,2017)

Bleeding and graft necrosis were not encountered in our study is similar to the findings of (Elfiky et al.,2017). We believe that great care of the vascular supply, testing the vascular perfusion of the conduit, especially the proximal part, avoiding twisting of the graft and fine handling and positioning of the graft are important factors that led to the absence of graft necrosis in our series.

One patient (5%) developed major anastomotic leakage which was managed with cervical side esophagostomy on the 6th postoperative day and redo cervical anastomosis

3 months later. In contrast to (Elfiky et al.,2017; McCollum et al.,2003; Hunter et al.,2009) who did not describe any thoracic or abdominal leakage in their series.

Minor cervical leakage creating a fistula was noticed in our study in 8 patients (40%); this is nearly similar to the results of (Elfiky et al.,2017). (44%) and higher than the results (Borgnon et al.,2004). (9.5%). and (Zarfati et al.,2023) (20%) . However, a lesser incidence was reported by (Milickovic et al.,2016). (52%) and (Choudhury et al.,2016) (60%). Fortunately, all cervical fistulas heal spontaneously from 8 days to one month with conservative treatment.

(Zhang, et al.,1994) claimed that esophagogastric leak was a result of insufficient venous drainage of the upper part of the fundus due to interruption of the left gastroepiploic vein in the absence of the gastroepiploic arch. Fortunately, all cervical fistulas heal spontaneously from 8 days to one month with conservative treatment (stopping oral feeding while continuing enteral feeding through the gastrostomy and improvement of the

general condition with correction of anemia and hypoalbuminemia that may occur postoperatively).

Unfortunately, we had one case of mortality (5%) due to severe bronchopneumonia and sepsis compared to (8% , 4.08%, and 5.7%) being reported by other series. (Elfiky et al.,2017; Milickovic et al.,2016; Tannuri et al.,2008)

Successful functional outcome of GTE is usually assessed by the ability to swallow a normal diet. Post-GTE swallowing problems could be attributed to the axial torsion of the tube, excessive tube angulation, poor peristalsis, cervical anastomotic stenosis, a lack of swallowing training, and problems with coordination at the cervical and pharyngeal levels of the esophagus. (Schettini and Pinus.,1998)

We reported 5 cases (25%) with minor postoperative cervical anastomotic leakage followed by stricture. This incidence was lower than the incidence in some series as in (Hunter et al.,2009; Tannuri et al.,2008) studies who reported an incidence of 33% to 38% of cervical anastomotic stricture. Also, (Milickovic et al.,2016) reported a higher incidence of cervical stricture 47.8% and some cases required dilatations up to 5 years and (Choudhury et al.,2016) reported a 60% incidence of cervical leak and 80% of stricture and 100% of prolonged feeding difficulty. On the other hand, a lower incidence of stricture (20%) was documented by (Youn et al.,2018; Zarfati et al.,2023); all of them improved with balloon dilatation.

The lower incidence of stricture in some series could be attributed to the adequate blood flow which should be tested repeatedly during the operation, low anastomotic tension, and wide

anastomotic caliber. Additionally, preoperative correction of anemia and/or hypoalbuminemia, proper construction of a wide thoracic inlet to prevent obstruction of the venous drainage and meticulous anastomotic technique (Elfiky et al.,2017)

Reflux was reported in our study in 3 cases (15%) as confirmed by a postoperative barium study. Other series reported a higher incidence as (Elfiky et al.,2017) was about (24%), (Youn et al.,2018) was about (20%) (Lee et al.,2014 ; Huh et al.,2014). who reported an incidence of 90.9%. (Milickovic et al.,2016) reported a lower incidence (10.8%) of the development of post-GTE dysphagia and reflux. (Schettini and Pinus.,1998) reported that the main factors that cause reflux in GTE are the exaggerated size of the gastric tube, the long tube reaching the pylorus, and the small gastric remnant as a consequence of the first two factors.

We reported one case of postoperative tube redundancy (5%) who complained of nocturnal regurgitation on the 3rd postoperative month. (Elfiky et al.,2017) reported a 4 % incidence of the same condition in his series. According to (Borgnon et al.,2004) the shape and diameter of the gastric tube in GTE are considerably similar to the original esophagus reducing the incidence of postoperative redundancy lower than any other conduit.

Mechanical intestinal obstruction & and Horner's syndrome did not happen in our series. According to.(Elfiky et al.,2017) adhesive intestinal obstruction occurred in 2 patients (4%); this developed in one of them 6 months postoperatively and it was managed conservatively. The other developed adhesive intestinal

obstruction 14 months postoperatively and was managed by exploratory laparotomy and adhesiolysis.

Longer periods of follow-up with regular endoscopic examination of the neo-esophagus are recommended to identify long-term consequences, particularly the relation between reflux and Barrett's esophagus. According to (Zarfati et al.,2023) after a 2-year follow-up, no patient developed signs of metaplasia, dysplasia, or Barrett's esophagus. (Borgnon et al.,2004) conducted their study on 21 patients with acid secretion of the gastric tube being proved in nine cases. Two patients were shown to have cervical Barrett's esophagus above the anastomosis. These findings indicate the need for lifelong endoscopic follow-up for these patients.

Conclusion

Esophageal replacement is a surgical challenge and a technically demanding operation due to the lack of an ideal conduit. In experienced hands, the rate of complications in gastric tube esophagoplasty is minimal. Cervical fistula appeared to be a significantly higher complication in gastric tube, however, most of them healed spontaneously without surgical intervention. Cervical stricture is a common complication after gastric tube. However, most respond well to esophageal dilatations. The pediatric surgeon needs to be aware of the various options available for replacement to deal with different accidental surgical challenges that may appear during surgery.

Recommendations

The study needs to be powered by including a large number of cases and the involvement of more centers in the future. Longer follow-up is recommended to detect long-term complications, especially the relation between reflux and Barrett's esophagus. Assessment of the quality of life from the children's point of view should be addressed and targeted in future studies.

List of abbreviations

EA: Long-gap esophageal atresia

PCES: Post-corrosive esophageal stricture

GTE: Gastric tube esophagoplasty

IQR: Interquartile range

ICU: Intensive care unit

PPI: Proton pump inhibitors

IV: Intravenous

Kg: Kilogram

N: Number

Min: Minimum

Max: Maximum

SD: Standard deviation

IO: Intestinal obstruction

GIA stapler: Gastrointestinal anastomosis stapler

Declarations:

Ethics approval and consent to participate:

Parents of all of the studied patients have signed an informed consent and the ethical committee of the Faculty of Medicine, Alexandria University has revised and approved our study (0305079- 19 Mars 2021).

The corresponding author as well as the co-authors confirm that all methods were performed by the ethical standards as laid down in the Declaration of Helsinki and its later amendments or comparable ethical standards

Competing interests: The authors declare that they have no competing interests

Funding: This study did not receive any fund

Authors' contributions: AK designed the work and performed the operation, YS revised the collected data, KB. collected and analyzed the data, AE. drafted and revised the manuscript. All authors have written and approved the manuscript and agreed to be personally accountable for their contributions and have ensured that questions related to the accuracy or integrity of any part of the work, even ones in which they were not personally involved, were appropriately investigated, resolved, and the resolution documented in the literature. AE; The corresponding author verified that all of the contributing authors have approved the manuscript before submission and that all the names and order of them were correct. He also complied with the transparency and reproducibility standards of both the field and journal by ensuring that all authors receive the submission and all substantive correspondence with editors, as well as the full reviews, verifying that all data, figures, materials (including reagents), and code, even those developed or provided by other authors.

Acknowledgments: No other person contributed to our study to acknowledge.

References

- **Spitz L, Kiely E, Pierro A. (2004).** Gastric transposition in children—a 21-year experience. *J Pediatr Surg*, 39(3):276–81.
- **Hamza AF, Abdelhay S, Sherif H, Hasan T, Soliman H, Kabesh A, et al. (2003).** Caustic esophageal strictures in children: 30 years experience. *J Pediatr*

- Surg,38(6):828–33.
- **Lee HQ, Doak J, Hawley A, Hutson JM, Nightingale MG. (2014).** Long-gap oesophageal atresia: comparison of delayed primary anastomosis and oesophageal replacement with gastric tube. *J Pediatr Surg*, 49(12):1762–6.
 - **Chirica M, Brette M-D, Faron M, Halimi B , Laborde C, Munoz Bongrand N et al. (2015).** Upper Digestive Tract Reconstruction for Caustic Injuries. *Ann Surg*, 261(5):894–901.
 - **Pearson EG, Barnhart DC, Black RE,Downey EC, Scaife ER, Rollins MD et al. (2010).** Reflux esophageal stricture—a review of 30 years’ experience in children. *J Pediatr Surg*, 45(12):2356–60.
 - **Richard G. Azizkhan. (2005).** Esophageal replacement. In: Moritz M. Ziegler, MD, Richard G. Azizkhan, MD, PhD (Hon), Daniel von Allmen, MD, Thomas R. Weber M, editor. *Operative Pediatric Surgery*. Second. New York: McGraw Hill;. p. 395–405.
 - **Krishnan U. (2019).** Eosinophilic Esophagitis in Esophageal Atresia. *Front Pediatr* Nov 29;7.
 - **Lobeck IN, von Allmen D. (2017).** Esophageal Injuries and Replacement. In: Peter Mattei, Peter F. Nichol, Michael D. Rollins, II CSM, editor. *Fundamentals of Pediatric Surgery [Internet]*. Second Edi. Cham: Springer International Publishing;. p. 291–9.
 - **Havanond C. (2003).** Clinical features of corrosive ingestion. *J Med Assoc Thai* ,86(10):918–24.
 - **Spitz L. (2011).**Esophageal Replacement. In: *Fundamentals of Pediatric Surgery* . New York, NY: Springer New York; p. 247–52.
 - **Sharma S, Gupta DK. (2017).** Surgical techniques for esophageal replacement in children. *Pediatr Surg Int*, 6;33(5):527–50.
 - **Lewis Spitz and Arnold G. Coran. (2012).** ESOPHAGEAL REPLACEMENT. In: Arnold G. Coran, Anthony Caldamone, N. Scott Adzick, Thomas M. Krummel, Jean-Martin Laberge and RS, editor. *Pediatric Surgery*. 7th ed. Philadelphia: Elsevier;. p. 927–38.
 - **Arul G, Parikh D. Oesophageal Replacement in Children. (2008) .** *Ann R Coll Surg Engl* ,90(1):7–12.
 - **Elfiky MMA, Abdel Azim O, Elfiky MA , El Tagy G, Mohamed W. (2017) .** Gastric tube esophagoplasty for pediatric esophageal replacement. *J Pediatr Surg* ,52(4):657–62.
 - **Holland AJA, Fitzgerald DA. (2010) .** Oesophageal atresia and tracheo-oesophageal fistula: current management strategies and complications. *Paediatr Respir Rev* ,11(2):100–7.
 - **Pietro Bagolan, Andrea Conforti FM. (2017).** Long-Gap Esophageal Atresia. In: Mattei, P., Nichol, P., Rollins, II, M., Muratore C, editor. *Fundamentals of Pediatric Surgery*. New York: Springer, Cham;. p. 269–81.
 - **Al-Salem AH, Alsenan K, Khogair S, Tayeb M, Roy A, Al-Jishi N, et al. (2006).** Esophageal atresia with or without tracheoesophageal fistula: success and failure in 94 cases. *Ann Saudi Med*,26(2):116–9.
 - **Steven W. Bruch AGC& SMK. (2013).** Esophageal Atresia and Tracheoesophageal Fistula. In: Mario

- Lima, editor. Pediatric thoracic surgery. Italy: Springer;. p. 93–110.
- **Amel Hashish, Essam Elhalaby, Hassan Abd Elaty AT , Khalid Ismail, Mohamed F Metwally. (2003).** Gastric pull-up versus colon interposition in treatment of corrosive esophageal stricture. Egypt J Surg, 22(3):283–8.
 - **Borgnon J, Auber F, Boeris Clemen F, Girardet JP, Larroquet M, Tounian P et al. (2004) .** Esophageal replacement in children by an isoperistaltic gastric tube: a 12-year experience. Pediatr Surg Int , 9;20(11–12):829–33.
 - **Youn JK, Han J-W, Jang H-J, Kim S-H, Oh C, Park T et al. (2018).** Prospective evaluation of clinical outcomes and quality of life after gastric tube interposition as esophageal reconstruction in children. Medicine (Baltimore) , 97(52):e13801.
 - **Milickovic M, Grujic B, Savic D, Stajevic M, Vlahovic A, Vukadin M, et al. (2016).** Gastric tube esophageal reconstruction in children with esophageal atresia and caustic stricture Study of clinical value based on 25 single-center. Centre experience. Ann Ital Chir , 87:589–94.
 - **Huh Y-J, Jung S-E, Kim H-Y, Lee S-C, Park K-W. (2014).** Comparison of outcomes according to the operation for type A esophageal atresia. Ann Surg Treat Res ,86(2):83.
 - **Hunter CJ, Connelly ME, Petrosyan M, Ford HR, Nguyen NX. (2009) .** Repair of long-gap esophageal atresia: gastric conduits may improve outcome—a 20-year single center experience. Pediatr Surg Int , 26;25(12):1087–91.
 - **McCollum M., Blair G., Moss R., Smith B., Skarsgard E , Rangel S. (2003) .**Primary reversed gastric tube reconstruction in long gap esophageal atresia. J Pediatr Surg , 38(6):957–62.
 - **Zarfati A, Bagolan P, Conforti A , Tambucci R. (2023).** Isoperistaltic gastric tube for long gap esophageal atresia (LGEA) in newborn, infants, and toddlers: a case-control study from a tertiary center. Front Pediatr [Internet], 16;11.
 - **Choudhury S, Debnath P, Khan N, Kumar V, Shah S, Yadav P. et al. (2016).** Pediatric esophageal substitution by gastric pull-up and gastric tube. J Indian Assoc Pediatr Surg, 21(3):110.
 - **Zhang J, Rath A, Chevrel J. (1994).** Anatomic basis of venous drainage in gastric tubular esophagoplasty. Surg Radiol Anat [Internet],16(3):221–8.
 - **Tannuri U, Cardoso SR, Gonçalves MEP, Tannuri ACA., (2008) .**Total gastric transposition is better than partial gastric tube esophagoplasty for esophageal replacement in children. Dis Esophagus [Internet], 1;21(1):73–7.
 - **Schettini ST, Pinus J. (1998).** Gastric-tube esophagoplasty in children. Pediatr Surg Int , 24;14(1–2):144–50. Available from: <http://link.springer.com/10.1007/s003830050466>