

ASDJ

AINSHAMS DENTAL
JOURNAL

Print ISSN 1110-7642

Online ISSN 2735-5039

AIN SHAMS DENTAL JOURNAL

Official Publication of Ain Shams Dental School

December 2023 • Vol. 32

Evaluation of Nasolabial Angle Changes after Dermal Fillers Injection of Skeletal Class III Orthodontically Treated Females

Ghada Youssry El Saeed¹, Islam Tarek Abbas², Noha Ezzat Sabet³, Ibrahim Mazen Negm⁴

Aim: The aim of this study is to assess the changes in the nasolabial angle following upper lip augmentation after orthodontic treatment completion in females with skeletal class III.

Methods and Materials: This prospective study was performed on 15 patients all had non-surgical upper lip augmentation using Hyaluronic Acid dermal filler injections (Restylane® Defyne) following camouflage orthodontic treatment. Nasolabial angle changes were assessed using lateral cephalometric x-ray analysis for all patients before and after upper lip augmentation.

Results: Following upper lip augmentation nasolabial angle showed a decrease in measurement at T1 by 4.88 ± 1.74 with overall mean value of 96.38 ± 12.63 degrees. There was a statistically significant change following lip augmentation (P-value < 0.001 , Effect size = 0.764) directly affecting the nasolabial angle.

Conclusion: The hyaluronic filler used in this study is well tolerated, efficient and safe. The nasolabial angle is directly affected by the soft tissue thickness of the maxillary lip as the lip augmentation put the nasolabial angle in the ideal zone.

Keywords: Class III, digital cephalometric analysis, hyaluronic acid, nasolabial angle.

1. Teaching assistant at Orthodontic Department, Faculty of Dentistry, British University in Egypt.
2. Professor of Orthodontics, Head of the Orthodontic Department, Faculty of Dentistry, Ain Shams University.
3. Professor of Orthodontics, Faculty of Dentistry, Ain Shams University.
4. Professor of Orthodontics, Faculty of Dentistry, Ain Shams University.

Corresponding author: Ghada Youssry El Saeed, email: Ghada.elsaeed@buc.edu.eg

Introduction

People seek orthodontic treatment to correct any soft tissue deficiencies; not only for correcting skeletal and/or dental defects. Correcting these problems in terms of "orthodontic principles" is not quite enough for many patients nowadays. They search for a healthy attractive smile, as well as soft tissue profile balance and harmony.

Skeletal class 3 patients are usually presented with retrusive facial profile, deficient nasomaxillary area and upper lip position with/without protrusive lower face. These patients usually give greater concern to the profile rather than the occlusion which is frequently one of the orthodontist's most difficult challenges. Thus, correct upper lip position after treatment completion is an important factor that should be put in consideration. [1]

The nose-lip relationship is a crucial determinant of facial aesthetics and soft tissue profile. This relation is defined by the nasolabial angle that is the angle formed by the two lines passing through the lower edge of the nose (the columella) and the edge of the upper lip. This angle should range from 95 to 110 degrees in adult women. [2]

The upper lip can be divided anatomically into skin and mucosa. The skin begins from the subnasale till the vermilion border and further inferiorly to the mucosa. Numerous alternatives with different techniques are used for lip augmentation depending on the severity and needs of each case individually. [3]

Correction of lip position can take place by more than one option using the surgical approach which was the most commonly used before the injections era which took place widely in the last two decades. Beginning with collagen fibers injections followed by autologous fats then Hyaluronic acid fillers injections that were widely spread during the last few years. [4]

The aim of this study is to assess the changes in the nasolabial angle following upper lip augmentation after orthodontic treatment completion in females with skeletal class III.

Material and Methods

This study is an intervention clinical trial. Evaluating the effect of using dermal fillers for upper lip augmentation.

This clinical study took place in the outpatient clinic of the Orthodontic Department and the Oral and Maxillofacial Surgery Department, Faculty of Dentistry, Ain Shams University. The subjects presenting to the clinic were assessed for eligibility according to the following selection criteria. All subjects were from the Egyptian population and were living in Cairo during the study.

Inclusion criteria

- Patients with skeletal class III pattern, having mild to moderate maxillary deficiency treated with orthodontic camouflage treatment modality.
- Patients with mild to moderate soft-tissue profile deficiency at the upper lip and/or mid face area.

Exclusion criteria

- Skeletal class III patients with severe upper lip deficiency.
- Skeletal class III patients with normal lip position and protruded mandible.
- Pregnant or lactating patients.
- Patients with craniofacial anomalies.
- Patients with severe allergies showed a history of anaphylaxis or known presence of multiple allergies.
- Immune-compromised patients.

Sample size calculation

The sample size calculation was based on an interventional study held by **Suber et al** [5], evaluating the effect of using injectables (Botulinum-A Toxin) on smile mainly regarding the maxillary incisal display using static photographs. The mean of the incisal display before injection was 5.214 ± 1.18 mm

and post injection it became 0.857 ± 1.561 mm. One sample *t-test* of two dependent means (matched pairs) at a conventional alpha-level ($p=0.5$) with desired power of 95% was done. The calculations were performed with the computer application G*power, which is based on the formulas of Cohen.

The test resulted in a total number of 4 participants. However, a total sample size of 15 participants was advocated to further increase the power of the study and to compensate for possible dropouts during follow up phases. Patient's Informed Consent All procedures were properly explained and detailed to the participants including all possible risks of soft tissue injection, risks pertaining to radiation exposure and an informed consent was obtained prior to the study.

The ethics committee at the Faculty of Dentistry, Ain Shams University approved the study after reviewing the study protocol (Research ethics approval no: FDASU-REC ID 101405).

Methods:

All participants underwent the same procedures by the same principal investigator of the study, the following is a detailed description of the whole process.

A detailed medical history was obtained via questionnaire and interview with discussing in detail to the patients all steps and their role in the research.

Data was Collected at 2 intervals of time from lateral cephalograms.

- Before upper lip augmentation procedure. (T0)
- At 15-21 days after augmentation. (T1)

Lip Augmentation Procedure took place using Restylane® Defyne is produced by Galderma, as a sterile, biodegradable, viscoelastic, non-pyrogenic, clear, colourless and homogenous, soft cross-linked hyaluronic acid gel. Galderma uses a unique

manufacturing process called XpresHAN Technology™, globally referred to as the OBT technology (Optimal Balance Technology). This technology creates a smooth and injectable gel that gives a natural appearance once injected.

For the upper lip, filler should be applied at or just inferior to the vermilion-cutaneous junction at a superficial depth to avoid vital structures injury. Extra care during injection is a must to avoid any injury to blood vessels (Fig. 1). [6]

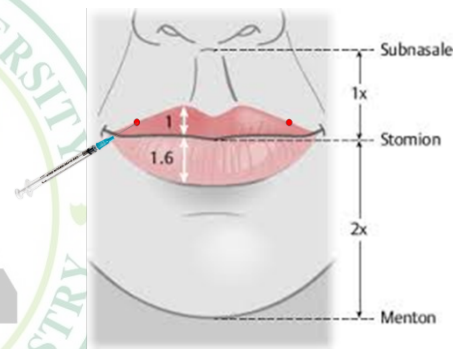


Fig. 1: Point of entry for lip injection.

A lateral Cephalometric radiograph was taken twice for each patient once after orthodontic treatment completion before lip augmentation while the second was taken 15-21 days after augmentation. All in natural head position so that the mid-sagittal plane was perpendicular to the floor using a PlanMeca machine, with facial muscles relaxed. Then the radiographs were uploaded to Dolphin® Imaging software.

A customized cephalometric analysis with of evaluation the upper lip to E-line and nasolabial angle were all measured to assess the soft tissue profile changes.

Declaration of interests

No financial competing interests. This study was part of a PhD degree in Orthodontics, Faculty of Dentistry, Ain-Shams University.

No financial conflicts of interests were declared. This study was self-funded by the principal investigator.

Statistics

Numerical data were explored for normality by checking the distribution of data and using tests of normality (Kolmogorov-Smirnov and Shapiro-Wilk tests). All data showed normal (parametric). Numerical data were presented as mean and standard deviation (SD) values. For parametric data, repeated measures ANOVA test was used to study the changes by time. Bonferroni's post-hoc test was used for pair-wise comparisons when ANOVA test is significant. For non-parametric data: Friedman's test was used to study the changes by time. Dunn's test was used for pair-wise comparisons when Friedman's test is significant. Inter-examiner agreement was assessed using Cronbach's alpha reliability coefficient and Intra-Class Correlation Coefficient (ICC). Closer coefficient values to one indicate better agreement. Qualitative data were presented as frequencies and percentages. The significance level was set at $P \leq 0.05$. Statistical analysis was performed with IBM SPSS Statistics for Windows, Version 23.0. Armonk, NY: IBM Corp.

Results

Data were collected and tabulated at the 2 different time intervals (table 1 and table 2)

Table (1): Mean±SD for nasolabial angle at different follow-up periods.

Table (1): Mean±SD for nasolabial angle at different follow-up periods.			
	T0	T1	T0-T1
Nasolabial angle	101.26±14.36	96.37±12.63	4.88±2.34

Table (2): P-value for the comparison of nasolabial angle at different follow-up periods.

Table (2): P-value for the comparison of nasolabial angle at different follow-up periods.	
T0-T1	
	<0.001*

Displaying that following upper lip augmentation nasolabial angle showed a

decrease in measurement at T1 by 4.88 ± 1.74 with overall mean value of 96.38 ± 12.63 degrees. There was a statistically significant change following lip augmentation (P -value < 0.001 , Effect size = 0.764) directly affecting the nasolabial angle

T0 displayed the significantly higher mean value than T1 showed significantly lower mean values.

Discussion

Dealing with orthodontic dentistry, signifies harmony between the teeth, and soft tissue esthetics [7]. In the last few years, using injectables showed a massive increase, such as botulinum toxin type A and dermal fillers [8]. Lips augmentation with hyaluronic acid fillers recently became an approach of high demand in soft tissue correction, following multiple dental procedures to reach ideal soft tissue balance in conjunction with ideal occlusion [9]. The nasolabial region is composed of two vital elements, the nose and upper lip. The nasolabial angle is a parameter of prime importance in determining the aesthetic of this region [10]. It was described by Burstone as the horizontal indicator of the upper lip position. While, according to Sarver and Jacobson [11] the nasolabial angle is directly affected by the soft tissue thickness of the maxillary lip.

All patients in this study finished their orthodontic treatment for dento-alveolar malocclusion correction. After treatment completion routine lateral cephalometric radiograph was made showing their mid face retrusive soft tissue profiles. Then dermal filler using hyaluronic acid was used for upper lip augmentation.

The average amount of filler delivered to the upper lip was 0.9 ml with injection points were 0.5 cm away from the corners of each lip. Though Alshehri et al [12]. as well as Al-Nerabieah et al. [13] used not more than 0.5 ml while assessing smiles, but their sample was on skeletal class 1

patients. 2D lateral cephalometric radiograph using a customized analysis was used to evaluate and observe nasolabial angle response to upper lip augmentation with hyaluronic acid dermal fillers. The customized analysis included evaluation of nasolabial angle and the upper lip position to E-plane. [14]

Following upper lip augmentation nasolabial angle showed a decrease in measurement at T1 by 4.88 ± 1.74 with overall mean value of 96.38 ± 12.63 degrees. According to Armijo et al. [15], it was found that the ideal nasolabial angle would be 95.5 to 100.1 degrees for women. Thus, lip augmentation put the nasolabial angle in the ideal zone.

This goes in accordance with Droubi et al. [16] that showed decrease in the mean of the nasolabial angle of the subjects after lip augmentation going from 108.80 degrees to 105.80 degrees. This indicates that the injection of the lips using hyaluronic acid led to a decrease in nasolabial angle by an average of 3 degrees that was clinically and statistically significant with increased patient satisfaction.

Conclusion

As per the results obtained from this study, it can be concluded that the usage of hyaluronic acid fillers dermal injections for upper lip augmentation was a safe and reliable procedure, improving the nasolabial angle, thus, the position of the upper lip.

References

[1] Eslami S, Faber J, Fateh A, Sheikholamemeh F, Grassia V et al. (2018) Treatment decision in adult patients with class III malocclusion: surgery versus orthodontics. *Prog Orthod* 19: 28.
 [2] Fitzgerald JP, Nanda RS, Currier GF. An evaluation of the nasolabial angle and the relative inclinations of the nose and upper lip. *AM J ORTHOD DENTOFAC*. 1992 Oct 1;102(4):328-34.
 [3] Votto SS, Read-Fuller A & Reddy L. Lip Augmentation. *Oral and Maxillofacial Surgery Clinics of North America* 2021; 33: 185–195.

[4] Guyuron B & Majzoub RK. Facial augmentation with core fat graft: a preliminary report. *Plast Reconstr Surg* 2007; 120: 295–302.
 [5] Suber JS, Dinh TP, Prince MD & Smith PD. OnabotulinumtoxinA for the treatment of a “gummy smile.” *Aesthetic Surgery Journal* 2014; 34: 432–437.
 [6] Gnanashanmugam SD & Ashok D. *European Journal of Molecular & Clinical Medicine Dermal Fillers in Orthodontics*; 7(4):2020.
 [7] İlik E, Özden N, Özak ŞT. Esthetic crown lengthening for maxillary anterior teeth: an interdisciplinary case report. *CDJ*;17(2):175-8.
 [8] Hung CH, Min KH. Multi-modal treatment strategy for achieving an aesthetic lower face. *Arch Plast Surg*. 2020 May;47(3):256-262.
 [9] Stojanović L, Majdić N. Effectiveness and safety of hyaluronic acid fillers used to enhance overall lip fullness: A systematic review of clinical studies. *J Cosmet Dermatol*. 2019 Apr;18(2):436-443.
 [10] Mitchell C, Oeltjen J, Panthaki Z, Thaller SR. Nasolabial aesthetics. *J Craniofac Surg*. 2007 Jul 1;18(4):756-65
 [11] Jacobson A, Upadhyay M & Nanda R. A dynamic analysis of the display of the dentition during speech. *European Journal of Orthodontics* 2013; 35: 689–695.
 [12] Alshehri R. Esthetics of Lip Morphology Changes after Filler Injections: A Clinical Assessment. *Bioscience Biotechnology Research Communications* 2021; 14: 1160–1166.
 [13] Al-Nerabieah Z. Evaluation of the effect of using hyaluronic acid for lip enhancement on the amount of vertical tooth exposure in smiling. *Aesthetic Medicine* 2021; 7(2) : 20-26.
 [14] Holdaway RA. A soft-tissue cephalometric analysis and its use in orthodontic treatment planning. *Am J Orthod*. 1983; Part I.
 [15] Armijo BS, Brown M & Guyuron B. Defining the ideal nasolabial angle. *Plastic and Reconstructive Surgery* 2012; 129: 759–764.
 [16] Droubi M, Al-Moudallal Y, Mouhamad M & Al-Nerabieah Z. Changes in nasolabial angle and mentolabial angle after lips augmentation with hyaluronic acid: Clinical study. *International Journal of Dentistry and Oral Science* 2020; 7: 912–916.