

Effect of Laser Treatment of Implant Surface on Bone changes in Implant-Retained Over Denture

Mohamed Wahied Gharieb Ali¹, Yasmine Galal El-din Thabet², Ahmed Mohamed Osama³

Aim: The study was designed to evaluate the effect of laser surface treatment of implants on volumetric bone changes in implant retained overdentures through radiographic assessment over a period of one year post loading.

Materials and methods: Seven patients were selected from the out-patient clinic of the department of Oral and Maxillofacial prosthodontics, Faculty of Dentistry Ain Shams University where each patient received two implants in the intraforaminal region through guided surgery protocol. Each Patient received one laser-lok implant on one side of the mandible while the other side received an identical implant but with resorbable blast texturing surface treatment. Then each patient had a CBCT scan done at 0,6,12-month period following loading of the implants. The MIMCS software was then used to evaluate the volumetric bone changes in the peri-implant bone through the bone density readings. Statistical analysis was performed with paired t-test for intergroup comparisons and repeated measures ANOVA followed by Bonferroni post hoc test for intragroup comparisons.

Results: The bone volume around the laser-lok implants showed a statistically significant higher values (2776.57 ± 322.79) and lower percentage change rate (10.48 ± 8.04) than the resorbable blast texturing group (2398.04 ± 108.74) (19.37 ± 0.20).

Conclusion: The Laser-Lok implant increased the density of bone formed around the implant post-surgically and decreased the rate of volumetric bone loss around implant retained overdentures.

Keywords: Laser-Lok, implant, overdenture, bone volume, surface treatment

-
1. Master's Degree Student, Faculty of Dentistry, Ain Shams University
 2. Associate professor of Prosthodontics, Faculty of Dentistry, Ain Shams University.
 3. Professor and Chairman of Prosthodontics, Faculty of Dentistry, Ain Shams University
- Corresponding author: Mohamed Wahied Gharieb Ali, email: mohamedwahied192@yahoo.com

Introduction

Edentulism is considered a debilitating condition that is described as the “final marker of disease burden for oral health”⁽¹⁾ Even though the number of completely edentulous patients has declined over the last few years, edentulism remains a major disease worldwide with a survey from the World Health Organization showing as many as 78% of patients aged 65 years or older were edentulous.⁽²⁾

Rehabilitation with dental implants is a vastly successful therapeutic option for completely edentulous jaws, with predictable long-term success rates. Thus, a mandibular two-implant overdenture therapy has become the first-choice treatment option in the rehabilitation of completely edentulous patients.⁽³⁾

Due to the vast success of the implant supported overdentures, a global consensus has been reached that states that an implant supported overdenture should be the first choice of treatment and the minimum offered for an edentulous mandible. Both the McGill Consensus and, more recently, the York Consensus Statement supported that concept.⁽⁴⁾

The research in the field of implantology has been focused to design implant surface that bring about controlled and rapid osseointegration into the surrounding bony tissues.⁽⁵⁾ The surface topography of dental implants is crucial for the cellular interactions of osteoblasts during the early phase of osseointegration as well as the later bone remodeling. Imperfections along these surfaces enable the osteogenic cells to adhere and attach to the bone, thus creating a bone-to-implant interface.⁽⁶⁾

In recent decades, Nanotechnology has become widely popular in different scientific fields and It is the technology that engages with the application of materials and devices at the nanometer scale that is from 1 to 100 nm (one billionth of meter). In dental

implants, nano topography affects the interactions between the implant and surrounding tissues at both the cellular and protein level, allowing for an improved osseointegration. The nanoroughness of dental implants also provide a wider surface area, better cell attachment and enhanced biomechanical interface with bone.⁽⁷⁾

To enhance osseointegration, it has been proposed to modify implant surfaces using laser to create the optimal surface roughness. The laser used onto the implant creates a highly-pure surface, with a fair regularity and a nanostructured topography.⁽⁸⁾ With the application of laser processing, identical and constant morphologies could be manufactured, providing better cell adhesion and proliferation along surfaces.⁽⁹⁾

One of the methods of altering the Nano topography of an implant is the laser ablation technique (Laser-Lok, BioHorizons, Birmingham, AL, USA). During the process of laser ablation, the implant surface is modified using laser micromachining which produces both microscale patterns as well as nano-channels by controlling the laser beam parameters.⁽¹⁰⁻¹⁴⁾

Materials and Methods

A single-arm randomized clinical trial was carried out in the department of Oral and Maxillofacial prosthodontics, Faculty of Dentistry Ain Shams University to investigate the effect of placing an implant with a laser-Lok surface treatment on the volumetric bone changes occurring in the peri-implant bone after loading the prosthesis. This study was approved by the Ain Shams Faculty of Dentistry Ethical committee and conducted in accordance to the rules of human research of the Egyptian dental syndicate.

The sample size was determined using the online sample size calculator (ClinCalc.com) using an (alpha error) of 0.05% and power (beta error) of 90% with

average mean of 1.0 mm and an anticipated mean of 0.5 mm. Seven edentulous patients were selected from the out-patient clinic of Removable Prosthodontics Department, Faculty of Dentistry, Ain Shams University. All patients were assorted into the same group as a split-mouth investigation was carried out.

The eligibility criteria of this study included that patients were all males, 50-60 years old with enough inter arch space and bone volume to accommodate both the implants and the overdenture with its attachment. Patients with parafunctional habits, uncontrolled diabetes and heavy smokers were excluded from the study.

Each of the Seven patients received a mandibular implant-overdenture constructed on two implants placed in the canine region bilaterally. A Laser-lok (Biohorizons Implant Systems, Inc, Alabama, USA) implant was placed on one side and an identical implant but without the Laser-lok surface treatment on the other side thus allowing a split-mouth investigation to be carried out.

Each patient received a set of conventional dentures fabricated using the traditional method of complete denture construction. Each patient was then recalled for the construction of a completely limiting surgical guide to be used during the implant placement.

Six different holes were drilled into the dentures using round stones size 2 to accommodate the radiographic markers. Flowable composite (Meta Biomed Nexcomp Flow, South Korea) was then injected into the pre-drilled holes and cured using for 20 seconds.

Two CBCT scans were taken with the patient wearing the radiographically labelled denture and the other was a denture scan. The two obtained scans were then superimposed using the radiographic markers to produce a surgical guide by 3D

laser printing using the stereo lithography technique.

On the day of the surgery, two bilateral mental nerve block injections were then given to the patient along with bilateral Inferior alveolar nerve block. The guide was then properly seated and the patient was instructed to bite using the upper denture. While the guide was held in place by the patient's occlusion, three fixation pins were used to stabilize the guide. (Fig.1)

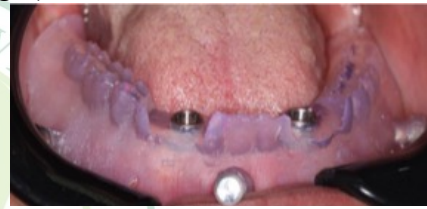

Figure 1 Surgical guide Fixed in place

First, a tissue punch was used to remove the oral mucosa covering the planned site of the implants through the sleeves of the guide. Sequential drilling protocol and the implants were then mounted on the surgical hand piece and the surgical motor was adjusted to the proper torque of 35 rpm. The implants were then placed until the implant platform was 1 mm below the marginal bone and both implants were placed at the same level. The surgical guide was then removed and a screwdriver was used to place the cover screw over each implant. (Fig.2&3)

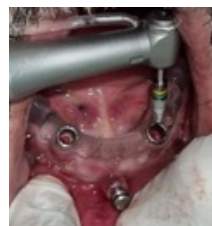

Figure 3 Placement of implant through the guide

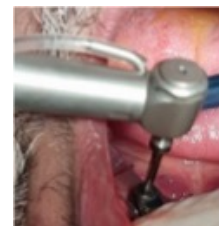

Figure 2 Placement of implant through the guide

After a period of 3 full months, the patients were recalled for the second phase

surgery and the exposure of the implants. A second surgical guide was fabricated to expose the implant by performing a tissue punch through it. The guide was then removed from the patient's mouth and the screw covers were removed using a screw driver. The ball attachments were installed initially by hand torque then by a calibrated torque ratchet according to the manufacturer's instructions which was 30Ncm.

The nylon caps were then inserted within the metal housings which were then fitted over the ball attachments in the patient's mouth. The undercut were then blocked out using flowable composite. (fig.4)

The denture's intaglio was then relieved using a metallic bur and a straight hand piece. Once enough space has been created to accommodate the housings, the hard pick-up (Dura Liner Hard chairside Reline, Reliance Dental Manufacturing, Illinois, USA) material was applied to the denture surface and inserted into the patient's mouth. Once the setting time has passed, the denture was removed from the patient's mouth and any remaining excess material was removed and the denture was polished.

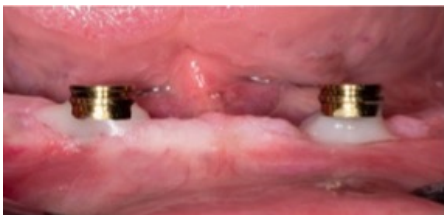

Figure 4 Metal Housings placed with undercut being blocked

The CBCT (i-CAT Vision Software, Imaging Sciences International, Hatfield, PA, USA) was obtained immediately after implant exposure, 6 months and 12 months after implant insertion to observe the volumetric change in the peri-implant bone. The MIMICS software (Materialise NV, Belgium) was used for the analysis of

volumetric change in peri-implant bone before and after implant placement.

The semi-automated segmentation technique was used to separate the implant and 1mm of the surrounding peri implant bone starting from the implant platform to the apex of the implant. The bone density was then measured and used as indication of the volumetric bone changes. (Fig.5)

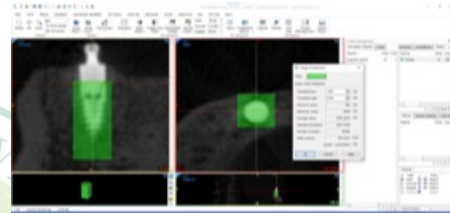


Figure 5 Bone density measurement using MIMICS

Results

At the Baseline, Group A (Laser-Lok) showed higher bone density value (3096.59 ± 129.73) than that (2974.49 ± 139.86) of group B (RBT group) which was statistically significant ($p < 0.001$). At 6 months, the statistical analysis showed a significant difference between group A and group B ($p = 0.0016$) where group A (2933.29 ± 295.50), still showed a higher bone density value than group B (2974.49 ± 139.86). finally, at the 12 months, group A maintained a higher bone density value (2776.57 ± 322.79) than that of group B (2398.04 ± 108.74) with the difference being statistically significant ($p = 0.007$).

Table (1): Mean and standard deviation (SD) values of bone density for the studied groups

Interval	Bone density (mean±SD)		t-value	p-value
	Group (A) Laser-Lok Group	Group (B) RBT Group		
Baseline	3096.59 ± 129.73	2974.49 ± 139.86	217.15	$< 0.001^*$
6 months	2933.29 ± 295.50	2645.90 ± 107.53	10.91	0.016^*
12 months	2776.57 ± 322.79	2398.04 ± 108.74	16.12	0.007^*

*; significant ($p \leq 0.05$) ns; non-significant ($p > 0.05$)

At the Baseline-6 months interval, Group B (RBT group) had a higher value (11.02 ± 0.92) than group A (Laser-Lok group) which showed a value of (5.38 ± 7.30) yet the difference was not statistically significant ($p = 0.089$). At the 6-12 months interval, however, Group (B)

(9.38 ± 0.71) had a significantly higher value than group (A) (5.46 ± 2.09) ($p < 0.001$). Finally, at the baseline-12 months, Group (B) (19.37 ± 0.20) had a significantly higher value than group (A) (10.48 ± 8.04) ($p = 0.026$).

Table (2): Mean and standard deviation (SD) values of bone density percentage change (%) for the studied groups

Interval	Bone density percentage change (%) (mean±SD)		t-value	p-value
	Group (A)	Group (B)		
	Laser-Lok group	RBT group		
Baseline-6 months	5.38±7.30	11.02±0.92	4.11	0.089
6-12 months	5.46±2.09	9.38±0.71	54.49	<0.001*
Baseline-12 months	10.48±8.04	19.37±0.20	8.56	0.026*

*; significant ($p \leq 0.05$) ns; non-significant ($p > 0.05$)

Discussion

The objective of this study was to assess the impact of implant surface laser treatment on the surrounding peri-implant bone changes with the hypothesis that the laser treatment of the implant surface enhances the density of the peri-implant bones as well as reduces the consequent marginal bone loss post loading.

The study design was a single arm prospective single center randomized study that followed a split-mouth protocol and was designed to determine any differences in outcome between implants having a laser modified surface and another with resorbable blast texturing surface treatment.^(15,16)

The treatment modality for the edentulous mandible in this study was the two-implant retained overdenture since it represents the minimum line of treatment for the edentulous mandible and the more cost-effective option for the patients.^(4,17)

The findings of the current study suggest that the presence of nano/micro channel grooves on the implant surface created by the laser ablation technique has actually induced the formation of peri-implant bone matrix with higher density and reduced the subsequent marginal bone loss following the loading of the implants.

After observing the CBCT records and the analysis using Mimics 21.0 software during a 12-month follow-up period, it was found that there is statistically significant difference in the bone density between both groups, with different amount of bone change from one group to the other.

This could be attributed to the laser-textured surface which augments the surface energy and improves osseointegration compared with the normal roughened implant surface. Also, the laser treatment increases the hydrophilicity of the titanium surfaces which in turn affects the osteoblast alignment on titanium. In other studies, the differentiation of human mesenchymal cells into an osteoblast and the mineralization of bone matrix has been shown to be significantly enhanced in case of laser-textured surfaces on titanium implants. It might be also suggested that nanotextured surface allows the attachment of cell types that enhances the development of mature, well mineralized bone allowing early osseointegration to occur more rapidly adjacent to implants with laser-textured collars.^(12,18-20)

Over the 12-months periods, group A (Laser-Lok) and group B (resorbable blast texturing) showed a decrease in the mean bone density surrounding the implant. This could be attributed to the bone loss that occurred crestally in response to the loading forces of the prosthesis transmitted through the attachment to the implant. The stresses acting on implants supporting overdentures increase the amount of the bending moment due to the prosthesis movement. Higher bending moments are generated around the unsplinted implants as the area of support in the bone decreases. The resultant micromotion has a detrimental effect on the bone-to-implant contact) and may result in greater bone turnover.^(21,22)

However, Group A showed a much lower change in the mean bone density in comparison with group B due to both an initial higher bone density and lower loss of crestal bone surrounding the implant.

Also, the attachment of the osteoblasts to the micro grooved surface allows stress transfer from the implant to the surrounding bone. A recent finite element analysis engineering study demonstrated that the Laser-Lok design reduced the crestal bone stress, in particular, the stress associated with collar region.^(19,23)

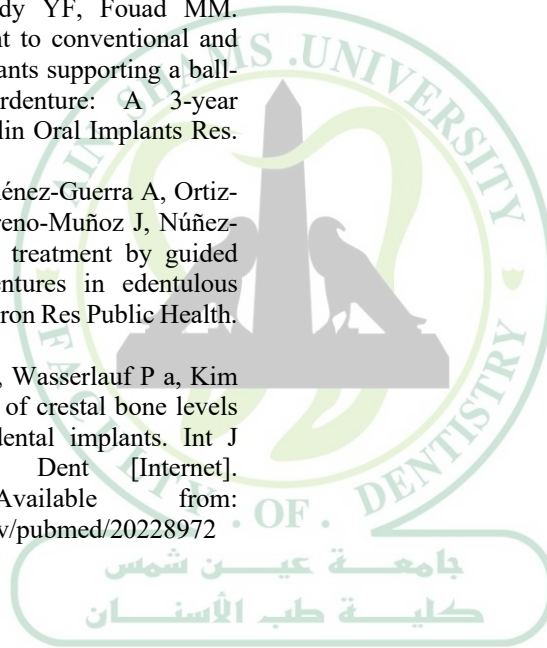
Conclusion

The Laser-Lok implant increased the density of bone formed around the implant post-surgically and decreased the rate of both the linear and volumetric bone loss around implant retained overdentures.

References

- Slade GD, Akinkugbe AA, Sanders AE. Projections of U.S. edentulism prevalence following 5 decades of decline. *J Dent Res*. 2014;93(10):959–65.
- Petersen PE, Bourgeois D, Ogawa H, Estupinan-Day S, Ndiaye C. The global burden of oral diseases and risks to oral health. *Bull World Health Organ*. 2005;83(9):661–9.
- Srinivasan M, Meyer S, Mombelli A, Müller F. Dental implants in the elderly population: a systematic review and meta-analysis. *Clin Oral Implants Res*. 2017;28(8):920–30.
- Thomason JM, Kelly SAM, Bendkowski A, Ellis JS. Two implant retained overdentures - A review of the literature supporting the McGill and York consensus statements. *J Dent* [Internet]. 2012;40(1):22–34. Available from: <http://dx.doi.org/10.1016/j.jdent.2011.08.017>
- Anjum S, Rajasekar A. Surface Modification of Dental Implants - A Review. *J Evol Med Dent Sci*. 2021;10(17):1246–50.
- Buser D, Janner SFM, Wittneben JG, Brägger U, Ramseier CA, Salvi GE. 10-Year Survival and Success Rates of 511 Titanium Implants with a Sandblasted and Acid-Etched Surface: A Retrospective Study in 303 Partially Edentulous Patients. *Clin Implant Dent Relat Res*. 2012;14(6):839–51.
- Matos GRM. Surface Roughness of Dental Implant and Osseointegration. *J Maxillofac Oral Surg* [Internet]. 2021;20(1):1–4. Available from: <https://doi.org/10.1007/s12663-020-01437-5>
- Pellegrini G, Francetti L, Barbaro B, Del Fabbro M. Novel surfaces and osseointegration in implant dentistry. *J Investig Clin Dent*. 2018;9(4):e12349.
- Kunrath MF, Muradás TC, Penha N, Campos MM. Innovative surfaces and alloys for dental implants: What about biointerface-safety concerns? *Dent Mater* [Internet]. 2021;37(10):1447–62. Available from: <https://doi.org/10.1016/j.dental.2021.08.008>
- Iorio-Siciliano V, Matarasso R, Guarnieri R, Nicolò M, Farronato D, Matarasso S. Soft tissue conditions and marginal bone levels of implants with a laser-microtextured collar: A 5-year, retrospective, controlled study. *Clin Oral Implants Res*. 2015;26(3):257–62.
- Degidi M, Piattelli A, Scarano A, Shibli JA, Iezzi G. Peri-implant collagen fibers around human cone Morse connection implants under polarized light: a report of three cases. *Int J Periodontics Restorative Dent* [Internet]. 2012;32(3):323–8. Available from: <http://www.ncbi.nlm.nih.gov/pubmed/22408777>
- Souza JCM, Sordi MB, Kanazawa M, Ravindran S, Henriques B, Silva FS, et al. Nano-scale modification of titanium implant surfaces to enhance osseointegration. *Acta Biomater* [Internet]. 2019;94:112–31. Available from: <https://doi.org/10.1016/j.actbio.2019.05.045>
- Asensio G, Vázquez-Lasa B, Rojo L. Achievements in the topographic design of commercial titanium dental implants: Towards anti-peri-implantitis surfaces. *J Clin Med*. 2019;8(11).
- Smeets R, Stadlinger B, Schwarz F, Beck-Broichsitter B, Jung O, Precht C, et al. Impact of Dental Implant Surface Modifications on Osseointegration. *Biomed Res Int*. 2016;2016.
- Nemli SK, Güngör MB, Aydin C, Yilmaz H, Türkcan I, Demirköprülü H. Clinical evaluation of submerged and non-submerged implants for posterior single-tooth replacements: A randomized split-mouth clinical trial. *Int J Oral Maxillofac Surg*. 2014;43(12):1484–92.
- Al Amri MD, Al-Johany SS, Al Baker AM, Al Rifaiy MQ, Abduljabbar TS, Al-Kheraif AA. Soft tissue changes and crestal bone loss around platform-switched implants placed at crestal and subcrestal levels: 36-month results from a prospective split-mouth clinical trial. *Clin Oral Implants Res*. 2017;28(11):1342–7.
- Dudley J. Implants for the ageing population. *Aust Dent J*. 2015;60(S1):28–43.
- Chen Z, Zhang Y, Li J, Wang H, Yu H. Influence of Laser-Microtextured Surface Collar

- on Marginal Bone Loss and Peri-Implant Soft Tissue Response: A Systematic Review and Meta-Analysis. *J Periodontol*. 2017;88(7):651–62.
19. Weiner S, Simon J, Ehrenberg DS, Zweig B, Ricci JL. The effects of laser microtextured collars upon crestal bone levels of dental implants. *Implant Dent*. 2008;17(2):217–28.
 20. Nevins M, Kim DM, Jun S-H, Guze K, Schupbach P, Nevins ML. Histologic Evidence of a Connective Tissue Attachment to Laser Microgrooved Abutments: A Canine Study. *Int J PERIODONTICS & Restor Dent*. 2010;30(3):245–55.
 21. Elsyad MA, Al-Mahdy YF, Fouad MM. Marginal bone loss adjacent to conventional and immediate loaded two implants supporting a ball-retained mandibular overdenture: A 3-year randomized clinical trial. *Clin Oral Implants Res*. 2012;23(4):496–503.
 22. Velasco-Ortega E, Jiménez-Guerra A, Ortiz-Garcia I, Garrido NM, Moreno-Muñoz J, Núñez-Márquez E, et al. Implant treatment by guided surgery supporting overdentures in edentulous mandible patients. *Int J Environ Res Public Health*. 2021;18(22).
 23. Shapoff C a, Lahey B, Wasserlauf P a, Kim DM. Radiographic analysis of crestal bone levels around Laser-Lok collar dental implants. *Int J Periodontics Restorative Dent* [Internet]. 2010;30(2):129–37. Available from: <http://www.ncbi.nlm.nih.gov/pubmed/20228972>



ASDJ

Ain Shams Dental Journal