

Detection of Sella Turcica Anomalies in Relation with Malocclusion. Lateral Cephalometric study in Sohag Population

Abeer Fareed AbdEl-Naeem^{a*}, Mahmoud Araby Abd El-Khalek^b, Tasneem Mohammed Ali^c, Naglaa Hammam Abo Eldahab^a

^aDepartment of Human Anatomy and Embryology, Faculty of Medicine, Sohag University, Sohag, Egypt

^bOral and Maxillofacial Radiology Department, Faculty of Oral and Dental Medicine, South Valley University, Qena, Egypt.

^cDepartment of Public Health and Community Medicine, Faculty of Medicine, Sohag University, Sohag, Egypt

Abstract

Background: Sella turcica is regarded as an important landmark that gives information about craniofacial development in lateral cephalometric radiographs. Malocclusion means disturbance in the arrangement of teeth which affects the general shape of the face, it is divided into 3 classes; I, II and III.

Objectives: to identify various anomalies of Sella turcica and their relation with malocclusion.

Subjects and methods: This retrospective study had been done on 321 lateral cephalograms of persons aged 5-16 who visited the Sohag university hospital, they were classified into three classes of malocclusion, and the anomalies of sella turcica in each class were recorded and analyzed.

Results: The highest prevalence of normal sella turcica was in class I (44.8%), then class III (21.4%) followed by class II (8.5%) The most frequent anomalies were the incomplete bridge and hypertrophic posterior wall.

Conclusion: There was an association between malocclusion classes and anomalies of sella turcica which should be noticed by orthodontists or clinicians for any interventional treatment.

Keywords: Sella; Malocclusion; Cephalometry.

DOI: 10.21608/svuijm.2023.223844.1622

***Correspondence:** abeerfareed167@gmail.com

Received: 18 July, 2023.

Revised: 7 August, 2023.

Accepted: 5 September, 2023.

Published: 9 December, 2023

Cite this article as: Abeer Fareed Abd El-Naeem, Mahmoud Araby Abd El-Khalek, Tasneem Mohammed Ali, Naglaa Hammam Abo Eldahab (2023). Detection of Sella Turcica Anomalies in Relation with Malocclusion. Lateral Cephalometric study in Sohag Population. *SVU-International Journal of Medical Sciences*. Vol.6, Issue 2, pp: 900- 910.

Copyright: © Abd El-Naeem et al (2023) Immediate open access to its content on the principle that making research freely available to the public supports a greater global exchange of knowledge. Users have the right to Read, download, copy, distribute, print or share link to the full texts under a [Creative Commons BY-NC-SA 4.0 International License](https://creativecommons.org/licenses/by-nc-sa/4.0/)

Introduction

Sella turcica is an important anatomical landmark in lateral cephalometric radiographs. It gives information about the craniofacial development (Alkofide, 2007). It is a saddle-shaped bony depression located on the upper surface of the sphenoid bone. It is also called hypophyseal fossa and lodges the hypophysis. It is related anteriorly to the tuberculum sellae and posteriorly to the dorsum sellae (Sathyanarayana et al., 2013).

There are two small processes on the side of the tuberculum sellae. These processes are the middle clinoid processes. On the superolateral angles of the dorsum sellae, the posterior clinoid processes are located. Sella turcica consists of three parts, the anterior wall, the floor, and the posterior wall (Yasa et al., 2017).

The size and shape of sella turcica vary. The size ranges from 4 to 12 mm vertical and from 5 to 16 mm anteroposteriorly (Choi et al., 2001). There are three normal shapes; circular, oval, and flat. The circular is the commonest shape while flat is the least. The round shape is common in 70% of children (Zagga et al., 2008).

The development of sella turcica associates with the development of the pituitary gland. The development of the pituitary gland completes before sella development. 28% of pituitary gland anomalies are diagnosed by using lateral cephalometric radiographs. The most frequent anomaly is pituitary adenoma which is detected by sella turcica enlargement (Moffitt, 2011).

The anterior wall of Sella turcica develops from the neural crest cells which migrate towards the frontonasal and maxillary bones. The posterior wall develops from the paraxial mesoderm and is associated with cerebral development (Kucia et al., 2014).

Human malocclusion means disarrangement of teeth and jaws that may lead to distortion in facial appearance, limitation in function in the jaw and teeth, an increase in risk for dental trauma, and a decrease in life quality (Moreno Uribe and Miller, 2015).

Angle, the "father of modern orthodontics" was the first to classify malocclusion. According to Angle, the mesiobuccal cusp of the upper first molar should align with the buccal groove of the mandibular first molar (Yadav et al., 2014).

Angle's classification in class I; the mesiobuccal cusp of the maxillary first molar occludes the buccal groove of the mandibular first molar, and the maxillary first molar is slightly posteriorly positioned relative to the mandibular first molar. Class II; the mesiobuccal cusp of the maxillary first molar occludes anterior to the buccal groove of the mandibular first molar, the maxillary first molar is in line with or anteriorly positioned relative to the mandibular first molar. Class III; the mesiobuccal cusp of the maxillary first molar occludes posterior to the buccal groove of the mandibular first molar, the maxillary first molar is severely posteriorly positioned relative to the mandibular first molar (Mohammad et al., 2021).

Salzmann (1966) also classified the malocclusion into 3 classes:

Class I: the bones of the face and jaws are in harmony with one another and with the rest of the head. The profile is orthognathic (Straight).

Class II: Distal mandibular development with the maxilla. The profile is prognathic (Convex).

Class III: Overgrowth of the mandible with obtuse mandibular angle. The profile is a retrognathic profile (Concave).

The current work aimed to identify various anomalies of Sella turcica and their relation with malocclusion classes.

Subjects and Methods

This retrospective study was done on 321 lateral cephalograms on subjects aged 5-16 years, attending the Department of Orthodontics in Sohag University Hospital for diagnosis of malocclusion in the period from June 2021 to June 2022.

An ethical acceptance was taken from the medical research ethics committee of the faculty of medicine at Sohag University under IRB number (Soh-Med-23-03-10PD).

Inclusion criteria

- Subjects from 5-16 years.
- Good discernibility of cephalometric structures, including the Sella turcica.

Exclusion criteria

- Subjects with craniofacial congenital deformities.
- Poor discernibility of cephalometric structures.

These cephalograms were inspected as monitor-displayed images as reported by (Segner and Hasund, 1998), by using a computer program. Subjects were classified into skeletal class I, II, and III malocclusion according to ANB angle: (A point) anterior limit of the maxillary bone, (B point) anterior limit of the mandibular bone, and (N point) the anterior limit of the nasofrontal suture. Those with an ANB angle of 0–4 degrees were categorized as skeletal Class I, with ANB 3-5 degree were classified as Class II, subjects with an ANB angle less than -1 degree were categorized as skeletal Class III (Patil et al.,2022) (Figs 1, 2).

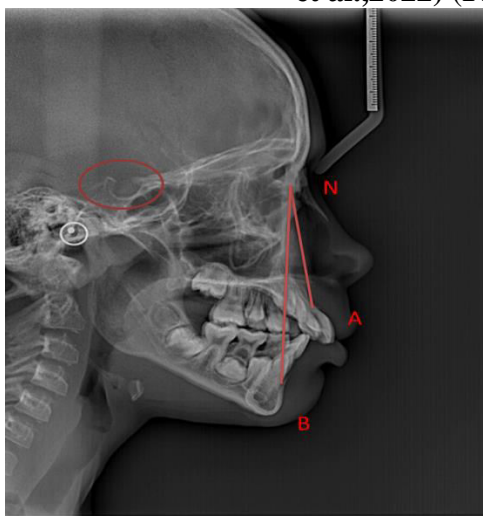


Fig.1. Lateral cephalometric images showing showing ANB angle and dtermination of sella turcica(circle)

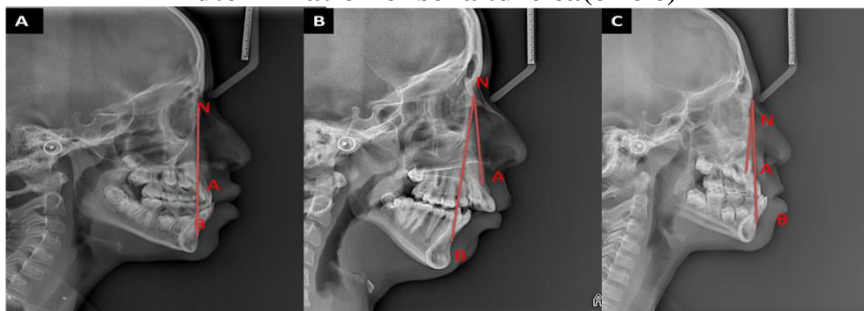


Fig. 2. Lateral cephalometric images showing malocclusion classes; (A) class I, (B) class II, (C) class III, notice ANB angle in the three classes ;0 degree in class I,more than 3 in class II ,less than1 in class III .

Anomalies of the Sella turcica were detected (Axelsson et al.,2004) (Fig.3):

They were classified into:

1. Complete Bridge (Ribbon-like fusion).
2. Incomplete Bridge.
3. Hypertrophic posterior clinoid process
4. Hypotrophic posterior clinoid process
5. The pyramidal shape of the dorsum sellae
6. The double contour of the floor
7. Oblique anterior wall
8. The oblique contour of the floor

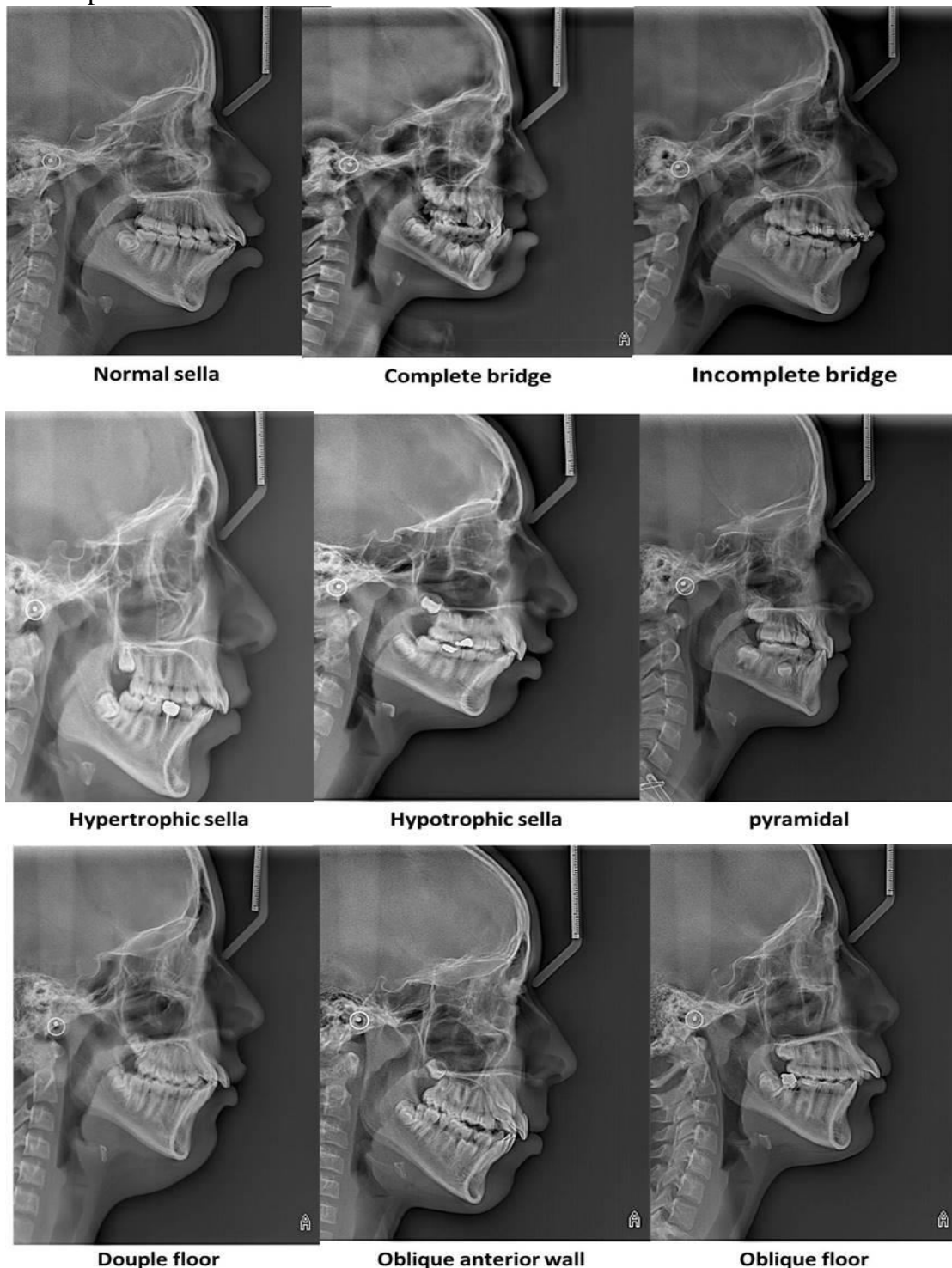


Fig.3. Anomalies of sella turcica

Statistical analysis

The obtained results were analyzed using SPSS software version 16 for the relation between sella turcica abnormalities and skeletal/dental malocclusions by descriptive statistics, and chi-square test, p value ≤ 0.05 was considered as significant.

Results

This retrospective study was done on 321 lateral cephalograms , 19 of them

were excluded for poor visibility or craniofacial anomaly to become 302 lateral cephalograms;100 males and 202 females. The subject's ages ranged from 5-16 years old with a mean age of 12.27± 2.41 . As seen in (Table.1) class II malocclusion had the highest number (188, 62.6%) followed by class I (58,19.2%)then Class III (56,18.5%).

Table 1. Gender distribution among the studied population, n= 302

Variables	Class I N= 58		Class II N= 188		Class III N=56		Total N=302	
	Count	%	Count	%	Count	%	Count	%
Males	18	31.0%	62	33.0%	20	35.7%	100	33.1%
Females	40	69.0%	126	67.0%	36	64.3%	202	66.9%
Total	58	100%	188	100%	56	100%	302	100%

(Table.2,and Fig.4) showed the number of normal and abnormal subjects in each class, class I had the highest percent of normal

shape(44.8%) while class II had the lowest percent (8.5%),there was highly significant difference in normal shaped sella between groups(p ≤0.0001) .

Table 2. Prevalence of abnormality among the studied population, n= 302

Variables	Class I N= 58		Class II N= 188		Class III N=56		Total N=302		P value
	No.	%	No.	%	No.	%	No.	%	
Normal	26	44.8%	16	8.5%	12	21.4%	54	17.9%	<0.0001
Abnormal	32	55.2%	172	91.5%	44	78.6%	248	82.1%	

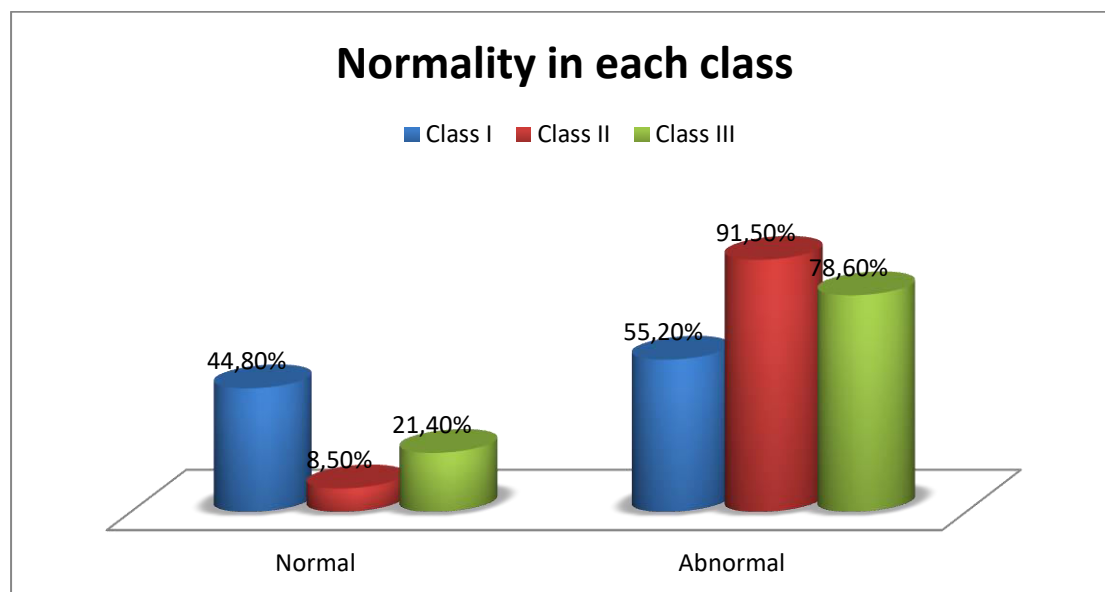


Fig.4. Normal and abnormal shaped sella in each class

There was no discernible difference in normal shaped sella between the sexes, and both males and females had nearly the same percentage of them ($p \geq 0.5$) (Table. 3).

Table 3. Distribution of abnormalities among males and females, n= 302

Variables	Males N=100		Females N=202		Total N=302		P value
	Count	%	Count	%	Count	%	
Normal	16	16.0%	38	18.8%	54	17.9%	0.5
Abnormal	84	84.0%	164	81.2%	248	82.1%	

Incomplete bridge was the most prevalent anomaly, occurring in 23.8% of cases, followed by hypertrophic posterior wall in 18.5% of cases (Table. 4, Fig.5)

Table .4. Description of types of abnormalities among the studied population, n= 302

Variables	Class I N= 58		Class II N= 188		Class III N=56		Total N=302	
	Count	%	Count	%	Count	%	Count	%
Complete bridge	6	10.3%	18	9.6%	5	8.9%	29	9.6%
Double contour of the floor	0	0.0%	14	7.4%	1	1.8%	15	5.1%
Hypertrophic posterior clinoid process	10	17.2%	40	21.3%	6	10.7%	56	18.5%
Hypotrophic posterior clinoid process	2	3.4%	4	2.1%	0	0.0%	6	2%
Incomplete bridge	10	17.2%	44	23.4%	18	32.2%	72	23.8%
Normal	26	44.8%	16	8.5%	12	21.4%	54	17.9%
Oblique anterior wall	4	6.9%	30	16%	12	21.4%	46	15.2%
Oblique contour of the floor	0	0.0%	6	3.2%	1	1.8%	7	2.3%
Pyramidal shape of the dorsum sellae	0	0.0%	16	8.5%	1	1.8%	17	5.6%

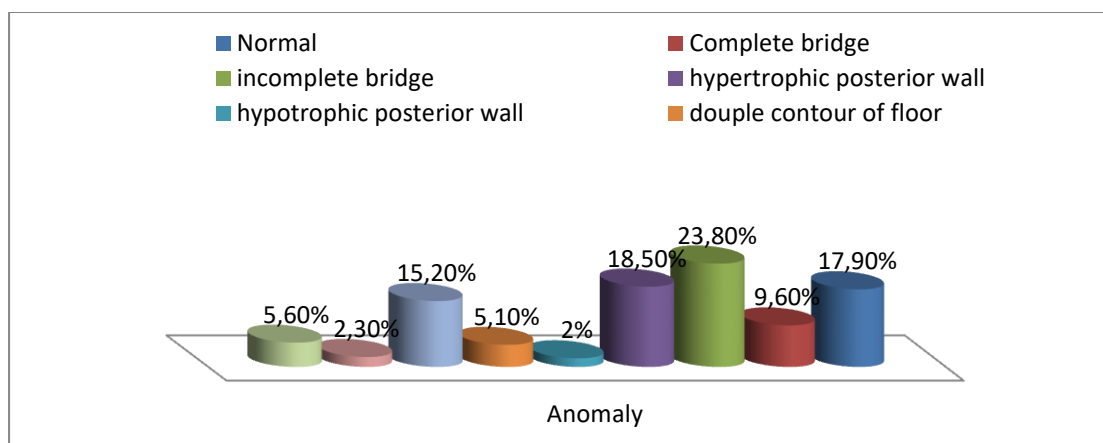


Fig.5. Anomalies of sella turcica

Discussion

Lateral cephalometry is considered a safe, easy, and non-invasive way to study the prevalence of sella turcica anomalies, as detection of anomalies at a young age can help surgeons in early intervention if needed (**Patil et al.,2022**). The sella turcica can be seen clearly in lateral cephalometric radiographs, and classes of malocclusion can be seen easily and precisely using previously established measurements.

The sella turcica develops embryologically from the notochord, and any deviation in cranial development will cause the sella turcica to develop abnormally later. The surrounding sella turcica develops after the pituitary gland. Therefore, variations or anomalies of the sella turcica are most frequently linked to variations or anomalies of the pituitary gland (**Yasa et al.,2022**).

This study was conducted on children as young as 5 years old because understanding the sella turcica's sound structure at a young age aids in the early diagnosis and treatment of cranial problems as well as the assessment of the growth of the cranial, facial, and mandibular bones at a later stage. According to some studies, the sella's anterior wall stabilized at age 5 (**Sathyanarayana et al., 2013**). The sella and other cranial bones' general characteristics and diameters grow and change as people age, and this is especially true of the sella turcica.

In subjects over the age of 19 compared to younger subjects, interclinoid ligament calcification is more pronounced due to dimensions and a decrease in interclinoid distance (**Kashio et al., 2017**)

In this study, we classified the people into 3 classes; class II malocclusion had the highest number

(188 persons, 62.6%) followed by class I (58 persons,19.2%)then class III (56 persons,18.5%), this is near to a study done by (**Issrani et al.,2023**) on Saudi Subpopulations on 300 subjects where he found that class II malocclusion was the commonest with 140 subjects followed by class I with101 , then class III with59 subjects. In Iran where a study was done on Iranian group; 31 subjects had class II, 30 class III ,29 had class I ,they differ from us in that the number of subjects in each class were nearly equal (**Valizadeh et al., 2015**) .

However, according to some researchers, class I was the most preventable (**De Rider et al.,2022**), where the distribution of malocclusion classes was Class I, Class II, and Class III with a mean prevalence of 51.9 %, 23.8%, and 6.5 %, respectively. Also (**Narayanan et al., 2016**) found that the prevalence of malocclusion was highest in class III (66.62 %), followed by class II (34.28 %), and class I (11.42 %). Other studies using different age groups from 14 to 26 found that the prevalence of malocclusion was highest in class III (66.62 %), followed by class II (9.3 %), and class I (11.42 %) (**Sobuti et al.,2018**).

In our current study, a total of 17.9% of people had normal sella, while 82.1% of people had abnormal sella. These findings are consistent with a research in an Iranian group where normal-shaped sellas were observed in 24.4% of cases and anomalies in 7.6% of cases (**Valizadeh et al.,2015**). Additionally, a second morphometric study on the north Indian population was conducted, with the findings indicating that 28% of the population had the typical Sella (**Chauhan et al.,2014**) .In Turkish population the normal sella turcica were seen in (39%) and anomalies in sella in (61%)

(Magat and Sener, 2018). According to a study conducted in Saudi Arabia, (44%) of patients had a normal shape, while (55%) had variations. (Issrani et al.,2013). Another study on the Norwegian population showed (65 %)of women and (71 %) of men had normal sella (Axelsson et al., 2004). this last study was done on children with normal skeletal class which may explain the difference in percentages.

Our current study showed that a higher presence of normal sella turcica was in class I (44.8%), then class III (21.4%) and class II (8.5%). Oktem agreed with our results. Class I had the highest percentage of normal sella turcica (46.7%), followed by class III (45.2%), and class II (30.3%) (Oktem et al.,2018). Hammami demonstrated that in Tunisian children, class II had the highest percentage of normal sella turcica (45.8%), followed by class III (40%) and class I (33%) in that order (Hammami et al.,2021).

Our study demonstrated that there is no difference in normality between males and females (Shahbeig et al., 2015) agreed with us in that there was no discernible gender difference in average diameters. Also (AL-Mohana et al.,2022) found no gender-specific shape differences in Yemen.

In our research, incomplete bridge was the most frequently observed anomaly (23,8%).This was accepted with the study done in Iran (Valizadeh et al.,2015) whose results was nearly similar to us. A study on Yamen found that the bridge shape (complete and incomplete) was present in 35.9 percent of the population. (AL-Mohana et al., 2022). (Shrestha et al.,2018) reported that 23.33% had incomplete bridge.

In our study, class III (32.2%) and class II (23.4%) were the

classes with the highest percentages of incomplete bridge , followed by class I (17.2%).This was comparable to the Iranian group. (Meyer-Marcotty et al.,2010) agreed with us as he reported the frequency of sella turcica bridging to be greater in skeletal class III patients compared to class I (16.8% versus 9.4%) .(Leonardi et al., 2006) reported that the prevalence of sella turcica bridge is higher in persons with dental anomalies.

An incomplete bridge or calcification of the inter clinoid ligament is said to be associated with a tooth or craniofacial anomaly, and any case discovered with this anomaly should undergo more examinations (Neha et al., 2016),but if calcification, or ‘bridging’ appeared with no symptoms ,it could be regarded as one of ST normal variants (AL-Mohana et al.,2022).

Different sella turcica anomalies could be signs of other dental or craniofacial anomalies, as well as underlying pathologies of the pituitary gland.(Karaman et al.,2021).Therefore, early diagnosis and surgical intervention can be aided by the routine use of simple lateral cephalometric radiographs in cases of malocclusion.

Conclusion

There were many anomalies of sella turcica which was associated with malocclusion classes which should be noticed by any clinician before any interventional maneuver.

Study's Limitation

In this study, our samples were all those how came for diagnosis or management of malocclusion, so the percentage of class I may not represent the true percent of the population, more research is needed to evaluate a large number of people, this study also was limited to children and adolescent peoples, not adult so no measurement was done to evaluate the normal

variation in depth and length of sella, so more researches are needed to study this measure in Sohag.

Authors' contribution

AA: Designed the study , TM statistical analysis .MA: data collection and data analysis, NA : Writing review ,revision .

References

- **Alkofide EA (2007)**. The shape and the size of the sella turcica in skeletal class I, class II, and class III Saudi subjects. *European Journal of Orthodontics* ,29:457-463.
- **AL-Mohana R , Muhammed F, Li X, Lubamba G (2022)**. The bridging and normal dimensions of sella turcica in Yemeni individuals. *Oral Radiology* , 38(1): 162–170.
- **Axelsson S, Storhaug K, Kjaer I (2004)**. Post-natal size and morphology of the sella turcica. Longitudinal cephalometric standards for Norwegians between 6 and 21 years of age. *European Journal of Orthodontics* , 26: 597-604.
- **Chauhan P, Kalra S, Mongia SM, Ali S, Anurag A(2014)**. Morphometric analysis of sella turcica in North Indian population: a radiological study. *International Journal of Research in Medical Sciences* ,2(2):521-526.
- **Choi WJ, Hwang EH, Lee SE (2001)**. The study of shape and size of normal sella turcica in cephalometric radiographs. *Korean Journal of Oral Maxillofacial Radiology* ,31:43–9.
- **De Rider L, Aleksieva A, Willems G, Declerck D, De Liano-Perula MC(2022)**. Prevalence of Orthodontic Malocclusions in Healthy Children and Adolescents: A Systematic Review. *International Journal of environmental research and public health* , 9 (12):7446.
- **Hammami W, Gmati H, Dhaoui S, Elelmi Y, Baccouche C, Touzi S, Zinelabidine A, Ghedira H(2014)**. Sella turcica shapes' anomalies in Tunisian children: prevalence and skeletal class relationship. *Journal of Annals of Dentistry and Oral Health* ,4(1):1030.
- **Issrani R, Alanazi S, Alrashed F, Alrasheed S, Bader A, Prabhu N, Alam M, Khan Z, Khan T(2013)**. Radiographic Analysis of Morphological Variations of Sella Turcica in Different Skeletal Patterns Among Saudi Subpopulations. *International Journal of General Medicine*, 16: 2481–2491
- **Karaman A, Cigerim S C, Kechagia N (2021)**. Evaluation of the relationship between sella turcica bridging and dental anomalies. *Journal of Dentistry Indonesia* ,28 (2):76-81.
- **Kashio H, Toriya N, Osanai S, Oka Y, Konno -Nagsaka M, Yamazaki A , Mugurma T, Nakao Y, Shiba T, Mizoguchi I(2017)**. Prevalence and dimensions of sella turcica bridging in Japanese female orthodontic patients. *Orthodontic Waves*, 9.
- **Kucia A, Jankowski T, Siewniak M, Janiszewska-Olszowska J, Grocholewicz K, Szych Z , Wilk G (2014)**. Sella turcica anomalies on lateral cephalometric radiographs of Polish children. *Dentomaxillofacial Radiology Journal* , 43(8):201.
- **Leonardi R, Barbato E, Vichi M, Caltabiano M(2006)**. A sella turcica bridge in subjects with dental anomalies. *European Journal of Orthodontics*, 28(6):580–5.
- **Magat G, Sener SO (2018)**. Morphometric analysis of the sella turcica in Turkish individuals with

- different dentofacial skeletal patterns. *Folia Morphology Journal*, 77 (3):543-550.
- **Meyer-Marcotty P, Reuther T, Stellzig-Eisenhauer A (2010).** Bridging of the sella turcica in skeletal Class III subjects. *European Journal of Orthodontics*, 32(2):148–53.
 - **Mohammad BH, Abdul-Jabbar MF, Mohammed MH (2021).** Prevalence of Angle's classification of malocclusion among patients Attending Orthodontic Department in College of Dentistry- a retrospective cross-sectional study. *Erbil Dental Journal*, 4(2):111-117.
 - **Moffitt AH (2011).** Discovery of pathologies by orthodontists on lateral cephalograms. *Angle Orthod Journal*, 81:58-63.
 - **Moreno Uribe LM, Miller SF (2015).** Genetics of the dentofacial variation in human malocclusion. *Orthod Craniofacial Research*, 18(1): 91–99.
 - **Narayanan Rk, Jeseem MT, Kumar TA (2016).** Prevalence of Malocclusion among 10-12-year-old Schoolchildren in Kozhikode District, Kerala: An Epidemiological Study. *International Journal of clinical pediatric dentistry*, 9(1):50-55.
 - **Neha SM, Shetty VS, Shetty S (2016).** Sella size and jaw bases – Is there a correlation? *Contemporary Clinical Dentistry*, 7: 61-66.
 - **Oktem H, Tuncer NI, Sencelikel T, Bagci ZI, Cesaretli S, Arslan A, Gursel IT, Degirmenci B (2018).** Sella turcica variations in lateral cephalometric radiographs and their association with malocclusions. *International Journal of Experimental and clinical anatomy*, 12(1):13-19.
 - **Patil K, Deshpande PS, Mahima VG, Panda R, Sanjay CJ, Nagabhushana D (2022).** Sella turcica anomalies and their association with malocclusion a lateral cephalometric study. *European Journal of Anatomy*, 26 (3): 325-333.
 - **Salzmann JA (1966).** Practice of orthodontics. Philadelphia: J. B. Lippincott Company.
 - **Sathyanarayana HP, Kailasam V, Chitharanjan AB (2013).** Sella turcica- its importance in orthodontics and craniofacial morphology. *Dental Research Journal (Isfahan)*, 10:571-575.
 - **Segner D, Hasund A (1998).** Individualisierte kephalometrie. Hamburg, Germany: D Segner Verlag.
 - **Shahbeig S, Mohseni S, Azimi F, Bakhshandeh H (2015).** Correlation of Shape and Size of Sella Turcica With the Type of Facial Skeletal Class in an Iranian Group. *Iranian Journal of Radiology*, 12(3): e16059.
 - **Shrestha GK, Pokharel PR, Gyawali R, Bhattarai B, Giri J (2018).** The morphology and bridging of the sella turcica in adult orthodontic patients. *BMC Oral Health*, 18(1):1–8.
 - **Sobuti F, Dadgar S, Seifi A, Musavi S J, Hadian H (2018).** Relationship between bridging and dimensions of sella turcica with classification of craniofacial skeleton. *Polish Journal of Radiology*, 83: 120-126.
 - **Valizadeh S, Shahbeig S, Mohseni S, Azimi F, Bakhshandeh H (2015).** Correlation of Shape and Size of Sella Turcica With the Type of Facial Skeletal Class in an Iranian Group. *Iranian Journal of Radiology*, 12(3): e16059

- **Yadav D, Rani MS, Shailaja AM, Anand D, Sood N, Goth R (2014).** Angle's Molar Classification Revisited. The Journal of Indian Orthodontic Society, 48(4):382-387.
- **Yasa Y, Ocak A, Bayrakdar IS, Duman SB, Gumusoy I (2017).** Morphometric analysis of sella turcica using cone beam computed tomography. Journal of Craniofacial Surgery ,28:70–74.
- **Yasa Y, Bayrakda I, OcakA, DumanS, Dedeoglu N (2022).** Evaluation of Sella Turcica Shape and Dimensions in Cleft Subjects Using Cone-Beam Computed Tomography. The journal of Oral Radiology,38(1): 162–170.
- **Zagga AD, Ahmed H, Tadros AA, Saidu SA (2008).** Description of the normal variants of the anatomical shapes of the sella turcica using plain radiographs: experience from Sokoto, Northwestern Nigeria. Annals of African Medicine , 7:77-81.