

Ancient Egyptian Ophthalmology: Eye Diseases and Eye Specialists

امراض العيون واطبائها في مصر القديمة

Sherin Mohamed Hafez¹ | Noha Mohamed Hafez²

Article Info

معلومات المقالة

Article Language: English

لغة المقالة: الإنجليزية

Vol. 7 No. 1, (2023) pp. 10-29 | <https://doi.org/10.21608/SIS.2023.221495.1149>

Abstract

الملخص

In ancient Egypt, the title *ir.tj* was associated with oculists, who were specialized doctors focusing on the treatment of eye conditions. The presence of this title alongside the principal title *swnw* indicates the specific expertise of these doctors in ophthalmology. They were highly respected members of society and were often consulted by the pharaoh and other members of the royal court. Ophthalmologists recognized the importance of eye health and developed specialized treatments for eye ailments. They employed a range of remedies, including herbal preparations, ointments, poultices, and eye drops. These treatments often utilized medicinal plants and substances with known healing properties. Oculists in ancient Egypt continued to play a significant role in society for centuries, making notable contributions to the development of medicine. The monuments and artifacts associated with oculists provide valuable insights into the practice of medicine during ancient times and offer glimpses into the lives of the individuals who dedicated themselves to this field.

ارتبط لقب *ir.tj* في مصر القديمة بأطباء العيون ، و يشير وجود هذا اللقب إلى جانب اللقب العام للأطباء *swnw* إلى الخبرة المحددة و المتخصصة لهؤلاء الأطباء في علاج العديد من امراض العيون التي عرفها المصري القديم و برع في علاجها . لقد احتل الاطباء مكانة عالية في المجتمع وغالبًا ما كانوا يستشارون من قبل الملك و كبار رجال الدولة شأنًا ، و قد أدرك أطباء العيون القدماء أهمية صحة العين وطوروا علاجات متخصصة لعلاج الامراض التي تصيبها ، و استخدموا مجموعة من المواد التي كان معظمها من الطبيعة و صنعوا منها المستحضرات العشبية والمرامح والكمادات وقطرات العين، و غالبًا ما كانت تتجح تلك العلاجات المستخلصة من النباتات الطبية والمواد ذات الخصائص العلاجية المعروفة في علاج هذه الامراض ، كما كانوا يقوموا ببعض العمليات الجراحية في بعض الحالات المستعصية . و قد حمل العديد من الاشخاص لقب طبيب العيون في مصر القديمة، و استمر أطباء العيون في لعب دور مهم في المجتمع لعدة قرون و كان لهم العديد من الآثار المرتبطة بهم و التي تحمل اسماءهم لتقدم رؤى قيمة حول ممارسة الطب خلال العصور القديمة وتقدم ايضاً لمحات عن حياة الأفراد الذين كرسوا أنفسهم لهذا المجال.

Keywords: Medicine; eye diseases; Ophthalmology; Oculists.

الكلمات الدالة: الطب؛ اطباء العيون؛ امراض العيون.

¹ Associate Professor, Tourist Guidance Department - Faculty of Tourism and Hotels - Suez Canal University - Egypt.

² Associate Professor, Tourist Guidance Department - Faculty of Tourism and Hotels - Suez Canal University - Egypt.

Aim of the research: The aim of this research is to highlight the significance of ophthalmology in ancient Egypt by exploring the practice of ophthalmology and the role of ophthalmologists. To shed light on the available information about eye diseases prevalent during that time and the knowledge and expertise of ancient Egyptian ophthalmologists in diagnosing and treating these conditions. Also to elucidate the prominent figures in ancient Egyptian ophthalmology, renowned practitioners who contributed significantly to this field.

Methodology : To gather information on ophthalmologists and eye diseases in ancient Egypt, a comprehensive review of available academic sources, including books and scholarly articles, was conducted. Primary sources such as ancient Egyptian medical texts, such as the Ebers Papyrus and the Edwin Smith Papyrus, were examined to understand the diagnostic techniques and treatments employed by ophthalmologists. Secondary sources provided additional insights and interpretations from modern researchers.

Introduction

Ancient Egypt, known for its remarkable civilization, made significant advancements in various fields, including medicine. Among the sciences practiced by the ancient Egyptians, medicine held a prominent position. The physicians of ancient Egypt were highly esteemed, renowned for their exceptional knowledge, skills, and experience. The medical papyri of ancient Egypt provide valuable insights into the ways in which medicine was practiced during that time, including the diagnosis of diseases and the remedies used for treatment.

The specialization of physicians in ancient Egypt was a notable aspect of their medical system. Herodotus, the Greek historian, observed that the medical profession in Egypt was highly specialized, with each physician focusing on a specific disorder. Physicians were categorized based on their expertise, treating diseases of the eyes, head, teeth, stomach, internal organs, and more. This specialization allowed for a deeper understanding of various medical conditions and enabled physicians to provide specialized care tailored to specific ailments. (Watermann, 1958, p. 125; Pollock, 1945, p.252; Krause, 1933, p. 258; Hirschberg, 1899, p.9-10)

The regulations governing the practice of medicine in ancient Egypt reflect the importance placed on patient care and the adherence to established practices. According to the legend, God *dhwtj* bestowed the Egyptians with a code of laws, recorded in eight books of wisdom. The vizier, was responsible for ensuring the execution of these laws. Deviation from the prescribed methods of treatment recorded in the canonical books could result in severe consequences, including death. However, there was also flexibility allowed, as Aristotle noted that if no improvement was observed after four days of treatment, physicians were permitted to modify their approach, assuming responsibility for the outcome. These regulations aimed to safeguard the well-being of patients and maintain the integrity of medical practice (Krause, 1933, p. 274)

The specialization, respect, and regulations surrounding ancient Egyptian medicine signify the significance placed on healthcare in their society. The advanced medical knowledge and specialization allowed for more effective diagnosis and treatment, addressing various ailments in a systematic manner. The existence of laws governing medical practice indicates a commitment to ensuring patient safety and maintaining standards of care.

This research will delve deeper into the field of ophthalmology in ancient Egypt, exploring the advancements made, the diseases encountered, and the contributions of ophthalmologists, who were known as *swnw-irty*. By examining the available sources, such as medical papyri and historical documents, we will gain valuable insights into the practice of ophthalmology in ancient Egypt and its significance within their advanced medical system.

The study will be divided in two main parts: an analysis of some eye diseases and their remedies, and mention the distinguished oculists or ophthalmologists in ancient Egypt.


I. Eye diseases and their remedies:

Ancient Egyptian ophthalmologists encountered a wide range of eye diseases and conditions. The medical texts of that time provide valuable insights into the various ailments they encountered and their methods of diagnosis and treatment. Ophthalmological cures were also carried out in sanctuaries and temples, through prayers, incantations, astrology for prognosis, amulets and pharmacotherapy with eye drops and ointments (Güemes, Luciana & Cusumano, 2022, p.20).




The ophthalmological papyri offer detailed information about the ancient Egyptian understanding of eye diseases, their classifications, and treatment methods. They demonstrate the advanced medical knowledge and skills possessed by ancient Egyptian ophthalmologists. The texts often prescribe remedies involving herbs, minerals, and other natural substances, as well as surgical interventions for certain conditions. Studying these papyri provides valuable information about the practice of ophthalmology and the ancient Egyptian approach to eye health and disease management.




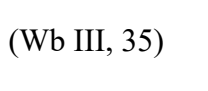

The oldest, important and famous medical reference for eye diseases is Ebers papyrus, which was written by the priests and discovered by the German Egyptologist Georg Ebers. It provides insights into the understanding of eye ailments and the methods used by ancient Egyptian physicians to diagnose and treat them by using natural substances; some parts from animals and birds, vegetable and minerals. There are also descriptions of the preparation of solid eye drops and various eye pathologies, such as trachoma, blepharitis, iritis, ectropion, cataracts, chalazion, nyctalopia and the pterygium. (Acosta Güemes, Luciana & Cusumano, Ana. ,2022, p.21; Wheeler,1946, p. 265)








In the following table some common eye diseases recognized by ancient ophthalmologists will be listed with their medical treatments as mentioned in some papyrus.









The diseases	definition	The treatment
 <p>(Wb I, p.224)</p>	<p>concern both glaucoma and cataract (fig.3)¹. They were unable to distinguish between these groups of diseases (Andersen,1997, p. 340). The cataracts, a clouding of the lens of the eye, were prevalent in ancient Egypt.</p>	<p>According to Ebers, the Egyptians tried to treat cases of 'h.t' by eye ointments and magic spells. It is hardly believable that such remedies had an effect, ophthalmologists attempted to alleviate this condition through surgical procedures, including couching, where the lens was pushed aside to improve vision.(Acosta, Luciana & Cusumano, Ana.,2022, p. 19; Ascaso & Huerva , 2013,p.75). They use goose grease and honey, lapis lazuli, milk, incense, but how intractable this disease must have proved (Bryan,1930, p.99).</p> <p>A wall painting in the tomb of the master builder <i>Ipwy</i> at Thebes (Fig 1) shows an oculist treating the eye of a craftsman.</p>




¹ The oldest documented case of cataract throughout history was reported in the priest reader Ka-āper (Sheikh el-Beled), dated to the 5th dynasty in the Egyptian Museum(Ascaso,Cristo'bal, 2001,p. 1714; Ascaso, and Huerva, 1994, pp.75-76)



		<p>Because of the length of the instrument, the scene might be considered as cataract surgery by couching of the lens into the vitreous cavity. (Acosta, Luciana & Cusumano, Ana. ,2022, p.20; Ascaso & Huerva,2013, p.75; Ascaso, Cristo'bal, 2009, p. 607).</p>
<p><i>3d.t</i>  or</p> <p><i>3dj.t</i> </p> <p>(Wb I, p.24; Budge,1978, p.14)</p>	<p>Severe ophthalmia concerning hemorrhages and an overflow of blood in the blood vessels, as well as excessive inflammations in the eyes (Andersen,1997, p.340,Hirschberg,1899,p.12).</p>	<p>The remedy for eliminating blood from the eyes: Ebers 348: ochre, malachite, galena, petrified wood, carob fruit, water, to be finely ground and placed on the eyes. Ebers 352: Frankincense, celery to be placed in the eye. Ebers384: Two bowls made from marl clay, the one with flour from <i>mjm.t</i> (Wb II, p.42) grain and milk from a woman who has borne a son, are to be left overnight for condensation to form. After this (treatment) wash the eyes with this milk four times a day. Ebers 387: Dried <i>myrrh</i>, <i>nhd.t myrrh</i> (Wb II, p. 304) and malachite, to be placed on the back of the eye. (Nunn,1996, p.202; Bryan, 1930, p.96)</p>
<p><i>Bdj</i></p> <p></p> <p>(Wb I, p.445)</p>	<p>Blindness</p>	<p>Blindness was depicted in Egyptian paintings and on monuments. It is well-known that blind musicians were admitted to the harems of kings and nobles, such as the tomb of Nacht (TT52) in Sheikh Abd el-Qurna (Fig.2 a), and the relief from the funerary chapel of <i>p3 itn m hb</i>, in Saqqara which dated to the 18th dynasty (fig.2 b). The singing, blind harpist, his eye is admirable, a crack of light between two swollen eyelids, it testifies to his blindness. (Nunn,1996, p.198, fig.9.3)</p> <p>Only blindness and ‘symbolic blindness’, especially in musicians, are occasionally depicted in tombs. Sometimes, male musicians were shown with a white band tied over their eyes (Fig. 2 c)</p> <p>The treatment as in Ebers 368: Black eye galena paint “placed in water 4 days”, fat of goose or duck “put in water for more 4 days”, then wash the galena with the milk from one who has borne a male child, <i>’ntjw</i> resin (Wb I, p.206), then put on both eyes (Nunn , 1996, p.199)</p>

		In column (1) in Kahun papyrus , the same disease is mentioned but not with his name;  , šš3.w st ir.tj šj mr n m33 n s , the treatment of a woman whose eyes are aching till she cannot see is fumigating her eyes with goose leg fat. (Trindade Lopes & Gurgel Pereira , 2021, p.12)
   (Wb III, 35)	<p>Cloudiness, concealment, blepharitis, blurred vision (Andersen, 1997, p. 341; Hirschberg,1899, p.12-13).</p>	<p>Ebers 339: Black eye galena paint “placed in water 4 days”, fat of goose or duck “put in water for more 4 days”, then wash the galena with the milk from one who has borne a male child, <i>ntjw</i> resin (Wb I ,p.206) ,then put on both eyes (Nunn,1996,p.199). šš3.t plant (Wb IV.545), carob fruit, lower Egyptian <i>gi.t</i> plants (Wb V,157), malachite <i>kšy.t</i> (Wb V,102) from a gazelle, the inner part of a <i>kšd.yt</i> beetle (Wb V, p.15), white oil. To be placed in water; and left overnight for condensation to form; then squeezed out. The afflicted area is to be bound with this. (Nunn, 1996, p.200)</p> <p>Ebers 340: <i>gšfn</i> drug (Wb V, p.206), <i>wsf</i> (Wb I, p.357) of the pond drug, tips/shoots of <i>mhy.t</i> papyrus. After this prepare for the patient 1 dose of bone marrow and wax to be placed on the eye’s back</p>
<p><i>šhd.w</i></p>  (Wb IV, 227)	<p>Albugines الغلالة البيضاء probably means corneal scars ندبة القرنية or leucoma عتامة القرنية (Andersen , 1997, p.340).</p> <p>Others translated it as white spots but it is not clear whether these are corneal opacities or pterygia (Nunn , 1996, p.202)</p>	<p>Ebers 347: Tortoise gall and honey to be placed on the back of the eyes.</p> <p>Ebers 382: Granite to be finely ground, sieved through a cloth, and sprinkled on the eye.</p> <p>Ebers 402: Galena and petrified wood, to be finely ground and put in the eyes.</p> <p>Ebers 403: <i>tr.w</i> ochre (Wb V, p. 386), galena and water, to be finely ground and placed in the eyes.</p> <p>Ebers 404: African Blackwood, galena, water, to be treated in the same manner.</p> <p>Ebers 405: Gall from an <i>šhdw</i> fish (Wb I, p. 8) and galena, to be treated in the same manner.</p> <p>Ebers 406: <i>smj</i> milk fat, milk,to be treated in the same manner. (Nunn,1996, p.202)</p>
<p><i>wh3.t</i></p>	<p>Trachoma, an infectious eye disease caused by the bacterium Chlamydia. It is a chronic inflammation of the eye and</p>	<p>Ophthalmologists employed various treatments, including the application of medicinal ointments and massages, to manage the symptoms and reduce its spread.</p>

 (Wb I, 347)	eyelids. It was known in ancient Egypt الرمد الحبيبي التهاب الملتحمة البكتيري Trichiasis and blindness were often the final result (Andersen, 1997, p. 340; Nunn,1996, p.201)	As in Ebers 346: dose of black eye paint “galena”, red ochre, ochre, and red natron applied to outside of both eyes. Ebers 347: dose of Tortoise gall, honey to be placed on the “back” of the eyes. (Nunn,1996, p.199)
 <i>h3rw</i> (<i>hl</i> or <i>hnr</i>)  (Wb III , p. 115)	weakness of sight or squint (Andersen, 1997, p. 341)	Lotion prepared by warming chips of a new <i>hnw</i> pot in fresh milk was recommended. Another lotion could be prepared by combining cream with the milk of a woman who has borne a son. A few salves are also given in this case. in one the Collyrium is combined with Honey; in another with Honey and Sap from fresh onions; in another with the Marrow of an ox; in another with Goose-grease and Water; in another with Incense and Real Lapis lazuli; in another with Antimony, Copper-vitriol, Writing-fluid, and Onions; and in still another with Writing-fluid, Myrrh, Opal-resin, Arabian wood powder and salt from Upper Egypt (Bryan, 1930, p.95).
 <i>hnt</i> (Wb III,308)	Eye inflammation	Ebers 367: black eye paint “galena” , red ochre , <i>snn</i> resin (Wb IV,p.166) , <i>htm</i> mineral (Wb III,196), <i>tr.w</i> mineral , <i>'ntjw</i> resin , upper Egyptian <i>šj3</i> mineral (Wb IV, p.31) ground and made into a homogenous mass and then put in the eyes, so that they will immediately be healthy.(Nunn,1996, p.199) Ebers 391: galena, petrified wood, <i>snn</i> resin , <i>htm</i> mineral, <i>tr.w</i> ,dried myrrh, fruit/seeds of a <i>tntj</i> plant (Wb V, p. 313)
 <i>hsf w</i> <i>hsf w n h'w</i>  (Wb III, 337; Andersen , 1997, p. 340)	Ectropion ارتشاء الجفن	Ebers 421: green eye paint “malachite”, <i>sntr</i> resin (Wb IV, p. 180), red ochre ground and applied to both eyes (Nunn,1996, p.199).
 <i>š3r.w</i> (Wb IV , 411;Andersen , 1997, p. 340)	Night blindness	Ebers 351: roasted ox liver which is rich source with vitamin A, pressed and applied thereon (Nunn,1996, p.199-200).

<p><i>ššm.w.t</i>  (Wb IV ,545)</p>	<p>Redness, eye inflammation</p>	<p>Ebers 408: carob fruit, Nile acacia leaves, malachite, milk from a woman who has borne a son. to be made into a homogenous mass, placed on the “back” of the eye. Ebers 409: galena, vulture eggshell to be finely ground, placed on the “back” of the eye. Ebers 410: galena, honey, ochre, red ochre, <i>snn</i> resin. Ebers 411: red ochre, ochre, galena, <i>snn</i> resin, honey Ebers 412: black flint, frankincense, faience, honey, to be placed on the corners of the eyes. Ebers 413: red ochre, ochre, honey, galena, <i>snn</i> resin</p>
<p><i>Knj.t</i>  (Wb V, 52)</p>	<p>Corneal ulcers, open sores on the cornea “front part of the eye”, were recognized and treated in ancient Egypt.</p>	<p>Ophthalmologists employed a combination of medicinal herbs, ointments, and bandages to facilitate healing and prevent complications. As in Ebers 416: green eye paint “malachite” <i>tr.w</i> mineral (Wb V, p. 386), black eye paint “galena”, natron, ochre, ground in water and applied to outside both eyes (Nunn,1996, p.199) Ebers 417: red ochre, fat of goose, the “backs” of the eyes are to be anointed with this.</p>
<p><i>kkw</i>  (Wb V, 142)</p>	<p>Darkness, dim and weakened vision (Andersen, 1997, p. 341)</p>	<p>Ebers 415: dose of Petrified wood, malachite, carob flour, Nile acacia leaves, small <i>hp'</i>  balls (Wb III, 366) from the African blackwood, juice from a <i>kb.w</i>  plant (Wb V, 25). To be made into a homogenous mass and made into an <i>jwšš</i>  mash (Wb I, 58); then dried and pounded into water and placed on the back of the eyes.</p>
<p><i>t3.w</i>  (Wb V, 229)</p>	<p>Heat, inflammation or irritation</p>	<p>Ebers 361: Phoenician juniper berries from Byblos Ebers 362: remedies include black eye paint, Marrow from the lower jaw of a donkey to be pounded in cold water (Nunn,1996, p.202). Ebers 366: Upper Egyptian <i>sj³</i> drug to be placed in water from a <i>p3.w</i> -^c water course (Wb I, p.497) and put in the eye.</p>
<p><i>thn</i> </p>	<p>Injury in the eye</p>	<p>Ebers 349: dried feces from belly of infant, honey, vegetable mucilage applied to</p>

(Wb V, 327)		<p>outside of both eyes. (Nunn,1996, p.199, 201)</p> <p>Ebers 381: cooked $\text{\\$3\text{\\$3}}$ (Wb IV, p. 413), carob fruit, honey, finely ground, sieved through a cloth and bandaged on both eyes (Nunn,1996, p.199- 201)</p> <p>Ebers 337: other remedies for <i>thn</i>; day one: marsh water</p> <p>Day two: honey, black eye paint “galena”, if it bleeds, honey, black eye paint, bandaged with it for two days (Nunn,1996, p.201)</p> <p>However, if much liquid is discharged the remedy will be: <i>j\text{\\$}w</i> drug, malachite, frankincense, head of a <i>h\text{\\$}n</i> tubular plant.</p>
<p><i>thm</i> ,</p> <p>(Wb V, 322)</p>	<p>Hole, perforation</p>	<p>Full discussion of the term <i>thm</i> was mentioned in Edwin Smith Papyrus in case 19 A, in this case the patient’s eye on the injured side is “ blood – shot” and his neck is stiff. His two eyes are red like the color of $\text{\\$3\text{\\$}}$ flowers, the treatment is grease, honey and lint every day until he recovers. (Breasted, 1991, 281 – 284)</p>
<p><i>dfdf.t</i></p> <p></p> <p>(Wb V, 573; Andersen, 1997, p. 340)</p>	<p>Contraction of the pupil or iris; perhaps a symptom of iridocyclitis التهاب القرنية.</p> <p>Also this word would appear to mean excessive lachrymation which can arise from many causes , including blocked tear ducts.</p>	<p>Ebers 345: One dose of Small <i>hp\text{\\$}</i> balls from the African blackwood, upper Egyptian <i>s\text{\\$}</i> drug, to be pounded in water and placed on the eyes very often.</p> <p>Ebers 378: another remedy, for eliminating an “increase” of water in both eyes and drive out the raising up of the water in the eyes</p> <p>the remedy included real powdered lapis lazuli, malachite, <i>snn</i> mineral, milk, galena, faience , <i>mnww</i> part the <i>\text{\\$}b.t</i> melon, to be made into a homogenous mass. (And) put on the “back” of the eyes (Nunn,1996, p.201).</p>
<p><i>\text{\\$}p.t</i> </p> <p>(Wb IV, 443)</p>	<p>Blindness</p> <p>(Andersen , 1997, p. 341; Hirschberg, 1899,p.16)</p>	<p>Ebers 356 a: The water of the pig’s eye, true galena, red ochre, to be finely ground and made into a homogenous mass, poured into the ear, which is linked to the eye.</p> <p>Ebers 357: dried <i>myrrh</i>, to be ground and placed on the back of the eyes.</p> <p>Ebers 358: carob fruit, to be pounded into honey and placed on the back of the eyes.</p> <p>Ebers 420: carob fruit, to be finely ground; then sieved through a cloth, combined with honey and put in the eyes (Nunn,1996, p.200).</p>

<p><i>pd.št.</i>  (Wb I, 567)</p>	<p>Small ball in the eye, sty, chalazion. (Andersen, 1997, p. 340; Hirschberg, 1899, p.16)</p>	<p>Ebers 355: Black eye paint “galena”, green eye paint “malachite”, carob fruit, <i>gšfn</i> mineral (Wb V, p. 206) to be mixed with water and placed on the back of the eye (Nunn,1996, p.199).</p>
<p><i>nh3.t</i>  (Wb II,290)</p>		<p>Ebers 350: tortoise gall, <i>jbr</i> oil applied to both eyes (Nunn,1996, p.199) Ebers 383: leaves of acacia, flour of carob, granite, ground, bandaged on both eyes Ebers 407: black eye paint “galena”, red ochre, ochre, red natron, applied to outside of both eyes (Nunn,1996, p.199, 201) https://sae.saw-leipzig.de/en/documents/papyrus-ebers</p>
<p>Troublesome eyelashes</p>		<p>Ebers 424: the Ebers papyrus is quite specific on troublesome eyelashes which grow inwards to irritate the cornea <i>‘ntjw</i> incense, blood of lizard, blood of bat, pull out the hair, apply to it so that it gets well (Nunn,1996, p.201) The second remedy is similar to the first but includes blood of ox, ass, pig, hound and goat. (Nunn,1996, p.202)</p>

Comment on the previous table:

- Ancient Ophthalmologists recognized the importance of eye health and developed specialized treatments for eye ailments. They employed a range of remedies, including herbal preparations, ointments, poultices, and eye drops. These treatments often utilized medicinal plants and substances with known healing properties.
- It can be noticed from the previous table that most of the treatments used to cure eyes’ diseases were derived from nature and were not chemical substances. They used foodstuffs such as; milk, honey, goose grease, carob fruit, water, roasted ox liver and vulture eggshell. They also used stones and minerals such as; malachite, lapis lazuli and ochre.
- In addition to medicinal treatments, ancient Egyptian oculists were skilled in surgical interventions related to eye conditions. They performed procedures such as incisions, removal of foreign objects, and cauterization (fig.1). Surgical tools used by ancient Egyptian doctors have been discovered in archaeological excavations, indicating their proficiency in carrying out these procedures.




II. The famous oculists or Ophthalmologists in ancient Egypt

From the previous table, it is obvious that the ancients knew a lot about the eye, its diseases and its treatment, but who take this responsibility? Who is the one who is in charge of healing the eyes? In ancient Egypt, there were individuals who specialized in treating eye ailments and were considered early practitioners of ophthalmology. These ancient Egyptian oculists played a significant role in



diagnosing and treating various eye conditions. Although specific names of individual oculists are not well-documented, there is evidence of their existence and their practices.


Ophthalmological medical assistance was in charge of *ir.tj* (eye doctors), *swnw* (doctors), priests and magicians, who worked together, since they believed that the origin of diseases was the result of external agents, as well as supernatural causes. (Güemes, Luciana & Cusumano, 2022, p. 18). Ancient Egyptian doctors were indeed recognized for their proficiency in treating various medical conditions, including eye ailments. Herodotus wrote that Cyrus sent to Ahmose II, 26th dynasty to ask for the services of the best ophthalmologist in Egypt. (Nunn, 1996, p. 198).


In ancient Egypt, the title *ir.tj* was associated with oculists, who were specialized doctors focusing on the treatment of eye conditions. The presence of this title alongside the principal title *swnw* indicates the specific expertise of these doctors in ophthalmology. **Here's an explanation of the titles:**

- 1- *šwnw* : The title *swnw* was a general term used to designate a physician or doctor in ancient Egypt. It indicated a person's profession and expertise in the field of medicine. Those with the title *swnw* were knowledgeable in various medical practices and treated a wide range of ailments.
- 2- *ir.tj*: The title *ir.tj* specifically identified oculists, indicating their specialization in diagnosing and treating eye-related conditions. The term *ir.tj* is believed to mean “one who does the eyes” or “one who tends to the eyes”. This title distinguished oculists from general physicians and highlighted their expertise in ophthalmology.
- 3- By having both the title *swnw* and *ir.tj* these ancient Egyptian oculists showcased their comprehensive medical knowledge as physicians while also highlighting their specialized focus on eye care. This dual title system allowed for a clear identification of doctors who possessed advanced skills and experience in treating eye conditions, emphasizing their specialization within the broader field of medicine (Dawood, 1998, p. 172). Some of them were *swnw ir.tj* ; Eye physician (Dilwyn, 2000, p. 826, no. 3018; PM III-2, H 118; Wb I, 106 [18]; *ibid.*, III, 427 [9]). Others were  the eye physician of the royal court (Helck, 1954, 67 [46]; PM III-2, H 119). Others also bear the title  *hrp swnw ir.tj pr 3* inspector of the eye physicians of the royal court (PM III-2, H 69). All these titles were known from the Old Kingdom (Watermann, 1958, Abb. 3; Junker, 1928, p. 66 [2-a]). In the following part, some of the famous *ir.tj* will be mentioned along with the documents that bear their medical titles.


It is important to note that the documentation of these titles and their associations with specific medical roles primarily dates back to the Old Kingdom of ancient Egypt. While the documentation of specific oculists is limited, there are a few notable individuals mentioned in ancient texts who held the title *ir.tj* alongside the title *swnw*, here are some examples:


I. *w^c.j* I  or *w³.c*  (Ranke, 1935, p. 76; PM III-1, p. 210)

w^c.j I is an eye physician  from the Old Kingdom (4th and 5th dynasty). His rock cut tomb was found in Giza necropolis (LG 67). The burial chamber is small and is filled by 2 wells, which are however full. The walls have no inscriptions but the drum of entrance doorway is inscribed with the name and titles of the deceased and his wife (PM III-1, p. 210; Lepsius, 1897, p. 89).


The inscription:  *rh.t nsw.t swnw ir.tj w^c.j*; *w^c.j* is known to the king, physician and oculist (Ghaliongui, 1983, p. 18; Pirenne, 1932, 348 [50]; Lepsius, 1849, Bl. 93 a).

II. Ipi 

The tomb of Ipi (Grab no.80) is found in Giza necropolis , it has small hall and entrance in the east end; in the middle of west end there is a burial chamber or offering room ,in its north wall a doorway leading to another room or to another tomb. (Reisner, 1942, p. 235[3]). Only the drum of entrance doorway of the tomb (fig. 4) is inscribed and Ipi’s name immediately follows the medical title as an oculist  Ipi *rh.t nšw.t ir.tj swnw pr 3*; which mean “Ipi is known to the king, oculist and physician of the Great House”(Lepsius, 1849 Bl.82f; PM III-1, p. 213; Mariette, 1885,p. 536). Most of the walls are black because of the smoke (Ghalionungui, 1983, p.17; Jonckheere, 1951, p. 243).

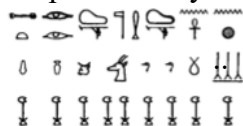III. w^c.j II 

w^c.j II dated also to the same period of w^c.j I. His name can be read on the fragment of the stela of Ipi (Fig.4). Unlike Quibell, which considers the doctor to be Ipi, it is believed that this profession should be also reserved for w^c.j whose name written on the same line and immediately follows the title *ir.tj* (Jonckheere, 1951, p. 243). From the inscription which was written direct above the head of Ipi , w^c.j – beside an Oculist – was *swnw h.t ir.tj*; belly (stomach) specialist (Bardinet, 1990, 234 [2]; Jonckheere ,1958, p.30).

IV. Nj ^cnh *dw3w* 


Nj ^cnh *dw3w* was a priest of *dw3w* and an Oculist in the 5th dynasty (Bardinet, 1990, 234 [4]; Jonckheere, 1958, p.50,51). His name was at first read *Nj ^cnh hnsu*, then it was later rectified to *Nj ^cnh *dw3w** which means *dw3w* processes life, or he who belongs to the life of *dw3w* (Ghalionungui, 1983, p.20). His title as *ir.tj* was inscribed on a part of an unfinished false door (fig.5 a, b), *Nj ^cnh *dw3w** is represented with long hair, clothed in an apron, collar and adorned with arm rings. His right hand reaches for food; his left hand is on his chest. He is sitting on a platform in a deep-seated low backed chair. The feet of the chair are modeled after those of an animal. Various vases and jars of wine are scattered about the platform. An ox’s joint, calf’s head, cakes, bread, capped by a goose on a trencher are piled high in front of him (Grdseloff, 1942, p.214; Borchardt ,1937, no.1452, p. 13; Krause, 1933, p. 262).



Above the offering table, positioned prominently before his head, the inscriptions stating:




*Nj ^cnh *dw3w* hmnt^r *dw3w* swnw *ir.tj* h3 t h3 hnk.t h3 k3w h3 m3- h^dh3 sr h3 mnw.t h3 šs h3 mn^h.t*

The priest of *dw3w*, the oculist, *Nj ^cnh *dw3w** , thousands of bread, bear, oxen, antelope, goose, doves alabaster and clothes



V. Nfr *tst* 

*Nfr *tst** was known as an oculist from the bas relief in the chapel of  *jbj* , son of *wp m nfrt*  and the director of the distribution of food in the house of life (Ghalionungui, 1963, p.15,1983,p.21; Jonckheere ,1958, p. 54; Hassan,1936, p.179). The scene (fig.6 a, b) represents *wp m nfrt* wears a long-plaited wig, false beard, necklace, wide triangular cloth and a pair of sandals. He is in a walking attitude with a long staff in his right hand, while he is pointing with his left hand to the inscriptions in front of him.


Before him, in a striking arrangement, fifteen figures are portrayed in four vertical rows. These individuals share a common posture, seated on the floor with one leg resting on the ground and the

other leg slightly raised. Their right hand is closed upon their chest; conversely, their left hand is placed upon their thigh, with the palm open and facing upward. All the figures facing towards *w p m nfrt* each of these accompanying figures is bestowed with individual identities and roles, as denoted by their inscribed names and titles placed in front of them. Within the first square of the second row, the name of the Oculist  *swnw ir.tj nfrtst* is prominently mentioned, which indicate his profession as an Oculist, indicating his specialized knowledge and expertise in the field of ophthalmology (Bardinet, 1990, 234 [5]; Watermann, 1958, p. 124, 128; Hassan, 1936, p. 190, 191).

VI. *Mdw nfr*

Mdw nfr “beautiful utterance or beautiful wand”, is the door-keeper of the god *dw3w*, master of the secrets of the Great House in the middle of 5th dynasty or later (Hassan, 1941, p.115; Ranke, 1935, p.167; PM III-1, p. 258). He has also some medical titles such as  *hrp swnw ir.tj n pr 3* “chief oculist of the Great House”, and  *swnw pr 3* “the physician of the Great House” (Watermann, 1958, p.124; Jonckheere, 1958, p.47; Grdseloff, 1942, p.214; Hassan, 1941, p.115).

His rock-cut tomb of is situated in Giza (fig. 7 a), the main entrance to his funerary chapel is reached by a long narrow passage; the jambs and the lintel of the doorway are made of enormous blocks of Tura limestone. No traces of inscriptions are visible on the jambs, while the lintel was found completely intact although fallen from its original place. It is finely inscribed with two horizontal rows of incised hieroglyphs (fig. 7 b, c).

At the middle of the first row his medical titles are inscribed;  *hrp swnw ir.tj n pr 3 nb im3h hr ntr f swnw pr 3*; “chief of physicians and oculist of the Great House, the lord before his god, the physician of the Great House” (Ghaliongui, 1983, p.19; Hassan, 1941, p.117)

VII. *Irn 3h.tj* , with the nickname *Trj* and *nj nh Ppy*

Next to the pyramids of Giza is the tomb of *nj nh Ppy* or *Trj*, the first documented royal oculist who lived during the 6th Dynasty (Jonckheere, 1958, p.25; Junker, 1943, p. 80). He was also a specialist in astrology and iridology. Inscriptions from his tomb describe him as “chief of royal physicians, royal ophthalmologist, chief of intestinal diseases, magician, and academician” (Güemes, Luciana & Cusumano, 2022, p.19; Krause, 1933, p.259,260).

The 6th dynasty court physician and high priest *Trj* has many medical titles, such as *swnw pr-3* physician of the palace, *shd swnw pr-3*; Inspector of the physician of the palace, *swnw ir.tj pr-c3* the eye physician of the great house, *swnw h.t pr-c3*; physician of the belly palace, *wr swnw pr-c3* chef of the physician of the palace and *nrrw phw.t* shepherd of the Anus (Ghaliongui, 1983, p.17; Jonckheere, 1958, p.25)

Trj's stele was found 1926 in a grave field westward to Khufu pyramid in an excavation of a cemetery of a 4th dynasty (fig. 8 a, b), the evidence indicates that it was removed from the original tomb and placed over the tomb on which it was discovered. The stela is a limestone slab in a good state of preservation; it mentions various medical activities and diseases, which were common at that time (Watermann, 1991, pp.17-20; Junker, 1928, p.53).

He is sitting on low backed chair, which ends in the form of a lotus flower at the back. The feet of the chair are modeled after those of an animal. He is wearing a shoulder length wig, a broad collar, and a knee-length kilt. He extends his right hand towards a table covered with conventionalized row of tall half-loaves of bread, surmounted by a foreleg of beef and a trussed duck, while his left hand is clenched on his chest holding a folded cloth. At his feet, under the long-forked stand of the offering table, are a basin and ewer resting on a small rectangular stand. Above the offering table is a brief ideographic list of offerings, in which the hieroglyph signs are directed towards the deceased. His left

hand holds a vase to his nose, the dish from which he eats is higher than the chair and is placed directly before him. (Fischer, 1963, p. 38-41; Krause, 1933, p. 260)

Various vases and jars of wine are scattered about the platform. An ox's joint, calf's head, cakes, bread, capped by a goose on a trencher are piled high in front of him. (Krause, 1933, p. 262). In front of a ritual table, In front of his head the inscriptions stating: "Iry, doctor at the royal court". This title is also shown on the ledger above the false door. On the jamb right to the door, he is mentioned as:



"Pr 3 swnw ir.tj", eye doctor at the great house, below it the name *Iry*. Other titles of him were mentioned here such as : doctor at the court , leader of Serket , inspector of doctors at pharaoh's court , pharaoh's doctor of the belly , eye doctor, then shepherd of the king's anus , again pharaoh's doctor and finally the name *Iry* (Velhagen, 1983, pp.38-39;). In Line (4) his title as oculist is written: *hry hb swnw ir.tj nfr h3t m sskr nb.w.f Tti*; senior lector priest, keeper of the headdress in ornamenting his lord (Dawood, 1998, p. 236).

VIII. *W3h dw3.w* (*dw3w* lasts)

W3h dw3.w was the priest of *dw3.w*; his burial chamber was found in Giza. On a tombstone from his destroyed tomb (fig.9), a scene is representing *W3h dw3.w* with the title *wrswnwir.ty pr-3*, great oculist of the palace (Ghalionungui, 1983, p.18; Jonckheere, 1958, p. 29).

W3h dw3.w is sitting on a low-backed chair which feet of an animal. He is wearing a shoulder length wig, and a knee length kilt. He extends his right hand towards a table covered with conventionalized row of tall half-loaves of bread, while his left hand is clenched on his chest (Krause, 1933, p. 260). Various vases and jars of wine are scattered about the platform. An ox's joint, calf's head, cakes, bread, capped by a goose on a trencher are piled high in front of him. (Krause, 1933, p. 262)

Conclusion:

-Ancient Egyptian doctors categorized various eye diseases based on their symptoms and characteristics. They recognized and differentiated between conditions such as conjunctivitis, cataracts, trachoma, corneal ulcers, and infections. This classification system helped in diagnosing and treating specific eye ailments effectively.

- Ancient Egyptian physicians possessed a considerable understanding of eye anatomy. They recognized the different structures of the eye, including the cornea, iris, lens, and retina. This knowledge allowed them to diagnose specific eye disorders and understand the functions of different eye components.

- Ancient Egyptian doctors were skilled in utilizing medicinal plants and substances to treat eye conditions. They had knowledge of the healing properties of various plant extracts, herbs, animal products, and minerals which they used to create ointments, eye drops, and poultices. These herbal remedies were often applied directly to the eyes or used in conjunction with other treatments.

-Religion played a central role in ancient Egyptian life, and medicine was no exception. The ancient Egyptians believed that diseases had both natural and supernatural causes. They attributed illnesses to various factors, including evil spirits, divine punishment, or the disruption of harmony in the body. Consequently, medical practices often involved rituals, prayers, and amulets to seek divine intervention for healing.

-Although surgical interventions were not as developed as they are in modern ophthalmology, the ancient Egyptians did perform some procedures. The Edwin Smith Papyrus, describes surgical techniques for treating eye injuries and conditions like entropion (an eyelid turned inward) and trichiasis (ingrown eyelashes). These surgeries were typically performed using primitive tools such as knives and needles.

- the available information about specific oculists during the Old Kingdom period is limited. The documentation of ancient Egyptian doctors and their titles became more extensive in later periods, such as the New Kingdom and the Greco-Roman era.

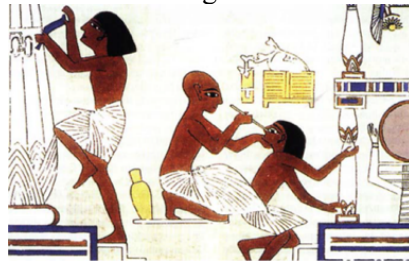
References:

- Acosta Güemes, Luciana & Cusumano, Ana. Maria, (2022), Ophthalmology in Ancient Egypt, *Asian Journal of Education and Social Studies*, Volume 35, Issue 4, p. 18-23.
- Andersen S. R., (1997), The eye and its diseases in Ancient Egypt. *Acta ophthalmologica Scandinavica*, 75(3), 338–344. <https://doi.org/10.1111/j.1600-0420.1997.tb00792.x>
- Ascaso, F. J., & Cristóbal, J. A., (2001), The oldest cataract in the Nile Valley, *Journal of cataract and refractive surgery*, 27(11), 1714–1715. [https://doi.org/10.1016/s0886-3350\(01\)01205-6](https://doi.org/10.1016/s0886-3350(01)01205-6)
- Ascaso, F. J., Lizana, J., & Cristóbal, J. A., (2009), Cataract surgery in ancient Egypt. *Journal of cataract and refractive surgery*, 35(3), 607–608. <https://doi.org/10.1016/j.jcrs.2008.11.052>
- Ascaso, F.J., & Huerva, V. (2013), The History of Cataract Surgery. In (Ed.), *Cataract Surgery*. IntechOpen. <https://doi.org/10.5772/19243>, Spain, p. 75-90
- Bardin, Th., (1990), Dents et mâchoires dans les représentations religieuses et la pratique médicale de l'Égypte ancienne, Roma.

- Blomstedt, P., (2014), Cataract surgery in ancient Egypt. *Journal of Cataract and Refractive Surgery* 40
- Borchardt, L., (1937), *Denkmäler des Alten Reiches*, CG I, Berlin
- Breasted, J.H., (1991), *The Edwin Smith Surgical Papyrus, Volume 1: Hieroglyphic Transliteration, Translation, and Commentary*
- Bryan C.P., (1930), *The Papyrus Ebers*, London
- Bryan C. P. & Smith G. E, (1931), *Ancient Egyptian Medicine, The Papyrus Ebers*, New York
- Budge, W., (1978), *An Egyptian Hieroglyphic Dictionary: With an Index of English Words, King List, and Geographical List with Indexes, List of Hieroglyphic Characters, Coptic and Semitic Alphabets (Vol 1)*
- Dawood, Kh., (1998), *The Inscribed Stelae of the Herakleopolitan Period from the Memphite Necropolis*, University of Liverpool
- Deines , H., Grapow, H & Westendorf, W., (1973): *Grundriss der Medizin der alten Ägypter. Ergänzungen. Drogenquanten, Sachgruppen, Nachträge, Bibliographie, Generalregister, Vol. IX, p 22*
- Dilwyn, J., (2000), *An Index of Ancient Titles; Epithets and Phrases of the Old Kingdom I, England*
- Fischer, H., (1963) ,“A stela of the Heracleopolitan Period at Saqqara: The Osiris *Iti*”, *ZÄS* 90, 35-41
- Ghalioungui, P., (1963), Pharaoh’s Doctors and Their Titles. *Egypt Travel Magazine* 109, pp. 10-17
- Ghalioungui, P., (1983), *The Physicians of Pharaonic Egypt*, Cairo
- Grdseloff, B., (1942), “Le Dieu Dw3w, Patron des oculistes , *ASAE* 41, pp.207-217
- Hassan, S., (1936) *Excavations at Gîza 2*, Cairo
- Hassan, S., (1941) *Excavations at Gîza 3*, Cairo
- Helck, W., (1954), *Untersuchungen zu den Beamtentiteln des ägyptischen alten Reiches* , Glückstadt
- Hirschberg, J., (1899), *Geschichte der Augenheilkunde*, university of California, Los Angeles
- Jonckheere, F., (1951), *Le cadre professionnel et administratif des médecins égyptiens*, *Chronique d’Égypte* 26, Issue 52, Bruxelles
- Jonckheere, F., (1958), *Les médecins de l’Égypte Pharaonique*, Brussels
- Junker, H., (1928), “ Die Stele des Hofarztes *jrj*” *ZAS* 63, Leipzig
- Junker, H., (1943), *Giza VI*, Leipzig
- Krause, A., C., (1933), Ancient Egyptian Ophthalmology, *Bulletin of the Institute of the History of Medicine* vol. 1, No.7, pp.258-76.

- Lefebvre, G., (1956), *Essai sur la médecine égyptienne à l'époque pharaonique*, Paris
- Lepsius, C.R., (1849), *Denkmäler aus Ägypten un Äthiopien* , plates II, Band IV, Berlin
- Lepsius, C.R., (1897), *Denkmäler aus Ägypten un Äthiopien* , Text I, Leipzig
- Mariette, A., (1885), *Les mastabas de l'ancien empire : Fragment du dernier ouvrage*. Paris
- Nunn, J.F., (1996) , *Ancient Egyptian medicine*, University of Oklahoma Press
- Pirenne, J., (1932), *Histoire des institutions et du droit privé de l'ancienne Égypte I*, Bruxelles
- Pollock, W. B., (1945), *The Antiquity of Ophthalmology*
- Quibell, J., (1908), *Excavations at Saqqara II*, Cairo
- Ranke, H., (1935), *Die Ägyptischen Personennamen I*, Glückstadt
- Reisner, G., (1905), *The Hearst medical papyrus: hieratic text in 17 facsimile plates in collotype*, Leipzig
- Reisner, G., (1942), *A History of the Giza Necropolis I*, Cambridge
- Scholtz SK., Mac Morris L., Krogmann F., Attia MSA, Assaf A, et al. (2018) 2400 BC, Egypt: Iry, The First Identified Eye Doctor by Stele Interpretation. *J Eye Stud Treat* 2018(1): 01-04
- Trindade Lopes, H., & Gurgel Pereira, R., (2021), *The Gynaecological Papyrus Kahun*, IntechOpen. doi: 10.5772/intechopen.98039
- Veiga, P., (2009), *Health and Medicine in Ancient Egypt: Magic and Science*, DOI :10.30861/9781407305004, Publisher: Bar Archaeopress , ISBN: 9781407305 004
- Velhagen, K., (1983), *Der Augenarzt*. Volume 9, VEB Georg Thieme, Leipzig, Germany
- Watermann, R., (1958), *Die altägyptischen Augenärzte*, *Sudhoffs Archiv für Geschichte der Medizin und der Naturwissenschaften*, Bd. 42, H. 2
- Watermann, R., (1991), *Augenarzt-Hieroglyphen altägyptische Gräber*, Neusser Druckerei und Verlag, Neuss, Germany
- Wheeler, J. R., (1946), *History of ophthalmology through the ages*, *British Journal of Ophthalmology (BJO)*, 264–275

fig 1




A wall painting in the tomb of the master builder *Ipwy* at Thebes showing an oculist treating the eye of a workman
(Ascaso, Cristóbal, 2009, p. 607, fig.1)

fig.2 a



A blind musician playing a harp, detail of a wall painting from the Tomb of Nakht (TT52).
(Andersen,1997, p.342, fig.7).

fig.2 b



A singing blind harpist from the funerary chapel of *p3 itn m hb*
(Nunn,1996, p.198, fig.9.3)

fig. 2 c



Male musicians with a band tied over their eyes (arrows) ('symbolic blindness')
(Andersen,1997, p.342, fig.8).

fig.3



Ka-aper's statue , detail of the white pupillary reflex in the left eye indicating a mature cataract (Ascaso, and Huerva, 1994, fig. 1 b)

fig.4



Fragment with the title of *w^c.j II* and *lpi* as eye physician and doctor (Quibell,1908, p. 73 , Pl.8 [4])

fig.5

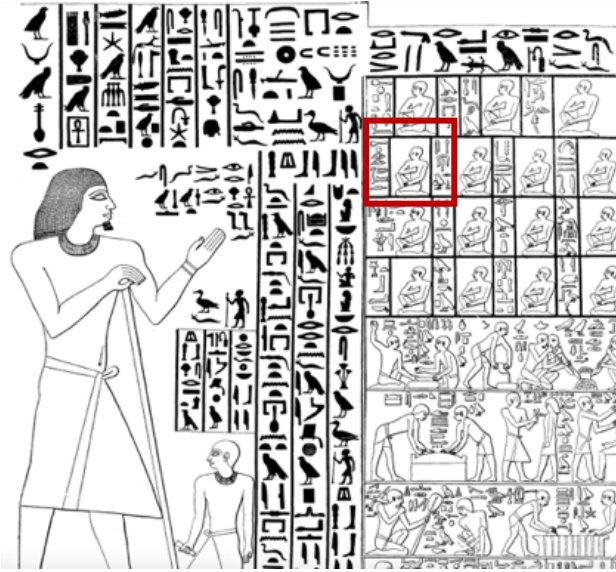
A b



Nj^cnh dw3w in Cairo Museum

(Grdseloff, 1942, p. 215 , fig.30; Ghaliongui, 1983,p.20, fig.10; Borchardt ,1937, no.1452, p. 138, Bl.34)

fig.6 a



Fifteen figures are portrayed before *w p m nfrt* ; the name of *nfrtst* is mentioned among them (Ghalionungui, 1983,p.21; Hassan,1936, fig. 219)

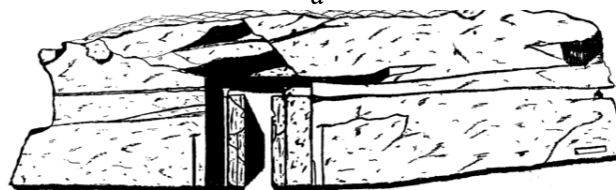b



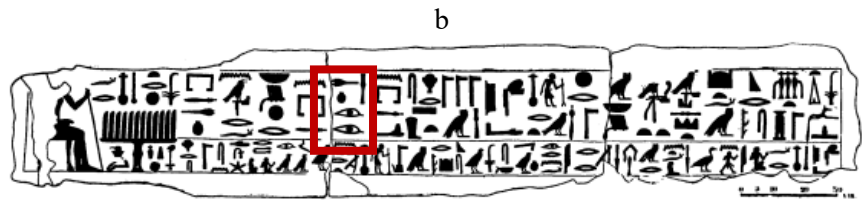
Scene on the eastern wall (Hassan,1936, pl. LXXV)

fig.7

a



Plan and façade of the mastaba of *mdwnfr* (Hassan, 1941, 116, fig.103)

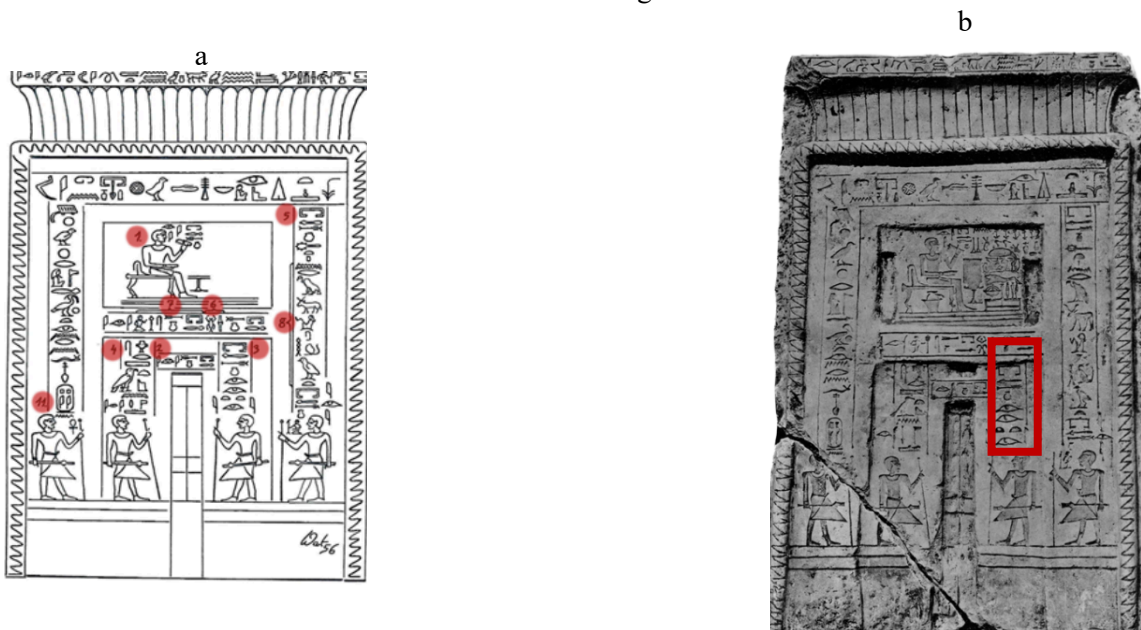


(Hassan,1941, fig.104, p. 117)



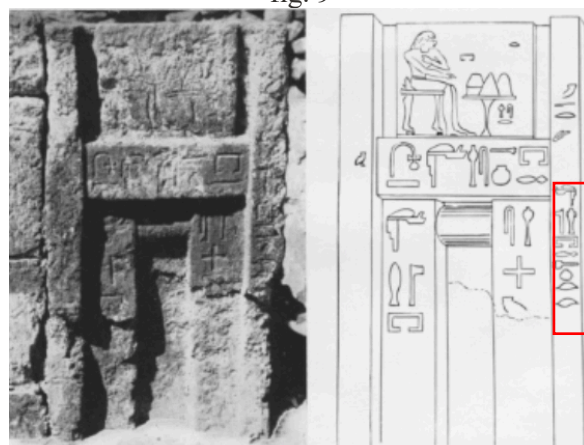
The lintel of the doorway of the mastaba of *mdwnfr*, has offering text dedicated by nephew *smrrj* (Watermann, R, ,1958, Abb. 4; Hassan, 1941 , pl.37; PM III-1, p. 258)

fig.8



False door inscribed for *Trj* (Scholtz , 2018, p.3 , fig.4; Junker, 1928,Taf. II)

fig. 9



A tombstone from the destroyed burial chamber of *W3h dw3.win* Giza (Watermann,1958, Abb. 9 b-c)