

CASE REPORT

Open Access



Thyroid cancer and post thyroidectomy tracheomalacia: algorithm for decoding a diagnostic dilemma!

Shagun B. Shah* and A. Kulkarni

Abstract

Adult tracheomalacia can be caused by long standing goitre or malignant infiltration and has a high morbidity. We anticipated possibility of postoperative tracheomalacia (based on preoperative dynamic cervical sonography and radiographic evidence), in both the cases presented here. A high index of suspicion helped in timely detection of this complication. An algorithm to decode tracheomalacia is constructed here. Elective endotracheal tube (ETT) retention postoperatively, followed by a planned, trial tracheal extubation with gradual ETT withdrawal under bronchoscopic guidance in the OT, several days post-surgery was employed. ETT re-insertion followed by an elective tracheostomy was performed on bronchoscopic confirmation of tracheomalacia.

Keywords: Bronchoscopy fiberoptic, Tracheostomy percutaneous, Thyroid cancer, Tracheomalacia, Ultrasonography

Introduction

Reported incidence of tracheomalacia ranges from 0–10% (Agarwal et al. 2007; Findlay et al. 2011). Aetiology of acquired tracheomalacia includes trauma, surgery (for long standing goitre/esophagectomy/tracheal resection), chronic irritation (prolonged tracheal intubation), infection, changes in mechanics and malignant infiltration (Balasubramanian et al. 2008). We highlight the importance of timely diagnosis based on high index of clinical suspicion in averting airway catastrophe, via two patients undergoing radical thyroidectomies for malignancy at Rajiv Gandhi Cancer Institute and Research Centre. Tracheostomy can then be performed electively avoiding pitfalls of an emergency.

Case report

Case I

A 65-year old male patient had dysphagia to liquids for the past 3 months without hoarseness of voice. Clinical

examination revealed diffuse thyroid enlargement and bilateral cervical lymphadenopathy (3.1 × 2.3 cm level III/IV on cervical CT-scan; mild compression of left lateral trachea wall). Direct laryngoscopy showed mild restriction of left vocal cord movement. His haematological and biochemical investigations were within normal limits. He was posted for total thyroidectomy with bilateral modified neck dissection.

Anaesthesia was induced with IV fentanyl 140 µg, morphine 7.5 mg, etomidate 6 mg, propofol 30 mg and atracurium 60 mg. A 7mmID cuffed flexometallic tube was nasotracheally inserted under C-Mac D-blade video-laryngoscopic guidance. Anaesthesia was maintained with oxygen, medical air and sevoflurane. The tumour was found to be infiltrating the trachea (two rings anteriorly) and had to be shaved off. Neuromuscular blockade was reversed and patient shifted to surgical intensive care unit (SICU), spontaneously breathing on T-piece. Dexmedetomidine infusion provided conscious sedation for endotracheal tube (ETT) retention.

On the first postoperative day, bronchoscope guided extubation was planned in the OT. When the ETT was gradually being withdrawn under bronchoscopic vision, at

* Correspondence: drshagun_2010@rediffmail.com

Department of Anaesthesia, Rajiv Gandhi Cancer Institute and Research Centre, Sector-5, Rohini, Delhi 110085, India

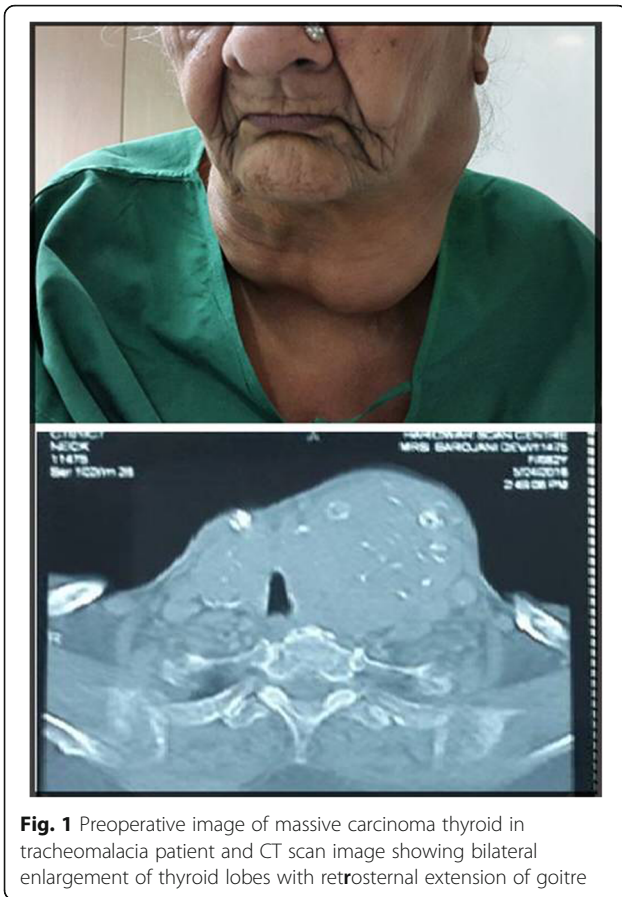

Fig. 1 Preoperative image of massive carcinoma thyroid in tracheomalacia patient and CT scan image showing bilateral enlargement of thyroid lobes with retrosternal extension of goitre

with an extra-long tracheostomy tube. The patient was comfortable (SPO₂ 100%). He was further managed with antibiotics, humidification and vigorous chest physiotherapy and discharged on the 4th postoperative day with tracheostomy tube in situ. After 3 weeks, check bronchoscopy revealed no tracheomalacia, and the tracheostomy tube was successfully removed.

Case II

An 82-year old lady presented with a massive 35-year old goitre with sudden increase in size over the past 1 month (Fig. 1). There was no stridor. On preoperative examination, the trachea could not be palpated. Her haematological and biochemical investigations including the thyroid profile were within normal limits. X-ray revealed tracheal displacement to the right and bilateral enlargement of thyroid lobes causing midtracheal compression. The dimensions, as evidenced in the CT scan (Fig. 1) were left lobe 20 × 10 cm and right lobe 10 × 8 cm with retrosternal extension. On preoperative cervical sonographic examination, left true cord showed paresis with a phonatory gap. Awake fiberoptic intubation after nebulisation with 5 ml 4% lignocaine was planned and a size 7 cuffed nasal flexometallic ETT was railroaded over the bronchoscope. Anaesthesia was induced with intravenous fentanyl 100 µg, propofol 30 mg, atracurium 50 mg and maintained with medical air, oxygen, BIS-guided sevoflurane, morphine 4.5 mg and peripheral nerve stimulator guided atracurium infusion. The surgery lasted for 3 h. She was electively ventilated post operatively (pressure support ventilation for 24 h followed by T-piece trial for next 24 h preceding extubation). After 48 h, check fiberoptic bronchoscopy before extubation revealed more than 50% collapse of upper tracheal lumen. Henceforth, she was electively tracheostomized and

a point 2 cm above the carina, a collapse of the posterior tracheal wall was visible on expiration as it ballooned into the tracheal lumen. The ETT was re-inserted beyond the point of collapse and a percutaneous tracheostomy was performed under local anaesthesia to replace the ETT

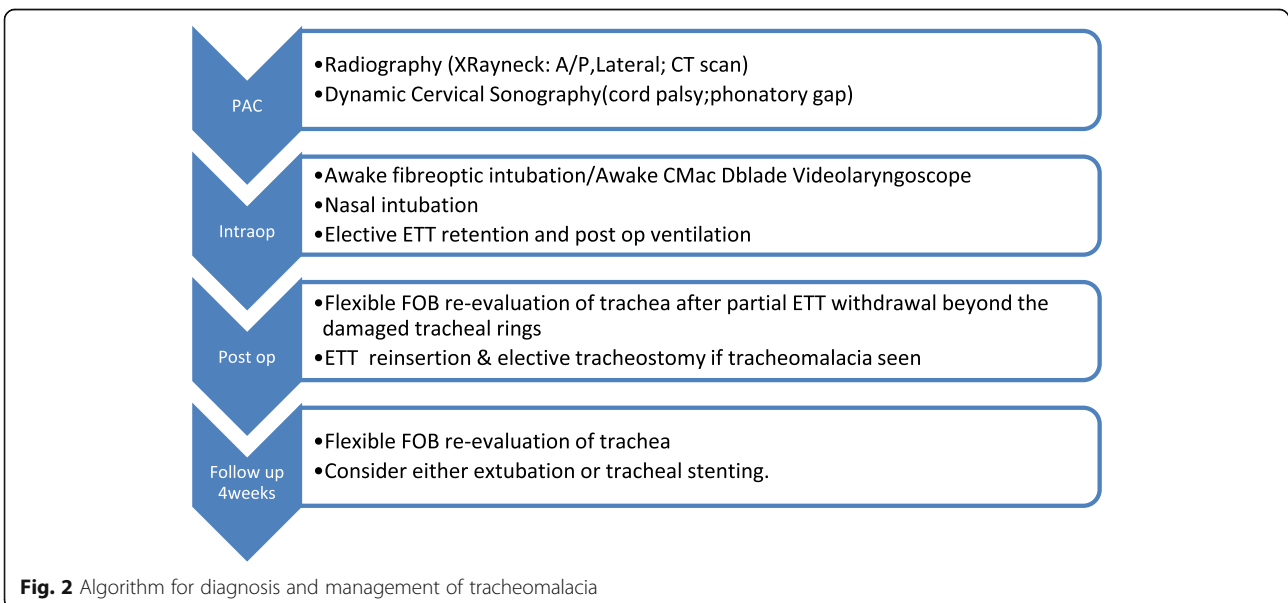


Fig. 2 Algorithm for diagnosis and management of tracheomalacia

discharged after 2 weeks, with the tracheostomy tube in situ, and was lost to follow-up.

Discussion

A C-Mac D-Blade videolaryngoscope (Shah et al. 2016) was utilized anticipating difficult airway in the first case, since the papillary thyroid cancer was infiltrative with bilateral cervical lymphadenopathy. In case-II an awake fiberoptic bronchoscopy was planned in anticipation of a difficult intubation due to the colossal goitre, radiographic evidence of tracheal compression and deviation and sonographic evidence of left vocal cord paresis.

Anticipating postoperative ETT-retention, endotracheal intubation was done nasally in both patients and postoperative dexmedetomidine infusion employed.

Preoperative sonographic vocal cord movement analysis is an excellent dynamic and noninvasive indicator of vocal cord paresis due to recurrent laryngeal nerve damage (Tsui et al. 2012; Wang et al. 2012). It also gauges the dimensions of the thyroid gland and trachea, tracheal deviation and compression and even tracheomalacia at end-expiration in a spontaneously breathing patient (Wang et al. 2012). We recommend its regular use to supplement direct laryngoscopic and radiographic findings.

Tracheomalacia results in flaccidity of the C-shaped tracheal cartilaginous rings and broadening of the posterior membranous wall with decreased anterior-posterior tracheal diameter (scabbard trachea). Expiratory prolapse of membranous trachea is more pronounced during coughing and straining and causes expiratory airway obstruction and carbon dioxide retention (Agarwal et al. 2007; Shen et al. 2004; Mayilvaganan and Agarawal 2014). Malignant infiltration of the trachea caused tracheomalacia in our first patient while external compression of trachea due to a four-decade-old goitre was the cause in our second patient. Owing to the rarity of this dreaded complication, diagnosis entails a high index of clinical suspicion. An algorithm to decode the diagnostic dilemma called tracheomalacia has been chalked out here (Fig. 2). Anticipation of this problem prompted us not to extubate the patient postoperatively and to undertake the extubation under bronchoscopic guidance the following day. This prevented a cycle of extubations and re-intubations with potential respiratory distress and de-oxygenation. Only after awake fiberoptic bronchoscopic confirmation of diagnosis of tracheomalacia the decision of percutaneous tracheostomy was undertaken.

Acquired tracheomalacia is treated with internal/external stenting or tracheostomy (Mayilvaganan and Agarawal 2014). Tracheostomy effectively counters tracheomalacia by forming a conduit across the focal segment of malacia and splinting the airway open (Mayilvaganan and Agarawal 2014). Recurrent laryngeal nerve palsy and tracheomalacia

were the two factors prompting a planned tracheostomy in both our patients.

Conclusion

Adult tracheomalacia, coupled with airway infection in the post-surgical setting, has high mortality. Extubation under bronchoscopic guidance in the OT should be planned keeping a high index of clinical suspicion (seconded by dynamic cervical sonography during preanaesthetic checkup and radiography) for tracheomalacia in radical thyroidectomies. On bronchoscopic visualization of tracheomalacia after partial ETT withdrawal beyond the damaged tracheal rings, the ETT should be reinserted and elective tracheostomy performed. Flexible fiberoptic bronchoscopic re-evaluation of trachea should be performed 4 weeks later to consider either extubation or tracheal stenting.

Abbreviations

ETT: Endotracheal tube; FOB: Fiberoptic bronchoscope; SICU: Surgical intensive care unit

Acknowledgements

None

Authors' contributions

SS contributed to planning the anaesthetic technique and preanaesthetic checkup review, performance of videolaryngoscopy and intubation in second patient, data collection and manuscript drafting and preparation. AK contributed to planning the anaesthetic technique, performance of videolaryngoscopy and intubation in second patient, photography (data collection) and preparation of the manuscript. The authors read and approved the final manuscript.

Funding

No sources of funding

Availability of data and materials

Not applicable

Ethics approval and consent to participate

Not applicable

Consent for publication

The manuscript contains data from two patients, and consent to publish has been obtained from both the patients.

Competing interests

The authors declare that they have no competing interests.

Received: 14 November 2019 Accepted: 2 March 2020

Published online: 11 March 2020

References

- Agarwal A, Mishra AK, Gupta SK (2007) High incidence of tracheomalacia in longstanding goiters: experience from an endemic goiter region. *World J Surg* 31:832–837
- Balasubramanian S, Kannan R, Balakrishnan K (2008) Post operative tracheomalacia after surgery on the thyroid gland and aerodigestive tract. *Int J Surg* 19(2):432–437
- Findlay JM, Sadler GP, Bridge H (2011) Post-thyroidectomy tracheomalacia: minimal risk despite significant tracheal compression. *Br J Anaesth* 106:903–906
- Mayilvaganan S, Agarawal A (2014) Management of post-thyroidectomy tracheomalacia. *World J Endoc Surg* 6:96–98
- Shah SB, Hariharan U, Bhargava AK (2016) C Mac D blade: Clinical tips and tricks. *Trends in Anaesthesia and Critical Care* 6:6–10

- Shen WT, Kebebew E, Duh QY (2004) Predictors of airway complications after thyroidectomy for substernal goiter. *Arch Surg* 139:656–659
- Tsui PH, Wan YL, Chen CK (2012) Ultrasound imaging of the larynx and vocal folds: recent applications and developments. *Curr Opin Otolaryngol Head Neck Surg* 20(6):437–442
- Wang CP, Chen TC, Yang TL, Chen CN, Lin CF, Lou PJ, Hu YL (2012) Transcutaneous ultrasound for evaluation of vocal fold movement in patients with thyroid disease. *Eur J Radiol* 81(3):288–291

Publisher's Note

Springer Nature remains neutral with regard to jurisdictional claims in published maps and institutional affiliations.

Submit your manuscript to a SpringerOpen[®] journal and benefit from:

- ▶ Convenient online submission
- ▶ Rigorous peer review
- ▶ Open access: articles freely available online
- ▶ High visibility within the field
- ▶ Retaining the copyright to your article

Submit your next manuscript at ▶ [springeropen.com](https://www.springeropen.com)
