

ORIGINAL ARTICLE

Open Access



Ultrasound-guided erector spinae block for postoperative analgesia in thoracotomy patients: a prospective, randomized, observer-blind, controlled clinical trial

Mohammed Gomaa Sobhy^{*} , Ahmed Mostafa Abd El-Hamid, Dina Hosni Elbarbary and Mohamed Fouad Elmeliegy

Abstract

Background and objectives: Thoracotomy is considered the most painful of surgical procedures and providing adequate analgesia is the onus for all anaesthesiologists. This study investigated the efficacy of the ultrasound-guided erector spinae plane (ESP) block in analgesia after thoracotomies.

Patients and methods: Sixty patients with American Society of Anesthesiology physical status (ASA-PS) I–IV, aged more than 18 years were allocated to two groups, ESP group which received the ESP block and C (control) group with no block. Single-shot U/S-guided ESP block with 20 ml 0.25% bupivacaine at the 5th thoracic vertebral level was performed preoperatively in the ESP group. Postoperative 24 h morphine consumption and pain scores were compared between the groups. Also, the side effects of opioid usage were compared.

Main results: Postoperative morphine consumption was 22.06 ± 6.24 mg in the ESP group and 30.6 ± 6.23 mg in the C group ($p < 0.001$). Results showed that there was a significant difference between both groups in favour of the ESP group regarding visual analogue score (VAS) at rest and with coughing ($p < 0.001$).

Conclusion: Our study findings show that US-guided ESP block exhibits a significant analgesic effect in patients undergoing thoracotomy surgery.

Trial registration: ClinicalTrials.gov, [NCT03749395](https://clinicaltrials.gov/ct2/show/study/NCT03749395). Registered 13 November 2018

Keywords: Erector spine block, Thoracotomy, Postoperative pain

Introduction

Thoracotomy is considered one of the most painful of surgical procedures, and providing effective analgesia is the responsibility for all anaesthesiologists. Ineffective relief of pain impedes deep breathing, coughing, and mobilization culminating in atelectasis and pneumonia (Mesbah et al. 2016).

Pain after thoracotomy arises from *nociceptive* and *neuropathic* mechanisms which may originate from somatic and visceral afferents. Pain can also be *referred*. The

intercostal nerves convey *nociceptive somatic* afferents to the ipsilateral dorsal horn of the spinal cord (T4–T10). The afferents are then transmitted to the limbic system and somatosensory cortices via the contralateral anterolateral system of the spinal cord. The phrenic and vagus nerves convey *nociceptive visceral* afferents after an injury to the bronchi, visceral pleura, and pericardium. *Neuropathic* pain, after intercostal nerve injury, results in the paradox of reduced sensory input (from touch, temperature, and pressure) with hypersensitivity (dysaesthesia, allodynia, hyperalgesia, and hyperpathia) (Kehlet et al. 2006).

* Correspondence: dr.mohammedgomaa@gmail.com
Faculty of Medicine, Benha University, Benha, Kalyobia 13518, Egypt

In adults and older children, the severe complications of post-thoracotomy pain have brought about an aggressive search to improve treatment modalities, including regional techniques, which have shown great benefits over systemic anaesthesia, with a comparable or improved safety profile (Davies et al. 2006).

Thoracic epidural analgesia (TEA) and thoracic paravertebral block (TPVB) are currently the recommended first-line techniques for use in post-thoracotomy pain management. However, they can be technically challenging to perform and are associated with a significant failure rate (up to 15% in TEA) (Romero et al. 2013).

Initial management usually includes NSAIDs, opioids, neuropathic medications, and topical local anaesthetics. A variety of interventional techniques has been portrayed for the treatment of refractory pain, including intercostal nerve blocks, thoracic paravertebral blocks, epidural steroid injections, thoracic sympathetic blocks, pulsed radio-frequency ablation of the dorsal ganglion, and spinal cord stimulation (Ayad and El Masry 2012). Recently, there has been a great focus in using myofascial plane blocks for postoperative analgesia for open abdomino-thoracic procedures (Steinthorsdottir et al. 2014).

The erector spinae plane (ESP) block is a newly described technique for managing post-thoracotomy pain and has numerous advantages that make it an attractive alternative technique. An ultrasound-guided ESP block was firstly reported in 2016. The ESP block injects a local anaesthetic around the erector spinae muscle at approximately the level of the T5. It may be able to block the dorsal and ventral rami of the thoracic spinal nerves. The first report of the successful use of this procedure was in 2016; the block was used to manage thoracic neuropathic pain in a patient with metastatic disease of the ribs and rib fractures (Forero et al. 2016). Since then, the block has been reported to have been used successfully in a multitude of procedures including Nuss procedure, thoracotomies, percutaneous nephrolithotomies, ventral hernia repairs, and even lumbar fusions (Yoshizaki et al. 2019; Raft et al. 2019; Kim et al. 2018; Chin et al. 2017a; Chin and Lewis 2019).

Aim of the study

This study aimed to compare between the new U/S ESP and the conventional methods of systemic analgesics in adult patients undergoing elective thoracotomy surgery regarding postoperative morphine consumption, VAS scores at rest and during coughing, morphine-related side effects, and hospital stay.

Materials and methods

Study design

After Institutional Ethical Committee approval, which carries the number 1017-11/7/2018, the study was designed as a prospective, randomized, observer-blind,

controlled clinical trial and was conducted in Benha University Hospital. This trial was registered on [Clinical-Trials.gov](https://clinicaltrials.gov) and was assigned an NCT number, [Clinical-Trials.gov](https://clinicaltrials.gov) ID NCT03749395. Written informed consent was obtained from all patients both for the interventions and enrolment into the study.

Sixty patients with American Society of Anesthesiologists (ASA) physical status I–IV, aged more than 18 years, who were scheduled for an elective thoracotomy between December 2018 and November 2019, were included in the study. The exclusion criteria included refusal of the patient to provide written consent, age less than 18, coagulation disorders, known allergy to study drugs, obesity (body mass index (BMI) > 40 kg/m²), infection at the injection site, and pregnant females.

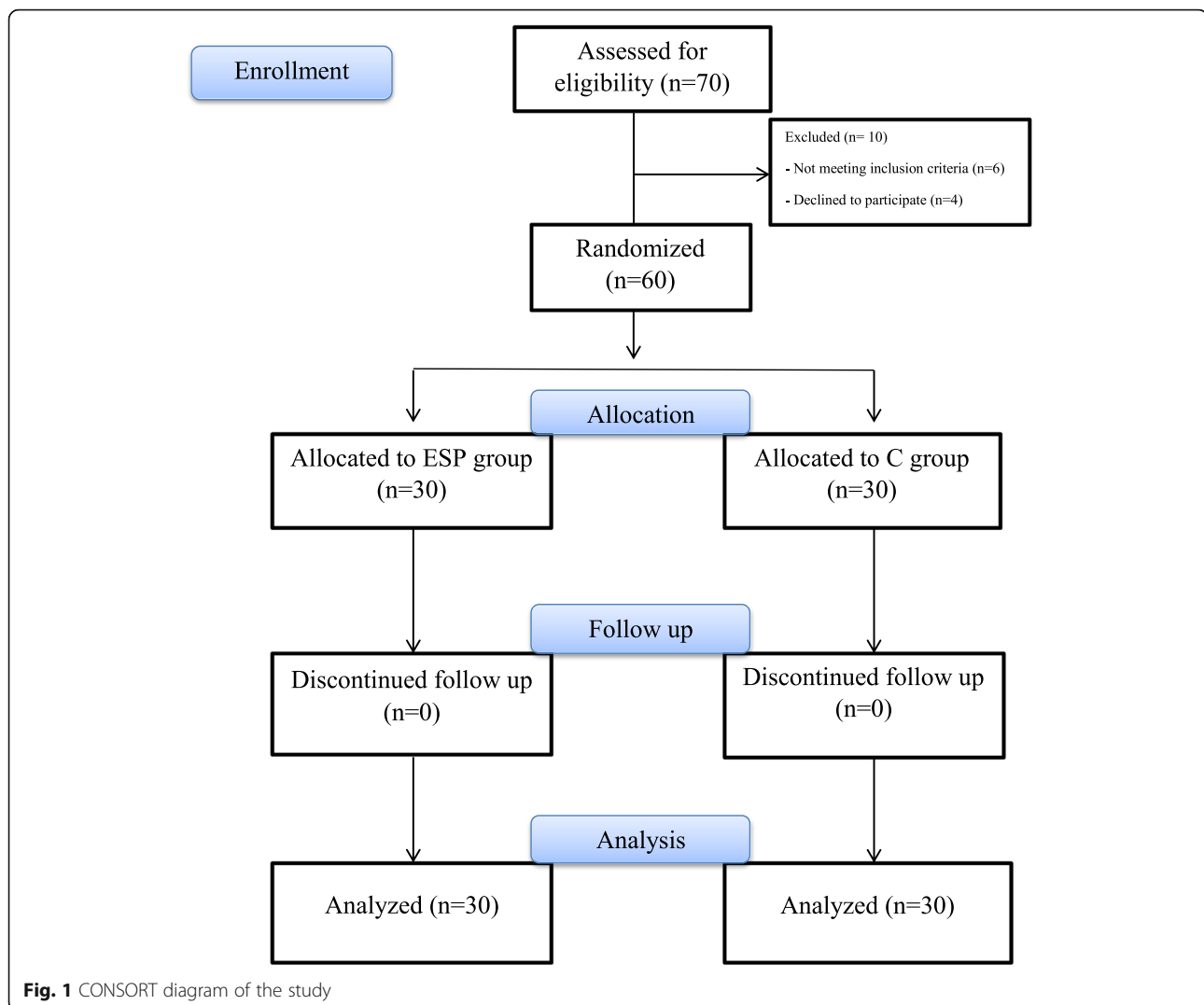
Patients were randomly chosen to receive either ESP plus conventional opioid analgesics (group ESP, $n = 30$) or receive only the conventional opioid analgesics (group C, $n = 30$) by a random sequence number generated by the computer kept in sealed envelopes. The sealed envelopes will be opened on the day of surgery when the patient in the operation room and participants will receive either ESP or not as per the envelope. The observer anaesthesiologist postoperative will be blinded to which group the patient belongs. The study design is demonstrated as a flow chart in Fig. 1.

Application of block interventions

Patients of the ESP group received the ESP block just before induction of general anaesthesia. The ultrasound machine used for the block was (General Electric; GE, “LOGIQ P5” ultrasound machine) with 6–13 MHz probes and colour Doppler imaging capability. The ESP block was performed as it was described by Forero et al. (Forero et al. 2016). The patient was placed in a sitting position and the ultrasound probe placed in a longitudinal orientation 3 cm lateral to the T5 spinous process. The needle was inserted in a cephalad-to-caudad direction until the tip lay deep to erector spinae muscles, as evidenced by the visible linear spread of fluid beneath muscle upon injection. A total of 20 mL of 0.25% bupivacaine was injected here. The needle used for performing the block was a 22-gauge, 50-mm echogenic needle (Stimuplex D; B Braun, Germany).

Anaesthesia application

All patients received pre-oxygenation with O₂ 100% for 3 min. Anaesthesia was induced by using fentanyl 1 µg/kg, propofol 1.5–2 mg/kg, and atracurium 0.5 mg/kg was used for muscle relaxation. Anaesthesia was maintained by controlled ventilation with oxygen and air (50:50) with a target of EtCO₂ ≈ 35–40 mmHg, isoflurane 1:1.5 MAC, 0.5 µg/kg fentanyl was given intraoperatively when either heart rate or NIBP report an increase by more



than 20% of the basal records. Anaesthesia was discontinued, and tracheal extubation was done once the patient fulfilled the extubation criteria.

Evaluation of analgesia

The quality of analgesia based on visual analogue scale (VAS) pain scores which were assessed every 6 h for 24 h. The score is determined by measuring the distance on the 10-cm line between the “no pain” and the “worst possible pain”, providing a range of scores from 0 to 10. A higher score indicates greater pain intensity, no pain (0) and severe pain (10).

Routine analgesia protocol and rescue analgesic

Patients received analgesic according to the local institutional protocol as the following (paracetamol 1 gm IV infusion/8 h, ketorolac 30 mg IM/12 h) as 2 components of multimodal anaesthesia regimen for postoperative pain control. Postoperative rescue analgesia with

intravenous morphine sulphate 3 mg morphine sulphate as a bolus dose that could be repeated every 5 min with a maximum dose of 15 mg per 4 h or 45 mg per 24 h was employed if VAS > 4. The morphine titration protocol was suspended if one or more of the following points was recorded: SPO₂ < 95%, respiratory rate < 10/min, the development of sedation (Ramsay sedation scale > 2), development of adverse effects (allergy, marked itching, excessive vomiting, and hypotension with systolic blood pressure ↓ by 20% of baseline values), or attaining an adequate level of analgesia.

Outcome measures

The primary outcome measure at the commencement of the study was total postoperative morphine consumption in the first 24 h. Secondary outcome measures were the VAS scores at five different time-points (0 “on arrival”, 6th hour, 12th hour, 18th hour, and 24th hour) at rest and during coughing, the incidence of complications

Table 1 Demographic characteristics and duration of surgery

		Group ESP	Group C	Test	<i>p</i> value
Age (years)		50.66 ± 8.01	50.2 ± 7.64	<i>t</i> = 0.23	0.81
Weight (kg)		81.63 ± 5.45	82.4 ± 6.02	<i>t</i> = 0.51	0.6
BMI (kg/m ²)		25.72 ± 1.62	25.79 ± 2.88	<i>t</i> = 0.11	0.9
Height (cm)		178.13 ± 5.15	179.1 ± 5.22	<i>t</i> = 0.72	0.47
Sex	M	18 (60%)	17 (56.66%)	$\chi^2 = 0.06$	0.79
	F	12 (40%)	13 (43.33%)		
ASA	I	5 (16.66%)	4 (13.33%)	$\chi^2 = 0.13$	0.93
	II	19 (63.33%)	20 (66.66%)		
	III	6 (20%)	6 (20%)		
Duration of surgery (min)		136.33 ± 18.93	131.33 ± 20.16	<i>t</i> = 0.99	0.32

related to the technique, morphine-related side effects (nausea, vomiting, pruritus, and excessive sedation) were reported and patients satisfaction with postoperative analgesia after 72 h postoperatively according to a satisfaction score (poor = 0, fair = 1, good = 2, excellent = 3) and total postoperative hospital stay.

Sample size

The sample size was calculated using G*Power© software version 3.1.7 (Institute of Experimental Psychology, Heinrich Heine University, Dusseldorf, Germany). Depending on previous research results with two-sided (two tails) type I error 0.05 and power of 80%, effect size (*d*) factor 0.8, each group should involve ≥ 27 subjects.

Statistical analysis

The results were compared using Statistical Package for the Social Sciences (SPSS Inc., Chicago, IL, USA) version 20. Parametric normally distributed numerical was presented as (mean ± SD) and differences between groups were compared using Student's *t* tests, non-parametric data was presented as (median and interquartile range), and differences between groups were compared using Mann-Whitney *U* test, categorical data were presented as number and percentage, and intergroup comparison was performed using Chi-square test. Statistically, we consider the results as significant if the *p* value was less than 0.05, and the confidence interval was 95%.

Table 2 Surgery type in both groups

Surgery Type	Group ESP	Group C	Test	<i>p</i> value
Pulmonary resection (<i>pneumonectomies, lobectomies, segmentectomies</i>)	7 (23.33%)	10 (33.33%)	$\chi^2 = 1.59$	0.8
Decortications	5 (16.66%)	3 (10%)		
Lung cyst excision	3 (10%)	2 (6.66%)		
Mediastinal mass	2 (6.66%)	1 (3.33%)		
Others	13 (43.33%)	14 (46.66%)		

Results

In this study, 70 patients were screened for eligibility, ten patients were excluded from the study, 6 of them had not met the inclusion criteria, and 4 of them declined to participate. The remaining 60 patients were allocated equally into two groups: ESP (study) group and C (control) group.

Demographic characteristics of the enrolled participants

Regarding age, weight, BMI, height, sex, and ASA status of enrolled patients, this study showed no significant statistical differences between both groups with *P* value > 0.05 (Table 1).

Duration of the surgery

Regarding the duration of surgery, the mean in group ESP was 136.33 ± 18.93, and in group C was 131.33 ± 20.16, which is statistically non-significant (*p* = 0.32) (Table 1).

Surgery type

Regarding the type of surgery, there are no statistically significant differences between both groups (*p* = 0.8) (Table 2).

Morphine consumption

By calculating the total morphine consumption in milligrammes in the first 24 h postoperatively, the current study found that there was a highly significant difference

Table 3 Morphine consumption, hospital stay, and satisfaction score

	Group ESP	Group C	Test	<i>p</i> value
Morphine consumption (mg)	22.06 ± 6.24	30.6 ± 6.23	<i>t</i> = 5.2	< 0.001
Hospital stay	3 ± 0.98	3.9 ± 0.95	<i>t</i> = 3.58	< 0.001
Satisfaction score	3 [2–3]	2 [2–2.75]	<i>U</i> test = 323	0.06

between both groups in favour of the ESP group with *p* value < 0.001 as demonstrated in Table 3.

Hospital stay and satisfaction score

When both groups were compared regarding the duration of hospital stay in days, there were highly significant differences in favour of the ESP group with *p* value < 0.001. But regarding patient satisfaction, there were no significant differences with (*p* = 0.06) as demonstrated in Table 3.

VAS score during rest (VASR)

Regarding VAS scores obtained during rest (VASR) in both groups which monitored at 0 times (on arrival to ICU), 6, 12, 18, and 24 h postoperative, we found that there were significant differences in favour of ESP group with *p* value < 0.04 at 0 times and *p* value < 0.001 at the other times. This difference is shown in Fig. 2.

VAS score with coughing (VASC)

When we compare VAS scores during coughing (VASC) in both groups at the same preset times as in VASR, we found that VAS scores are less in the ESP group. The *p* value was < 0.001 at 0 time, 18, and 24 h postoperative. And it was 0.001 at the 6th hour and 0.006 at 12th hour postoperative. These data are demonstrated in Fig. 3.

Side effects of opioid usage and block technique

The results of this study showed that there was an obvious decrease in the incidence of side effects of opioid usage in the ESP group. For example, two patients in the ESP group suffered from nausea; in contrast, there were nine patients in the C group with a *p* value = 0.01. Regarding the incidence of hemodynamic changes due to the block or morphine usage, there was no significant difference

between both groups. We recorded hypotension (systolic pressure < 90 mmHg) in 2 patients and five patients in the ESP group and group C, respectively. Also, we recorded bradycardia (heart rate < 60 beats/min) in two patients and five patients in the ESP group and group C, respectively. Regarding other side effects, including vomiting, pruritus, and sedation, data is demonstrated in Table 4.

Discussion

Regional anaesthetic techniques are a crucial component of multimodal analgesia after thoracotomy (Gerbershagen et al. 2013). Traditional regional anaesthesia techniques such as thoracic epidural analgesia (TEA) and thoracic paravertebral blockade (TPVB) are commonly used, but these techniques have many complications such as the complexity of the block, hemodynamic effects, and risk of bleeding and hematoma formation. On the other hand, the ESP block targets a myofascial plane located between the erector spinae muscles and the posterior aspect of the transverse processes. The needle does not enter the paravertebral space and remains away from the neuroaxis, discrete plexi or nerves, and major blood vessels (Adhikary et al. 2018a).

Ultrasound-guided ESP block is a myofascial plane block that provides analgesia for thoracic or abdominal segmental innervation depending on the level of the injection site (Chin et al. 2017a). When ESP block is performed at the level of the T4, local anaesthetic (LA) spreads in a cranio-caudal pattern over several levels. The LA agent penetrates anteriorly through the costovertebral foramina and enters the thoracic paravertebral space. Herein, it can block the ventral and dorsal rami of spinal nerves and rami communicants (El-Boghdady and Pawa 2017). When ESP block is performed at the level of T5, reports have shown that LA spreads

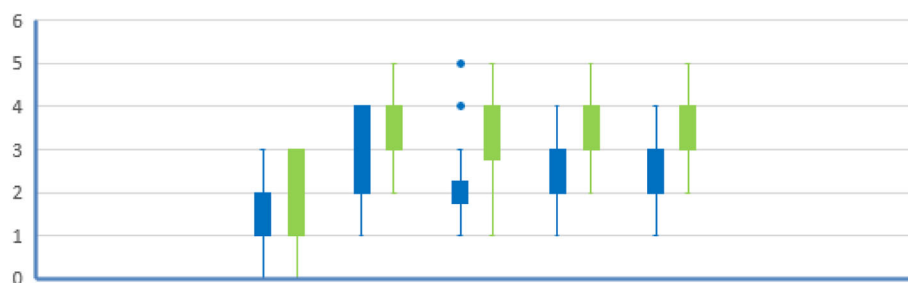


Fig. 2 VASR at 0, 6, 12, 18, and 24 h in both groups. Blue box, ESP group; green box, C group

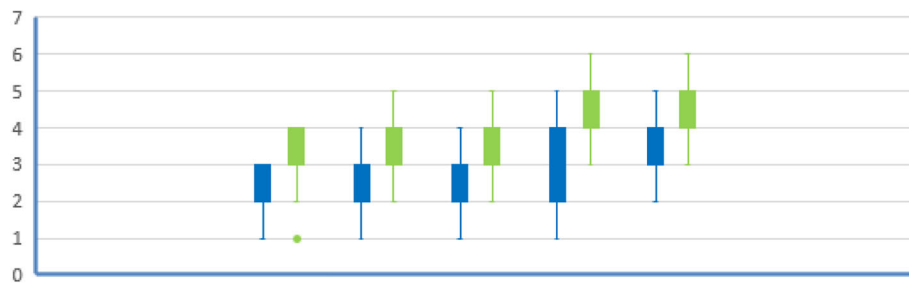


Fig. 3 VASc at 0, 6, 12, 18, and 24 h in both groups. Blue box, ESP group; green box, C group

cranio-caudally between T3 to L2 (Adhikary et al. 2018b). The ESP plane is larger than the epidural space as the erector spinae muscle runs along the length of the thoraco-lumbar spine, thus providing extensive cranio-caudal spread (Forero et al. 2016).

This study demonstrated that the ESP block is an excellent technique in reducing pain and morphine consumption in patients scheduled for thoracotomy surgery. Results showed that there is a significant decrease in total morphine consumption in the first 24 h postoperatively in the ESP group. Also, when comparing VASc score during rest and coughing, results showed that there is a significant decrease in VASc and VASR at 6, 12, 18, and 24 h postoperatively in the ESP group. Regarding the side effects of opioid usage in the ESP group, there were two patients, one patient and two patients who suffer from nausea, vomiting, and sedation, respectively. Only five patients suffered from pain during ESP block, and this is the only registered side effect.

Since the ESP block is a relatively new regional analgesia technique, there is a paucity of well-designed randomized controlled trials investigating its efficacy in postoperative analgesia after thoracotomy surgery.

Results of this study come in agreement with results showed by Krishna et al. (Krishna et al. 2019), who found that patients in the ESP group had a significantly higher duration of analgesia compared with the control group. Besides, they found that the ESP group had reduced perioperative total opioid usage as we found in our study.

Similarly, Macaire et al. (Macaire et al. 2019) have demonstrated that the ESP block group received a significantly reduced amount of opioids both intraoperatively and 48 h postoperatively, therefore promoting faster recovery in the postoperative period.

Also, the results of our study are supported by the findings of the pooled review done by Tsui et al. (Tsui et al. 2018). It is a review of 85 publications with 242 cases between 2016 and 2018. They found that there was a reduction in opioid use in 76.0% of cases.

Also, the results of this study regarding pain control come in agreement with many previous reports (Forero et al. 2016; Chin et al. 2017a; Leyva et al. 2018; Chin et al. 2017b; Forero et al. 2017; Restrepo-Garces et al. 2017; Ohgoshi et al. 2018).

There are some limitations to this research. First, it was only a single-blinded study. No other block group was established, which may be considered a limitation. Since patients know whether or not they have received an injection for ESP block, the placebo effect could not be minimized. We think these limitations could and should be considered in future studies.

Conclusion

Our study shows that ultrasound-guided single-shot ESP block provided adequate analgesia following thoracotomy surgery and reduced morphine consumption significantly compared to the control group. Further studies comparing different regional anaesthetic techniques are needed to identify the optimal analgesic technique for thoracotomy surgery.

Acknowledgements

No acknowledgements.

Authors' contributions

M.G.S. and A.M.A. conceived and planned the study. M.G.S. and D.H.E. worked out almost all of the technical details and collect data throughout the study. M.F.E. verified the analytical methods. A.M.A., D.H.E., and M.F.E. processed the data, performed the analysis, drafted the manuscript, and designed the figures. All authors discussed the results and contributed to the final manuscript. The author(s) read and approved the final manuscript.

Funding

None.

Table 4 Side effects of opioid usage and block technique

Side effects	Group ESP	Group C	Test	<i>p</i> value
Nausea	2 (6.66%)	9 (30%)	$Z = 2.33$	0.01
Vomiting	1 (3.33%)	6 (20%)	$Z = 2.01$	0.04
Pruritus	2 (6.66%)	5 (16.66%)	$Z = 1.2$	0.22
Sedation	2 (6.66%)	8 (26.66%)	$Z = 2.07$	0.03
Hypotension	2 (6.66%)	5 (16.66%)	$Z = 1.2$	0.22
Bradycardia	2 (6.66%)	5 (16.66%)	$Z = 1.2$	0.22
Pain on injection	5 (16.66%)	0 (0%)	$Z = 2.33$	0.01

Availability of data and materials

Data supporting findings can be obtained from the corresponding author.

Ethics approval and consent to participate

The Research Ethics Committee at Faculty of Medicine, Benha University (REC—FOMBU) has approved this study at 11 July 2018 with the number 1017-11/7/2018, and written informed consent was obtained from all patients enrolled in this study.

Consent for publication

Not applicable.

Competing interests

The authors declare that they have no competing interests.

Received: 27 March 2020 Accepted: 27 July 2020

Published online: 05 August 2020

References

- Adhikary SD, Bernard S, Lopez H, Chin KJ (2018a) Erector spinae plane block versus retrolaminar block: a magnetic resonance imaging and anatomical study. *Reg Anesth Pain Med*
- Adhikary SD, Pruet A, Forero M, Thiruvengatarajan V et al (2018b) Erector spinae plane block as an alternative to epidural analgesia for postoperative analgesia following video-assisted thoracoscopic surgery: a case study and a literature review on the spread of local anaesthetic in the erector spinae plane. *Indian J Anaesth* 62(1):75
- Ayad AE, El Masy A (2012) Epidural steroid and clonidine for chronic intractable post-thoracotomy pain: a pilot study. *Pain Pract* 12:7–13
- Chin KJ, Adhikary S, Sarwani N, Forero M (2017a) The analgesic efficacy of pre-operative bilateral erector spinae plane (ESP) blocks in patients having ventral hernia repair. *Anaesthesia*. 72(4):452–460
- Chin KJ, Lewis S (2019) Opioid-free analgesia for posterior spinal fusion surgery using erector spinae plane (ESP) blocks in a multimodal anesthetic regimen. *Spine*. 44(6):E379–E383
- Chin KJ, Malhas L, Perlas A (2017b) The erector spinae plane block provides visceral abdominal analgesia in bariatric surgery: a report of 3 cases. *Reg Anesth Pain Med* 42:372–376
- Davies RG, Myles PS, Graham JM (2006) A comparison of the analgesic efficacy and side-effects of paravertebral vs epidural blockade for thoracotomy—a systematic review and meta-analysis of randomized trials. *Br J Anaesth* 96: 418–426
- El-Boghdady K, Pawa A (2017) The erector spinae plane block: plane and simple. *Anaesthesia* 72(4):434–438
- Forero M, Adhikary SD, Lopez H, Tsui C, Chin KJ (2016) The Erector Spinae Plane Block: A Novel Analgesic Technique in Thoracic Neuropathic Pain. *Reg Anesth Pain Med* 41(5):621–627
- Forero M, Rajarathinam M, Adhikary S et al (2017) Continuous erector spinae plane block for rescue analgesia in thoracotomy after epidural failure: a case report. *A A Case Rep* 8:254–256
- Gerbershagen HJ, Aduckathil S, van Wijck AJ, Peelen LM, Kalkman CJ, Meissner W (2013) Pain intensity on the first day after surgery: a prospective cohort study comparing 179 surgical procedures. *Anesthesiology*. 118(4):934–944
- Kehlet H, Jensen TS, Woolf CJ (2006) Persistent postsurgical pain: risk factors and prevention. *Lancet* 367:1618–1625
- Kim E, Kwon W, Oh S, Bang S (2018) The erector spinae plane block for postoperative analgesia after percutaneous nephrolithotomy. *Chin Med J* 131(15):1877–1878
- Krishna SN, Chauhan S, Bhoi D, Kaushal B, Hasija S, Sangdup T, Bisoi AK (2019) Bilateral erector spinae plane block for acute post-surgical pain in adult cardiac surgical patients: a randomized controlled trial. *J Cardiothorac Vasc Anesth* 33(2):368–375
- Leyva F, Mendiola W, Bonilla A, Cubillos J, Moreno D, Chin K (2018) Continuous erector spinae plane (ESP) block for postoperative analgesia after minimally invasive mitral valve surgery. *J Cardiothorac Vasc Anesth* 32(5):2271–2274. <https://doi.org/10.1053/jjvca.2017.12.020>
- Macaire P, Ho N, Nguyen T, Nguyen B, Vu V, Quach C et al (2019) Ultrasound-guided continuous thoracic erector spinae plane block within an enhanced recovery program is associated with decreased opioid consumption and improved patient postoperative rehabilitation after open cardiac surgery—a patient-matched, controlled before-and-after study. *J Cardiothorac Vasc Anesth* 33(6):1659–1667. <https://doi.org/10.1053/jjvca.2018.11.021>
- Mesbah A, Yeung J, Gao F (2016) Pain after thoracotomy. *BJA Education* 16(1):1–7. <https://doi.org/10.1093/bjaceaccp/mkv005>
- Ohgoshi Y, Ikeda T, Kurahashi K (2018) Continuous erector spinae plane block provides effective perioperative analgesia for breast reconstruction using tissue expanders: a report of two cases. *J Clin Anesth* 44:1–2. <https://doi.org/10.1016/j.jclinane.2017.10.007>
- Raft J, Chin KJ, Belanger ME, Clairoux A, Richebé P, Brulotte V (2019) Continuous erector spinae plane block for thoracotomy analgesia after epidural failure. *J Clin Anesth* 54:132–133
- Restrepo-Garcés CE, Chin KJ, Suarez P et al (2017) Bilateral continuous erector spinae plane block contributes to effective postoperative analgesia after major open abdominal surgery: a case report. *AA Case Rep* 9:319–321
- Romero A, Garcia JEL, Joshi GP (2013) The state of the art in preventing postthoracotomy pain. *Semin Thorac Cardiovasc Surg* 25:116–124
- Steinhorsdottir KJ, Wildgaard L, Hansen HJ, Petersen RH, Wildgaard K (2014) Regional analgesia for video-assisted thoracic surgery: a systematic review. *Eur J Cardiothorac Surg* 45:959–966
- Tsui BCH, Fonseca A, Munshey F, McFadyen G, Caruso TJ (2018) The erector spinae plane (ESP) block: A pooled review of 242 cases. *J Clin Anesth* 53:29–34
- Yoshizaki M, Murata H, Ogami-Takamura K, Hara T (2019) Bilateral erector spinae plane block using a programmed intermittent bolus technique for pain management after Nuss procedure. *J Clin Anesth* 57:51–52

Publisher's Note

Springer Nature remains neutral with regard to jurisdictional claims in published maps and institutional affiliations.

Submit your manuscript to a SpringerOpen[®] journal and benefit from:

- Convenient online submission
- Rigorous peer review
- Open access: articles freely available online
- High visibility within the field
- Retaining the copyright to your article

Submit your next manuscript at ► [springeropen.com](https://www.springeropen.com)