

CASE REPORT

Open Access



Anesthetic management of a patient undergoing abdominal surgery with bilateral ventricular peritoneal shunt in situ

Renu Bala, Priyanka Bansal*, Srishti Malhan and Himani Mittal

Abstract

Background: Ventriculoperitoneal (VP) shunts are commonly performed procedures for a variety of disorders and are mostly long standing. These patients when present for non-neurological surgeries like gastrointestinal, urology, or caesarean section, there are several concerns like difficult abdominal surgery due to peritoneal adhesions, chances of shunt infection with potential retrograde infective meningoencephalitis, and ventriculitis or shunt failure with recurrent hydrocephalus.

Case presentation: A 35-year-old male, known case of third ventricular tumour with functional left-sided ventricular peritoneal shunt was scheduled to undergo cholecystectomy for gall bladder stone. Intraoperatively optic nerve sheath diameter was measured as an indicator of raised intracranial pressure. Intraoperative was uneventful. Efforts were taken to prevent rise in intracranial pressure perioperatively. Patient was discharged on third postoperative day.

Conclusion: A vigilant perioperative care along with adequate team work go a long way in achieving success in patients of ventriculoperitoneal shunts presenting for non-neurological surgeries.

Keywords: Cholecystectomy, VP shunt, ICP monitoring

Background

Innovations and advancements in neurosurgical procedures is improving prognosis of neurosurgical patients and thereby increasing life span of these patients. Ventriculoperitoneal (VP) shunts are one of the most commonly performed neurosurgical procedures. Such patients may present for several routine surgeries in later period of life and anesthetic management is quite difficult and complicated in them (Li & Dutta, 2008; Whitney & Sturgess, 2016). We hereby report a 35-year-old male patient with bilateral VP shunt in situ posted for cholecystectomy. We intend to discuss the available literature and potential options for better care of these patients.

Case presentation

A 35-year-old male patient with a body mass index of 24 kg/m² was scheduled to undergo cholecystectomy for gall bladder stones. He was a known case of third ventricular tumour for which initially right VP shunt was done followed by craniotomy and tumor excision 12 years back. The surgery and postoperative period was uneventful. Right hemiparesis was present before surgery and failed to resolve. Nine years back, patient reported for shunt blockage and VP shunt was revised on left side. Presently, his neurological examination was unremarkable except for the presence of right hemiparesis. There were no features of raised intracranial pressure like headache, nausea, vomiting, or difficulty in vision. General physical examination, airway examination, biochemical, and hematological investigations were within normal range. Baseline vitals were pulse 85/min and blood pressure of 130/78 mmHg. MRI brain showed presence of ventricular ends of shunts (Fig. 1).

* Correspondence: dr.priyankabansal1986@gmail.com
Department of Anaesthesiology, Pt. B.D.Sharma UHSR, Rohtak 124001, India

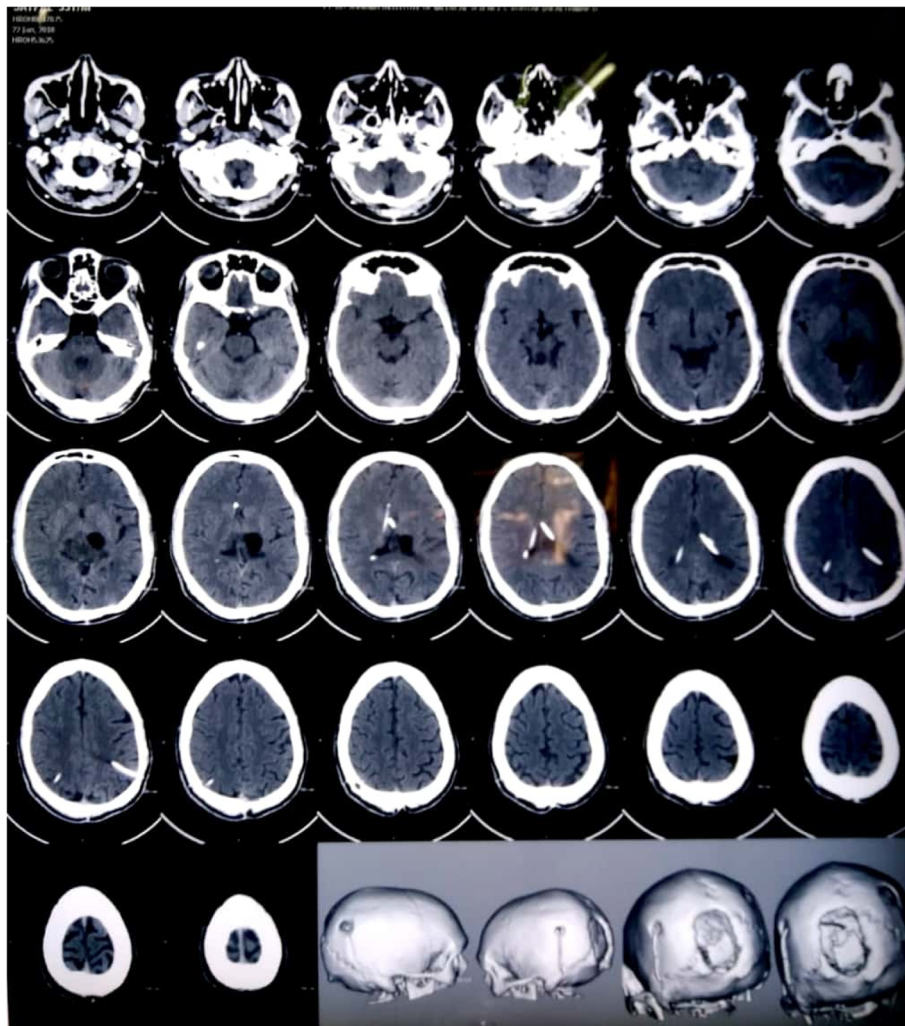


Fig. 1 MRI brain showing presence of ventricular ends of right VP shunt indicated by the arrow (only left shunt is functional)

Neurosurgeon consultation was sought which confirmed normal functioning of shunt and no active intervention was required. Only left-sided shunt was functional. Surgeons decided for open cholecystectomy.

A written, informed consent was taken and adequate fasting of 6 h preoperatively was obtained. Premedication was given in the form of tablet alprazolam 0.25 mg and tablet ranitidine 150 mg at night and 2 h preoperatively. In the operating room, standard monitoring constituted of heart rate, ECG, non-invasive blood pressure, SpO₂, and EtCO₂. Optic nerve sheath diameter (ONSD) was measured as non-invasive indicator of raised intracranial pressure (ICP). Tegaderm was applied on patients eye on which thick layer of jelly was placed. Linear probe having frequency of 7.5 MHz of Sonosite M-Turbo ultrasound machine was placed gently on superior and lateral aspect of left upper eyelid. The probe was angled gently in the caudad and medial direction till axial view of orbit was obtained displaying entry of optic nerve into

the globe. The image was frozen and cursors were placed on the outer contours of dural sheath, 3 mm behind the globe. The ONSD was measured as the horizontal distance between two cursors. It was 0.46 cm and was within normal range (0.45–0.5 cm)

Induction of anesthesia was done with thiopentone 250 mg, fentanyl 100 mcg, and vecuronium 6 mg (1 mg additional as and when required as additional dose). Oral endotracheal intubation was done and maintenance of anesthesia was done with oxygen, nitrous oxide in the ratio of 40:60 and isoflurane (1–1.5MAC). Volume control mode was used for ventilating the patient with following settings: tidal volume 450 ml, respiratory rate 12–14/min to keep end tidal carbon dioxide (ETCO₂) of 30–35 mmHg, peak inspiratory pressure 30 cmH₂O, and no peak end expiratory pressure (PEEP) was used. The surgeons first palpated shunt and carefully applied right Kocher's incision. VP shunt was noted in right upper quadrant and the intraperitoneal portion appeared intact

but adhered to omentum. It was clamped and put aside, thereafter gall bladder was removed (Fig. 2). Peritoneal end of shunt was then placed in the abdomen. Intraoperatively, hemodynamic parameters (heart rate and mean arterial pressure) were kept within 20% of baseline values. During surgery, sand bags below abdomen were placed to facilitate surgical exposure but due consideration was given to prevent head low position which could raise ICP. Adequate analgesia (fentanyl 100 mcg) and neuromuscular blockade also prevented sympathetic surges which could raise ICP. Moreover, ocular sonography on left eye was performed (Fig. 3) when the surgery was ongoing and VP shunt was clamped in a similar manner as done preoperatively (Fig. 2). ONSD was found to be within normal limits.

The surgery was uneventful and took 45 min during which additional dose of opioid or neuromuscular blockade was not required. One litre of crystalloid was infused and blood loss was negligible. Local anesthetic infiltration was done with lignocaine with adrenaline before wound closure and inj. Paracetamol 1 gm was infused intravenously. After completion of surgery, anesthetic gases were switched off and neuromuscular blockade was reversed with inj. glycopyrrolate 0.5 mg and inj neostigmine 2.5 mg. The recovery was smooth and uneventful. The patient was observed in post-anesthesia care unit (PACU) for 2 h and thereafter shifted to high dependency unit (HDU) with vitals of pulse 86/min and BP 140/84 mmHg. Antibiotic prophylaxis was given in the form of cephalosporin preoperatively and continued 3 days postoperatively. The patient was watched continuously for features of raised ICP and ONSD measurement was repeated daily. On third postoperative day, he was discharged home.

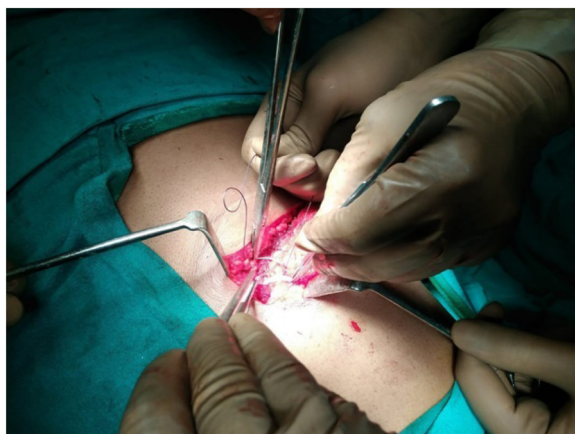


Fig. 2 Image showing clamped right sided VP shunt (indicated by the arrow). The procedure was on right side, the shunt was found adhered omentum but intact. It was clamped during surgery later peritoneal end of shunt was released in abdomen

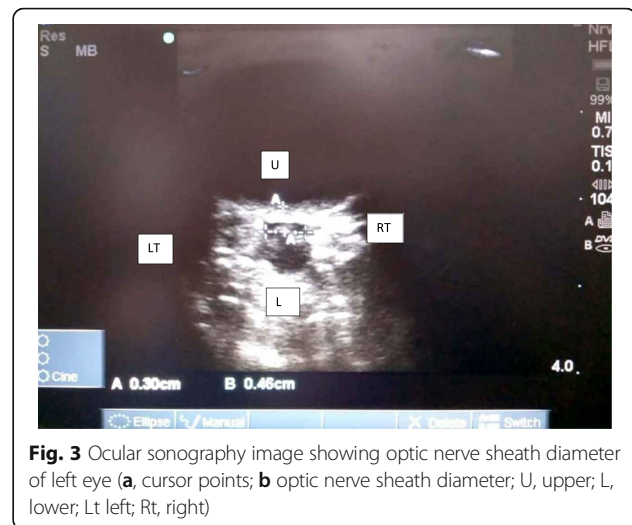


Fig. 3 Ocular sonography image showing optic nerve sheath diameter of left eye (a, cursor points; b optic nerve sheath diameter; U, upper; L, lower; Lt left; Rt, right)

Discussion

Ventriculoperitoneal shunts are silicone catheters placed from a lateral brain ventricle, through a subcutaneous tunnel and into the peritoneal space in order to drain excess cerebrospinal fluid in the ventricular system. The first VP shunt was performed in 1908 and since then has become a common neurosurgical procedure for a variety of disorders such as hydrocephalus, normal pressure hydrocephalus, and pseudotumor cerebri (Hammill et al., 2010). The survival rate of these patients is improving; therefore, it is quite common to encounter them for incidental surgeries in later period of life. The exact guidelines for the management of these patients are lacking; however, it requires meticulous preanesthetic assessment, understanding, and correct application of basic neurophysiological principles for successful anesthesia (Li & Dutta, 2008; Whitney & Sturgess, 2016).

In our patient, we carried out meticulous and thorough preoperative assessment which ensured normal shunt function. The onus of deciding for laparoscopic or open cholecystectomy was on surgeons. Although available literature suggest safe conductance of laparoscopy in these patients, the concerns of raised ICP, shunt malfunction do exist (Lykoudis et al., 2017). Furthermore, the shunt was placed long back, and there was a history of shunt malfunction increasing the chances of peritoneal adhesions which could make laparoscopic dissection difficult and risky (Whitney & Sturgess, 2016). Thus, the surgeons preferred open approach.

Intraoperatively, the conditions and manoeuvres which could increase ICP such as head down position, hypercapnia, and nociceptive reflexes were avoided. To prevent shunt damage, the peritoneal end was exteriorized and reinserted after removal of gall bladder. Monitoring of ICP perioperatively is highly desirable in these conditions. Though invasive methods are not feasible, we used

ocular sonography to measure ONSD as marker of ICP. This technique is well recognised nowadays as surrogate measure of raised ICP (Raffiz & Abdullah, 2016). Previous report describes transcranial Doppler (TCD) for non-invasive estimation of ICP in a patient with VP shunt (Staikou et al., 2012). We used left eye for performing ocular sonography because patient was operated on right side and thus there were technical problems in carrying out procedure on that side. We monitored ONSD preoperatively, intraoperatively, and postoperatively daily till discharge of patient (third day).

The chances of shunt infection are minimal in clean abdominal surgery thus antibiotics are not indicated according to a previous review (Li & Dutta, 2008). But, as per our institutional protocol, 3 days course of cephalosporins was administered. Postoperative care is also equally important since shunt infection or blockage may occur and lead to adverse neurological outcome (Wang et al., 2003).

Conclusion

To conclude, anesthetic management of a patient with VP shunt in situ undergoing non-neurological surgery may be complicated by neurological status, shunt infection and raised ICP. A good team work and communication between anesthesiologist, operating surgeon, and neurosurgeon along with proper perioperative care are crucial to prevent and treat possible complications.

Abbreviations

VP: Ventriculoperitoneal; ONSD: Optic nerve sheath diameter; TCD: Transcranial Doppler; PACU: Post-anesthesia care unit; HDU: High dependency unit; ICP: Intracranial pressure; EtCO₂: End tidal carbon dioxide; PEEP: Peak end expiratory pressure

Acknowledgements

None

Authors' contributions

SM helped in the searching of the literature. SM helped in the methodology. RB helped in the editing. PB and SM helped in the writing of the manuscript. HM helped in the basic outline of the manuscript. The authors read and approved the final manuscript.

Funding

None

Availability of data and materials

The data was extracted from the medical records file of the patient and Title Page. The materials are being used which were available in our set up with valid reasons.

Declarations

Ethics approval and consent to participate

Ethical approval is not required for publication of isolated case reports.

Consent for publication

Written permission/consent for reproduction of images of the patient and for the purpose of publication in an educational medical journal was obtained from the patient.

Competing interests

The authors declare that they have no competing interests.

Received: 12 November 2020 Accepted: 6 May 2021

Published online: 17 May 2021

References

- Hammill CW, Au T, Wong LL (2010) Laparoscopic cholecystectomy in a patient with a ventriculoperitoneal shunt. *Hawaii Med J* 69(4):103–104 PMID: 20481236; PMCID: PMC3111663
- Li G, Dutta S (2008) Perioperative management of ventriculoperitoneal shunts during abdominal surgery. *Surg Neurol* 70(5):492–497. <https://doi.org/10.1016/j.surneu.2007.08.050>
- Lykoudis PM, Nastos C, Dellaportas D, Vezakis A, Ayiomamitis GD, Papaconstantinou I, Theodosopoulos T, Polydorou A, Polymeneas G (2017) Laparoscopic cholecystectomy in patients with ventriculoperitoneal shunts: a case series. *Hell J Surg* 89(3-4):163–165. <https://doi.org/10.1007/s13126-017-0405-3>
- Raffiz M, Abdullah JM (2016) Optic nerve sheath diameter measurement: a means of detecting raised ICP in adult traumatic and non-traumatic neurosurgical patients. *Am J Emerg Med* 35(1):150–153. <https://doi.org/10.1016/j.ajem.2016.09.044>
- Staikou C, Tsaroucha A, Mani A, Fassoulaki A (2012) Transcranial Doppler monitoring of middle cerebral flow velocity in a patient with a ventriculoperitoneal shunt undergoing laparoscopy. *J Clin Monit Comput* 26(6):487–489. <https://doi.org/10.1007/s10877-012-9380-y>
- Wang YM, Liu YC, Ye XD, Chia YY, Liu K (2003) Anesthetic management of laparoscopic surgery in a patient with a ventriculoperitoneal shunt. *Acta Anaesthesiol Sin* 41(2):85–88 PMID: 12934423
- Whitney PS, Sturgess J (2016) Anesthetic considerations for patients with neurosurgical implants. *BJA Educ* 16(7):230–235. <https://doi.org/10.1093/bjaed/mkv049>

Publisher's Note

Springer Nature remains neutral with regard to jurisdictional claims in published maps and institutional affiliations.

Submit your manuscript to a SpringerOpen® journal and benefit from:

- Convenient online submission
- Rigorous peer review
- Open access: articles freely available online
- High visibility within the field
- Retaining the copyright to your article

Submit your next manuscript at ► [springeropen.com](https://www.springeropen.com)