

## The Impact of Laparoscopic Ovarian Cystectomy Versus Laparoscopic Deroofing upon Ovarian Reserve in Endometriomas

Ahmed G.Ahmed, Mohamed A.Mohamed, Mohamed A.El nory and Basma E.Sakr

Obstetrics and Gynecology Dept., Faculty of Medicine, Benha University, Benha, Egypt

E-Mail: ahmed.geme22@gmail.com

### Abstract

**Background:** Endometriomas are usually treated surgically using laparoscopic procedures, however the effect of various surgical methods on ovarian reserve is still being studied. The purpose of this research was to compare the effects on ovarian reserve (as determined by blood levels of AMH and AFC) between laparoscopic ovarian cystectomy and laparoscopic cyst de-roofing of endometriomas. The methods included testing 100 women who had been diagnosed with endometrioma. Patients were split into two groups: those who had laparoscopic ovarian cyst removal (N=50) and those who had laparoscopic cyst de-roofing (N=50). The results showed that the cystectomy group had considerably larger differences in terms of AMH, AFC, and ovarian volume. The two groups did not vary substantially in terms of either the mean difference or the mean difference percentage of the VAS. In instances with bilateral lesions, the AMH levels measured one month after cystectomy were considerably lower than those measured in the deroofing group. Ovarian volume was positively correlated with AMH, as was AFC and lesion size (p0.001). There were no statistically significant associations between age, body mass index, or VAS. There was a significant association between AMH level and lesion size, AFC, and ovarian volume, suggesting that laparoscopic cyst deroofing was less detrimental to ovarian reserve than cystectomy in instances of endometriomas.

Endometriomas, laparoscopic ovarian cyst removal, laparoscopic cyst de-roofing, ovarian reserve, anti-mullerian hormone, and antral follicle count are some of the keywords that will be used in this paper.

### 1. Introduction

Endometriosis is the presence of uterine lining tissue outside of the uterus, most often in the ovaries, fallopian tubes, and pelvis, affecting 7–10% of women overall and up to 50% of infertile women [1]. This may cause discomfort, infertility, and other symptoms that negatively impact quality of life.

The most typical ovarian endometriosis symptom is the development of an endometrioma. However, implants are not limited to the abdominal wall; they may also be detected on the colon, inside previous surgical wounds, and in very rare circumstances, even as far away as the cerebellum [3]. Somewhere between 17 and 44 percent of women with endometriosis will develop an endometrioma. Because the fluid within of these tumours is so thick and dark brown, people sometimes refer to them as chocolate cysts [4].

While ovarian endometrioma is a hot subject, there are still many questions to be answered about its impact on surrounding tissue, possible responses in the area, and the viability of surgical removal. Ovarian endometrioma's effect on fertility is still up for debate [5].

In comparison to drainage and ablation, laparoscopic cystectomy results in a higher incidence of clinical pregnancy and a lower recurrence of endometriomas [6]. However, since intact ovarian tissue must be removed during surgical excision of the endometrioma cyst wall, two investigations

reported a considerable decrease in ovarian reserve [7].

It has been shown that much surgical competence is required to preserve the ovarian reserve after endometrioma surgery, and that this declines dramatically with each additional operation [8]. Surgical recurrence is a constant problem because surgeons must strike a delicate balance between destroying all endometriotic tissue and damaging the patient's ovarian reserve.

A woman's regeneration capacity in terms of ovarian follicle number and oocyte quality is known as her "ovarian reserve" [10]. When compared to other known serum indicators [11], anti-mullerian hormone (AMH) was shown to be the most useful, reliable hormonal marker of the ovarian primordial follicle pool. Furthermore, there is a robust correlation between blood AMH levels and ultrasound-determined Antral Follicle Count (AFC) [12].

When it comes to ovarian reserve and follicle loss, there is much discussion between two common surgical procedures (laparoscopy-assisted cystectomy and laparoscopic cyst de-roofing) [8].

The purpose of this research was to compare the effects on ovarian reserve (as determined by blood levels of AMH and AFC) between laparoscopic ovarian cystectomy and laparoscopic cyst de-roofing of endometriomas.

### 2. Methods

#### Patient Population:

The One hundred women, aged 18 to 35, were included in a prospective, randomised clinical trial study at Benha University hospital and private hospitals; all had been diagnosed with endometrioma (either unilaterally or bilaterally) and were candidates for laparoscopic surgery.

All women who participated voluntarily provided written informed permission after receiving detailed explanations of the study's goals, methods, and follow-up strategy.

Cases were included if they were between the ages of 18 and 35 and had a transvaginal ultrasonography diagnosis of endometrioma (either unilateral or bilateral) with a diameter of more than 3 cm.

Prior ovarian surgery, positive evidence for polycystic ovary syndrome as defined by the Rotterdam criteria, premature ovarian failure as determined by a follicle-stimulating hormone level 40 IU/L, any endocrine disorders affecting ovarian function (such as thyroid dysfunction, hyperprolactinemia), recent use of hormonal medication within the last 3 months prior to surgery (oral contraceptive pills, gonadotropin-releasing hormone analogues), and

One hundred women were randomly assigned to either have laparoscopic ovarian cystectomy (Group 1) or laparoscopic cyst deroofing (Group 2).

All patients were subjected to a thorough history and physical examination as part of the methodology. An accurate diagnosis of endometriosis requires a thorough understanding of the patient's medical, gynaecological, pharmaceutical, and familial histories in addition to the usual suspects (age, gender, race/ethnicity/ethnicity), major complaints, and presenting symptoms. Information on the patient's demographics, primary complaints, and presenting history might help doctors better diagnose and treat their patient. The patient's medical and gynaecological history, current and past medication use, and family history provide valuable context. The general examination, on the other hand, includes a variety of systemic evaluations based on the patient's symptoms and medical history, such as measuring vital signs, assessing the patient's general appearance and well-being, calculating the body mass index (BMI), performing abdominal and pelvic examinations, and so on. Everyone who comes in is checked out for a general.

Serum samples are obtained from the veins before and after surgery, centrifuged, and frozen at -20 degrees Celsius until tested using

commercially available ELISA kits to quantify AMH. AMH levels between 0.5 and 25 ng/mL are detectable[13].

Ovarian volume and antral follicle count are measured on day 3 of the patient's final cycle before to surgery and day 3 of the patient's second cycle post-operation. The number of follicles between 2 and 9 mm in diameter is used to calculate the antral follicle count. Using the formula for prolate ellipsoids, one may get the volume of the ovary: volume (cm<sup>3</sup>) = 0.5233 x anteroposterior diameter (cm) x transverse diameter (cm) x longitudinal diameter (cm) (cm). When determining ovarian volume, one must first remove the volume of any cysts from the overall ovarian volume [14].

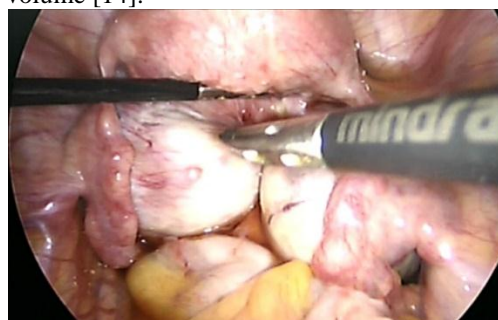


Fig. (1) Bilateral Endometrioma.

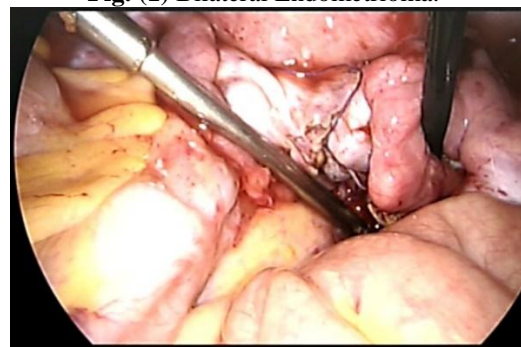
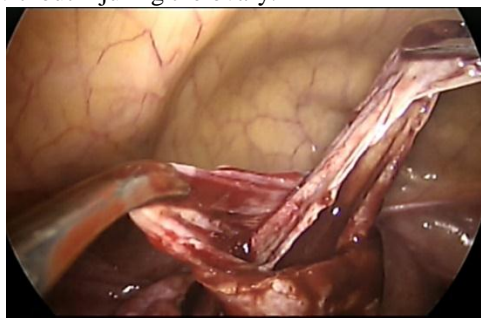


Fig. (2) Bilateral Endometrioma after laparoscopic cystectomy.

#### Interventions

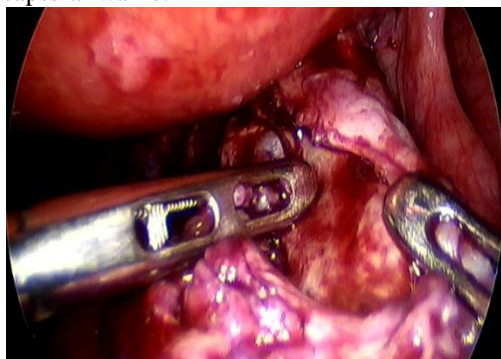
**Group (1): Active Comparator:** laparoscopic The proliferative phase of the menstrual cycle was chosen for the ovarian cystectomy. Before and after surgery, the patient's level of anti-mullerian hormone was measured, and the number of antral follicles was estimated. Under general anaesthesia, three 5-mm trocars were placed in the lower abdomen in addition to the 10-mm intraumbilical main trocar; pneumoperitoneum was induced with carbon dioxide; 5-mm scissors and graspers were employed; and Ringer's lactate solution was used for irrigation. The ovaries were fully liberated using both blunt and sharp dissection prior to the start of ovarian surgery. Two atraumatic gripping forceps are used to carefully and gently remove the ovaries in opposing

directions when a cleavage plane between the cyst wall and ovarian cortex has been found. When the pseudo capsule was taken out of the abdomen, the surgeon used a modest (15 watt) bipolar coagulation device to stop the bleeding without injuring the ovary.



**Fig. (3)** laparoscopic cystectomy of unilateral endometrioma.

**Group (2): Active Comparator:** laparoscopic The deroofting of the cyst occurred during the fertile period of the female reproductive cycle. Before and after surgery, the number of antral follicles were estimated by measuring anti-mullerian hormone levels. Procedure: Under general anaesthesia and video guidance, we made three 5-mm trocar incisions in the lower abdomen and one 10-mm intraumbilical main trocar, inserted 5-mm scissors and graspers, and irrigated with Ringer's lactate solution. The ovaries were first carefully and painstakingly released using obtuse and acute dissection before the ovarian surgery could begin. Ovary mobilisation followed by suction-irrigator probe removal of cyst contents and cavity irrigation. Endometriosis-affected ovarian cortex was surgically excised after an examination of the cyst's inside. Bipolar electro coagulation might stop bleeding from the ovarian hilum and small blood vessels in the ovarian bed (15 watt). Application of low-intensity bipolar coagulation on the superfluous ovarian capsular wallle.



**Fig. (4)** Unilateral endometrioma cyst deroofting.

Visual Analogue Scale (VAS) was also used to evaluate the cases' pain.

**Outcome Measures:** Comparison comparing the effects on ovarian reserve, as measured by the change in AMH level and antral follicle count estimate in endometrioma patients after 1 month, between laparoscopic ovarian cystectomy versus laparoscopic cyst deroofting.

Instructions for taking and handling AMH samples: Concentration in Serum (preferred); Concentration in Plasma (lithium heparin). Within 2 hours after collection, samples should be separated. The storage life of separated samples is two to five days in the fridge. For medium-term storage, freeze them at -20 degrees Celsius, and for long-term storage, set the freezer to -80 degrees Celsius.

Pelvic ultrasound evaluations were carried out between days 3 and 5 of the woman's menstrual cycle to determine the number of antral follicles. The total number of left and right ovarian antral follicles between 2 and 10 mm in size is what makes up the antral follicle count (AFC).

IBM SPSS Statistics was used for the statistical analysis, which included cleaning, coding, and tabulating the raw data (Version 25.0, IBM Corp., Released 2017, Armonk, NY). The Shapiro-Wilk test was used to check for normality. Means, standard deviations (SD), and frequency and percentage estimates were some of the descriptive statistics used. The Chi-Square test was used to compare means on independent variables, the Mann-Whitney U test was used to compare non-parametric variables across groups, and the Repeated-Measures ANOVA was used to compare means on dependent variables. Using odds ratios (OR) to show the relative risk of an event with a given exposure against its absence, and confidence intervals (CI) to show the extent to which the OR may be trusted, logistic regression enabled risk prediction for categorical dependent variables. A p-value less than 0.05 at a 95% confidence interval (CI) was considered statistically significant.

### 3. Results

In terms of age, body mass index, parity, and lesion criteria, there was no statistically significant difference between the groups. Table 1

Table (1) Demographic data and Lesion criteria of the studied groups

		Laparoscopic ovarian cystectomy n=50	Laparoscopic cyst deroofing n=50	test	p
Age, (y)	mean±SD	27.19 ± 2.38	26.69 ± 2.35	t=1.064	0.29
	Median (Range)	27.06 (23.20 - 32.65)	26.39 (23.00 - 32.30)		
BMI, (kg/m2)	mean±SD	23.17 ± 2.52	22.97 ± 1.70	t=0.479	0.63
	Median (Range)	22.88 (20.49 - 28.59)	22.41 (21.12 - 27.57)		
Parity, n (%)	Nulligravida	20(60%)	32(64%)	X <sup>2</sup> =0.17	0.83
	Multigravida	20(40%)	18(36%)		
Lesion size, cm3	mean±SD	5.17±0.44	5.32±0.46	Z=1.724	0.08
	Median (Range)	5.07(4.66 -6.4)	5.26(4.76 -6.53)		
Lesion laterality, n(%)	Unilateral	28(56%)	35(70%)	X <sup>2</sup> =2.10	0.21
	Bilateral	22(44%)	15(30%)		

t= t student test; X<sup>2</sup>=Chi square test; Z=Mann-Whitney test, \*: Significant ≤0.05

There after one month, the AMH levels in the cystectomy group had dropped significantly. After one month, the AFC significantly dropped in the cystectomy group. After one month, the ovarian volume significantly decreased in the cystectomy

group. Both groups reported considerably less pain (VAS) after surgery compared to before. Neither pre- or post-operative pain (as measured by VAS) differed significantly across the groups. Table 2

Table (2) AMH, AFC, Ovarian volume and VAS measurement at preoperative and postoperative in the studied groups

Variable		Laparoscopic ovarian cystectomy n=50	Laparoscopic cyst deroofing n=50	test	p
Preoperative AMH level, ng/ml	mean±SD	4.29 ± 0.82	4.30 ± 1.37	Z=0.0	0.926
	Median (Range)	4.20 (3.47 - 6.03)	4.23 (2.68 - 7.06)		
Postoperative AMH level, ng/ml	mean±SD	1.82 ± 0.91	2.35 ± 1.33	Z=-.92	0.042
	Median (Range)	1.58 (0.74 - 4.17)	2.40 (0.82 - 5.68)		
	Same group comparison	p1= <0.001*	p1= <0.001*		
Preoperative AFC, n	mean±SD	8.56 ± 1.27	7.78 ± 2.28	t=0.98	0.452
	Median (Range)	8 (7 - 12)	8 (6 - 10)		
Postoperative AFC, n	mean±SD	3.46 ± 1.09	5.79 ± 1.14	t=7.17	<0.00
	Median (Range)	3 (5 - 6)	6 (5 - 8)		
	Same group comparison	p1= <0.001*	p1= <0.001*		
Preoperative ovarian volume, Cm3	mean±SD	8.62 ± 1.56	7.51 ± 1.80	Z=0.9	0.458
	Median (Range)	8.95 (6.50 - 11.43)	6.94 (5.60 - 11.65)		
Postoperative ovarian volume, cm3	mean±SD	3.09 ± 1.33	5.78 ± 1.32	Z=7.6	<0.00
	Median (Range)	2.99 (1.66 - 8.32)	5.58 (4.26 - 9.46)		
	Same group comparison	p= <0.001*	p= <0.001*		
Preoperative pain (VAS)	mean±SD	7.71 ± 0.98	7.86 ± 1.12	t=0.76	0.442

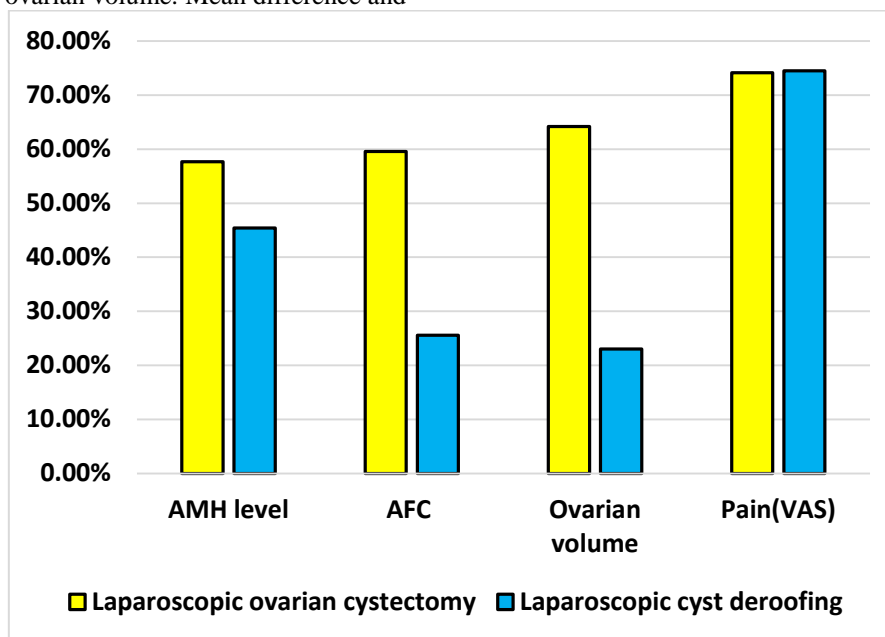
<b>1-month postoperative pain (VAS)</b>	Median (Range)	8 (6- 10)	8 (6 - 11)	9	t=0.45 0.758
	mean±SD	1.99 ± 0.84	2.00 ± 1.01		
	Median (Range)	2 (1 - 4)	2 (1 - 4)	1	
	<b>Same group comparison</b>	<b>p= &lt;0.001*</b>	<b>p= &lt;0.001*</b>		

Z=Mann-Whitney test; VAS: Visual analog scale, \*: Significant ≤0.05

Mean difference and mean difference percentage were significantly higher in cystectomy group according to AMH level, AFC and ovarian volume. Mean difference and

mean difference percentage of VAS was not significantly difference between the two groups.

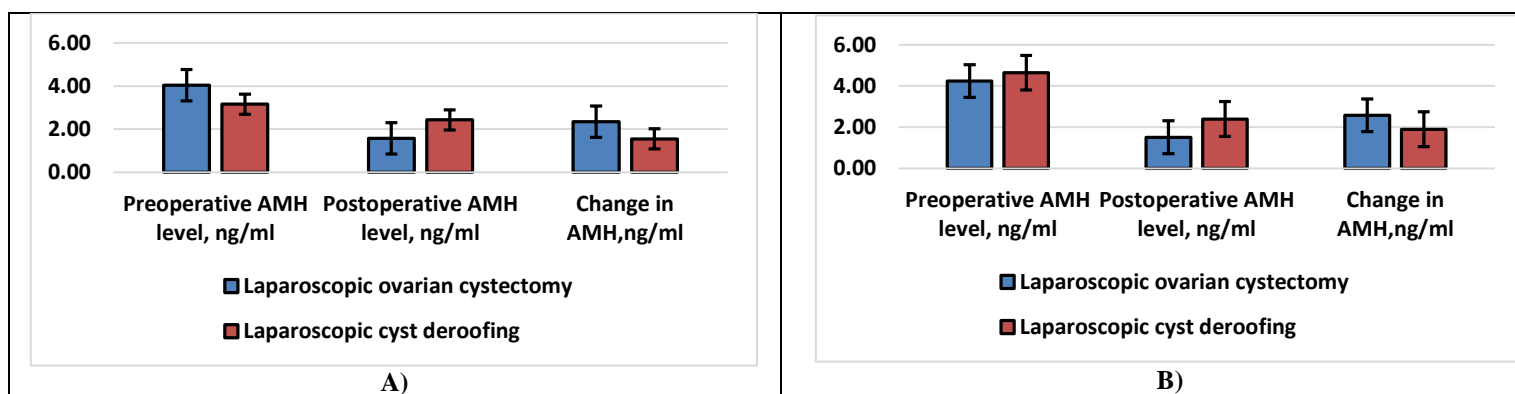
**Figure 1**



**Fig. (5)** Preoperative and postoperative mean difference percentage difference between the studied groups

AMH level showed significant lower measurement in cystectomy group one month

compared with deroofing group in bilateral lesion cases. **Figure 2**



**Fig. 6:** A) AMH level among unilateral lesion cases and B) AMH level among bilateral lesion cases

Ovarian volume was positively correlated with AMH, as was AFC and lesion size (p0.001). There were no statistically

significant associations between age, body mass index, or VAS. Table 3

**Table (3)** Correlation between AMH and other studied parameters among studied subjects

	AMH	
	r <sub>s</sub>	p
Age	0.003	0.568
BMI	0.017	0.190
Lesion size	0.806	<0.001*

<b>AFC</b>	0.982	<0.001*
<b>Ovarian volume</b>	0.690	<0.001*
<b>VAS</b>	0.016	0.209

rs: Spearman correlation coefficient, \*: Significant  $\leq 0.05$

Age, body mass index, lesion laterality, and surgical method were employed in a regression analysis to predict characteristics related with ovarian volume

change. There was a statistically significant correlation between ovarian volume change and cystectomy (p0.001). Table 4

**Table (4)** Regression analysis for determinants of change in ovarian volume

	<b>p</b>	<b>OR</b>	<b>95% CI</b>
<b>Age</b>	0.207	1.166	0.918-1.481
<b>BMI</b>	0.667	0.944	0.752-1.229
<b>Laterality of lesion</b>	0.524	1.459	0.456-4.666
<b>Surgical procedure (cystectomy)</b>	<0.001*	0.022	0.01-0.052

OR: odds ratio, CI: confidence interval, \*: Significant  $\leq 0.05$

Age, body mass index, lesion laterality, and surgical method were employed in a regression analysis to predict characteristics related with AMH change.

There was a statistically significant correlation between cystectomy and AMH shift (p0.001). Table 5

**Table (5)** Regression analysis for determinants of change in AMH

	<b>p</b>	<b>OR</b>	<b>95% CI</b>
<b>Age</b>	0.685	0.971	0.843-1.119
<b>BMI</b>	0.984	0.998	0.854-1.168
<b>Laterality of lesion</b>	0.307	0.699	0.352-1.39
<b>Surgical procedure (cystectomy)</b>	<0.001*	1.124	0.309-1.154

OR: odds ratio, CI: confidence interval, \*: Significant  $\leq 0.05$ .

#### 4. Discussion

Endometriosis affects 7–10% of the general female population and up to 50% of infertile women [15]. It is characterised by improperly located endometrial glands and stroma outside the uterine cavity and is associated with pelvic discomfort, dysmenorrhea, and infertility.

There were no significant variations in age, body mass index, or parity between the groups in this research.

A recent clinical randomised research [16] involved 120 women with unilateral or bilateral ovarian endometriomas to assess laparoscopic ovarian cystectomy against cyst deroofing for ovarian reversal, and their findings were consistent with ours. No statistically significant differences were seen between the cystectomy and cyst deroofing groups with respect to demographic data, baseline clinical, or sonographic preoperative features.

Using a randomised prospective design, [17] analysed the impact of coagulation and cystectomy on the AFC and ovarian volumes before and after surgery in 84 women with bilateral endometriomas. They discovered that demographic information was consistent across all groups.

No statistically significant changes in lesion size or laterality were seen between the groups in our investigation.

Our results are consistent with those of [16], which found no difference in lesion laterality or size between patients who had laparoscopic ovarian cystectomy and those who underwent cyst deroofing.

The anti-mullerian hormone (AMH) has recently been proposed as the most accurate and repeatable measure since it is unaffected by the menstrual cycle and hormonal medications [18].

One month after surgery, the AMH level dropped considerably in both groups, although the drop in the cystectomy group was greater than the drop in the deroofing group. Consistent with our findings, [16] demonstrated a substantial reduction in AMH level 1 month and 1 year postoperatively, with a more pronounced drop in the cystectomy group compared to the deroofing group.

Similarly, [19] did a prospective research on 44 women undergoing laparoscopic cystectomy for ovarian endometriomas-related discomfort or infertility. They discovered that after laparoscopic cystectomy, the median levels of serum AMH dropped significantly from preoperative readings.

The present study's findings corroborate those of [20, 21], the first studies to reveal the deleterious effects of cystectomy for ovarian endometrioma on ovarian reserve by the reduced value of AMH level and AFC.

Successive meta-analyses [7, 22] demonstrated the deleterious effects of surgical cystectomy of endometriomas on ovarian reserve, e.g., a drop in AMH levels.

Twenty-one papers matched the criteria for the systematic review and meta-analysis [7], and eight were included in the meta-analysis. Serum AMH levels decreased significantly after cystectomy for ovarian endometrioma, as shown by pooled study of 237 individuals.

The AFC is a good sonographic measure of ovarian reserve [23] because of its significant association with the primordial follicle pool. Natural and clomiphene citrate-stimulated cycles showed a reduced follicular ovarian response in ovaries after cyst removal. Another indication of ovarian reserve that has been shown to be dependable is ovarian volume [24].

Our findings show that AFC was reduced considerably one month after surgery in both groups, with a greater reduction in the cystectomy group compared to the deroofting group. Our results corroborate those of Sweed et al. [16], who found a similar decline in AFC between the cystectomy and deroofting groups at 1 month and 1 year postoperatively, with the former seeing a more pronounced decline.

In addition, individuals who had laparoscopic ovarian cystectomy had significantly lower median values of AFC postoperatively compared to preoperative measures, as shown by [19]. Our findings are consistent with those of Var et al. [17], who found that the number of antral follicles was considerably lower after cystectomy than after coagulation.

Compared to the unoperated ovary, the AFC was considerably lower in the ovary that had surgical intervention, according to a meta-analysis and systematic review undertaken by [25] of 13 studies including 597 participants.

Comparing AFC, ovarian volume, and ovarian artery Doppler velocity between cystectomy and the three-stage surgery in patients with endometrioma was also performed. Women who received laparoscopic ovarian cystectomy had lower AFC levels [26]. Another research found that laparoscopic ovarian cystectomy was associated with higher ovarian damage when compared to open surgery and a three-stage method for ovarian removal [27].

In the present investigation, ovarian volume was shown to be significantly less in the postoperative than preoperative period for both groups. Ovarian volume was significantly lower one month following surgery in the cystectomy group compared to the deroofting group. Our research indicated that laparoscopic cyst deroofting may be safer for ovarian reserve than cystectomy for the treatment of endometriomas. Results from the cystectomy group showed a more pronounced reduction in ovarian volume than those from the deroofting group at 1 month postoperative, which is consistent with our findings. Furthermore, Var et al. [17] shown that cystectomy resulted in much smaller ovarian volumes than coagulation did in the post-procedure period.

In our research, post-operative pain (VAS) was considerably lower than pre-operative pain (VAS) in both groups. Neither group had much more pain than the other before or after surgery. In contrast, Sweed et al. [16] found that after a year, deroofting patients had much higher discomfort than cystectomy patients. This discrepancy might be due to the various study periods and sample sizes used.

One month after surgery, the AMH level was considerably lower in the cystectomy group compared to the deroofting group in instances with unilateral lesion, as shown by the present research. In contrast to our findings, Sweed et al. [16] showed that patients with unilateral and bilateral endometriomas saw a larger reduction in AMH levels in the cystectomy group.

Ovarian reserve was reduced three months following laparoscopic cystectomy for endometriotic cysts. Our study's findings were consistent with those of others [28]. Ovarian reserve may be diminished in a number of ways, including by the accidental loss of healthy tissue during a cystectomy or by thermal damage. Normal ovarian tissue, including the ovarian parenchyma and the primordial follicle, was found in the surgical specimens [29]. Ovarian follicles may be damaged by electrocauterization techniques such bipolar electrosurgery, which are often used to reduce bleeding during laparoscopic cystectomy [30].

Our results revealed that the AMH level was positively related to the magnitude of the lesion, the area under the curve, and the ovarian volume ( $p < 0.001$ ). While there were no statistically significant associations between age, body mass index, and VAS. The rate of AMH reduction at 1 month after surgery was substantially linked with patient age, according to a prospective study by Saito et al. [31] that

examined the blood level of AMH in 62 patients before and after 1, 6, and 12 months following laparoscopic cystectomy.

After controlling for age, body mass index (BMI), and lateralization of lesion, we found that the relationships between cystectomy and ovarian volume reduction were still statistically significant in both the univariate and multivariate analyses. Supporting our findings, a prior research by Sweed et al. [16] found that the surgical method was a major driver of change in ovarian volume when using multivariable regression analysis.

The relationships between cystectomy and AMH declines in our sample remained statistically significant after controlling for age, body mass index, and lesion side, as shown by both univariate and multivariate analyses. Consistent with our findings, Sweed et al. [16] discovered that the surgical method was a major driver of change in AMH level by multivariable regression analysis.

### 5. Conclusion

There was a positive connection between AMH level and lesion size, AFC, and ovarian volume after laparoscopic cyst deroofing in instances of endometriomas, suggesting that this procedure was less detrimental to ovarian reserve than cystectomy.

### References

- [1] 1. C. Bafort, Y. Beebeejaun, C. Tomassetti, J. Bosteels, J.M. Duffy. Laparoscopic surgery for endometriosis. Cochrane Database of Systematic Reviews. 2020
- [2] 2. Y. Wang, K. Nicholes, I.M. Shih. The Origin and Pathogenesis of Endometriosis. *Annu Rev Pathol*;15:71-95. 2020
- [3] 3. M. Meggyesy, M. Friese, J. Gottschalk, U. Kehler. Case Report of Cerebellar Endometriosis. *J Neurol Surg A Cent Eur Neurosurg*;81:372-6. 2020
- [4] 4. C. Exacoustos, G. De Felice, A. Pizzo, G. Morosetti, L. Lazzeri, G. Centini, et al. Isolated Ovarian Endometrioma: A History Between Myth and Reality. *J Minim Invasive Gynecol*;25:884-91. 2018
- [5] 5. P. Santulli, M.C. Lamau, L. Marcellin, V. Gayet, P. Marzouk, B. Borghese, et al. Endometriosis-related infertility: ovarian endometrioma per se is not associated with presentation for infertility. *Hum Reprod*;31:1765-75. 2016
- [6] 6. L. Muzii, C. Di Tucci, M. Di Feliciano, G. Galati, L. Verrelli, V.D. Donato, et al. Management of Endometriomas. *Semin Reprod Med*;35:25-30. 2017
- [7] 7. F. Raffi, M. Metwally, S. Amer. The impact of excision of ovarian endometrioma on ovarian reserve: a systematic review and meta-analysis. *J Clin Endocrinol Metab*;97:3146-54. 2012
- [8] 8. D. Jiang, X. Nie. Effect of endometrioma and its surgical excision on fertility (Review). *Exp Ther Med*;20:114. 2020
- [9] 9. M.F. Shaltout, A. Elsheikhah, A.M. Maged, M.M. Elsherbini, S.S. Zaki, S. Dahab, et al. A randomized controlled trial of a new technique for laparoscopic management of ovarian endometriosis preventing recurrence and keeping ovarian reserve. *J Ovarian Res*;12:66. 2019
- [10] 10. R. Lew. Natural history of ovarian function including assessment of ovarian reserve and premature ovarian failure. *Best Pract Res Clin Obstet Gynaecol*;55:2-13. 2019
- [11] 11. H. Xu, L. Shi, G. Feng, Z. Xiao, L. Chen, R. Li, et al. An Ovarian Reserve Assessment Model Based on Anti-Müllerian Hormone Levels, Follicle-Stimulating Hormone Levels, and Age: Retrospective Cohort Study. *J Med Internet Res*;22:e19096. 2020
- [12] 12. H.L. Khan, S. Bhatti, S. Suhail, R. Gul, A. Awais, H. Hamayun, et al. Antral follicle count (AFC) and serum anti-Müllerian hormone (AMH) are the predictors of natural fecundability have similar trends irrespective of fertility status and menstrual characteristics among fertile and infertile women below the age of 40 years. *Reprod Biol Endocrinol*;17:20. 2019
- [13] 13. R. Vržáková, V. Šimánek, O. Topolčan, V. Vurm, D. Slouka, R. Kučera. The Stability of the Anti-Müllerian Hormone in Serum and Plasma Samples under Various Preanalytical Conditions. *Diagnostics (Basel)*;13. 2023
- [14] 14. J. Lee, D.G. Hong. Serum anti-Müllerian hormone recovery after ovarian cystectomy for endometriosis: A retrospective study among Korean women. *Medicine (Baltimore)*;101:e30977. 2022
- [15] 15. G. Bonavina, H.S. Taylor. Endometriosis-associated infertility: From pathophysiology to tailored treatment. *Front Endocrinol (Lausanne)*;13:1020827. 2022
- [16] 16. M.S. Sweed, A.K. Makled, M.A. El-Sayed, M.E. Shawky, H.A. Abd-



- Elhady, A.M. Mansour, et al. Ovarian Reserve Following Laparoscopic Ovarian Cystectomy vs Cyst Deroofing for Endometriomas. *J Minim Invasive Gynecol*;26:877-82. 2019
- [17] 17. T. Var, S. Batioglu, E. Tonguc, I. Kahyaoglu. The effect of laparoscopic ovarian cystectomy versus coagulation in bilateral endometriomas on ovarian reserve as determined by antral follicle count and ovarian volume: a prospective randomized study. *Fertil Steril*;95:2247-50. 2011
- [18] 18. D.B. Seifer, D.T. Maclaughlin. Mullerian Inhibiting Substance is an ovarian growth factor of emerging clinical significance. *Fertil Steril*;88:539-46. 2007
- [19] 19. A. El-Aal, M. Hany, I.M. Mira, E.M. Samy. The impact of laparoscopic ovarian cystectomy on ovarian reserve in cases of endometrioma. *The Egyptian Journal of Hospital Medicine*;73:7692-8. 2018
- [20] 20. H.J. Chang, S.H. Han, J.R. Lee, B.C. Jee, B.I. Lee, C.S. Suh, et al. Impact of laparoscopic cystectomy on ovarian reserve: serial changes of serum anti-Müllerian hormone levels. *Fertil Steril*;94:343-9. 2010
- [21] 21. A. Iwase, W. Hirokawa, M. Goto, S. Takikawa, Y. Nagatomo, T. Nakahara, et al. Serum anti-Müllerian hormone level is a useful marker for evaluating the impact of laparoscopic cystectomy on ovarian reserve. *Fertil Steril*;94:2846-9. 2010
- [22] 22. E. Somigliana, N. Berlanda, L. Benaglia, P. Viganò, P. Vercellini, L. Fedele. Surgical excision of endometriomas and ovarian reserve: a systematic review on serum antimüllerian hormone level modifications. *Fertil Steril*;98:1531-8. 2012
- [23] 23. S. Muttukrishna, H. McGarrigle, R. Wakim, I. Khadum, D.M. Ranieri, P. Serhal. Antral follicle count, anti-müllerian hormone and inhibin B: predictors of ovarian response in assisted reproductive technology? *Bjog*;112:1384-90. 2005
- [24] 24. M.L. Haadsma, H. Groen, V. Fidler, A. Bukman, E.M. Roeloffzen, E.R. Groenewoud, et al. The predictive value of ovarian reserve tests for spontaneous pregnancy in subfertile ovulatory women. *Hum Reprod*;23:1800-7. 2008
- [25] 25. L. Muzii, C. Di Tucci, M. Di Felicianantonio, C. Marchetti, G. Perniola, P.B. Panici. The effect of surgery for endometrioma on ovarian reserve evaluated by antral follicle count: a systematic review and meta-analysis. *Hum Reprod*;29:2190-8. 2014
- [26] 26. G. Pados, D. Tsolakidis, E. Assimakopoulos, D. Athanatos, B. Tarlatzis. Sonographic changes after laparoscopic cystectomy compared with three-stage management in patients with ovarian endometriomas: a prospective randomized study. *Hum Reprod*;25:672-7. 2010
- [27] 27. D. Tsolakidis, G. Pados, D. Vavilis, D. Athanatos, T. Tsalikis, A. Giannakou, et al. The impact on ovarian reserve after laparoscopic ovarian cystectomy versus three-stage management in patients with endometriomas: a prospective randomized study. *Fertil Steril*;94:71-7. 2010
- [28] 28. M. Candiani, J. Ottolina, E. Posadzka, S. Ferrari, L.M. Castellano, I. Tandoi, et al. Assessment of ovarian reserve after cystectomy versus 'one-step' laser vaporization in the treatment of ovarian endometrioma: a small randomized clinical trial. *Hum Reprod*;33:2205-11. 2018
- [29] 29. O. Mircea, L. Puscasiu, B. Resch, J. Lucas, P. Collinet, P. von Theobald, et al. Fertility Outcomes After Ablation Using Plasma Energy Versus Cystectomy in Infertile Women With Ovarian Endometrioma: A Multicentric Comparative Study. *J Minim Invasive Gynecol*;23:1138-45. 2016
- [30] 30. A. Sugita, A. Iwase, M. Goto, T. Nakahara, T. Nakamura, M. Kondo, et al. One-year follow-up of serum antimüllerian hormone levels in patients with cystectomy: are different sequential changes due to different mechanisms causing damage to the ovarian reserve? *Fertil Steril*;100:516-22.e3. 2013
- [31] 31. N. Saito, Y. Yamashita, K. Okuda, K. Kokunai, Y. Terai, M. Ohmichi. Comparison of the impact of laparoscopic endometriotic cystectomy and vaporization on postoperative serum anti-Müllerian hormone levels. *Asian J Endosc Surg*;11:23-9. 2018