



EGYPTIAN ACADEMIC JOURNAL OF  
**BIOLOGICAL SCIENCES**  
**ENTOMOLOGY**


A



ISSN  
1687-8809

[WWW.EAJBS.EG.NET](http://WWW.EAJBS.EG.NET)

**Vol. 16 No. 4 (2023)**



## Effects of Tramadol and Cypermethrin on the Histology of *Sarcophaga ruficornis* Larvae and Their Concentrations in Postmortem Rabbit Tissues and Their Post-Feeding Larvae

Mohammed Z. Y. Aly; Khaled S. M. Osman; Gihan H. M. Ali and Salwa I. Sebak\*

Department of Zoology, Faculty of Science, South Valley University.

\*E-mail: [salwa\\_ibrahim@sci.svu.edu.eg](mailto:salwa_ibrahim@sci.svu.edu.eg)

### ARTICLE INFO

#### Article History

Received:14/11/2023

Accepted:19 /12 /2023

Available: 23/12 /2023

#### Keywords:

Sarcophagidae,  
*Sarcophaga ruficornis*,  
Entomotoxicology,  
Tramadol,  
Cypermethrin,  
HPLC.

### ABSTRACT

*Sarcophaga* has forensic and medical importance because its larvae are commonly associated with cadavers. This study aims to determine tramadol and cypermethrin levels in postmortem rabbit tissues and inside the larvae of *Sarcophaga ruficornis* that invade these corpses and explore the histological effects of tramadol and cypermethrin on *Sarcophaga ruficornis* larvae. To accomplish these objectives, three groups of rabbits were used. The first group received double LD<sub>50</sub> of tramadol hydrochloride; the second group received double LD<sub>50</sub> of cypermethrin; and the third group received saline solution and was killed by air injection and used as a control. After the deaths of all rabbits, stomach, liver, kidney, gall bladder, lung, spleen tissues and *Sarcophaga ruficornis* larvae were taken. Tramadol and cypermethrin concentrations in postmortem tissues and *Sarcophaga ruficornis* larvae were analyzed using (HPLC). The current study demonstrated that all rabbit tissues treated with tramadol and cypermethrin were positive for these toxins, except tissues of the gall bladder, lung and spleen, which were negative. However, all control rabbit tissues were negative. The toxicological analysis showed that tramadol and cypermethrin were transferred from the administered rabbits to the feeding *Sarcophaga ruficornis* larvae. Histological observations revealed various pathological changes in larvae, especially deformities in the structures of the cuticular body wall, muscles and fat bodies with damage to the epithelial cells lining the midgut. Therefore, histological examination of insects is used in forensic entomology when drugs are suspected as a cause of death.

### INTRODUCTION

The focus of forensic medical entomology, often known as medico-criminal entomology, involves the crucial role of arthropod evidence in resolving crimes (Byrd and Sutton 2020). Studying insects involves determining the postmortem interval (PMI), the place of death and the reason for death (Byrd and Castner 2001). A variety of different vertebrate and invertebrate scavengers are attracted to a decaying corpse (Muñoz-Lozano *et al.*, 2019), while decay's products can cause alterations to the original soil flora and fauna (Barton *et al.*, 2013).

Sarcophagid flies (also known as flesh flies) visiting a corpse generally originate from the synanthropic dement, which is native to the subtropics or even the tropics. They are an integral part of the insect faunal succession and truly represent the first crucial destruction step necessary for essential decomposition (Pape, 1996; Povolny, 1997 and Singh and Bharti, 2008). However, sarcophagids have unique characteristics that make it easier to estimate PMI<sub>min</sub> when compared to other fly species. Firstly, many flesh flies are well known for using the ovoviviparous (or ovarviparous) reproductive technique; they directly deposit maggots on a corpse instead of laying eggs (Byrd and Castner, 2010; Singh and Bharti, 2008 and Szpila *et al.*, 2015). Secondly, due to their larger size, they are more observable than others (Cai, 2015; Pape, 1996 and Tomberlin and Benbow, 2015). Third, throughout various stages of the decay of corpses, sarcophagid flies become more active (Anderson and VanLaerhoven, 1996; Povolny, 1997 and Silahuddin *et al.*, 2015). Furthermore, because they are more effective substrate colonizers than blowflies, they may play a significant role in the decomposition of buried carrion (Pastula and Merritt, 2013). Sarcophagid flies should be widely used to determine the PMI, as previously mentioned. The presence of toxins or other drugs in decaying corpses affects the growth rate of forensic insects via food eating or food shackles transmitted by necrophagous insects, which could be an important cause of inaccurate estimation of the postmortem interval (PMI) (Abd Al Galil *et al.*, 2020). So, a new field of forensic entomology is entomotoxicology, which uses forensic insects to detect the presence of toxins or other drugs ingested by the victim before death via toxicological analysis (Campobasso *et al.*, 2019 and Samnol *et al.*, 2020).

Opioid analgesics with a central action, such as tramadol, are employed to treat mild to extreme pain (Shipton, 2000). Tramadol has a dual mode of action that causes its analgesic and sedative effects by binding to the  $\mu$ -opioid receptor and suppressing the release of norepinephrine and serotonin, which reduces sensitivity to pain (El-Hadidy and Helaly, 2015). In contrast to other conventional opioid drugs, tramadol modifies the activity of neurotransmitters involved in pain modulation, such as norepinephrine and serotonin, which stimulate descending pain-inhibitory pathways, as well as monoamines (Wiffen *et al.*, 2017). Tramadol can cause serious morbidity and death when used at overdose levels (AbouZied, 2016). Tramadol is used as an aphrodisiac and as a recreational drug, although they mostly use it as an energy booster (Salem, *et al.*, 2008 and AbouZied, 2016). Only in 2004 did the medication receive a prescription (WHO, 2006 and Fawzi, 2011). Insect colonization on cadavers may stall as a result of the presence of this drug in a dead body, which renders the body unattractive to colonize insects after death (Hamdy *et al.*, 2022).

Cypermethrin is considered a pyrethroid compound that has been broadly utilized because of its powerful insecticidal properties and slow pest resistance (Aggarwal *et al.*, 2015). Because of its weak cutaneous absorption, quick metabolism, low tissue accumulation, and ambient persistence, it is regarded as less hazardous for human usage (Parajuli, 2006). Only a few instances of accidental pyrethroid poisoning at work have been reported (Ray and Fry, 2006), however, poisoning with a fatal or suicidal intent is incredibly rare (Bradberry *et al.*, 2005). However, pyrethroid poisoning may become more common due to its extensive usage and unregulated over-the-counter availability in our country (Aggarwal *et al.*, 2015).

This study aims to estimate the postmortem concentrations of tramadol and cypermethrin in rabbit tissues and *Sarcophaga ruficornis* larvae and explore the histological effects of tramadol and cypermethrin on *Sarcophaga ruficornis* third-instar larvae.

## MATERIALS AND METHODS

### Sampling of Rabbit Tissues for Toxicological Analysis:

Three healthy male rabbits, *Oryctolagus cuniculus*, were chosen to mimic a newborn's delicate skin and they were distinguished by a relatively constant size ( $\approx 600 \pm 50$  gm). The aforementioned rabbits were purchased locally in a variety of colors. Rabbits were divided randomly into three groups. The first group received a toxin with a double LD<sub>50</sub> of tramadol hydrochloride (LD<sub>50</sub>=132 mg/kg) via ear vein injection. A toxic dose of 132 mg/kg of rabbit was calculated according to Aly *et al.* (2023). The second group received a toxin with a double LD<sub>50</sub> of cypermethrin (LD<sub>50</sub>=126  $\mu$ /kg) via ear vein injection. A toxic dose of 126  $\mu$ /kg rabbit was calculated according to Aly *et al.* (2023), while the third group received saline solution at the ear vein and was injected with air to simulate a natural death situation without the use of any drugs or chemicals and was used as a control.

After the death of all rabbits, by making a cut on the rabbits' ventral side, tissues from the stomach, liver, kidney, gall bladder, lungs, and spleen were collected. 1.0 gm of each fresh tissue was dissected out over a piece of aluminum foil cooled with ice. After weight, the fresh tissue was put in a small plastic bag and immediately frozen in the deep freezer (-80) until analysis.

Also, ten third-feeding larval instars of *Sarcophaga ruficornis* were collected randomly from all treated rabbit carrions and control groups. All collected insects were placed in glass vials and preserved in a deep freezer (-80) until analysis.

### Tissue Extraction for Toxicological Analysis:

0.1 gm from each sample of different rabbit tissues (stomach, liver, kidney, gall bladder, lung and spleen) as well as the 3<sup>rd</sup> larval instars from the control and treated groups was homogenized in 1 ml of phosphate buffer at pH 7.4. 50 ml of the homogenized samples were mixed with 100 ml of an acidic ammonium sulfate solution (250g of ammonium sulfate in 1 L of 20% hydrochloric acid). It was shaken for twenty minutes and then heated in an oven for two hours at 80°C. The pH of the filtered solution was increased to 8.9 by adding ammonia. Then 100 ml of chloroform-isopropanol was added to the samples at a ratio of 80:20 v/v and shaken for 20 minutes. Afterwards, it was poured into the decanter and underneath the organic phase which contained tramadol or cypermethrin, and was separated in a beaker. After drying, 1 ml of methanol was added to the sample (the residue) and using a syringe of 0.2  $\mu$ l, the sample was filtered, transferred, and placed in a 1.5 ml polypropylene Eppendorf tube, where 20  $\mu$ l of it was introduced into the chromatographic system (Salimi *et al.*, 2018).

### HPLC and Tissue Analysis:

High-performance liquid chromatography (HPLC Agilent 1260 series) with a UV-visible spectrophotometric detector at 218 nm was used to evaluate the levels of toxins (tramadol and cypermethrin) in both the control and treated groups. The separation was carried out using an Eclipse Plus C18 column (4.6mm x 100mm); the mobile phase consists of 0.1 tri-floro-acetic acid in water, acetonitrile and methanol (70: 25: 5 v/v) at a flow rate of 1 ml/min. The injection volume was 20  $\mu$ l for each sample solution. The column temperature was maintained at 40 °C.

### Histological Investigations:

The histological examinations were carried out using the H&E (hematoxylin and eosin) stain on the 3<sup>rd</sup> larval instars of *Sarcophaga ruficornis* according to Bancroft (1996). Third-instar larvae of *Sarcophaga ruficornis* were collected from both treated and control groups and fixed in Carnoy's solution for 2 hours, dehydrated in 100% ethyl alcohol for approximately three times (15 minutes each) and cleared in methyl benzoate for about

three times (8 hours each) and toluene for approximately three times (2 hours total), then embedded in paraffin wax at 60 °C in an oven for about three times (2 hours each). Leica RM microtomes were used to slice paraffin wax blocks into 7-micron sections. The sections were then mounted on glass slides using xylene, rehydrated using descending ethyl alcohol (100%, 90%, 70%, and 50%), cleared with distilled water and stained with haematoxylin and eosin (H&E). Dehydration was then accomplished using an ascending series of ethyl alcohol (50%, 70%, 90% and 100%), washed by xylene and mounted by DPX (Drury and Wallington, 1976). All sections were photographed and examined using an Olympus light microscope (BX-50, Olympus, Japan).

## RESULTS AND DISCUSSION

### Entomo-Toxicological Results:

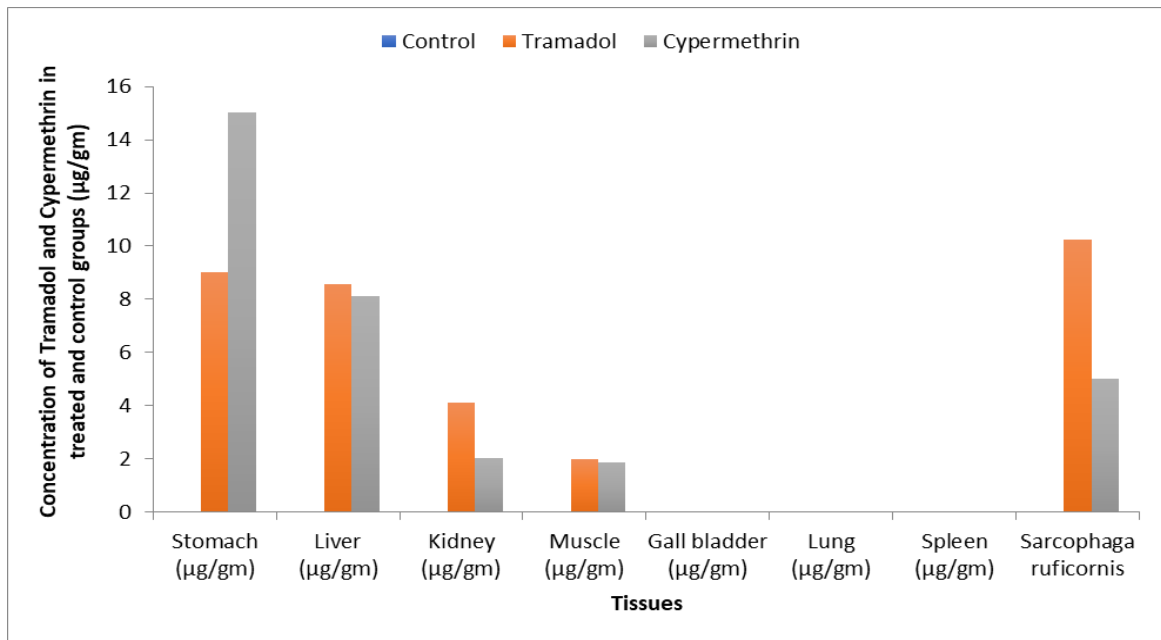
Results presented in Table 1 and Figure 1 showed that all tissues collected from rabbits receiving double LD<sub>50</sub> of tramadol and cypermethrin were positive for these toxins, except tissues of the gall bladder, lung and spleen, which were negative. However, all tissues collected from the control rabbit were negative. The highest concentrations of tramadol were detected in the stomach and liver, recording 10.23 µg/gm and 8.55 µg/gm, respectively, followed by the kidney (4.12 µg/gm) and then muscles (1.98 µg/gm). Also, the highest concentrations of cypermethrin were detected in the stomach and liver, recording 15.02 µg/gm and 8.11 µg/gm, respectively, followed by the kidney (2.04 µg/gm) and muscles (1.86 µg/gm). Furthermore, the arrangement of the rabbit tissues might be as follows, depending on the tramadol and cypermethrin concentrations: stomach, liver, kidney and muscles.

The toxicological analysis from the current study showed that tramadol and cypermethrin were transferred from the administered rabbits to the feeding third larval instar of *Sarcophaga ruficornis*. However, the concentrations of tramadol and cypermethrin detected in the feeding third larval instar were observed lower than those recorded in rabbit tissues. The concentrations of tramadol and cypermethrin were determined in the 3rd larval instars of *Sarcophaga ruficornis*, recording 9.03 µg/gm and 5.02 µg/gm, respectively.

**Table 1:** Concentrations of tramadol and cypermethrin in different postmortem tissues of rabbits and inside 3rd instar larvae of *Sarcophaga ruficornis*.

Tissues	Control	Tramadol	Cypermethrin
Stomach (µg/gm)	ND	9.03	15.02
Liver (µg/gm)	ND	8.55	8.11
Kidney (µg/gm)	ND	4.12	2.04
Muscle (µg/gm)	ND	1.98	1.86
Gall bladder (µg/gm)	ND	ND	ND
Lung (µg/gm)	ND	ND	ND
Spleen (µg/gm)	ND	ND	ND
<i>Sarcophaga ruficornis</i> third larval instar	ND	10.23	5.02

Where ND Non detected



**Fig. 1:** Concentrations of tramadol and cypermethrin in postmortem rabbit tissues and inside third-instar larvae of *Sarcophaga ruficornis*.

### Histological Results:

The histological examinations were carried out to control and treat the third larval instar of *Sarcophaga ruficornis*.

#### Normal Histology of Control Larvae:

The integument of the normal third larval instar of *Sarcophaga ruficornis* is composed of a cuticle, epidermis and basement membrane. The outer-dense layer of the cuticle, known as the epicuticle, forms a continuous layer covering the cuticular surface. The procuticle refers to the area of the cuticle that is between the epicuticle and the epidermal cell layer, which represents the majority of the entire cuticle and consists of the exocuticle (the outermost layer) and the endocuticle (the innermost layer). Finally, the epidermal cell layer (Fig. 2).

The muscle layer found beneath the cuticle consists of bundles of striated fibers that display a closely packed pattern. Each muscle fiber is composed of a number of myofibrils that occupy the entire fiber cross-section (Fig. 3).

The midgut of the 3<sup>rd</sup> instar *Sarcophaga ruficornis* larvae is the longest part of the alimentary canal. It is coiled and convoluted inside the body cavity and it is the most effective part of the alimentary canal where digestion and absorption occur. The external surface of the midgut is extremely smooth, with outer longitudinal and inner circular muscles. The peritrophic membrane is present within the central lumen of the midgut tissue, which is preceded by a single layer of cuboidal epithelial cells found on the basement membrane. The peritrophic membrane is a thin, thread-like structure with a translucent membrane. Epithelial cells project inward from their basement membranes (Fig. 4).

The normal fat bodies of *Sarcophaga ruficornis* consist of two layers: an outer layer composed of ribbons under the body wall and a visceral layer located between the various organs. The fat body consists mainly of a large number of storage cells called trophocytes, which seem to be composed of a nucleus and cytoplasm (Fig. 5).

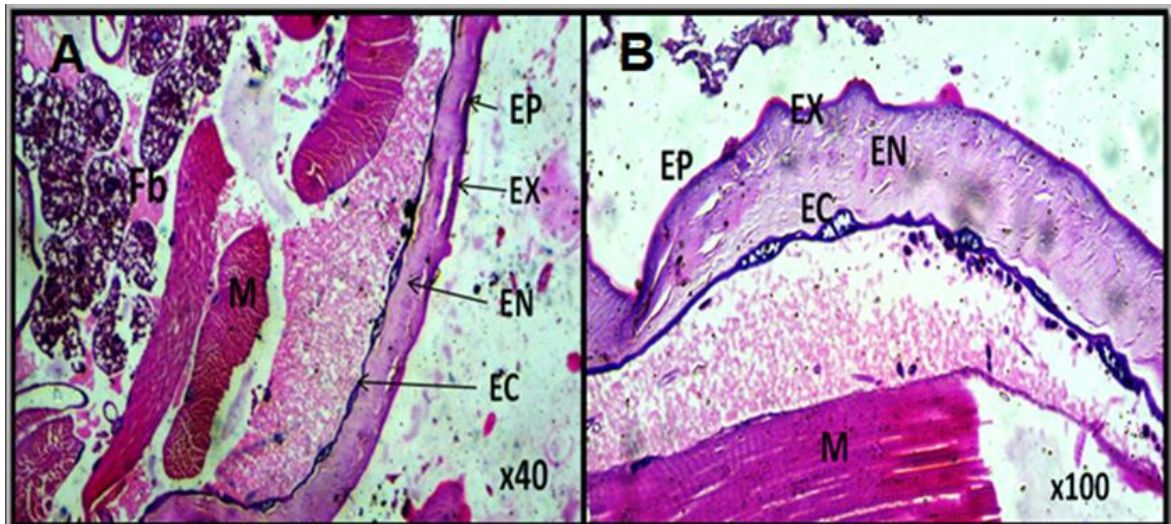
#### Histopathological Studies of Treated Larvae:

The third larval instar of *Sarcophaga ruficornis* treated with tramadol and cypermethrin suffered from different pathological changes, especially in the cuticle, gut,

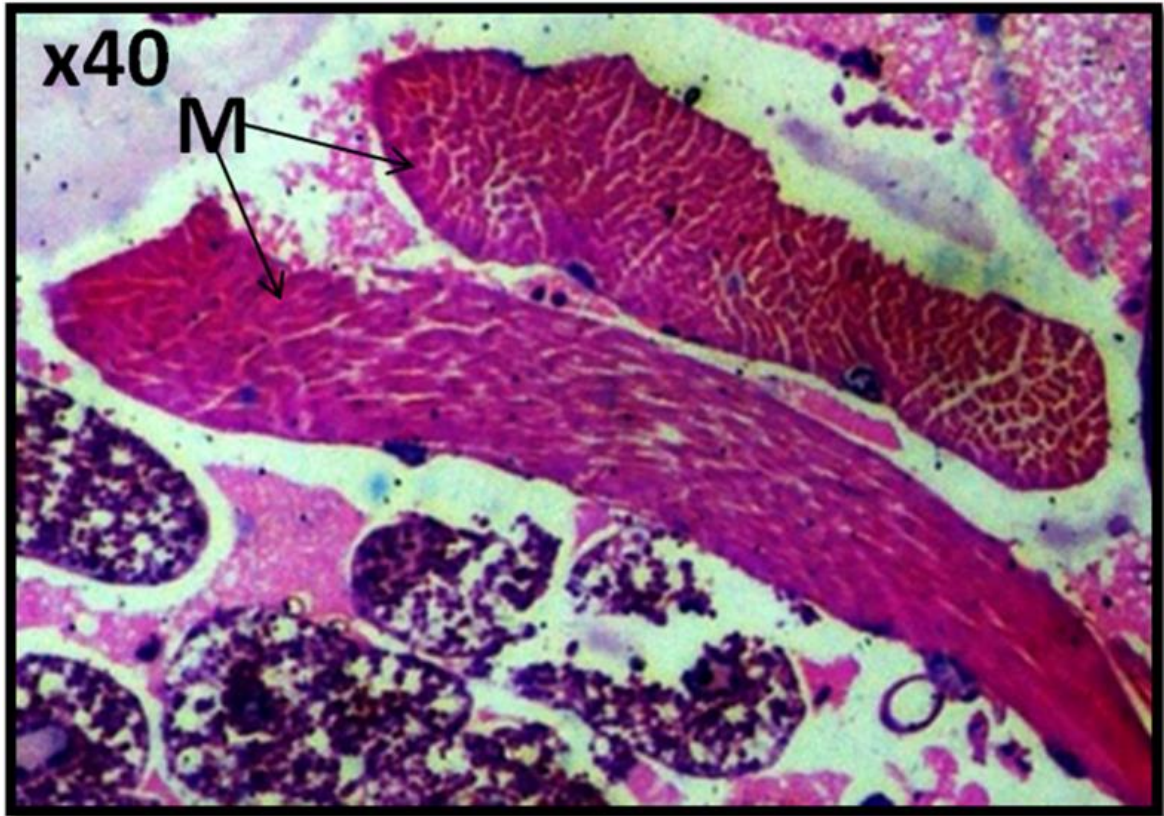
fat bodies and muscles. Tramadol treatment resulted in severe integument damage in third-instar *Sarcophaga ruficornis* larvae, where the epicuticle has completely disintegrated and an exocuticle was observed in some regions; irregular thickening of the cuticle; disorganization of epithelial cells of the epidermis and the nucleus being absent, accompanied by the removal of the cuticle from the inner cellular layer of epidermal cells (Fig. 6). However, larvae of *Sarcophaga ruficornis* treated with cypermethrin showed thinning of the cuticular surface with the detachment of epithelial cells of the epidermis away from the cuticle and the degeneration of the epidermis in some regions, as shown in (Fig.7).

Transverse sections through the midgut of 3rd larvae of *Sarcophaga ruficornis* treated with tramadol showed prominent enlargement, distorted shape and cellular disorganization of epithelial cells. The nuclei become absent in most cells. Vacuolization of epithelial cells was noticed, as was the disappearance of boundaries between cells (Fig. 8). While the midgut of larvae treated with cypermethrin showed destruction of the gut wall in addition to epithelial cell necrosis, we noticed some epithelial cells shrinking and others expanding. Additionally, the development of vacuoles in epithelial cells and the separation of certain cells in the lumen were observed (Fig. 9).

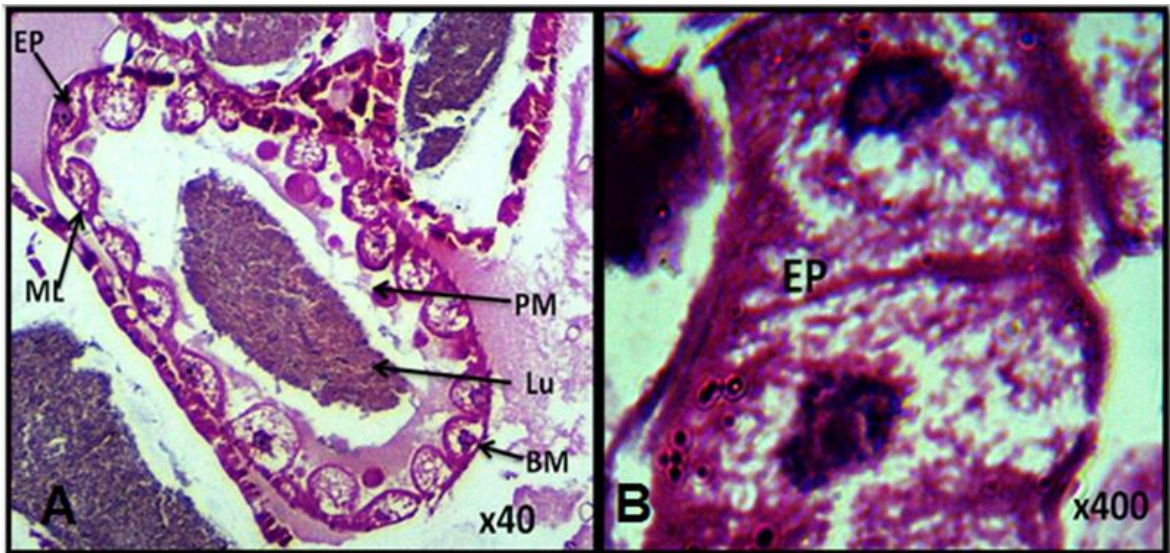
The histological effect of tramadol and cypermethrin on muscles was observed as mild degeneration by the formation of fissures and fragmentation of complete muscular tissue (Figs. 10 and 11). On the other hand, the third larval instar of *Sarcophaga ruficornis* treated with tramadol revealed vacuolization and destruction in the fat bodies in addition to the disappearance of nuclei and cell boundaries of trophocytes in some regions (Fig. 12). However, 3rd larvae treated with cypermethrin suffered from more significant vacuolization on fat bodies; the cell boundaries of trophocytes disappeared and the nuclei became absent (Fig. 13).



**Fig. 2:** A light micrograph of the cuticle of the control *Sarcophaga ruficornis* larvae showed the structure of a normal cuticle. Ep: Epicuticle, Ex: Exocuticle, En: Endocuticle, Fb: Fat body, EC: Cellular layer of epidermal cell, M: muscle fiber. Hematoxyline–eosin stain A (x40) and B (x100).

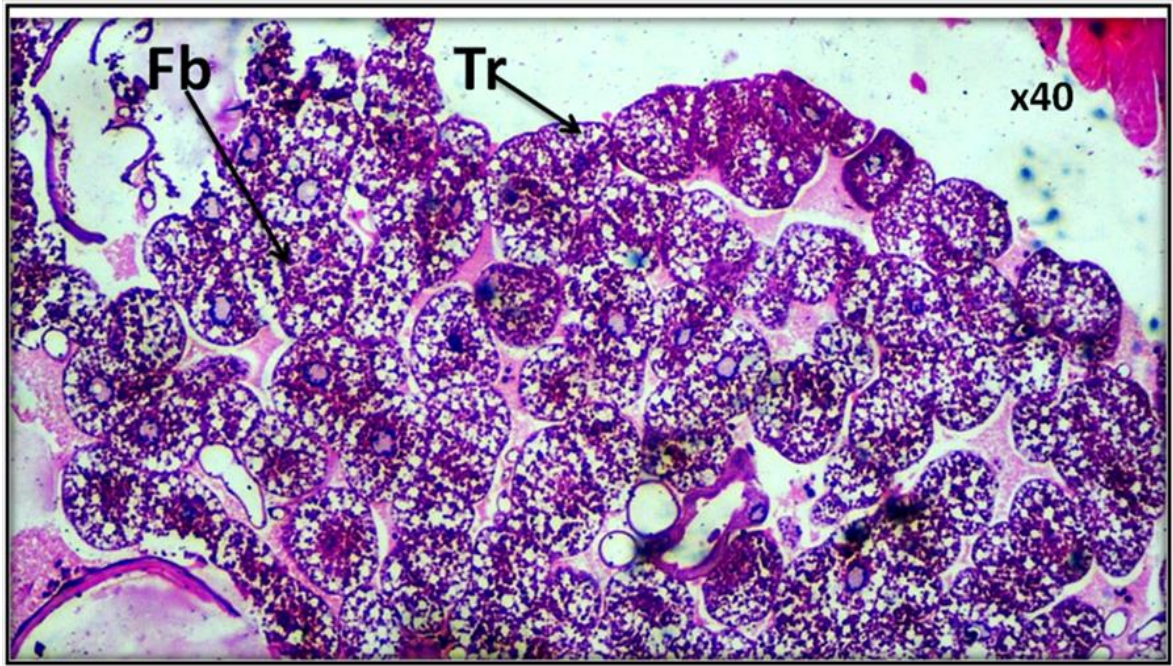


**Fig. 3:** A light micrograph of muscles of control *Sarcophaga ruficornis* larvae showed normal muscle fibers. M: muscle fiber. Hematoxline-eosin stain (x40).

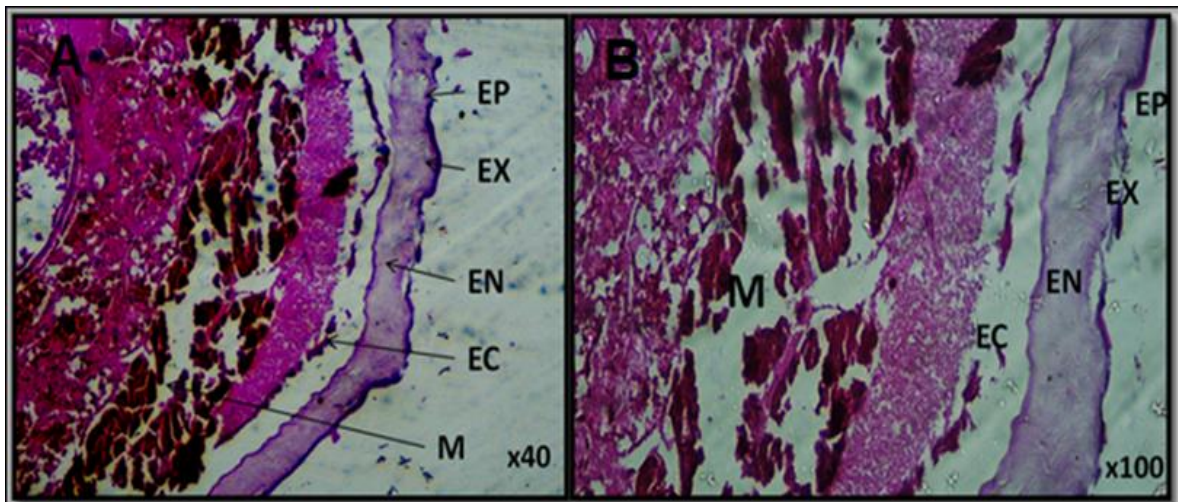


**Fig. 4:** A light micrograph of the midgut of the control *Sarcophaga ruficornis* larvae showed normal midgut layers. EP: Epithelial cells, ML: Muscle layer, BM: Basement membrane, PM: Peritrophic membrane, Lu: Lumen. Hematoxline-eosin stain A (x40) and B (x400).

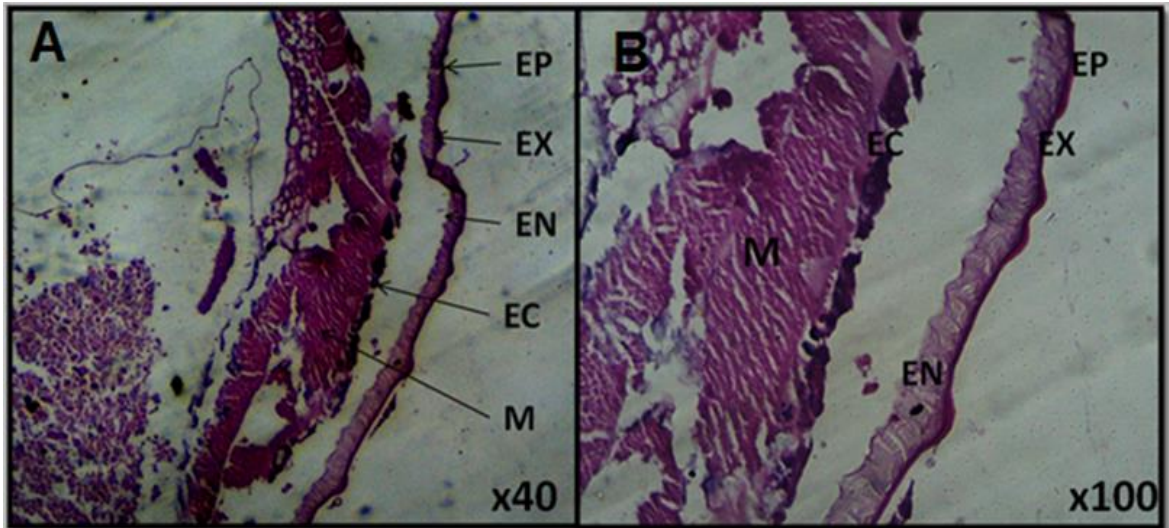




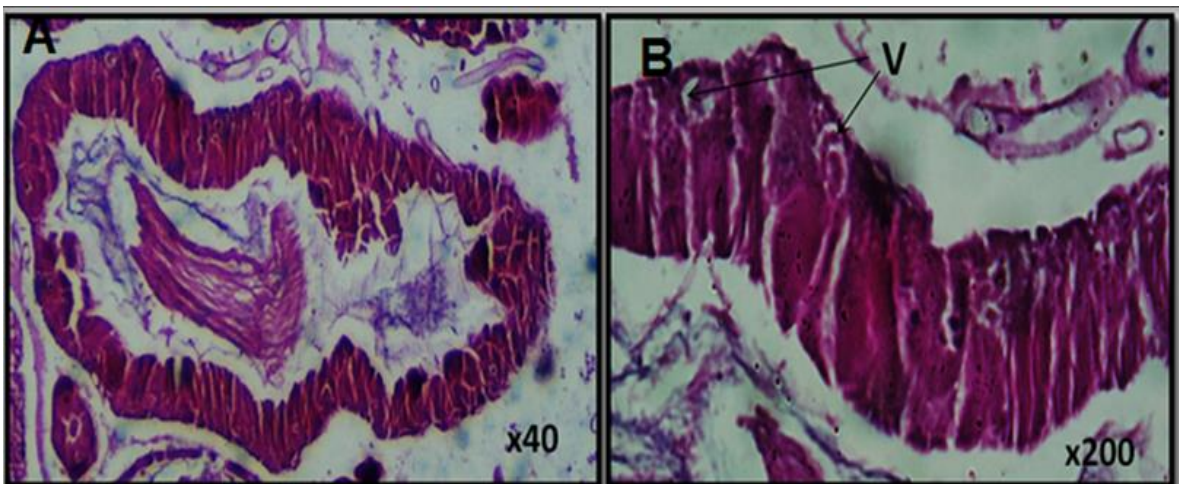
**Fig. 5:** A light micrograph of the fat body of the control *Sarcophaga ruficornis* larvae showed the normal structure of the fat body. Fb: Fat body, Tr: trophocytes. Hematoxiline-eosin stain (x40).



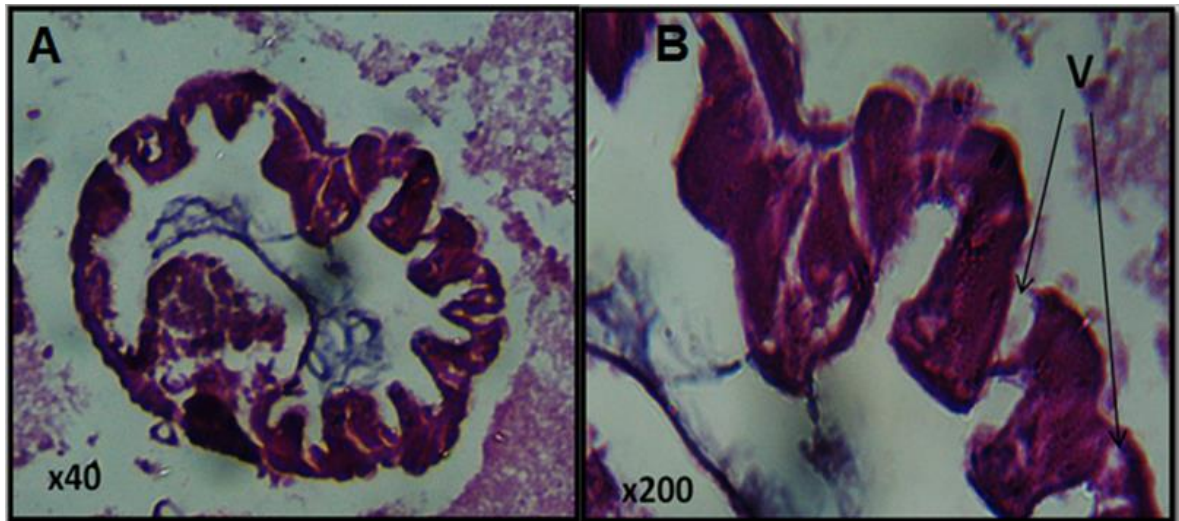
**Fig. 6:** A light micrograph of the cuticle from *Sarcophaga ruficornis* larvae treated with tramadol showed disintegration of the cuticle surface. Ep: Epicuticle, Ex: Exocuticle, En: Endocuticle, EC: Cellular layer of the epidermal cell, M: muscle fiber. Hematoxiline-eosin stain A (x40) and B (x100).



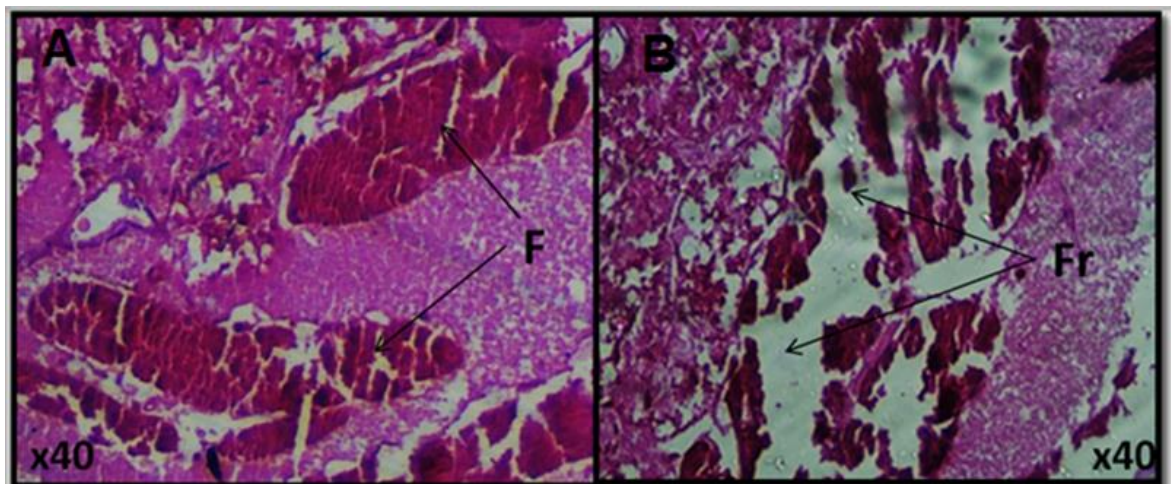
**Fig. 7:** A light micrograph of the cuticle from *Sarcophaga ruficornis* larvae treated with cypermethrin showed destruction and thinning of the cuticular surface and degeneration in skeletal muscles. Ep: Epicuticle, Ex: Exocuticle, En: Endocuticle, EC: Cellular layer of the epidermal cell, M: muscle fiber. Hematoxyline-eosin stain A (x40) and B (x100).



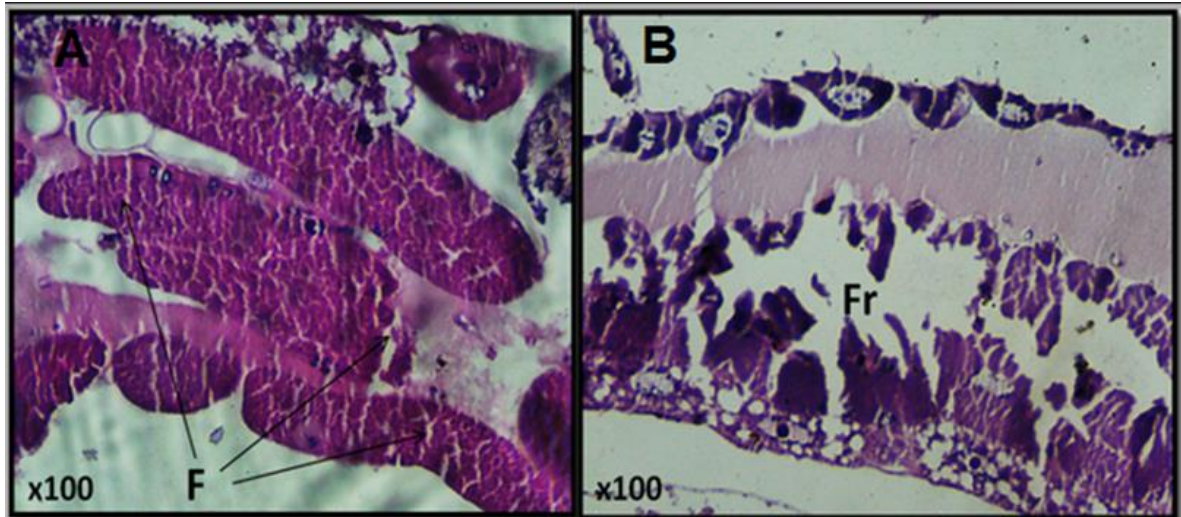
**Fig. 8:** A light micrograph of the midgut from *Sarcophaga ruficornis* larvae treated with tramadol showed vacuolization of epithelial cells with cellular disorganization and the nucleus being absent in the midgut. V: Vacuolization. Hematoxyline-eosin stain A (x40) and B (x200).



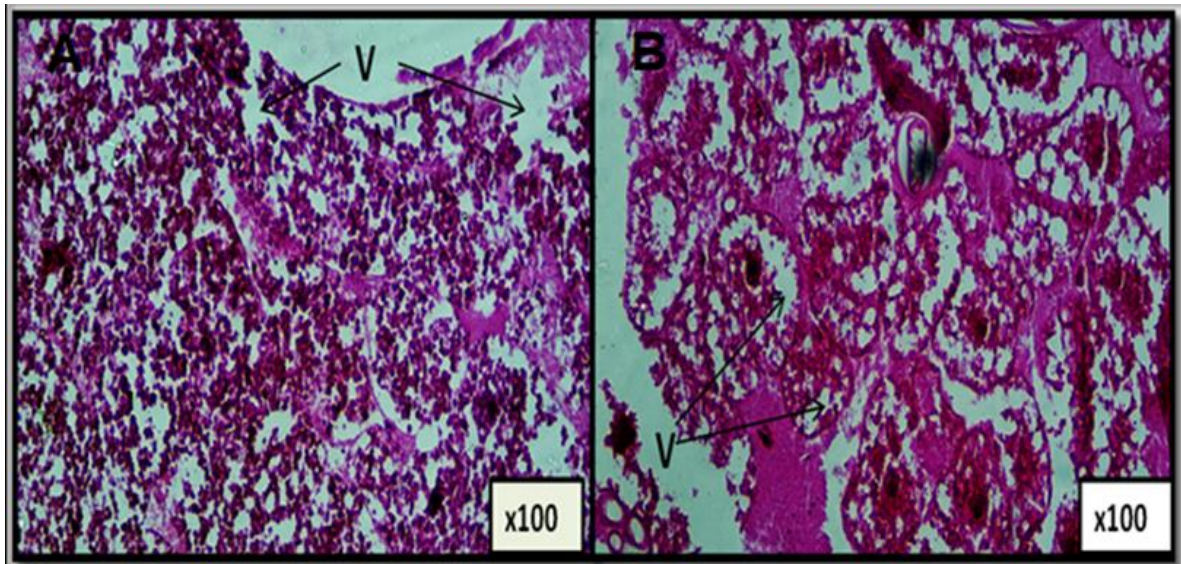
**Fig. 9:** A light micrograph of mid-gut from *Sarcophaga ruficornis* larvae treated with cypermethrin showed necrosis of epithelial cells with destruction and vacuolization of epithelial cells, with some cells detached in the lumen. Hematoxline-eosin stain A (x40) and B (x200).



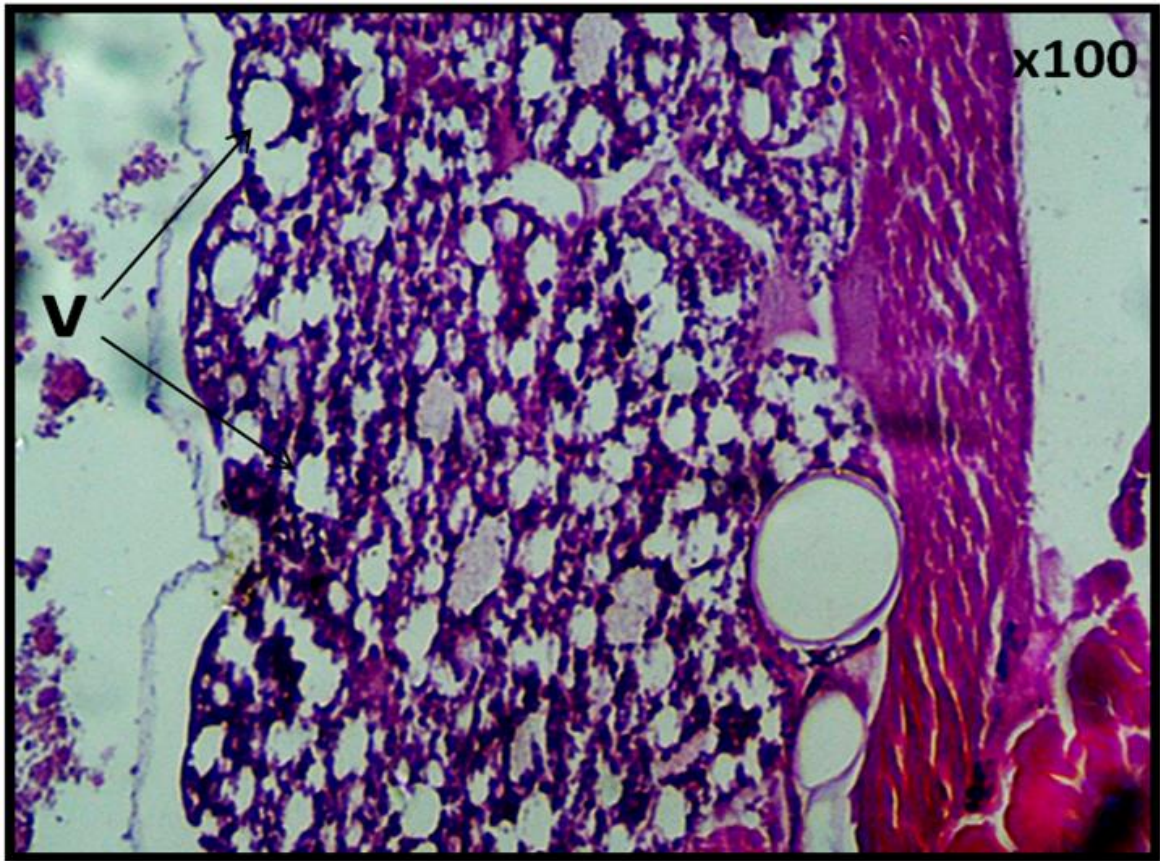
**Fig. 10:** A light micrograph of muscles from *Sarcophaga ruficornis* larvae treated with tramadol showed depletion in muscles. F: Fissures, Fr: Fragmentation. Hematoxline-eosin stain (x40).



**Fig. 11:** A light micrograph of muscle from *Sarcophaga ruficornis* larvae treated with cypermethrin displayed destruction in muscle fibers. F: Fission, Fr: Fragmentation. Hematoxyline-eosin stain (x100).



**Fig. 12:** A light micrograph of the fat body from *Sarcophaga ruficornis* Larvae treated with tramadol showed vacuolization and decomposition in the fat body. V: Vacuolization. Hematoxyline-eosin stain (x100).



**Fig. 13:** A light micrograph of the fat body from *Sarcophaga ruficornis* Larvae treated with cypermethrin showed vacuolization and decomposition in the fat body. V: Vacuolization. Hematoxyline-eosin stain (x100).

## DISCUSSION

A branch of forensic entomology called entomo-toxicology uses forensic insects such as flies and beetles to detect the presence of drugs or other toxins ingested by the victim before death. Toxicological analysis conducted in the current study observed the presence of tramadol and cypermethrin within the rabbit tissues that received double LD50 of these toxins via ear vein injection. Whereas all control rabbit tissues were negative. This result agreed with those of Tahoun and AbouZied (2017) and Elshehaby *et al.* (2019a, 2019b).

The current results showed that the highest concentration of both tramadol and cypermethrin was recorded in the rabbit stomach, followed by the liver and kidney, whereas the lowest concentration was found in muscles, which could be helpful in detecting the possible time of toxin or drug delivered. This result agreed with that of (El-Samad *et al.*, 2011). Williams and Pounder (1997) stated that muscles are the largest single mass of drugs in the body, which frequently reflects that they have a higher drug burden than any other mass of tissue. However, working with muscles is challenging and caution is needed to achieve total medication excretion. This may explain the lower concentration of toxins detected inside muscles in the present study.

If human specimens are not available for toxicological examination to determine the presence of toxins or drugs in cadavers, maggots found in decomposing corpses might be used as an alternative sample (De Letter *et al.*, 2000). The current study carried out toxicological analysis on the only active feeding larval instars, as they serve as the most

reliable source for finding toxins inside the corpse. In agreement with this result, Hédouin *et al.* (2001) and Tjaderborn *et al.* (2007) revealed that metabolism and elimination of drugs by maggots decrease gradually during the development of larvae, and the lowest concentration of drugs was measured in post-feeding maggots and during pupation. So, fully grown maggots that actively feed on carrions should be collected first from the crime scene for toxicological analysis.

Toxicological analysis revealed the presence of tramadol and cypermethrin within all third larval instars of *Sarcophaga ruficornis* reared on rabbit carrions exposed to these toxins. This result agreed with Afifi *et al.* (2022), who recorded the presence of clonazepam inside all larval instars of *Sarcophaga argyrostoma*. Also, El-Ashram *et al.* (2022) stated the existence of aluminum phosphide in third-instar larvae of *Chrysomya albiceps*.

According to the results of the current investigation, tramadol and cypermethrin concentrations found in third-instar larvae were similar to those found in rabbit tissues utilized as food sources. This result is in harmony with that observed in *Chrysomya albiceps* larvae (Elshehaby *et al.*, 2019a) reared on rabbit tissues containing tramadol and larvae of *C. vicina* (Introna *et al.*, 1990) reared on human liver tissues containing morphine. However, some studies were in contrast with the results of the current study, such as El-Samad *et al.* (2011) and Tahoun and AbouZied (2017), which found that the concentration of tramadol within larvae was lower than that in animal tissues. In a similar vein, studies by Nolte *et al.* (1992) and Kintz *et al.* (1994) reported that drug concentrations in maggots were significantly lower than those in tissues. In addition, El-Ashram *et al.* (2022), found the concentration of aluminum phosphide in the 3rd larvae body was significantly lower than in rabbit tissues.

Histopathology of insects may be a crucial tool in eco-toxicological assessment since it enables the identification and characterization of internal tissues in insects and helps us comprehend the acute and long-term effects of drugs or toxins on their various tissues and organs. Consequently, in the current study, target organ morphology and cell structure were examined in *Sarcophaga ruficornis* larvae.

The treatment of the 3<sup>rd</sup> instar of *Sarcophaga ruficornis* larvae with a double lethal dose (LD<sub>50</sub>) of tramadol and cypermethrin caused numerous histological changes in the cuticle, midgut and some other organs. Changes in the cuticle included degradation in certain regions of the epicuticle. Vacuoles can be seen between the cuticle and the epidermis. Damage to muscular layers was observed. Detachment of the cuticle from the epidermis was reported as well. Similar histological alterations in the cuticle and epidermis of insects treated with plant extracts and active chemical compounds from plants have been reported by numerous studies, such as Schlüter (1987), which detected some cuticular abnormalities as well as hypodermal cell degeneration in *Epilachna varviests* maggots treated with azadirachtin. As well, Khalaf *et al.* (2009) observed that the cuticle detached from the epidermis, the epidermis disintegrated, and the basement membrane was destroyed when *Synthesomyia nudesita* larvae were exposed to *Cupressus macrocarpa* and *Alpinia officinarum* volatile oils.

The histopathological effects of tramadol and cypermethrin on the muscles of larvae in the current study ranged from mild degeneration by the formation of fissures to severe degeneration by the fragmentation of whole muscular tissue. Also, Khater (2020) recorded the same result in the larvae of *Dacus ciliates* treated with azadirachtin and attributed the occurrence of fissures and fragmentation to the disintegration of the sarcolemma.

On the other hand, the third instar larvae of *Sarcophaga ruficornis* treated with tramadol and cypermethrin revealed apparent vacuolization and destruction of the fat

bodies. This result is agreed with that of Khater (2020). The midgut was severely affected by the treatment, with some epithelial cells showing symptoms of shrinking and others of swelling. Damaged epithelial cell borders were present.

Furthermore, the present study revealed severe damage in the midgut of larvae treated with tramadol and cypermethrin. This damage included the notable enlargement and malformed shape in cubical epithelial cells, with a detachment of epithelial cells from the basement membrane in the lumen. Similar results were recorded in *Spodoptera frugiperda* treated with *Azadirachta indica* (Roel *et al.*, 2010), in the larvae of *Chrysomya megacephala* treated with malathion (Bakr *et al.*, 2012), in *Chironomus calligraphus* larvae fed with cypermethrin (Lavariás *et al.*, 2017), and in *Spodoptera litura* exposed to leaf extract of *Mirabilis jalapa* (Suryani *et al.*, 2020). Also, the treatment caused other damage in the midgut, with some epithelial cells showing symptoms of shrinking and others of swelling; the appearance of vacuoles in epithelial cells was accompanied by the destruction of the gut wall and epithelial cell borders disappeared. The same results were obtained in *Simulium pertinax* larvae exposed to delta-endotoxins of *Bacillus thuringiensis* (Cavados *et al.*, 2004), in *Blattella germanica* exposed to boric acid (Habes *et al.*, 2006), in *Chrysomya megacephala* fed on malathion (Bakr *et al.*, 2012), in *Periplaneta americana* exposed to N-nitroso-Nmethyl urea (Jain and Ahi, 2014), in *Periplaneta americana* exposed to deltamethrin (Majumdar *et al.*, 2016), in *Culex pipiens* larvae treated with *Carum copticum* methanol extract (Al-Mekhlafi, 2018), in *Dysdercus koenigii* exposed to deltamethrin (Faizan *et al.*, 2019), and in *Sarcophaga ruficornis* exposed to cypermethrin (Mirza and Amir, 2022).

**Ethical Approval:** All experiments in this research were approved by the Research Ethics Committee of the Faculty of Science, South Valley University, Qena governorate, Egypt. (Code No. 005/10/23).

**Competing interests:** The authors declare no conflict of interest.

**Authors Contributions:**

I hereby verify that all authors mentioned on the title page have made substantial contributions to the conception and design of the study, have thoroughly reviewed the manuscript, confirm the accuracy and authenticity of the data and its interpretation, and consent to its submission.

**Funding:** No funding was received.

**Availability of Data and Materials:** All datasets analysed and described during the present study are available from the corresponding author upon reasonable request.

## REFERENCES

- Abd Al Galil, F. M.; Zambare, S. P.; AlMekhlafi, F. A. and AL-Keridis, L. A. (2020). Effect of dimethoate on the developmental rate of forensic importance Calliphoridae flies. *Saudi Journal of Biological Sciences*, 28(2):1267-1271.
- AbouZied, E. M. (2016). Postmortem attraction of sarcosaprophagous Diptera to tramadol-treated rats and morphometric aspects of the developed larvae. *Neotropical Entomology*, 45(3): 326-332.
- Afifi, F. M.; Abdelfattah, E. A. and El-Bassiony, G. M. (2022). Impact of using *Sarcophaga (Liopygia) argyrostoma* (Robineau-Desvoidy, 1830) as a toxicological sample in detecting clonazepam for forensic investigation. *Egyptian Journal of Forensic Sciences*, 12(1): 1-10.
- Aggarwal, P.; Jamshed, N.; Ekka, M. and Imran, A. (2015). Suicidal poisoning with cypermethrin: A clinical dilemma in the emergency department. *Journal of Emergencies, Trauma, and Shock*, 8(2): 123–125.

- Al-Mekhlafi, F. A. (2018). Larvicidal, ovicidal activities and histopathological alterations induced by *Carum copticum* (Apiaceae) extract against *Culex pipiens* (Diptera: Culicidae). *Saudi Journal of Biological Sciences*, 25(1): 52-56.
- Aly, M. Z. Y.; Osman, K. S. M.; Ali, G. H. M. and Sebak, S. I. (2023). Comparative study on forensic insects encountered on rabbit corpses killed with different methods in Upper Egypt. *SVU- International Journal of Veterinary Sciences*, 6(1): 175-201.
- Anderson, G. and VanLaerhoven, S. L. (1996). Initial studies on insect succession on carrion in southwestern British Columbia. *Journal of Forensic Sciences*, 41(4): 617-625.
- Bakr, R. N.; Ramadan, R. H.; El-Sawy, S. and Hussien, S. (2012). Ultrastructure of the midgut of the third larval instar of *Chrysomya megacephala* (Diptera: Calliphoridae) fed on malathion treated diet. *Egyptian Academic Journal of Biological Sciences, D. Histology & Histochemistry*, 3(1): 13-26.
- Bancroft, N. H. (1996). Implementing SAP R/3 How to introduce a large system into a large organization. Prentice-Hall, Inc.
- Barton, P. S.; Cunningham, S. A.; Lindenmayer, D. B. and Manning, A. D. (2013). The role of carrion in maintaining biodiversity and ecological processes in terrestrial ecosystems. *Oecologia*, 171(4): 761-772.
- Bradberry, S. M.; Cage, S. A.; Proudfoot, A. T. and Vale, J. A. (2005). Poisoning due to pyrethroids. *Toxicological Reviews*, 24: 93-106.
- Byrd, J. H. and Castner, J. L. (2001). Forensic entomology: the utility of arthropods in legal investigations. Boca Raton, Florida: CRS Press LLC.
- Byrd, J. and Sutton, L. (2020). Forensic entomology for the investigator. Wiley Interdisciplinary Reviews: *Forensic Science*, 2(4): e1370.
- Byrd, J. H. and Castner, J. L. (2010). Forensic entomology – the utility of arthropods in legal investigation. 2nd ed. Boca Raton (FL): CRC Press.
- Cai, J. F. (2015). Forensic entomology. Beijing: People's Medical Publishing House.
- Campobasso, C. P.; Bugelli, V.; Carfora, A.; Borriello, R. and Villet, M. H. (2019). Advances in entomotoxicology. Weaknesses and strengths. In Byrd, J. and Tomberlin, J. K. (Eds.), Forensic entomology: the utility of arthropods in legal investigations, CRC Press, Boca Raton, FL, pp. 305-330.
- Cavados, C. F. G.; Majerowicz, S.; Chaves, J. Q.; Araújo-Coutinho, C. J. P. C. and Rabinovitch, L. (2004). Histopathological and ultrastructural effects of delta-endotoxins of *Bacillus thuringiensis serovar israelensis* in the midgut of *Simulium pertinax* larvae (Diptera, Simuliidae). *Memórias do Instituto Oswaldo Cruz*, 99: 493-498.
- De Letter, E. A.; De Paepe, P.; Clauwaert, K. M.; Belpaire, F. M.; Lambert, W. E.; Van Bocxlaer, J. F. and Piette, M. H. A. (2000). Is vitreous humour useful for the interpretation of 3, 4- methylenedioxymethamphetamine (MDMA) blood levels?. *International Journal of Legal Medicine*, 114(1): 29-35.
- Drury, R. and Wallington, E. (1976). Carleton's Histological Technique. Oxford University Press, London.
- El-Ashram, S.; Toto, N. A.; El Wakil, A.; Augustyniak, M. and El-Samad, L. M. (2022). Reduced body length and morphological disorders in *Chrysomya albiceps* (Diptera: Calliphoridae) larvae reared on aluminum phosphide-treated rabbits. *Scientific Reports*, 12(1): 1-9.
- El-Hadidy, M. A. and Helaly, A. M. (2015). Medical and psychiatric effects of long-term dependence on high dose of tramadol. *Subst Use Misuse*, 50(5): 582 – 589.
- El-Samad, L. M.; El-Moaty, Z. A. and Makemer, H. M. (2011). Effects of tramadol on the development of *Lucilia sericata* (Diptera: Calliphoridae) and detection of the drug



- concentration in postmortem rabbit tissues and larvae. *Journal of Entomology*, 8(4): 353-364.
- Elshehaby, M. I.; Tony, M. F. and Abdellah, N. (2019a). Effects of tramadol on *Chrysomya albiceps* larvae and its concentration in postmortem tissues and larvae. *The Egyptian Journal of Forensic Sciences and Applied Toxicology*, 19(3): 11-24.
- Elshehaby, M.; Tony, M.; Abdellah, N. Z. and Abd Elreheem, A. E. M. (2019b). Effects of sildenafil citrate and diazepam on developmental stages of forensically important fly: *Chrysomya albiceps* (Diptera: Calliphoridae). *International Journal of Entomology Research*, 4(6): 82- 89.
- Faizan, M.; Amir, M.; Gupta, R.; Yasmeen, S. and Pradesh, U. (2019). Insecticide induced alterations in the mid gut of Red Cotton Stainer, *Dysdercus koenigii* (Fabricius)(Hemiptera: Pyrrhocoridae) treated with Deltamethrin. *International Journal of Entomology Research*, 4(4): 1-4.
- Fawzi, M. M. (2011). Some medicolegal aspects concerning tramadol abuse: The new Middle East youth plague 2010. An Egyptian overview. *Egyptian Journal of Forensic Sciences*, 1(2): 99–102.
- Habes, D.; Morakchi, S.; Aribi, N.; Farine, J. P. and Soltani, N. (2006). Boric acid toxicity to the German cockroach, *Blattella germanica*: Alterations in midgut structure, and acetylcholinesterase and glutathione S-transferase activity. *Pesticide Biochemistry and Physiology*, 84(1): 17- 24.
- Hamdy, R.; El-Hamouly, H.; Sawaby, R. F. and Abd El-Bar, M. M. (2022). Identification of insects colonizing carrions of tramadol-intoxicated rabbits and guinea pigs in relation to seasonal variances in Cairo, Egypt. *Egyptian Journal of Pure and Applied Science*, 60(1): 34-61.
- Hédouin, V.; Bourel, B.; Bécart, A.; Tournel, G.; Deveaux, M.; Goff, M. L. and Gosset, D. (2001). Determination of drug levels in larvae of *Protophormia terraenovae* and *Calliphora vicina* (Diptera: Calliphoridae) reared on rabbit carcasses containing morphine. *Journal of Forensic Sciences*, 46(1): 12-14.
- Introna, F.; Dico, C. L.; Caplan, Y. H. and Smialek, J. E. (1990). Opiate analysis in cadaveric blowfly larvae as an indicator of narcotic intoxication. *Journal of Forensic Science*, 35(1): 118-122.
- Jain, R. and Ahi, J. (2014). Effect of N-nitroso-N-methylurea on midgut in *Periplaneta americana*. *International Journal of Pure and Applied Bioscience*, 2(6): 258-264.
- Khalaf, A. F. A.; Hussein, K. T. and Shoukry, K. K. (2009). Biocidal activity of two botanical volatile oils against the larvae of *Synthesiomyia nudiseta* (Wulp) (Diptera: Muscidae). *Egyptian Academic Journal of Biological Sciences. A, Entomology*, 2(1): 89-101.
- Khater, K. S. (2020). Histopathological Effects of Azadirachtin on *Dacus ciliatus* Loew (Diptera: Tephritidae). *Egyptian Academic Journal of Biological Sciences, D. Histology and Histochemistry*, 12(1): 91-104.
- Kintz, P.; Tracqui, A. and Mangin, P. (1994). Analysis of opiates in fly larvae sampled on a putrefied cadaver. *Journal-Forensic Science Society*, 34(2): 95-97.
- Lavariás, S.; Arrighetti, F. and Siri, A. (2017). Histopathological effects of cypermethrin and *Bacillus thuringiensis var. israelensis* on midgut of *Chironomus calligraphus* larvae (Diptera: Chironomidae). *Pesticide Biochemistry and Physiology*, 139: 9-16.
- Majumdar, S.; Amir, M.; Gupta, R. and Yasmeen, S. (2016). Histopathological effect of deltamethrin on the midgut of American cockroach, *Periplaneta americana* (Linn.)(Diptera: Blattellidae). *Journal of Entomology and Zoology Studies*, 4: 13-16.
- Mirza, B. and Amir, M. (2022): Impact of insecticide cypermethrin on the midgut

- histology of adult flesh fly, *Sarcophaga ruficornis* Fab. (Diptera: Sarcophagidae). *International Journal of Entomology Research*, 7(1): 120- 123.
- Muñoz-Lozano, C.; Martín-Vega, D.; Martínez-Carrasco, C.; Sánchez-Zapata, J. A.; Morales-Reyes, Z.; González, M. and Moleón, M. (2019). Avoidance of carnivore carcasses by vertebrate scavengers enables colonization by a diverse community of carrion insects. *PLoS One*, 14(8): e0221890.
- Nolte, K. B.; Pinder, R. D. and Lord, W. D. (1992). Insect larvae used to detect cocaine poisoning in a decomposed body. *Journal of Forensic Science*, 37(4): 1179-1185.
- Pape T. (1996). Catalogue of the Sarcophagidae of the world (Insecta: Diptera). Florida, Gainesville: Associated Publishers.
- Parajuli, S. (2006). Cypermethrin poisoning and anti-cholinergic medication-a case report. *Internet Journal of Medical Update*, 1(2).
- Pastula, E. C. and Merritt, R. W. (2013). Insect arrival pattern and succession on buried carrion in Michigan. *Journal of medical entomology*, 50(2): 432-439.
- Povolny, D. (1997). The flesh-flies of Central Europe (Insecta, Diptera, Sarcophagidae). *Spixiana Suppl.*, 24: 1-260.
- Ray, D. E. and Fry, J. R. (2006). A reassessment of the neurotoxicity of pyrethroid insecticides. *Pharmacology & therapeutics*, 111(1): 174-193.
- Roel, A. R.; Dourado, D. M.; Matias, R.; Porto, K. R.; Bednaski, A. V. and Costa, R. B. D. (2010). The effect of sub-lethal doses of *Azadirachta indica* (Meliaceae) oil on the midgut of *Spodoptera frugiperda* (Lepidoptera, Noctuidae). *Revista Brasileira de Entomologia*, 54: 505- 510.
- Salem, E. A.; Wilson, S. K.; Bissada, N. K.; Delk, J. R.; Hellstrom, W. J. and Cleves, M. A. (2008). Tramadol HCL has promise in on-demand use to treat premature ejaculation. *The Journal of Sexual Medicine*, 5(1): 188-193.
- Salimi, M.; Rassi, Y.; Chatrabgoun, O.; Kamali, A.; Oshaghi, M. A.; ShiriGhaleh, V.; Moradi, M.; Rafizadeh, S.; Akbarzadeh, K. and Parkhideh, S. Z. (2018). Toxicological analysis of insects on the corpse: a valuable source of information in forensic investigations. *Journal of arthropod-borne diseases*, 12(3): 219.
- Samnol, A.; Kumar, R. and Mahipal, S. M. (2020). Study of insect larva used to detect toxic substance through decomposed bodies. *International Journal of Forensic Science and Pathology (IJFP)*, 7(1): 420-422.
- Schlüter, U. (1987). Effects of azadirachtin on developing tissues of various insect larvae. In Natural pesticides from the neem tree and other tropical plants. *Proc. 3rd Int. Neem Conf. Kenya*, pp. 331-348.
- Shipton, E. A. (2000). Tramadol-present and future. *Anaesthesia and intensive care*, 28(4): 363-374.
- Silahuddin, S. A.; Latif, B.; Kurahashi, H.; Walter, D. E. and Heo, C. C. (2015). The importance of habitat in the ecology of decomposition on rabbit carcasses in Malaysia: implications in forensic entomology. *Journal of Medical Entomology*, 52(1): 9-23.
- Singh, D. and Bharti, M. (2008). Some notes on the nocturnal larviposition by two species of *Sarcophaga* (Diptera: Sarcophagidae). *Forensic Science International*, 177(1): 19-20.
- Suryani, A. I.; Hariani, N.; Majid, A. F. and Amalia, D. N. (2020). Histological changes in the midgut of *Spodoptera litura* larvae exposed by the extract of *Mirabilis jalapa* leaves. In IOP Conference Series: *Earth and Environmental Science*, 484: 1-9.
- Szpila, K.; Mądra, A.; Jarmusz, M. and Matuszewski, S. (2015). Flesh flies (Diptera: Sarcophagidae) colonising large carcasses in Central Europe. *Parasitology Research*, 114: 2341-2348.

- Tahoun, I. F. and AbouZied, E. M. (2017). The effect of the tramadol accumulated in rat liver on the development of the immature stages of the flesh fly *Sarcophaga argyrostoma* (Robineau-Desvoidy, 1830) (Diptera: Sarcophagidae). *Journal of the Egyptian Society of Parasitology*, 47(1): 55-64.
- Tjaderborn, M.; Jönsson, A. K.; Hägg, S. and Ahlner, J. (2007). Fatal unintentional intoxications with tramadol during 1995–2005. *Forensic science international*, 173(2-3): 107-111.
- Tomberlin, J. K. and Benbow, M. E. (2015). *Forensic entomology international dimensions and frontiers*. Boca Raton (FL): CRC Press.
- Wiffen, P. J.; Derry, S. and Moore, R. A. (2017). Tramadol with or without paracetamol (acetaminophen) for cancer pain. *Cochrane Database Systematic Reviews*, 5(CD012508): 1-36.
- Williams, K. R. and Pounder, D. J. (1997). Site-to-site variability of drug concentrations in skeletal muscle. *The American journal of forensic medicine and pathology*, 18(3): 246-250.
- World Health Organization (WHO) (2006) 34th ECDD 2006/4.5: assessment of tramadol. Last retrieved at December 09, 2014. Available from: [http://www.who.int/medicines/areas/quality\\_safety/5.2TramadolCritReview.pdf](http://www.who.int/medicines/areas/quality_safety/5.2TramadolCritReview.pdf).

## ARABIC SUMMARY

### تأثير الترامادول والسايبيرمثرين على أنسجة يرقات *Sarcophaga ruficornis* وتركيزهم في أنسجة الأرناب بعد الوفاة ويرقاتها بعد التغذية

محمد زكي يوسف علي، خالد سعيد محمد عثمان، جيهان حسن محمد علي، سلوى إبراهيم سباق  
قسم علم الحيوان، كلية العلوم، جامعة جنوب الوادي

تتمتع ذبابة اللحم بأهمية طبية وشرعية لأن يرقاتها ترتبط عادةً بالجثث. وتهدف هذه الدراسة إلى استكشاف تأثير الترامادول والسايبيرمثرين على يرقات ذبابة اللحم من خلال الفحص النسيجي وتحديد مستويات الترامادول والسايبيرمثرين في أنسجة الأرناب بعد الوفاة وداخل الأطوار اليرقية لذبابة اللحم التي تغزو هذه الجثث. ولتحقيق هذه الأهداف تم استخدام ثلاث مجموعات من الأرناب. تلقت المجموعة الأولى جرعة مضاعفة من هيدروكلوريد الترامادول. وتلقت المجموعة الثانية جرعة مضاعفة من مادة السايبيرمثرين. والمجموعة الثالثة أعطيت محلول ملحي وتم قتلها عن طريق الحقن بالهواء واستخدمت كمجموعة ضابطة. بعد وفاة جميع الأرناب، تم أخذ عينات من المعدة والكبد والكلية والمرارة والرئة والطحال و يرقات ذبابة اللحم. تم تحليل تركيزات الترامادول والسايبيرمثرين في الأنسجة ما بعد الوفاة و يرقات ذبابة اللحم بواسطة تحليل كروماتوجرافي. كما أجريت دراسة لأنسجة العمر اليرقي الثالث لحشرة ذبابة اللحم. وأظهرت نتائج الدراسة الحالية أن جميع عينات الأنسجة التي تم تجميعها من الأرناب التي تلقت جرعات مضاعفة من الترامادول والسايبيرمثرين كانت إيجابية لهذه السموم، باستثناء أنسجة المرارة والرئة والطحال التي كانت سلبية. ومع ذلك، كانت جميع عينات الأنسجة من أرناب المجموعة الضابطة سلبية. أظهر تحليل السمية من الدراسة الحالية أن الترامادول والسايبيرمثرين تم انتقالهما من الأرناب المعاملة إلى يرقات الطور الثالث لذبابة اللحم. في حين كانت تركيزات الترامادول والسايبيرمثرين الموجودة في الطور اليرقي الثالث لذبابة اللحم أقل من تلك الموجودة في أنسجة الأرناب. كشف الفحص النسيجي عن تغيرات مرضية مختلفة في هذه اليرقات، وخاصة التشوهات في تركيب جدار الجسم والعضلات والأجسام الدهنية مع تلف الخلايا الطلائية المبطنة للأمعاء الوسطى، والتي بدورها أدت إلى انخفاض نموها بشكل صحيح مقارنة إلى المجموعة الضابطة. ولذلك، يوصى باستخدام الفحص النسيجي للحشرات في علم الحشرات الشرعي عندما يشتبه في أن المخدرات هي سبب الوفاة. وأظهرت الدراسة الحالية أن جميع عينات الأنسجة من الأرناب المعالجة بالترامادول والسايبيرمثرين كانت إيجابية لهذه السموم، باستثناء أنسجة المرارة والرئة والطحال التي كانت سلبية. ومع ذلك، كانت جميع عينات الأنسجة من أرناب السيطرة سلبية. أظهر تحليل السمية أن الترامادول والسايبيرمثرين قد تم نقلهما من الأرناب المعطاة إلى يرقات *Sarcophaga ruficornis*. كشفت المراقبة النسيجية عن تغيرات مرضية مختلفة في اليرقات، وخاصة التشوهات في هيكل جدار الجسم الجلدي والعضلات والأجسام الدهنية مع تلف الخلايا الظهارية المبطنة للأمعاء الوسطى. ولذلك، يتم استخدام الفحص النسيجي للحشرات في علم الحشرات الشرعي عندما يشتبه في أن المخدرات هي سبب الوفاة.