



## Application of Immunohistochemistry in Rat Models of Erosive Gastritis

Maha Hammady

*Histology and Cell Biology Department,, Faculty of Medicine, University of Alexandria, Alexandria, Egypt.*

**E**rosive gastritis still represents a significant health problem, increasing in prevalence in the last few years. Due to its burden on health and the economy, there is a need for novel biomarkers to understand its molecular pathology and develop new treatments. Immunohistochemistry has emerged as a valuable tool in gastritis research, enabling the visualization and analysis of specific proteins within tissue sections. This review aims to provide a comprehensive overview of the application of immunohistochemistry in gastritis research, highlighting its contributions to revealing the complex molecular mechanisms involved in the progression of gastritis. The applications gained from these studies hold promise for developing targeted therapies and improving patient outcomes in managing erosive gastritis. Several molecules have been identified and tested in recent years for their clinical relevance in research. In this paper, we will focus on the well-known markers. Furthermore, this review emphasizes diagrammatic illustrations visually representing the molecular interactions underlying pathogenesis. These illustrations enhance the clarity and understanding of the reviewed concepts.

**Keywords:** Immunohistochemistry, erosive gastritis, gastric ulcers, COX-2, Nrf

### Introduction

Gastric mucosal injury is highly prevalent, it ranges from mild gastritis to complicated peptic ulcers and represents the most prevalent gastrointestinal tract (GIT) disorder worldwide. According to estimates, 70% of the population is affected by stomach disorders.[1] Over four million people worldwide are affected by gastric ulcers yearly.[2] Gastric mucosal injury may be in the form of gastritis, an inflammation of the stomach mucosa that can cause mucosal edema, mucosal hyperemia, and superficial erosions. Gastritis may be acute or chronic according to the etiology, and it may progress to more profound, more extensive erosions called gastric ulcers.[3] Gastric ulcer is defined as a localized discontinuity of the gastric mucosa that may extend to the muscularis mucosa and even reach deeper into the submucosa, it can lead to gastric perforation and subsequent internal bleeding, which could be lethal. [4] A gastric ulcer is an advanced form of gastritis, ranging from an asymptomatic condition to epigastric pain and nausea. In addition to the pain and complications

associated with gastric ulcers, it can cause massive bleeding, which can be lethal.

An imbalance between the aggravating factors, such as hydrochloric acid, pepsin enzyme, ingested drugs and chemicals, and the protective factors, including antioxidant enzymes, nitric oxide, mucin production, surface phospholipids, prostaglandins, and growth factors, primarily cause gastric mucosal injury.[5]

In clinical practice, the term “gastritis” is commonly applied to these three categories: erosive (hemorrhagic) gastritis, non-erosive (non-specific) gastritis, and specific types of gastritis.[6]

The most common causes of erosive gastropathy are medications, especially non-steroidal anti-inflammatory drugs (NSAIDs), alcohol, stress due to severe medical or surgical illness, and portal hypertension. Uncommon causes of erosive gastropathy include ischemia, caustic ingestion, and radiation. Erosive gastritis is typically diagnosed at endoscopy. Endoscopic findings include subepithelial hemorrhages, petechiae, and erosions.

\*Corresponding author: Maha Hammady, E-mail: maha.hemdan@alexmed.edu.eg. Tel.: 00201282343560

(Received 11/10/2023, accepted 24/12/2023)

DOI: 10.21608/EJVS.2023.241929.1637

©2024 National Information and Documentation Center (NIDOC)

These lesions are superficial, vary in size and number, and may be focal or diffuse. There usually is no significant inflammatory cell infiltration on histologic examination.[7, 8]

Many agents can be used to induce gastric ulcers in Wistar rats to study the protective or therapeutic potential of new therapies. These are some of the generally used agents for the induction of gastric ulcers:

### **Indomethacin**

It is an NSAID used to relieve pain, reduce inflammation, and control fever. Its primary mechanism of action involves inhibiting the production of prostaglandins, which are involved in the inflammatory response. Indomethacin is widely prescribed for conditions such as arthritis, gout, and many inflammatory disorders[9] . It is commonly used in inducing a rat model of erosive gastritis. Its dose ranges from 40-100 mg/kg body weight received after 24-36 hours of food deprivation. Retrieval of gastric tissues is performed 4-8 hours later. Studies suggest that indomethacin and other NSAIDs causes inhibition of prostaglandin synthesis, accumulation of neutrophil, and subsequent mucosal injury under the effect of oxidative imbalance, reduction of submucosal blood flow, and reduction mucosal cell proliferation[10-15] .

### **Aspirin (Acetylsalicylic acid)**

Aspirin, known for its anti-inflammatory, analgesic, and antipyretic properties, finds application in both human and veterinary medicine. In humans, it serves as a pain reliever for conditions like headaches and muscle aches, an anti-inflammatory for arthritis, and a fever reducer. Additionally, low doses may be recommended for cardiovascular health.[16] In veterinary medicine, aspirin is prescribed for pain management in animals with arthritis or injuries, fever reduction, and addressing musculoskeletal inflammation. Its use in animals should be under veterinary supervision due to variations in sensitivity among species, and caution is advised to ensure its benefits outweigh potential risks.[17] Aspirin is also utilized for inducing erosive gastritis, as it triggers inflammation through the exact pathogenesis described with indomethacin. Overnight food-deprived rats received a single oral dose of 200-300 mg/kg/day body weight for five consecutive days.

Euthanasia of animals and obtainment of gastric tissues is done 4-8 hours later [18-21] .In a study conducted by Elkerdasy *et al.*, a different dosing regimen was employed to induce gastritis using acetylsalicylic acid (200 mg/kg). The rats, which were food-deprived overnight, received a single oral dose of 200 mg/kg of acetylsalicylic acid. This dosage was administered once[21]. In a study by Abdel-Kawi *et al.*, 25 mg/kg body weight was administered intraperitoneally[22] .

### **Ethanol**

Ethanol induces gastritis by solubilizing the protective mucous and causing direct membrane damage, which leads to cell exfoliation and surface erosions and thus increases mucosal permeability to hydrochloric acid and pepsin, which induces further injury[23] . The resultant inflammatory cell recruitment causes further damage by releasing vasoactive products and causing oxidative damage. Moreover, alcohol stimulates gastric acid secretion and reduces gastric blood flow leading to increased apoptosis. To induce gastric mucosal injury, absolute ethanol (95-99%), 1-1.5 mL/200 g body weight is administered orally after fasting for 24-36 hours. Animals can be euthanized one hour after ethanol administration. [23-25] In a study by Abdel-Kawi *et al.*, 1 ml/200 g body weight of 70% ethanol concentration was administered to induce gastric ulcers.[26]

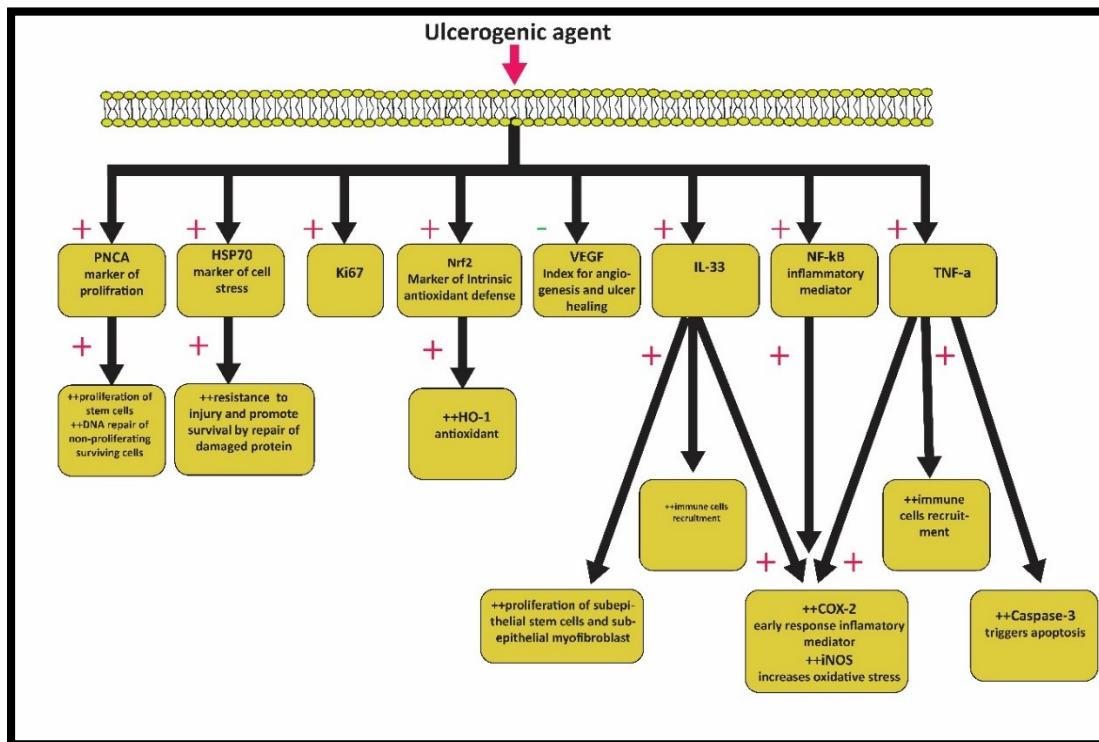
### **Others**

Gastric mucosal lesions can be also induced by hypothermic restraint stress[27-29], ischemia-reperfusion[30, 31], ibuprofen[32, 33], histamine[34, 35], reserpine[36, 37], diethyldithiocarbamate[38, 39], Acetic acid[40-44], serotonin[45, 46] or pylorus ligation (Shay's Method).[47, 48] Erosive gastritis may be studied as part of the adverse effects of other agents such as Sofosbuvir[49], 5-fluorouracil[50], nicotine[51], Tartrazine[52], or tetrachlorodibenzo-p-dioxin (TCDD)[53], or diseases such as diabetes mellites[54].

In general, when studying the protective effects of a specific drug, it is recommended to administer the medication to animals at least two weeks before inducing gastric ulcers. However, when investigating potential therapeutic effects, the induction of the ulcer occurs before administering

**Immunohistochemistry in gastric ulcer research (Fig. 1).**

surgical pathologists to diagnose and determine the stage of different types of malignancies. Moreover, IHC assists researchers in detecting markers, which can provide information on the pathogenesis of multiple diseases by studying their molecular aspects. Furthermore, IHC provides a valuable tool for studying the neuronal pathways controlling many organs. Therefore, IHC links molecular biology, basic sciences, and clinical medicine.[56-65]



Applications of IHC markers in various models of erosive gastritis are shown in table (1).

**TABLE 1. Application of IHC Markers in Various Rat Models of Erosive (Hemorrhagic) Gastritis and Their Significance: A Comparative Analysis**

IHC Marker	Significance	Morphometry (image analysis)[66]	% in the control group	% in the ulcer group	Agent used	Route	Dose/body weight	Reference
	Inflammation marker	The mean area % of COXII immunopositive cells	6± 1	60± 5	Indomethacin	Oral	60mg/kg once	[15]
			0.71 ± 0.1	2.73 ± 0.1			100 mg/kg once	[13]
			0.71 ± 0.1	2.73 ± 0.1	70 % ethanol		1 mL/200 g body weight once	[26]
COX-2		Authors depend on their subjective interpretation	Decreased	Increased	5-fluorouracil	Intraperitoneal	15 mg/kg for five days	[50]
HSP-70	Marker of cell stress	The mean area % of HSP-70 immunopositive cells	10± 1	20± 2	Indomethacin	Oral	60mg/kg once	[15]
IL-33	Inflammation marker	The mean area % of IL-33 immunopositive cells	19.28±0.14	95.12±3.64	Indomethacin	Oral	100 mg/kg once	[14]
PCNA	marker of proliferative activity	The mean area % of PCNA immunopositive cells	15.38±6.1	53.83 ±9.5	Aspirin	Oral	200mg/kg once	[21]
		Authors depend on their subjective interpretation	Decreased	Increased	Sofosbuvir	oral	4 mg/kg daily for five weeks	[49]
VEGF	Index for angiogenesis and ulcer healing	The mean area % of VEGF immunopositive cells	7.77 ± 0.51	1.93% ± 0.41	Absolute ethanol (95-99%)	Oral	1 mL/200 g once	[67]
			16. 83 ± 0.7	6.23 ± 0.34	70 % ethanol	Oral	1 mL/200 g body weight once	[26]
TNF- $\alpha$	Inflammation marker	The mean area % of TNF- $\alpha$ immunopositive cells	0.06± 0.03	8.08± 0.67	Absolute ethanol (95-99%)	Oral	1 mL/200 g body weight once	[67]
Caspase-3	Marker of apoptosis	Authors depend on their subjective interpretation.	Decreased	Increased	5-fluorouracil	intraperitoneal	15 mg/kg body weight injected five days	[50]
iNOS	Marker of oxidative stress	The mean area % of iNOS immunopositive cells	4.29±1.91	29.77±3.64	Tartrazine	Oral	200 mg/kg daily for 60 days	[52]
Ki67	Marker of proliferative activity	the mean area % of Ki67 immunopositive cells	35.88±4.59	56.45±6.90	Tartrazine	Oral	200 mg/kg daily for 60 days	[52]
Chromogranin A	Still being explored	The mean area % of CgA immunopositive cells	32±2	10±2	TCDD	Oral	100 µg/kg daily for eight weeks	[53]
NF- $\kappa$ B	inflammation marker	the mean area % of NF- $\kappa$ B immunopositive cells	0.1±0.01	0.3±0.05	acetic acid	Surgical (subserosal injection)	120 µL of 40% acetic acid	[44]
			8±2	40±5	indomethacin	oral	48 mg/kg	[12]
Cd44	Marker of proliferative activity	the mean area % of Cd44 immunopositive cells	1.2±1.09	2.4±1.14	Aspirin	oral	200 mg/kg once	[68]
HO-1	Marker of Intrinsic antioxidant defense	the mean area % of HO-1 immunopositive cells	3.5±1	6±1	indomethacin	intraperitoneal	25 mg/kg	[22]
			0.75±.05	1.25±0.1	absolute ethanol (95-99%)	Oral	1 mL/200 g once	[69]
		Authors depend on their subjective interpretation.	decreased	increased	absolute ethanol (95-99%)	Oral	1 mL/200 g once	[70]
Nrf-2	Marker of Intrinsic antioxidant defense	the mean area % of Nrf-2 immunopositive cells	4±1	9±2	indomethacin	intraperitoneal	25 mg/kg	[22]
			0.9±.02	1.3±0.1	absolute ethanol (95-99%)	Oral	1 mL/200 g once	[69]

## **Biomarkers used in the erosive gastritis**

### **Cyclooxygenase-2 (COX-2)**

COX is the rate-limiting enzyme that converts arachidonic acid to various molecules, including prostaglandins, prostacyclin, and thromboxanes. This enzyme has two distinct isoforms, COX-1 and COX-2. While they share structural and enzymatic similarities, their functions differ significantly. COX-1 is constitutively expressed in multiple human tissues, playing a role in vital physiological processes such as vascular homeostasis and gastroprotection. In contrast, COX-2 is an immediate early-response gene whose expression is induced by various factors, including endotoxins, growth factors, transcription factors such as NF- $\kappa$ B, cytokines such as TNF- $\alpha$ , and interleukins such as IL-1 $\beta$ . [71] In experimentally induced gastritis models, the mean area % of COX-II-immunopositive cells in the gastric mucosa increases significantly in the gastritis group may correlate with the ongoing inflammatory process. This percentage decreases in the treated groups, which the anti-inflammatory effect of the drug under study can explain. [15, 26, 72-75]

### **Heat shock protein 70 (HSP70)**

HSP70 is a highly conserved protein found in cells across various organisms, including humans. It belongs to the family of heat shock proteins, molecular chaperones involved in cellular stress response and protein homeostasis. Upon exposure to different irritants, gastric cells express heat shock proteins (HSPs) to enforce their resistance and promote survival. It acts mainly by refolding the essential functioning proteins that were partially damaged or enhancing the delivery of the necessary precursor proteins to mitochondria and endoplasmic reticulum to promote mucosal healing [76]. In rat models of experimentally induced gastritis, the mean area % of HSP70-immunopositive cells increases significantly in the diseased group, this may correlate with the stress applied upon the mucosal cells. This ratio decreases in the treated groups, which may be explained as the resolution of this stress and progression toward healing. [15, 77-79]

### **Interleukin-33 (IL-33)**

IL-33 is released by necrotic epithelial cells and acts as an alarmin, a danger signal released upon tissue damage initiating an immune response. It is predominantly found in the nucleus of cells, and it

diffuses into the extracellular space upon cell damage or necrosis. Once released, IL-33 binds to its receptor, ST2 (IL-1 receptor-like 1), expressed on various immune cells, including mast cells, T-helper cells, and regulatory T cells. The binding of IL-33 to its receptor triggers a cascade of signalling events that activate and recruit immune cells. IL-33 also promotes the production of other allergic and inflammatory cytokines. Simultaneously, IL-33 can directly or indirectly stimulate epithelial proliferation and repair by affecting epithelial stem cells and subepithelial myofibroblasts. [80] In the abovementioned study, Danışman et al. [14] reported that the mean area % of IL-33-immunopositive cells had increased significantly in the diseased group, this may correlate with the extent of the inflammatory process [80].

### **Proliferating cell nuclear antigen (PCNA)**

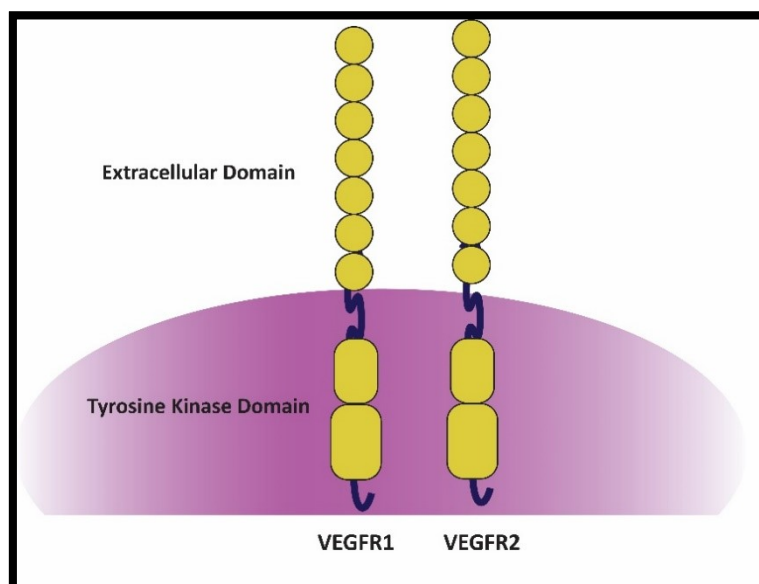
It is a protein that plays a crucial role in DNA replication processes. PCNA encircles DNA strands during DNA replication to stabilize the replication machinery. In addition to its role in DNA replication, PCNA is involved in DNA repair mechanisms. It acts as a scaffold to recruit repair enzymes to the site of DNA damage. PCNA is considered a marker of cellular proliferation and is widely used as an immunohistochemical marker in research and clinical settings. Its expression level is often used to assess proliferation rate and can indicate cellular processes such as tumor growth and response to therapy. [81] The diseased groups revealed increased reaction for PCNA in the cells lining the whole fundic glands. This increase indicates the presence of stem cells that proliferate and differentiate to allow for the regeneration of damaged cells, thus permitting the healing of the degenerated areas of the gastric mucosa. Another explanation for increased PCNA reaction in the cells is induced as a response to damaged DNA even after the cell is no longer active in the cell cycle. They also added that PCNA is involved in the excision and replacement of abnormal nucleotides and is thus also expressed in non-proliferating surviving cells undergoing DNA repair. [21, 49, 82-84]

### **Vascular endothelial growth factor (VEGF)**

VEGF or VEGF-A represents the prototype of a distinctive family consisting of at least six growth factors predominantly expressed in endothelial cells, possessing heparin-binding properties, and having angiogenic functions. This family includes VEGF-A, VEGF-B, VEGF-C, VEGF-D, VEGF-E, and the placental growth factor (PlGF). VEGF

plays a crucial role in two critical processes involved in vascular development. Vasculogenesis refers to forming new vascular tubes from precursor endothelial cells, and angiogenesis involves sprouting small vessels and capillaries from existing larger blood vessels. VEGF stimulates endothelial cells in both the vascular and lymphatic systems to degrade extracellular matrix, proliferate, migrate, and form tubes while also serving as a survival factor for endothelial cells. Additionally, VEGF significantly enhances vascular permeability by creating fenestrations in the endothelium of small venules and capillaries. This characteristic led to its previous designation as a vascular permeability factor (VPF). VEGF receptors

(VEGFRs) consist of three closely related peptides spanning the cell membrane and contain an extracellular immunoglobulin-like domain and two intracellular tyrosine kinases (Fig. 2). VEGF primarily interacts with two of these receptors: VEGFR-1 (also known as flt-1) and VEGFR-2 (also known as flk-1). The binding of VEGF to VEGFR-1 stimulates endothelial cell migration and may contribute to vascular organization. Activation of VEGFR-2 stimulates endothelial cell differentiation, proliferation, and migration and is involved in angioblast differentiation. VEGFR-3 (flt-4), predominantly expressed in lymphatic endothelium, binds VEGF-C and VEGF-D[85-93].



**Fig. 2 diagram showing the structure of the VEGFR, it is composed of extracellular, trans cellular and intra cellular domain. The latter has a tyrosine kinase intrinsic activity.**

Immunohistochemical staining for the angiogenic marker VEGF assesses the extent of gastric mucosal healing. The mean area % of VEGF immunopositive cells reflects the angiogenesis status within the tissue. Notably, mucosae exposed to the inflammatory process displayed a visible decrease in the immunopositive cells compared to the control group, indicating reduced VEGF expression. Contrarily, treated groups exhibited a significant increase in brown stains, like the control group, indicating improved VEGF expression. As a growth factor, VEGF plays a crucial role in protecting the mucosa by restoring restored microvasculature, thus maintaining endothelial cell viability, and enhancing vascular permeability. Levels of VEGF expression increased during the

healing of gastric mucosa, indicating its significance in mucosal repair.[26, 67]

### **Tumor Necrosis Factor-alpha (TNF- $\alpha$ )**

TNF- $\alpha$  is a cytokine that plays a crucial role in the immune system and inflammatory responses. Activated macrophages primarily produce TNF- $\alpha$ , but other cell types, including lymphocytes, natural killer cells, and endothelial cells, can also secrete it. TNF- $\alpha$  is involved in various physiological and pathological processes. It regulates immune responses, inflammation, and cell survival. In the immune system, TNF- $\alpha$  acts as a potent mediator, promoting the activation and recruitment of immune cells to sites of infection or injury. It enhances the expression of adhesion molecules on

endothelial cells, facilitating the migration of immune cells into tissues. In addition to its role in immune responses, TNF- $\alpha$  has been implicated in the pathogenesis of various inflammatory and autoimmune diseases, including rheumatoid arthritis, inflammatory bowel disease, psoriasis, and systemic lupus erythematosus. It contributes to tissue damage and chronic inflammation by promoting the recruitment of inflammatory cells and producing pro-inflammatory mediators. Its dysregulation has been linked to various inflammatory and autoimmune diseases, and targeted therapies that block TNF- $\alpha$  have shown efficacy in treating these conditions. TNF- $\alpha$  plays a central role in the development of gastric ulcers by initiating the acute inflammatory response, accompanied by neutrophil infiltration into the injury site. It activates caspase-3 and thus stimulates apoptosis. In addition, it delays healing by suppressing blood flow and cell growth.[67, 94-96]

### **Cysteine-aspartic acid protease-3 (Caspase-3)**

Caspases represent the main constituent of the apoptotic cascade. One of the principal members of the caspase family is Caspase 3, which is activated through a cascade of signalling events as a result of tissue apoptosis with endonuclease activation and sequelae of DNA fragmentation. Once activated, caspase-3 cleaves and activates downstream substrates, leading to the characteristic morphological and biochemical changes associated with apoptosis. Caspase-3 activation is tightly regulated in normal physiological processes to ensure proper cell death and tissue homeostasis. Dysregulation of caspase-3 activity can contribute to various diseases, including cancer, neurodegenerative disorders, and autoimmune diseases. Its activation leads to the characteristic changes observed during apoptosis, and its dysregulation is associated with various conditions. Caspase-3 is a vital apoptosis marker widely studied in basic research and clinical applications. Studies have shown that caspase-3 activation is increased in gastric ulcer tissues. Elevated caspase-3 activity indicates enhanced apoptosis in the gastric mucosa. Various factors, including oxidative stress, inflammation, and damage to the gastric mucosa, trigger the activation of caspase-3. Increased caspase-3 activity in gastric ulcers may contribute to the breakdown of the gastric mucosal barrier and impair the normal healing process. Caspase-3-mediated apoptosis of epithelial cells in

the gastric mucosa can lead to tissue damage and delayed ulcer healing. However, it is essential to note that the role of caspase-3 in gastritis is complex, and further research is needed to understand its precise mechanisms and potential therapeutic implications.[7, 50]

### **Inducible Nitric Oxide Synthase (iNOS)**

It is an enzyme that catalyzes the production of nitric oxide (NO) from the amino acid L-arginine. Unlike constitutive forms of nitric oxide synthase (NOS), which are involved in normal physiological processes, iNOS is not expressed under normal conditions but can be induced in response to various stimuli, such as inflammation, infection, and immune activation. iNOS is primarily expressed in immune cells, including macrophages, neutrophils, and certain types of lymphocytes. These cells can upregulate iNOS expression and generate high nitric oxide levels upon activation. The production of NO by iNOS serves multiple functions in the immune system. It is a signalling molecule regulating immune responses, vasodilation, and neurotransmission. In the context of immune defense, NO produced by iNOS has antimicrobial effects by inhibiting the growth and activity of some pathogens. High NO levels can damage tissues and contribute to the pathogenesis of various inflammatory diseases, including erosive gastritis. While NO can have beneficial effects as a signalling molecule and a host defense mechanism, excessive production of NO by iNOS in the context of gastric ulcer can have detrimental effects on the gastric mucosa. Excessive NO production can cause oxidative stress, disrupt the balance of antioxidants, and damage the stomach lining tissue. NO can also interact with other molecules and inflammatory mediators, forming reactive nitrogen species (RNS) that can further contribute to tissue injury and inflammation. Furthermore, NO derived from iNOS can affect blood flow regulation in the gastric mucosa. Excessive NO production can induce vasodilation and increase blood flow, which may exacerbate the damage caused by gastric ulcers. While increased blood flow is generally beneficial for tissue repair and healing, it can have negative consequences in the context of gastric ulcers. The increased blood flow can bring more inflammatory cells and substances to the ulcer site, which may exacerbate tissue damage and prolong the healing process. However, the use of iNOS inhibitors in erosive gastritis is still under investigation, and further research is needed to fully understand the



precise role and therapeutic potential of iNOS in this condition.[52, 97-99]

#### **Ki67**

The name Ki67 is taken from the city of Kiel (Ki) where the antibody was produced in the university department of pathology and refers to the number of the original clone 67.[100] It is a nuclear protein commonly used to assess cellular proliferation or the growth rate of a dividing cell but not in quiescent ones, which is considered an important predictive and prognostic marker in several cancers. Ki67 is present during various cell cycle phases but is absent in resting cells (G0 phase). The expression of Ki67 is associated with cell proliferation, making it a valuable tool for determining the proliferative activity of cells in various tissues and during different biological processes. The percentage of positively stained cells can be assessed and used to indicate cellular proliferation. Simultaneously, low Ki67 expression may indicate a less proliferative or more quiescent state[52, 101].

#### **Chromogranin A (CgA):**

CgA is an acidic glycoprotein that is widely distributed throughout neuroendocrine cells throughout the body. It is produced and stored in their secretory granules, where it functions as a precursor molecule for multiple biologically active peptides and hormones. CgA is processed and cleaved into smaller peptides, including chromostatin, vasostatin, pancreastatin, and others, which can have regulatory effects on various organ systems. CgA is a clinical practice and research biomarker, particularly in neuroendocrine tumors and certain endocrine disorders. CgA has been studied in the context of gastritis, although its exact role and significance in this condition are still being explored. Studies have reported alterations in CgA levels in cases with gastric ulcers, and the findings can be conflicting or inconclusive. While some studies have reported increased levels of CgA in subjects with gastric ulcers, other studies have not consistently observed this association. The changes in CgA levels may depend on various factors, including the severity of the ulcer, the presence of associated conditions, and individual variations.[53, 102-105]

#### **Nuclear factor kappa B (NF-κB)**

NF-κB represents a family of inducible transcription factors that regulate various cellular processes, including immune responses, inflammation, cell survival, and proliferation. It is involved in the control of numerous genes that are

responsible for mediating immune responses. NF-κB typically composed of dimers of different subunits. In an inactive state, NF-κB is retained in the cytoplasm by interacting with inhibitory proteins called IκBs (Inhibitor of κB). These IκB proteins prevent NF-κB from entering the nucleus and activating target genes. Various signals, including pro-inflammatory cytokines, microbial products, oxidative stress, and other cellular stressors, can trigger the activation of NF-κB. Upon activation, the inhibitory proteins IκBs are phosphorylated and targeted for degradation, allowing NF-κB to translocate to the nucleus. In the nucleus, NF-κB binds to specific DNA sequences promotes the transcription of target genes involved in inflammatory response. NF-κB also regulates cell survival by promoting the expression of anti-apoptotic proteins. Dysregulation of NF-κB signalling has been implicated in various diseases, including chronic inflammation, autoimmune disorders, cancer, and neurodegenerative diseases. Therapeutically, targeting NF-κB signalling has been explored as a potential approach for treating inflammatory and autoimmune diseases. Inhibitors of NF-κB activation or downstream signalling pathways are being investigated for their potential to modulate immune and inflammatory responses. In gastric ulcers, NF-κB activation has been observed in the gastric mucosa. Upon activation, NF-κB induces the expression of pro-inflammatory cytokines, chemokines, adhesion molecules, and enzymes that mediate inflammation. These factors can further recruit immune cells, stimulate iNOS which enhance oxidative damage, and initiate tissue injury. The specific effects of NF-κB activation or inhibition may vary depending on the stage, severity, and underlying causes of erosive gastritis.[12, 44, 106-110]

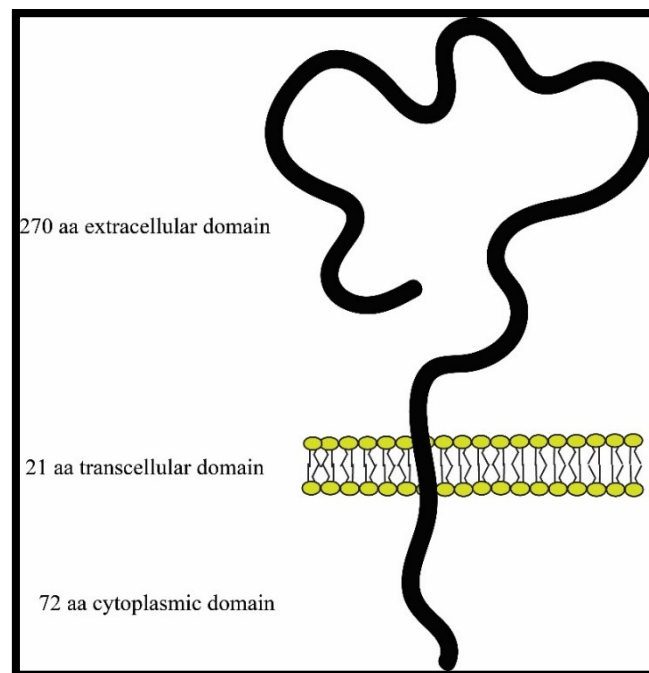
#### **Cluster differentiation 44 (CD44):**

CD44 is a cell surface glycoprotein involved in various cellular processes, including cell adhesion, migration, tissue development, inflammation, wound healing, and cancer progression and signaling. CD44 consists of three regions: a 270 aa N-terminal extracellular domain, a 21 aa transmembrane domain, and 72 aa C-terminal cytoplasmic domain (Fig. 3). It is expressed in different cell types, including immune, epithelial, and mesenchymal cells. CD44 is known for its role in cell-cell and cell-matrix interactions, mainly through its ability to bind to hyaluronic acid, an extracellular matrix component. Through this interaction, CD44 facilitates the binding and



retention of inflammatory cells at the site of injury or inflammation in the gastric mucosa. The accumulation of these cells can contribute to the

development of gastric ulcers by promoting tissue damage and prolonging the inflammatory response[111-116].



**Fig. 3 the structure of the CD44, it is composed of a 270 aa N-terminal extracellular domain, a 21 aa transmembrane domain, and 72 aa C-terminal cytoplasmic domain.**

### Heme Oxygenase-1 (HO-1)

HO-1, also known as HSP32 (Heat Shock Protein 32), is an enzyme that plays a crucial role in heme catabolism and cellular defense against oxidative stress. The HMOX1 gene encodes it and is inducible in response to various stimuli, including oxidative stress, inflammation, and cellular injury. HO-1 is responsible for the breakdown of heme into carbon monoxide (CO), biliverdin, and iron. HO-1 is widely expressed in different tissues, including the gastric mucosa. HO-1 has been investigated as a potential tissue protection and healing mediator in gastric ulcers. Studies have shown that HO-1 expression is upregulated in gastric ulcer tissues. This upregulation is believed to be a cellular response to oxidative stress and inflammation associated with the ulcerative process. HO-1 induction in gastritis is considered a protective mechanism that helps to mitigate tissue damage and promote tissue repair. The byproducts generated by HO-1 activity, such as CO and biliverdin, have antioxidant and anti-inflammatory properties, contributing to tissue protection and reducing inflammatory responses. Examining HO-1 expression levels in ulcer tissues can help assess its potential as a diagnostic or

prognostic marker for gastritis severity or healing capacity[22, 69, 117-120].

### Nuclear Factor-Erythroid 2 Related Factor 2 (Nrf-2)

Nrf2 is a well-known target that regulates redox balance by promoting the production of antioxidant enzymes. When cells are exposed to various stressors, Nrf2 translocates from the cytoplasm to the nucleus, activating the transcription of many antioxidants and cytoprotective genes such as HO-1, catalase, and glutathione. In addition, Nrf2 has an anti-inflammatory role by inhibiting pro-inflammatory signaling by reducing NF- $\kappa$ B, IL-1 $\beta$ , IL-6, and TNF- $\alpha$ . Moreover, Nrf2 has an antiapoptotic effect by modulating Bax, Bcl-2, and caspase 3 and 9. In addition to its antioxidant and anti-inflammatory properties, Nrf2 also plays a role in tissue repair and regeneration. It promotes gene expression in cell proliferation, angiogenesis, extracellular matrix synthesis, and essential tissue healing processes. Activation of Nrf2 in gastric ulcer models has been shown to enhance gastric mucosal repair, stimulate the regeneration of damaged tissues, and accelerate ulcer healing[69, 121-123].

## Conclusions

IHC has emerged as a valuable tool in erosive gastritis research, providing insights into the molecular mechanisms involved in ulcer formation and progression. It enabled many researchers to visualize and analyze specific proteins within tissue sections, identifying novel biomarkers with clinical relevance. These findings could aid in developing targeted therapies and improve patient outcomes in managing erosive gastritis. Furthermore, diagrammatic illustrations in this review have enhanced the clarity and understanding of the reviewed concepts, making them accessible to a broad readership. Diagrammatic drawings are essential for improving the clarity of examined concepts, particularly in explaining the molecular connections that contribute to disease. These visual aids facilitate the comprehension of sophisticated concepts by providing a systematic analysis of complex procedures. Illustrations enhance comprehension by emphasising crucial components and connections, enabling readers to more effectively link theoretical information with real-world implementations. Furthermore, the use of visual format serves to mitigate the risk of overwhelming individuals with excessive information and improves the ability to remember, so providing advantages to a wide range of individuals, such as students, researchers, and professionals. Essentially, these pictures function as potent instruments to communicate intricate scientific information in a more comprehensible and influential way. Continuing research and advancements in IHC techniques are promising to elucidate the molecular basis of gastritis and facilitate effective treatment development.

## List of Abbreviations

Caspase-3: Cysteine-aspartic acid protease-3  
 CD44: Cluster differentiation 44  
 CgA chromogranin A  
 CO: carbon monoxide  
 COX-2: Cyclooxygenase-2  
 GIT: gastrointestinal  
 HSP70: Heat shock protein 70  
 IHC: Immunohistochemistry  
 IL-33: Interleukin-33  
 iNOS: Inducible Nitric Oxide Synthase  
 NF- $\kappa$ B Nuclear factor kappa B  
 NO: nitric oxide  
 Nrf-2: Nuclear Factor-Erythroid 2 Related Factor 2  
 NSAIDs: non-steroidal anti-inflammatory drugs  
 PCNA: Proliferating cell nuclear antigen

PIGF: placental growth factor

TCDD: tetrachlorodibenzo-p-dioxin

TNF- $\alpha$ : Tumor Necrosis Factor-alpha

VEGF: Vascular endothelial growth factor

VPF: vascular permeability factor

VEGFRs: VEGF receptors

## Declarations

### Compliance with Ethical Standards

The present article is a review and does not involve any direct interaction with human or animal subjects. Therefore, informed consent and ethical approval did not apply to this study. The author declares no conflicts of interest or financial disclosures that could have influenced the interpretation or reporting of the review. However, it is important to note that I strictly adhere to the ethical guidelines established by the Faculty of Medicine, University of Alexandria, in all of my work.

### Informed consent

In this case, informed consent is not applicable since this is a review article that did not involve the use of any animal or human subjects. The article is based solely on the review and collection of data from already published articles. As a result, no individuals or animals were directly involved or affected by the research process, eliminating the need for informed consent.

### Availability of data and materials

The sources for the information discussed in this review can be obtained from the papers cited in the references.

### Competing interests

Competing interests are not applicable since the author is the sole author of the article.

### Funding

This research received no grant from any funding agency in the public, commercial, or not-for-profit sectors during the preparation of this manuscript.

### Author contributions

MH conceived the review structure, wrote the manuscript, drew all the scientific illustration (fig 1-3) via adobe illustrator program, and revised the manuscript.

### Acknowledgments

I express sincere gratitude to the Egyptian Knowledge Bank (EKB) providing unlimited access to the articles and books that have been read in this work.

## References

1. Antonisamy, P., Dhanasekaran, M., Ignacimuthu, S., Duraipandiyar, V., Balthazar, J. D., Agastian, P. and Kim, J.-H. Gastroprotective effect of epoxy clerodane diterpene isolated from *tinospora cordifolia* miers (guduchi) on indomethacin-induced gastric ulcer in rats. *Phytomedicine*, **21** (7), 966-969 (2014).
2. Song, H., Hou, X., Zeng, M., Chen, X., Chen, X., Yang, T., Xu, F., Peng, J., Peng, Q., Cai, X. and Yu, R. Traditional chinese medicine li-zhong-tang accelerates the healing of indomethacin-induced gastric ulcers in rats by affecting tlr-2/myd88 signaling pathway. *J. Ethnopharmacol.*, **259**, 112979 (2020).
3. Herrington, C. S. *Muir's textbook of pathology*. 15th ed., CRC Press: Florida, (2020).
4. Salari, N., Darvishi, N., Shohaimi, S., Bartina, Y., Ahmadipana, M., Salari, H. R. and Mohammadi, M. The global prevalence of peptic ulcer in the world: A systematic review and meta-analysis. *Indian J. Surg.*, **84** (5), 913-921. (2022).
5. Kuna, L., Jakab, J., Smolic, R., Raguz-Lucic, N., Vcev, A. and Smolic, M. Peptic ulcer disease: A brief review of conventional therapy and herbal treatment options. *Journal of Clinical Medicine*, **8** (2), 179(2019).
6. McPhee, S. J., Papadakis, M. A. and Rabow, M. W. *Current medical diagnosis & treatment*. 62nd ed., McGraw-Hill Medical: New York, (2023).
7. Kumar, V. A., A and Aster, J. *Robbins basic pathology*. 10th ed., elsevier: Philadelphia,, (2018).
8. Ai, Q., Chen, W., Li, Y. and Li, G. Upper gastrointestinal tract iras: A case report about sintilimab-induced acute erosive hemorrhagic gastritis. *Front. Immunol.*, **13**, 840916(2022).
9. Villar-Martínez, M. D., Moreno-Ajona, D., Chan, C. and Goadsby, P. J. Indomethacin-responsive headaches—a narrative review. *Headache: The Journal of Head and Face Pain*, **61** (5), 700-714(2021).
10. Slomiany, B. L. and Slomiany, A. Endothelin-1-dependent up-regulation of leptin production in gastric mucosal injury by indomethacin. *InflammoPharmacology*, **13** (5), 455-466. (2005).
11. Rofaeil, R. R. and Mohamed, A. S. Gastroprotective effect of sitagliptin in experimentally-induced peptic ulcer in rats. *Minia Journal of Medical Research*, **31** (2), 253-256 (2020).
12. AbdelAziz, E. Y., Tadros, M. G. and Menze, E. T. The effect of metformin on indomethacin-induced gastric ulcer: Involvement of nitric oxide/rho kinase pathway. *Eur. J. Pharmacol.*, **892**, 173812. (2021).
13. Elsisy, A. E., Mekky, E. F. and Abu-Risha, S. E. Potential effects of carbon monoxide donor and its nanoparticles on experimentally induced gastric ulcer in rats. *Inflammopharmacology*, **31** (3), 1495-1510 (2023).
14. Danışman, B., Çiçek, B., Yıldırım, S., Yüce, N. and Bolat, I. Gastroprotective effects of bromelain on indomethacin-induced gastric ulcer in rats. *GSC Biological and Pharmaceutical Sciences*, **23** (1), 277-286 (2023).
15. Mahmoud, M. F., Abdo, W., Nabil, M., Drissi, B., El-Shazly, A. M., Abdelfattah, M. A. O. and Sobeh, M. Apple (*malus domestica* borkh) leaves attenuate indomethacin-induced gastric ulcer in rats. *Biomed. Pharmacother.*, **160**, 114331 (2023).
16. Zheng, S. L. and Roddick, A. J. Association of aspirin use for primary prevention with cardiovascular events and bleeding events: A systematic review and meta-analysis. *JAMA*, **321** (3), 277-287 (2019).
17. Bergh, M. S. and Budsberg, S. C. The coxib nsoids: Potential clinical and pharmacologic importance in veterinary medicine. *J. Vet. Intern. Med.*, **19** (5), 633-643(2005).
18. Saranya, P., Geetha, A. and Selvamathy, S. N. A biochemical study on the gastroprotective effect of andrographolide in rats induced with gastric ulcer. *Indian J. Pharm. Sci.*, **73** (5), 550. (2011).
19. Mohammed Ali, A. M., Abd-Elgwad, S. K., Hasan, R. A. A. and Abd-Elgalil, M. M. Trio-clar versus portulaca oleracea and/or foeniculum vulgare extracts on induced gastric ulcer in adult female albino rats. A histological study. *Egyptian Journal of Histology*, **43** (4), 1008-1033 (2020).
20. Abd\_Elhamid, A., Salem, M. A.-E., Mahmoud, S. M. and Abd Elgalil, M. M. Histological study of the caffeine effect on intact gastric mucosa and induced gastric ulcer in adult male albino rats. *Egyptian Journal of Histology*, **44** (1), 163-187 (2021).
21. Elkerdasy, H. I. and Mousa, H. R. A comparative study between the therapeutic role of adipose derived mesenchymal stem cells and omeprazole in regeneration of gastric ulcer induced by aspirin in albino rats : Histological and immunohistochemical study. *Egyptian Journal of Histology*, **44** (4), 993-1006 (2021).
22. Sallam, A.-A. M., Darwish, S. F., El-Dakroury, W. A. and Radwan, E. Olmesartan niosomes ameliorates the indomethacin-induced gastric ulcer in rats: Insights on mapk and nrf2/ho-1 signaling pathway. *Pharm. Res.*, **38** (11), 1821-1838 (2021).
23. Mousa, A. M., El-Sammad, N. M., Hassan, S. K., Madboli, A. E. N. A., Hashim, A. N., Moustafa, E. S., Bakry, S. M. and Elsayed, E. A. Antiulcerogenic effect of cuphea ignea extract against ethanol-induced gastric ulcer in rats. *BMC Complement. Altern. Med.*, **19** (1), 345 (2019).
24. Simões, S., Lopes, R., Campos, M. C. D., Marruz, M. J., da Cruz, M. E. M. and Corvo, L. Animal models of acute gastric mucosal injury: Macroscopic and microscopic evaluation. *Animal Models and Experimental Medicine*, **2** (2), 121-126 (2019).
25. Izhar, H., Shabbir, A., Shahzad, M., Mobashar, A. and Ahmed, S. S. Phyllanthus reticulatus prevents ethanol-induced gastric ulcer via downregulation of il-8 and tnfr-α levels. *Evid. Based Complement. Alternat. Med.*, **2021**, 1734752 (2021).

26. Abdel-Kawi, S. H., Hashem, K. S., Saad, M. K., Fekry, G. and Abdel-Hameed, E. M. M. The ameliorative effects of cinnamon oil against ethanol-induced gastric ulcer in rats by regulating oxidative stress and promoting angiogenesis. *J. Mol. Histol.*, **53** (3), 573-587 (2022).
27. Murakami, M., Lam, S. K., Inada, M. and Miyake, T. Pathophysiology and pathogenesis of acute gastric mucosal lesions after hypothermic restraint stress in rats. *Gastroenterology*, **88** (3), 660-665 (1985).
28. Al-Moutairy, A. R. and Tariq, M. Effect of vitamin e and selenium on hypothermic restraint stress and chemically-induced ulcers. *Dig. Dis. Sci.*, **41** (6), 1165-1171 (1996).
29. Landeira-Fernandez, J. Analysis of the cold-water restraint procedure in gastric ulceration and body temperature. *Physiol. Behav.*, **82** (5), 827-833 (2004).
30. Omayone, T. P., Salami, A. T., Olopade, J. O. and Olaleye, S. B. Attenuation of ischemia-reperfusion-induced gastric ulcer by low-dose vanadium in male wistar rats. *Life Sci.*, **259**, 118272 (2020).
31. Gemici, B., Birsen, İ. and İzgüt-Uysal, V. N. The apelin-apela receptor apj is necessary for formation and healing of ischemia reperfusion-induced gastric ulcer in rats. *Peptides*, **166**, 171027 (2023).
32. Girard, P., Coppé, M. C., Pansart, Y. and Gillardin, J. M., Gastroprotective effect of saccharomyces boulardii in a rat model of ibuprofen-induced gastric ulcer. *Pharmacology*, **85** (3), 188-193 (2010).
33. Liu, J., Sun, D., He, J., Yang, C., Hu, T., Zhang, L., Cao, H., Tong, A.-p., Song, X., Xie, Y., He, G., Guo, G., Luo, Y., Cheng, P. and Zheng, Y., Gastroprotective effects of several h2ras on ibuprofen-induced gastric ulcer in rats. *Life Sci.*, **149**, 65-71 (2016).
34. Hay, L., Varco, R., Code, C. F. and Wangenstein, O. The experimental production of gastric and duodenal ulcers in laboratory animals by the intramuscular injection of histamine in beeswax. *Surg. Gynecol. Obstet.*, **75**, 170-182 (1942).
35. Sirmagul, B., Kilic, F. S., Batu, O. and Erol, K. The effects of verapamil on stress- and histamine-induced gastric lesions in rats. *Methods Find. Exp. Clin. Pharmacol.*, **26** (10), 763-767 (2004).
36. Pfeiffer, C. J., Cho, C. H., Cheema, A. and Saltman, D. Reserpine-induced gastric ulcers: Protection by lysosomal stabilization due to zinc. *Eur. J. Pharmacol.*, **61** (4), 347-353 (1980).
37. Yi, R., Wang, R., Sun, P. and Zhao, X. Antioxidant-mediated preventative effect of dragon-pearl tea crude polyphenol extract on reserpine-induced gastric ulcers. *Exp. Ther. Med.*, **10** (1), 338-344 (2015).
38. Ogino, K., Hobara, T., Ishiyama, H., Yamasaki, K., Kobayashi, H., Izumi, Y. and Oka, S. Antiulcer mechanism of action of rebamipide, a novel antiulcer compound, on diethyldithiocarbamate-induced antral gastric ulcers in rats. *Eur. J. Pharmacol.*, **212** (1), 9-13 (1992).
39. Yıldırım, E., Sağiroğlu, O., Kılıç, F. S. and Erol, K. Effects of nabumetone and dipyron on experimentally induced gastric ulcers in rats. *Inflammation*, **36** (2), 476-481 (2013).
40. Amagase, K. and Okabe, S. Acetic acid ulcers: A new method for producing solitary chronic ulcers in rat stomachs by intraluminal application of acetic acid solution. *Inflammo. Pharmacology*, **10** (4), 385-389(2002).
41. Karakoyun, B., Yüksel, M., Ercan, F., Erzik, C. and Yeğen, B. Ç. Alpha-lipoic acid improves acetic acid-induced gastric ulcer healing in rats. *Inflammation*, **32** (1), 37-46 (2009).
42. Tanigawa, T., Watanabe, T., Otani, K., Nadatani, Y., Machida, H., Okazaki, H., Yamagami, H., Watanabe, K., Tominaga, K., Fujiwara, Y., Oshitani, N., Higuchi, K. and Arakawa, T. Leptin promotes gastric ulcer healing via upregulation of vascular endothelial growth factor. *Digestion*, **81** (2), 86-95 (2010).
43. Garabadu, D., Singh, S. and Gautam, T. Manilkara hexandra (roxb.) dubard ameliorates acetic acid-induced rat gastric ulcer. *J. Diet. Suppl.*, **18** (3), 278-292 (2021).
44. Foadoddini, M., Javdani, H., Farahi, A. and Hosseini, M. Therapeutic potential of ferula foetida(bunge) regel on gastric ulcer model in rats. *Environmental Science and Pollution Research*, **29** (8), 12147-12156 (2022).
45. Nikodijevic, B. and Vanov, S. The influence of thenalidine on reserpine- and serotonin-induced gastric ulcers in rats. *Experientia*, **16**, 464-466 (1960).
46. Gidener, S., Koyuncuoglu, M., Gelal, A., Gümüstekin, M., Guven, H., Bökesoy, A. and Güre, A. Circadian rhythmicity in serotonin-induced acute gastric mucosal injury in rats. *Int. J. Exp. Pathol.*, **79** (2), 105-108 (1998).
47. Khushtar, M., Kumar, V., Javed, K. and Bhandari, U. Protective effect of ginger oil on aspirin and pylorus ligation-induced gastric ulcer model in rats. *Indian J. Pharm. Sci.*, **71** (5), 554-558 (2009).
48. Wang, X.-Y., Yin, J.-Y., Zhao, M.-M., Liu, S.-Y., Nie, S.-P. and Xie, M.-Y. Gastroprotective activity of polysaccharide from hericium erinaceus against ethanol-induced gastric mucosal lesion and pylorus ligation-induced gastric ulcer, and its antioxidant activities. *Carbohydrate Polymers*, **186**, 100-109 (2018).
49. Elghazouly, D. E. and Yassien, R. I. Effect of sofosbuvir (sovaldi) on the fundic mucosa of adult male albino rats and the possible protective role of fucoidan: Histological, histochemical, and immunohistochemical study. *Egyptian Journal of Histology*, **45** (1), 17-35 (2022).
50. Bashandy, M. A. and Noya, D. A. E. Light and electron microscopic studies on the possible protective effect of ginger on the gastric fundic mucosa of adult male albino rats treated with 5-fluorouracil. *Egyptian Journal of Histology*, **43** (1), 36-50 (2020).

51. Abd El-Naeem, A. F. Effect of nicotine on the structure of gastric mucosa of adult male albino rats and the possible protective effect of royal jelly (light and scanning electron microscopic study). *Egyptian Journal of Histology*, **45** (2), 404-415 (2022).
52. Elwan, W. M. and Ibrahim, M. A. Effect of tartrazine on gastric mucosa and the possible role of recovery with or without riboflavin in adult male albino rat. *Egyptian Journal of Histology*, **42** (2), 297-311 (2019).
53. Mahmoud, M. S. Gastroprotective activity of olive leaves extract on 2,3,7,8 tetrachlorodibenzo-p-dioxin induced gastric fundic mucosal injury in adult male albino rats (light and electron microscopic study). *Egyptian Journal of Histology*, **43** (4), 1188-1204 (2020).
54. Raafat, M. and Hamam, G. G. The possible role of bee venom on gastric fundic mucosa in streptozotocin induced diabetes mellitus in rats. A histological study. *Egyptian Journal of Histology*, **42** (4), 1029-1043 (2019).
55. Adinortey, M. B., Ansah, C., Galyuon, I. and Nyarko, A. In vivo models used for evaluation of potential antigastroduodenal ulcer agents. *Ulcers*, **2013**(4), ID: 73332209 (2013).
56. Liu, Y., Yamada, H. and Ochi, J. Immunocytochemical studies on endothelin in mast cells and macrophages in the rat gastrointestinal tract. *Histochem. Cell Biol.*, **109** (4), 301-307(1998).
57. Kouznetsova, I., Peitz, U., Vieth, M., Meyer, F., Vestergaard, E. M., Malfertheiner, P., Roessner, A., Lippert, H. and Hoffmann, W. A gradient of tff3 (trefoil factor family 3) peptide synthesis within the normal human gastric mucosa. *Cell Tissue Res.*, **316** (2), 155-165 (2004).
58. Fink, C., Hembes, T., Brehm, R., Weigel, R., Heeb, C., Pfarrer, C., Bergmann, M. and Kressin, M. Specific localisation of gap junction protein connexin 32 in the gastric mucosa of horses. *Histochem. Cell Biol.*, **125** (3), 307-313 (2006).
59. Ogawa, K., Takemoto, N., Ishii, M., Pasquale, E. B. and Nakajima, T. Complementary expression and repulsive signaling suggest that ephb receptors and ephrin-b ligands control cell positioning in the gastric epithelium. *Histochem. Cell Biol.*, **136** (6), 617-636 (2011).
60. Duraiyan, J., Govindarajan, R., Kaliyappan, K. and Palanisamy, M. Applications of immunohistochemistry. *J. Pharm. Bioallied Sci.*, **4** (Suppl 2), S307-9 (2012).
61. Lastraioli, E., Romoli, M. R. and Arcangeli, A. Immunohistochemical biomarkers in gastric cancer research and management. *Int. J. Surg. Oncol.*, **2012**, 868645 (2012).
62. Zalecki, M. Gastric ulcer induced changes in substance p and nk1, nk2, nk3 receptors expression in different stomach localizations with regard to intrinsic neuronal system. *Histochem. Cell Biol.*, **151** (1), 29-42 (2019).
63. Furness, J. B., Di Natale, M., Hunne, B., Oparija-Rogenmozere, L., Ward, S. M., Sasse, K. C., Powley, T. L., Stebbing, M. J., Jaffey, D. and Fothergill, L. J. The identification of neuronal control pathways supplying effector tissues in the stomach. *Cell Tissue Res.*, **382** (3), 433-445 (2020).
64. Cui, G., Yuan, Y., Wang, Y. and Li, Z. The expression of ripk3 is associated with cell turnover of gastric mucosa in the mouse and human stomach. *J. Mol. Histol.*, **52** (4), 849-857 (2021).
65. Di Natale, M. R., Hunne, B., Liew, J. J. M., Fothergill, L. J., Stebbing, M. J. and Furness, J. B. Morphologies, dimensions and targets of gastric nitric oxide synthase neurons. *Cell Tissue Res.*, **388** (1), 19-32 (2022).
66. Crowe, A. R. and Yue, W. Semi-quantitative determination of protein expression using immunohistochemistry staining and analysis: An integrated protocol. *Bio-Protoc.*, **9** (24), e4610 (2019).
67. El-azab, N. E.-E., Mansy, A. E., El-Mahalaway, A. M. and Sabry, D. Comparative study of the therapeutic effect of pomegranate alone or in combination with bone marrow mesenchymal stem cells on experimentally induced gastric ulcer in adult male rats: A histological and immunohistochemical study. *Egyptian Journal of Histology*, **41** (2), 150-166 (2018).
68. El Kasaby, A., Ghaly, M., Abo Zeid, A. and Fayed, I. Therapeutic potential of adipose derived mesenchymal stem cells in regeneration of gastric ulcer in rats. *Journal of Medical Histology*, **1** (2), 190-201 (2017).
69. Alomair, M. K., Alabduladheem, L. S., Almajed, M. A., Alobaid, A. A., Alkhalifah, E. A. R., Younis, N. S. and Mohamed, M. E. Achillea millefolium essential oil mitigates peptic ulcer in rats through nrf2/ho-1 pathway. *Molecules*, **27** (22), 7908 (2022).
70. Zhang, Y., Jia, J., Ding, Y., Ma, Y., Shang, P., Liu, T., Hui, G., Wang, L., Wang, M., Zhu, Z., Li, Y. and Wen, A. Alpha-boswellic acid protects against ethanol-induced gastric injury in rats: Involvement of nuclear factor erythroid-2-related factor 2/heme oxygenase-1 pathway. *J. Pharm. Pharmacol.*, **68** (4), 514-522 (2016).
71. Fang, L., Chatterjee, S., Dong, Y. L., Gangula, P. R. R. and Yallampalli, C. Immunohistochemical localization of constitutive and inducible cyclooxygenases in rat uterus during the oestrous cycle and pregnancy. *The Histochemical Journal*, **30** (6), 383-391 (1998).
72. Possekel, S., Lombes, A., de Baulny, H. O., Cheval, M.-A., Fardeau, M., Kadenbach, B. and Romero, N. B., Immunohistochemical analysis of muscle cytochrome oxidase deficiency in children. *Histochem. Cell Biol.*, **103** (1), 59-68 (1995).

73. Paiotti, A. P. R., Miszputen, S. J., Oshima, C. T. F., de Oliveira Costa, H., Ribeiro, D. A. and Franco, M. Effect of cox-2 inhibitor after tnbs-induced colitis in wistar rats. *J. Mol. Histol.*, **40** (4), 317-324 (2009).
74. Paiotti, A. P. R., Ribeiro, D. A., Silva, R. M., Marchi, P., Oshima, C. T. F., Neto, R. A., Miszputen, S. J. and Franco, M. Effect of cox-2 inhibitor lumiracoxib and the tn $\alpha$  antagonist etanercept on tnbs-induced colitis in wistar rats. *J. Mol. Histol.*, **43** (3), 307-317 (2012).
75. Wójcik, M., Ramadori, P., Blaschke, M., Sultan, S., Khan, S., Malik, I. A., Naz, N., Martius, G., Ramadori, G. and Schultze, F. C. Immunodetection of cyclooxygenase-2 (cox-2) is restricted to tissue macrophages in normal rat liver and to recruited mononuclear phagocytes in liver injury and cholangiocarcinoma. *Histochem. Cell Biol.*, **137** (2), 217-233 (2012).
76. Beasley, T. C., Tytell, M. and Sweatt, A. J. Heat shock protein 70 in the retina of xenopus laevis, in vivo and in vitro: Effect of metabolic stress. *Cell Tissue Res.*, **290** (3), 525-538 (1997).
77. Figueiredo, D., Gertler, A., Cabello, G., Decuypere, E., Buyse, J. and Dridi, S. Leptin downregulates heat shock protein-70 (hsp-70) gene expression in chicken liver and hypothalamus. *Cell Tissue Res.*, **329** (1), 91-101 (2007).
78. Vydra, N., Winiarski, B., Rak-Raszewska, A., Piglowski, W., Mazurek, A., Scieglinska, D. and Widlak, W. The expression pattern of the 70-kda heat shock protein hspa2 in mouse tissues. *Histochem. Cell Biol.*, **132** (3), 319-330 (2009).
79. Mandour, D. A., Morsy, M. M., Fawzy, A., Mohamed, N. M. and Ahmad, M. M. Structural and molecular changes in the rat myocardium following perfluorooctane sulfonate (pfos) exposure are mitigated by quercetin via modulating hsp 70 and serca 2. *J. Mol. Histol.*, 283-296(2023).
80. Lopetuso, L. R., Scaldaferrì, F. and Pizarro, T. T., Emerging role of the interleukin (il)-33/st2 axis in gut mucosal wound healing and fibrosis. *Fibrogenesis & Tissue Repair*, **5** (1), 18 (2012).
81. Thaete, L. G., Ahnen, D. J. and Malkinson, A. M. Proliferating cell nuclear antigen (pcna/cyclin) immunocytochemistry as a labeling index in mouse lung tissues. *Cell Tissue Res.*, **256** (1), 167-173 (1989).
82. Wrobel, K.-H., Bickel, D. and Kujat, R. Immunohistochemical study of seminiferous epithelium in adult bovine testis using monoclonal antibodies against ki-67 protein and proliferating cell nuclear antigen (pcna). *Cell Tissue Res.*, **283** (2), 191-201 (1996).
83. Zborek, A., Małusecka, E., Krzyżowska-Gruca, S., Wysocka, A. and Krawczyk, Z. Immunohistochemical studies on the expression pattern of molecular chaperones hsc70 and hsp25 and cell cycle-related proteins cyclin d1 and pcna in rat liver after thioacetamide intoxication. *Histochem. Cell Biol.*, **118** (4), 311-319 (2002).
84. Köhler, T., Pröls, F. and Brand-Saberi, B. Pcn in situ hybridization: A novel and reliable tool for detection of dynamic changes in proliferative activity. *Histochem. Cell Biol.*, **123** (3), 315-327 (2005).
85. Perez-Pomares, J. M., Macias, D., Garcia-Garrido, L. and Munoz-Chapuli, R. Immunolocalization of the vascular endothelial growth factor receptor-2 in the subepicardial mesenchyme of hamster embryos: Identification of the coronary vessel precursors. *The Histochemical Journal*, **30** (9), 627-634 (1998).
86. Baillie, R., Harada, K., Carlile, J., MacLuskey, M., Schor, S. L. and Schor, A. M. Expression of vascular endothelial growth factor in normal and tumour oral tissues assessed with different antibodies. *The Histochemical Journal*, **33** (5), 287-294 (2001).
87. Celik-Ozenci, C., Akkoyunlu, G., Kayisli, U. A., Arici, A. and Demir, R. Localization of vascular endothelial growth factor in the zona pellucida of developing ovarian follicles in the rat: A possible role in destiny of follicles. *Histochem. Cell Biol.*, **120** (5), 383-390 (2003).
88. Aoyama, J., Tanaka, E., Miyauchi, M., Takata, T., Hanaoka, K., Hattori, Y., Sasaki, A., Watanabe, M. and Tanne, K. Immunolocalization of vascular endothelial growth factor in rat condylar cartilage during postnatal development. *Histochem. Cell Biol.*, **122** (1), 35-40(2004).
89. Kria, L., Khalfaoui, T., Mkannez, G., Beltaief, O., Anane, R., Errais, K., Tounsi, L., Zhioua, R., Jilani, S. B. and Ouertani, A. M. Immunohistochemical study of vascular endothelial growth factor (vegf), tumor suppressor protein (p53) and intercellular adhesion molecule (icam-1) in the conjunctiva of diabetic patients. *J. Mol. Histol.*, **36** (6), 381-390 (2005).
90. Mukdsi, J. H., Paul, A. L. D., Gutiérrez, S., Roth, F. D., Aoki, A. and Torres, A. I. Subcellular localisation of vegf in different pituitary cells. Changes of its expression in oestrogen induced prolactinomas. *J. Mol. Histol.*, **36** (8), 447-454 (2005).
91. Maniscalco, W. M. and D'Angio, C. T., Vascular endothelial growth factor. In *Encyclopedia of respiratory medicine*, Laurent, G. J. and Shapiro, S. D., Eds. Academic Press: Oxford, pp 413-418 (2006).
92. Ali, E. M. T., Abdallah, H. I. and El-Sayed, S. M. Histomorphological, vegf and tgf- $\beta$  immunoexpression changes in the diabetic rats' ovary and the potential amelioration following treatment with metformin and insulin. *J. Mol. Histol.*, **51** (3), 287-305 (2020).

93. Bernatz, S., Monden, D., Gessler, F., Radic, T., Hattingen, E., Senft, C., Seifert, V., Ronellenfisch, M. W., Plate, K. H., Harter, P. N. and Baumgarten, P. Influence of vegf-a, vegfr-1-3, and neuropilin 1-2 on progression-free: And overall survival in who grade ii and iii meningioma patients. *J. Mol. Histol.*, **52** (2), 233-243 (2021).
94. Aziz, R. S., Siddiqua, A., Shahzad, M., Shabbir, A. and Naseem, N. Oxyresveratrol ameliorates ethanol-induced gastric ulcer via downregulation of il-6, tnf- $\alpha$ , nf-kb, and cox-2 levels, and upregulation of ttf-2 levels. *Biomed. Pharmacother.*, **110**, 554-560(2019).
95. Zou, Y., Cui, X., Xiang, Q., Guo, M., Liang, Y., Qu, Y. and Yang, X. Protective effect of against ethanol-induced gastric ulcer and its mechanism. *Zhejiang Da Xue Xue Bao Yi Xue Ban*, **50** (5), 561-567 (2021).
96. Navaei-Alipour, N., Mastali, M., Ferns, G. A., Saberi-Karimian, M. and Ghayour-Mobarhan, M., The effects of honey on pro- and anti-inflammatory cytokines: A narrative review. *Phytother. Res.*, **35** (7), 3690-3701(2021).
97. Mahattanadul, S., Kongpuckdee, S., Wiwattanapatapee, R., Tansakul, P., Nitiruangjaras, A. and Hansakul, P. system of curcuminand tetrahydrocurcumin-self-microemulsifying liquid formulation in chronic gastric ulcer model. *Curr. Pharm. Biotechnol.*, **22** (7), 1005-1012 (2021).
98. Mohamed, Y. T., Naguib, I. A., Abo-Saif, A. A., Elkomy, M. H., Alghamdi, B. S. and Mohamed, W. R. Role of adma/ddah-1 and inos/enos signaling in the gastroprotective effect of tadalafil against indomethacin-induced gastric injury. *Biomed. Pharmacother.*, **150**, 113026. (2022).
99. Mahmoud, M. F., Nabil, M., Hasan, R. A., El-Shazly, A. M., El-Ansari, M. A. and Sobeh, M. Pentagalloyl glucose, a major compound in mango seed kernel, exhibits distinct gastroprotective effects in indomethacin-induced gastropathy in rats via modulating the no/enos/inos signaling pathway. *Front. Pharmacol.*, **13**, 800986 (2022).
100. Pelosi, G., Rindi, G., Travis, W. D. and Papotti, M. Ki-67 antigen in lung neuroendocrine tumors: Unraveling a role in clinical practice. *J. Thorac. Oncol.*, **9** (3), 273-284 (2014).
101. Grillo, F., Campora, M., Pigozzi, S., Bonadio, S., Valle, L., Ferro, J., Paudice, M., Dose, B. and Mastracci, L. Methods for restoration of ki67 antigenicity in aged paraffin tissue blocks. *Histochem. Cell Biol.*, **156** (2), 183-190 (2021).
102. Mei, Q. and Sundler, F. Local downregulation of enterochromaffin-like cell histamine formation in ulcer healing: A study in rats. *Digestion*, **60** (3), 227-237 (1999).
103. Waldum, H. L. and Syversen, U. Serum chromogranin a in the control of patients on long-term treatment with inhibitors of acid secretion. *Eur. J. Clin. Invest.*, **31** (9), 741-743 (2001).
104. Waldum, H. L., Sørдал, Ø. and Fossmark, R. Proton pump inhibitors (ppis) may cause gastric cancer – clinical consequences. *Scand. J. Gastroenterol.*, **53** (6), 639-642 (2018).
105. Waldum, H. L., Sørдал, Ø. F. and Mjones, P. G. The enterochromaffin-like [ec] cell—central in gastric physiology and pathology. *Int. J. Mol. Sci.*, **20** (10), 2444 (2019).
106. Liu, T., Zhang, L., Joo, D. and Sun, S.-C. Nf-kb signaling in inflammation. *Signal Transduction and Targeted Therapy*, **2** (1), 17023 (2017).
107. Rofaeil, R. R. and Gaber, S. S. Gastroprotective effect of memantine in indomethacin-induced peptic ulcer in rats, a possible role for potassium channels. *Life Sci.*, **217**, 164-168 (2019).
108. Hu, J., Cai, L., Yao, Z., Zhang, Z., Zhang, M., Zhang, Y., Jiang, L. and Hu, B. Fisetin attenuates gastric mucosal lesions through modulating nuclear factor-kappa b and peroxisome proliferator-activated receptor-a in rats. *Pharmacogn. Mag.*, **16**, 605 (2020).
109. Mirzaei, S., Zarrabi, A., Hashemi, F., Zabolian, A., Saleki, H., Ranjbar, A., Seyed Saleh, S. H., Bagherian, M., Sharifzadeh, S. O., Hushmandi, K., Liskova, A., Kubatka, P., Makvandi, P., Tergaonkar, V., Kumar, A. P., Ashrafizadeh, M. and Sethi, G. Regulation of nuclear factor-kappa b (nf-kb) signaling pathway by non-coding rnas in cancer: Inhibiting or promoting carcinogenesis? *Cancer Lett.*, **509**, 63-80 (2021).
110. Yi, L., Lu, Y., Yu, S., Cheng, Q. and Yi, L. Formononetin inhibits inflammation and promotes gastric mucosal angiogenesis in gastric ulcer rats through regulating nf-kb signaling pathway. *Journal of Receptors and Signal Transduction*, **42** (1), 16-22. (2022).
111. Nakamura, H., Kenmotsu, S.-i., Sakai, H. and Ozawa, H. Localization of cd44, the hyaluronate receptor, on the plasma membrane of osteocytes and osteoclasts in rat tibiae. *Cell Tissue Res.*, **280** (2), 225-233 (1995).
112. Seelentag, W. K. F., Komminoth, P., Saremaslani, P., Heitz, P. U. and Roth, J. Cd44 isoform expression in the diffuse neuroendocrine system. I. Normal cells and hyperplasia. *Histochem. Cell Biol.*, **106** (6), 543-550 (1996).
113. Puré, E. and Cuff, C. A., A crucial role for cd44 in inflammation. *Trends Mol. Med.*, **7** (5), 213-221 (2001).
114. Johnson, P. and Ruffell, B. Cd44 and its role in inflammation and inflammatory diseases. *Inflamm Allergy Drug Targets*, **8** (3), 208-220. (2009).



115. Mishra, M. N., Chandavarkar, V., Sharma, R. and Bhargava, D. Structure, function and role of cd44 in neoplasia. *J. Oral Maxillofac. Pathol.*, **23** (2), 267-272 (2019).
116. Bhavikatti, A., Channigaramaiah, G., Chikkannaiah, P. and Venkataramanappa, S. Cluster of differentiation 44 expression in gastrointestinal malignancies. A study from south india. *J. Lab. Physicians*, (EFirst), 15(3), 365-371 (2023).
117. Morsy, M. A., Heeba, G. H., Abdelwahab, S. A. and Rofaail, R. R. Protective effects of nebivolol against cold restraint stress-induced gastric ulcer in rats: Role of no, ho-1, and cox-1,2. *Nitric Oxide*, **27** (2), 117-122 (2012).
118. Rahman, Z., Dwivedi, D. K. and Jena, G. B. Ethanol-induced gastric ulcer in rats and intervention of tert-butylhydroquinone: Involvement of nrf2/ho-1 signalling pathway. *Hum. Exp. Toxicol.*, **39** (4), 547-562 (2019).
119. Zhou, D., Yang, Q., Tian, T., Chang, Y., Li, Y., Duan, L.-R., Li, H. and Wang, S.-W. Gastroprotective effect of gallic acid against ethanol-induced gastric ulcer in rats: Involvement of the nrf2/ho-1 signaling and anti-apoptosis role. *Biomed. Pharmacother.*, **126**, 110075 (2020).
120. Raish, M., Shahid, M., Bin Jordan, Y. A., Ansari, M. A., Alkharfy, K. M., Ahad, A., Abdelrahman, I. A., Ahmad, A. and Al-Jenoobi, F. I. Gastroprotective effect of sinapic acid on ethanol-induced gastric ulcers in rats: Involvement of nrf2/ho-1 and nf-kb signaling and antiapoptotic role. *Front. Pharmacol.*, **12**, 622815 (2021).
121. Asaad, G. F. and Mostafa, R. E., Lactoferrin mitigates ethanol-induced gastric ulcer via modulation of ros/icam-1/nrf2 signaling pathway in wistar rats. *Iran. J. Basic Med. Sci.*, **25** (12), 1522-1527 (2022).
122. Balaha, M. F., Almalki, Z. S., Alahmari, A. K., Ahmed, N. J. and Balaha, M. F. Ampk/mtor-driven autophagy & nrf2/ho-1 cascade modulation by amentoflavone ameliorates indomethacin-induced gastric ulcer. *Biomed. Pharmacother.*, **151**, 113200 (2022).
123. Rahman, Z., Dwivedi, D. and Jena, G. Ethanol-induced gastric ulcer in rats and intervention of tert-butylhydroquinone: Involvement of nrf2/ho-1 signalling pathway. *Hum. Exp. Toxicol.*, **39** (4), 547-562 (2020).

### تطبيق الكيمياء المناعية النسيجية في نموذج التهاب المعدة التآكلي بالجرذان

مها حمادي

قسم الهستولوجي وبيولوجيا الخلية-كلية الطب- جامعة الاسكندرية- الاسكندرية-مصر

التهاب المعدة التآكلي لا يزال يمثل مشكلة صحية كبيرة، وقد زاد انتشاره في السنوات القليلة الماضية. نظراً لثقله على الصحة والاقتصاد، هناك حاجة إلى مؤشرات حيوية جديدة لفهم الآلية الجزيئية لحدوثه وتطوير علاجات جديدة. وقد برزت الكيمياء المناعية النسيجية كأداة قيمة في البحث في التهاب المعدة، مما يتيح تصور وتحليل بروتينات محددة داخل مقاطع الأنسجة. تهدف هذه المراجعة إلى تقديم نظرة شاملة على تطبيق الكيمياء المناعية النسيجية في البحوث العلمية التي تدرس التهاب المعدة، مع تسليط الضوء على مساهماتها في الكشف عن الآليات الجزيئية المعقدة المشاركة في تطور التهاب المعدة. تأثير التطبيقات المكتسبة من هذه الدراسات الأمل في تطوير علاجات موجهة وتحسين نتائج المرضى في علاج التهاب المعدة التآكلي. وقد تم تحديد واختبار العديد من الجزيئات في السنوات الأخيرة فيما يتعلق بأهميتها السريرية في البحث. في هذه البحث المرجعي، ركزنا على العلامات الجزيئية المعروفة. بالإضافة إلى ذلك، أرفقنا رسوماً توضيحية تمثل التفاعلات الجزيئية الكامنة وراء التسبب في المرض.

الكلمات الدالة: الكيمياء الهستولوجية المناعية، التهاب المعدة التآكلي، قرحة المعدة، COX-2، Nrf